

Can Magnetic Resonance Imaging Differentiate Undifferentiated Arthritis Based on Knee Imaging?

YASSER EMAD, YASSER RAGAB, AHMED SHAARAWY, ALAA ABOU-ZEID, AHMED SAAD, MAGDY FAWZY,
HANI JOKHDAR, and JOHANNES J. RASKER

ABSTRACT. *Objective.* To compare findings as observed on enhanced magnetic resonance imaging (MRI) of the knee joints, in oligoarticular-undifferentiated arthritis (UA) in those with established rheumatoid arthritis (RA) and spondyloarthropathy (SpA).

Methods. A total of 55 patients with knee arthritis were consecutively recruited for the study, including 25 with undifferentiated oligoarthritis of the knee joint(s), 15 fulfilling the American College of Rheumatology criteria for RA and 15 with SpA. Laboratory investigations included erythrocyte sedimentation rate, C-reactive protein, complete blood count, aspartate aminotransferase, alanine aminotransferase, serum creatinine, and urine analysis. In all patients in the UA and in the RA group, rheumatoid factor and anti-CCP2 antibody (ELISA) were tested. All patients underwent enhanced MRI of the more symptomatic knee. All groups were compared in terms of demographics, laboratory investigations, and MRI findings.

Results. Synovial thickness differed significantly in the RA group compared to UA and SpA groups ($p < 0.001$). The RA group showed a higher rate of bony and cartilaginous erosions and bone marrow edema compared to UA and SpA groups ($p < 0.001$). Enthesitis was found in all patients in the SpA group (100%) and differed from RA and UA groups ($p < 0.001$).

Conclusion. Patients with RA showed more destructive changes in terms of synovial thickening, bone marrow edema, cartilaginous and bone erosions compared to UA and SpA groups. Enthesitis is a common feature on MRI in SpA, while absent in the RA and UA groups. This latter finding may have important clinical implications for classification purposes, and can help to determine the evolving pattern of patients with UA of the knee joint. (First Release Aug 1 2009; J Rheumatol 2009; 36:1963–70; doi:10.3899/rheum.081320)

Key Indexing Terms:

ENHANCED MAGNETIC RESONANCE IMAGING
UNDIFFERENTIATED ARTHRITIS OF THE KNEE JOINT RHEUMATOID ARTHRITIS
SERONEGATIVE ARTHROPATHY INFLAMMATORY SYNOVITIS

Magnetic resonance imaging (MRI) has advanced our understanding of many types of arthritis, with respect both to inflammatory processes and articular damage¹. High sensitivity for the detection of inflammatory and destructive changes in inflammatory joint diseases makes MRI poten-

From the Departments of Rheumatology and Rehabilitation, Radiology, Public Health, and Internal Medicine, Faculty of Medicine, Cairo University, Cairo, Egypt; and University Twente, Enschede, The Netherlands.

Y. Emad, MD, Department of Rheumatology and Rehabilitation, Cairo University, Dr. Erfan and Bagedo General Hospital, Jeddah, Saudi Arabia; Y. Ragab, MD, Department of Radiology, Cairo University, Dr. Erfan and Bagedo General Hospital; A. Shaarawy, Department of Ophthalmology, Cairo University, Dr. Erfan and Bagedo General Hospital; A. Abou-Zeid, MD, Department of Public Health, Cairo University; A. Saad, MD; M. Fawzy, MD, Department of Internal Medicine, Cairo University, Dr. Erfan and Bagedo General Hospital; H. Jokhdar, PhD, Department of Community Medicine and Pilgrims Health Care, Makkah, Dr. Erfan and Bagedo General Hospital, Jeddah, Saudi Arabia; J.J. Rasker, MD, University Twente.

Address correspondence to Dr. Y. Emad, Department of Rheumatology and Rehabilitation, Faculty of Medicine, Cairo University, Cairo 12613, Egypt. E-mail: vasseremad68@yahoo.com

Accepted for publication April 2, 2009.

tially useful for assigning specific diagnoses, such as rheumatoid arthritis (RA) and psoriatic arthritis (PsA), in arthritis that remains undifferentiated after conventional clinical, biochemical, and radiographic examinations². Models are being developed of how to predict the future of patients with early undifferentiated arthritis (UA), to make early diagnosis possible³.

The role of MRI in differentiating between different forms of arthritis is still under discussion. MRI has been applied for defining subsets of early synovitis patients on the basis of the distribution pattern of the inflammation⁴. The data suggest 2 principal imaging patterns, one where the inflammatory changes are based primarily in the synovium, and another where the periarticular entheses are inflamed in association with intense edema of the adjacent bone. These 2 patterns are proposed to broadly classify patients with early synovitis into an “RA” phenotype where synovitis is the primary process, and a “spondyloarthropathy” (SpA) phenotype where enthesitis is the primary process and synovitis occurs on a secondary basis⁴. It has been stated that UA of the large joints, in particular the knee joint, at first

presentation is predictive for a high level of radiological destruction of the small joints in RA⁵. Further, enhanced MRI may play an important role in the evaluation of the effect of treatment of patients with early-undifferentiated oligoarthritis of the knees. We showed that after a short episode of conventional disease-modifying antirheumatic drugs (DMARD) treatment, an improvement can be seen regarding synovitis and even bone marrow edema in early arthritis of the knees⁶. Moreover, MRI is a useful tool for assessment of disease activity, progression, and response to therapy in established RA⁷; MRI may help to predict future erosiveness and therapeutic decision making⁸.

The recent European League Against Rheumatism (EULAR) expert panel formed a set of recommendations based on a review of evidence-based literature, including: early referral of patients with arthritis within 6 weeks, the use of MRI in evaluation of such cases, and the early start of DMARD in patients at risk of developing persistent and/or erosive arthritis⁹.

MATERIALS AND METHODS

Synovial fluid was aspirated in 25 patients presenting with unilateral or bilateral knee arthritis. When an inflammatory synovial fluid was found (leukocyte count exceeding 2,000/mm³) without crystals, a full history was taken and detailed rheumatological examination was performed to exclude any peripheral or axial joint involvement (sacroiliac joints, axial mobility tests, and chest expansion), or other extraarticular features such as nail lesions (pits and onycholysis), dactylitis, enthesal sites, distal interphalangeal joint involvement, and psoriatic skin lesions, so that all the patients in this group are perceived as truly undifferentiated cases.

In addition there were 15 RA patients with knee arthritis who fulfilled the American College of Rheumatology criteria for RA¹⁰ (RA group), and another 15 patients with knee arthritis who fulfilled The European Spondylarthropathy Study Group preliminary criteria for the classification of SpA¹¹ (SpA group): 13 with psoriatic and 2 with reactive arthritis. All the patients included in our study were consecutively recruited from the Rheumatology and Rehabilitation outpatient clinic of Dr. Erfan and Bagedo General Hospital. An informed consent was taken from all the participants before enrolling in this study.

Laboratory investigations included erythrocyte sedimentation rate (ESR), C-reactive protein (CRP), hemoglobin, leukocytes, platelets, aspartate aminotransferase, alanine aminotransferase, serum creatinine, urine analysis, rheumatoid factor (RF), anti-cyclic citrullinated peptide (CCP)2 antibody (ELISA), and antinuclear antibodies (ELISA).

Ophthalmological examination in all patients included unaided and best-corrected visual acuity, intraocular pressure assessment, anterior segment evaluation with slit lamp, and fundus examination with indirect ophthalmoscopy and biomicroscopy, and Schirmer's tear test to exclude dry eyes.

MRI protocol. MRI/gadolinium-enhanced MRI was done for all patients with unilateral presentation and for the more symptomatic knee in cases of bilateral knee involvement. Siemens EXPERT 1 TESLA and General Electric 1.5 TESLA MR Units were used; both units are equipped with a dedicated cylindrical knee coil. Sagittal, coronal, and axial, T1-weighted, spin echo MRI were obtained. Immediately after the acquisition of baseline images, bolus intravenous Gd-DTPA was administered 0.05 mmol Gd-DTPA (Schering, Berlin, Germany)/kg body weight including fat saturation. Detailed MR sequences and imaging measures are illustrated in Table 1.

Interpretation of MRI findings. The MRI were evaluated for the following radiological signs before and after intravenous contrast injection: bone marrow edema, bone erosions, cartilaginous erosions, synovial cyst, Baker's

cyst, periarticular soft tissue edema, knee effusion, and synovial thickness and distribution.

Joint effusion size was subjectively graded within the suprapatellar bursa, intercondylar region, and tibiofibular joint as follows: mild, moderate, and large. Articular cartilage was assessed for contour (smooth vs irregular) and focal destruction (intact, superficial loss and/or thinning, or deep erosions to subchondral bone). Bone was assessed for marrow signal intensity abnormalities and focal erosions.

Signal intensities in the regions of interest (ROI), identified as the synovial membrane of the suprapatellar pouch, and were measured on MRI. Maximal synovium thickness was measured in the suprapatellar pouch on sagittal T1-weighted gadolinium-enhanced images.

Special emphasis was given to the following enthesal sites and carefully evaluated for abnormalities: the quadriceps tendon insertion, the proximal and distal patellar tendon, the iliotibial band insertion, the lateral collateral ligament origin and insertion, the lateral capsular insertions, the cruciate ligaments origins and insertions, the biceps femoris insertion, the semimembranosus insertion and the medial collateral ligament origin and insertion. Focal areas of abnormal signal adjacent to the superior and inferior attachments of the posterior capsule and related calf muscle origins were also considered as enthesitis. An experienced musculoskeletal radiologist, who was blinded to the patient's diagnosis, interpreted all MRI scans.

Ethics. The study was approved by the ethical committee of the Dr. Erfan and Bagedo General Hospital and performed following the Declaration of Helsinki principles; all patients gave informed written consent before participation.

Statistical analysis. Data were coded and summarized using SPSS version 12.0 for Windows. Quantitative variables were described using mean \pm standard deviation (SD) and categorical data by using frequency and percentage. Analysis of variance (ANOVA) test examined the differences among the means of the studied groups of patients. Nonparametric Mann-Whitney U-test compared independent variables, while Spearman's rank correlation test was used as a measure of association of quantitative variables. A p value < 0.05 was considered statistically significant.

RESULTS

In Table 2 the demographic and clinical characteristics of the studied groups of patients are summarized. Multiple comparisons tests (ANOVA) showed statistically significant differences regarding age; between UA group versus RA group ($p < 0.001$), UA versus SpA ($p = 0.008$), while no statistically significant difference was found between the RA group compared to the SpA group ($p = 0.14$). The disease duration differed between UA group compared to RA group ($p < 0.001$) and between RA group versus SpA group ($p = 0.002$); no significant difference was found between UA group and the SpA group ($p = 0.11$) regarding disease duration. Age at onset differed significantly between UA compared to RA and SpA groups ($p < 0.001$ and $p = 0.008$ consecutively). Details of mean \pm SD for age, disease duration, age at onset, and other clinical characteristics in each group are illustrated in Table 2.

The RA group of patients showed significantly higher CRP levels compared to UA and SpA groups ($p = 0.008$ and $p = 0.005$, respectively), while no significant difference was found in CRP levels between UA group compared to SpA group ($p = 0.613$). ESR did not differ between the study groups. Other laboratory investigations among the groups of patients are summarized in Table 3.

Detailed MRI findings observed in the studied groups of

Table 1. Detailed MR sequences and imaging measures.

Sequence	Measures
Coronal T2-weighted	TR/TE: 2600-24/68; matrix size: 256 × 160; section thickness: 4 mm; spacing 0.5 mm; FOV: 16 × 16.
Coronal STIR	TR/TE: 5250-94/68; matrix size: 256 × 160; section thickness: 4 mm; spacing 0.5 mm; FOV: 16 × 16.
Sagittal T2	TR/TE: 2600-24/68; matrix size: 256 × 160; section thickness: 4 mm; spacing 0.5 mm; FOV: 16 × 16.
Sagittal STIR	TR/TE: 5250-49; matrix size: 256 × 160; section thickness: 4 mm; spacing 0.5 mm; FOV: 16 × 16.
Axial T1	TR/TE: 450-11.2; matrix size: 320 × 192; section thickness: 4 mm; spacing 0.5 mm; FOV: 16 × 16.
Axial T2	TR/TE: 2600-23.5; matrix size: 256 × 192; section thickness: 4 mm; spacing: 0.5 mm; FOV: 16 × 16.

TR: repetition time; TE: echo time; FOV: field of view; STIR: short tau inversion recovery sequence.

Table 2. Demographic features and clinical characteristics among the groups of patients.

Characteristic	Group 1 (UA) n = 25	Group 2 (RA) n = 15	Group 3 (SpA) n = 15
Sex (F/M)	9/16	8/7	6/9
Age*	33.0 ± 5.7	43.3 ± 9.3	39.5 ± 7.3
Disease duration, mos*	14.4 ± 7.3	34.7 ± 17.1	20.6 ± 11.5
Age at onset*	31.8 ± 5.2	40.7 ± 8.5	37.8 ± 7.2
Family history			
RA	2 (8)	2 (13.3)	0 (0)
PsA	1 (4)	0 (0)	1 (6.7)
Enthesopathy	0 (0)	NA	8 (53.3)
Dactylitis	0 (0)	0 (0)	7 (46.7)
Psoriatic skin lesions	0 (0)	NA	13 (86.7)
Nail changes (pits & onycholysis)	0 (0)	0 (0)	5 (6.7)
Sacroiliitis	0 (0)	0 (0)	2 (13.3)
Anterior uveitis	0 (0)	0 (0)	4 (26.7)
Dry eyes	0 (0)	3 (20)	0 (0)

* Data are mean ± standard deviation. All other data are percentages. UA: undifferentiated arthritis; RA: rheumatoid arthritis; SpA: spondyloarthropathy; NA: not applicable.

Table 3. Laboratory findings among the studied groups of patients.

Laboratory finding	Group 1 (UA) n = 25	Group 2 (RA) n = 15	Group 3 (SpA) n = 15
ESR, mm/h*	46.5 ± 14.1	55.1 ± 12.3	45.6 ± 9.1
CRP, mg/dl*	2.6 ± 1.2	3.6 ± 1.2	2.4 ± 0.8
Mean RF titer*	11.3 ± 24.6	109.7 ± 129.7	NA
Mean anti-CCP titer*	70.3 ± 97.8	275.2 ± 136.4	NA
RF			
Positive	4/25	10/15	NA
Negative	21/25	5/15	NA
Anti-CCP ²			
Positive	13/25	15/15	NA
Negative	12/25	0/15	NA
RF-negative and anti-CCP negative	11/25	0/15	NA
RF-negative and anti-CCP-positive	9/25	5/15	NA
RF-positive and anti-CCP-positive	4/25	10/15	NA

* Data are mean ± standard deviation. RF: rheumatoid factor; CRP: C-reactive protein; Anti-CCP: anti-cyclic citrullinated peptide; ANA: antinuclear antibody; UA: undifferentiated arthritis; RA: rheumatoid arthritis; SpA: spondyloarthropathy; NA: not applicable.

patients are illustrated in Table 4; significant differences regarding synovial thickness were found between UA group versus RA and SpA groups ($p < 0.001$ and $p = 0.01$, respectively); synovial thickness also differed significantly

between RA and SpA groups ($p < 0.001$). Detailed frequency and percentages of other detected MRI lesions in each group are shown in Table 4. The differences remained significant after correcting for age and disease duration.

Table 4. Detailed MRI findings among the studied groups of patients.

MRI feature	Group 1 (UA) n = 25	Group 2 (RA) n = 15	Group 3 (SpA) n = 15
Mean synovial thickness, mm*	4.33 ± 1.47	6.53 ± 2.16	3.03 ± 0.93
Cartilaginous erosions	9 (36)	12 (80)	8 (53.3)
Bone erosions	4 (16)	13 (86.7)	5 (33.3)
Soft tissue edema	12 (48)	14 (93.3)	6 (40)
Bone marrow edema	3 (12)	13 (86.7)	8 (53.3)
Enthesitis by MRI	3 (12)	0 (0)	15 (100)
Baker's cyst	2 (13.3)	12 (80)	2 (13.3)
Mild knee effusion	6 (24)	1 (6.7)	4 (26.7)
Moderate knee effusion	8 (32)	6 (40)	9 (60)
Large knee effusion	11 (44)	8 (53.3)	2 (13.3)

* Data are mean ± standard deviation. All other data are n (%). MRI: magnetic resonance imaging; UA: undifferentiated arthritis; RA: rheumatoid arthritis; SpA: spondyloarthropathy.

In the RA group, a significantly higher rate of cartilaginous erosions was detected compared to the UA group ($p = 0.026$). Regarding bone erosions, patients with RA had significantly more bone erosions (86.7%) (Figure 1C) compared to the other 2 groups (UA and SpA) ($p < 0.001$). Also, the same group of patients with RA showed significantly more bone marrow edema (86.7%) (Figure 1A) compared to the other 2 groups ($p < 0.001$). The RA group had significantly more soft tissue edema (93.3%) (Figure 1B) compared to the other 2 groups ($p = 0.005$). The 13 patients with PsA did not differ from the 2 with reactive arthritis.

In the SpA group, results showed that all patients in this group had enthesitis (100%), significantly more than the other 2 groups (RA and UA) ($p < 0.001$). Enthesitis by anatomical localization in the SpA group as observed by MRI showed involvement of fibular collateral ligament in 1 patient (6.7%), fibular insertion of biceps femoris in 2 patients (13.3%), posterior cruciate ligament (PCL) in 4 patients (26.7%), (Figure 2 A, B), medial collateral ligament (MCL) in 7 patients (46.7%) (Figure 2D), and patellar tendon in another 5 patients (33.3%) (Figure 2A), while 3 patients (12%) in UA group showed enthesitis of MCL, and no patients with RA showed enthesitis.

A comparison of the anti-CCP positive patients ($n = 13$) in the UA group with the anti-CCP negative patients ($n = 12$) showed no significant differences regarding age, disease duration, age at onset, ESR, CRP levels, and MRI findings [mean synovial thickness (mm), cartilaginous erosions, bone erosions, soft tissue edema, bone marrow edema, and degree of knee effusion].

No significant correlations were found in the UA group between disease duration and MRI findings assessed (degree of synovial thickening, cartilaginous erosions, bone erosions, soft tissue edema, and bone marrow edema) (Figure 3).

DISCUSSION

The role of MRI in differentiating UA is still debatable, and earlier attempts have incorporated anatomic information. Small

studies have shown that MRI signs of inflammation in RA are more frequent in the synovial membrane than at the insertions of ligaments and tendons (enthesitis), while the opposite is true for seronegative spondyloarthritides such as PsA⁴.

To date, most studies examined MRI changes in the hand joints of patients with RA and seronegative SpA, most commonly PsA^{4,12-16}. A limited number of studies examined the MRI changes in undifferentiated cases by using MRI^{6,17,18}, and only 1 study examined characteristic MRI enthesal changes of knee synovitis in SpA¹⁹.

To our knowledge, ours is the first study to describe changes in the knees as observed by enhanced MRI in a cohort of patients with 3 subsets of the inflammatory process (UD, RA, and SpA).

Imaging may play an important role in the evaluation of patients with early arthritis. Various imaging methods can be utilized to aid with diagnosis, predict prognosis, and follow disease progression and treatment response. Previously, conventional radiography was the principal method used to evaluate and follow bone damage in patients with inflammatory arthritis²⁰.

The potential advantage of using MRI in the differential diagnosis of UA is evident²¹. Further, MRI is considered the modality of choice in early diagnosis and management of RA and provides high sensitivity in detecting inflammatory changes in the joints. Recent advances in MRI technology include contrast enhancement, dynamic and quantitative, which allowed earlier initiation of treatment with disease-modifying therapies²².

PsA of the knee joints has received less research scrutiny than RA in many areas, including imaging¹, although several studies describe the findings in other joints^{4,12,13}. PsA is a diverse condition that may be characterized by peripheral inflammatory arthritis, axial involvement, dactylitis, and enthesitis²².

The diagnosis of RA or PsA is primarily based on clinical findings and laboratory tests, but sometimes it is difficult to differentiate among RA, PsA, or other chronic inflamma-

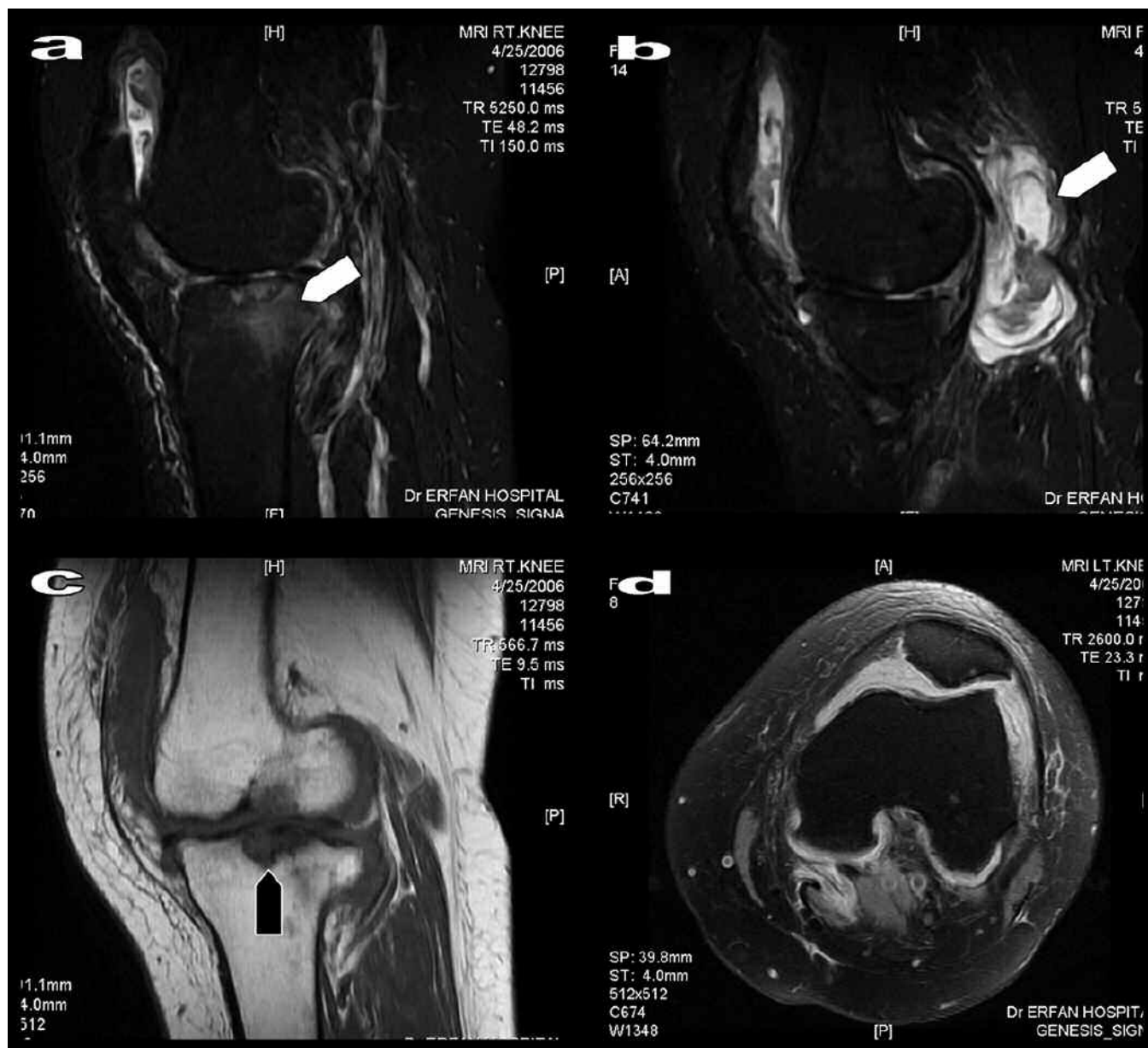

Figure 1. Rheumatoid arthritis: STIR sequence (a and b) showing cartilage loss, bone marrow edema (white arrow), and large Baker's cyst with debris and thick synovium (Pannus). T1 and PD Fat Sat (c and d) showing synovial thickening and bone erosions.

tory joint diseases such as undifferentiated cases that remain undifferentiated after initial clinical, biochemical, and radiographic evaluation. Moreover, the absence of psoriatic skin lesions does not always exclude the diagnosis of PsA, especially in absence of other important features of the disease (e.g., finger nail dystrophy, seronegativity for RF, distal interphalangeal joint involvement, oligoarthritis, asymmetry, and dactylitis).

Our data suggest that MRI allows visualization of soft tissue, articular, and enthesal lesions in PsA and provide a unique picture of the disease process that cannot be gained by using other imaging modalities¹.

Using MRI has helped in the evaluation of PsA by sug-

gesting that the primary site of inflammation is extrasynovial and that synovial inflammation may be a secondary phenomenon²³. Moreover the application of fat-suppression MRI to knee joint swelling in PsA has increased our understanding of these capsular-based changes. Knee pathology in PsA is strongly associated with enthesitis, which is shown as diffuse bone edema or soft tissue and capsular swelling adjacent to the entheses¹⁹.

Utilizing these currently available data can be important in the initial evaluation of undifferentiated oligoarthritis of the knee joint(s) for diagnostic and classification purposes and can also be useful to determine the evolving pattern in these domains.

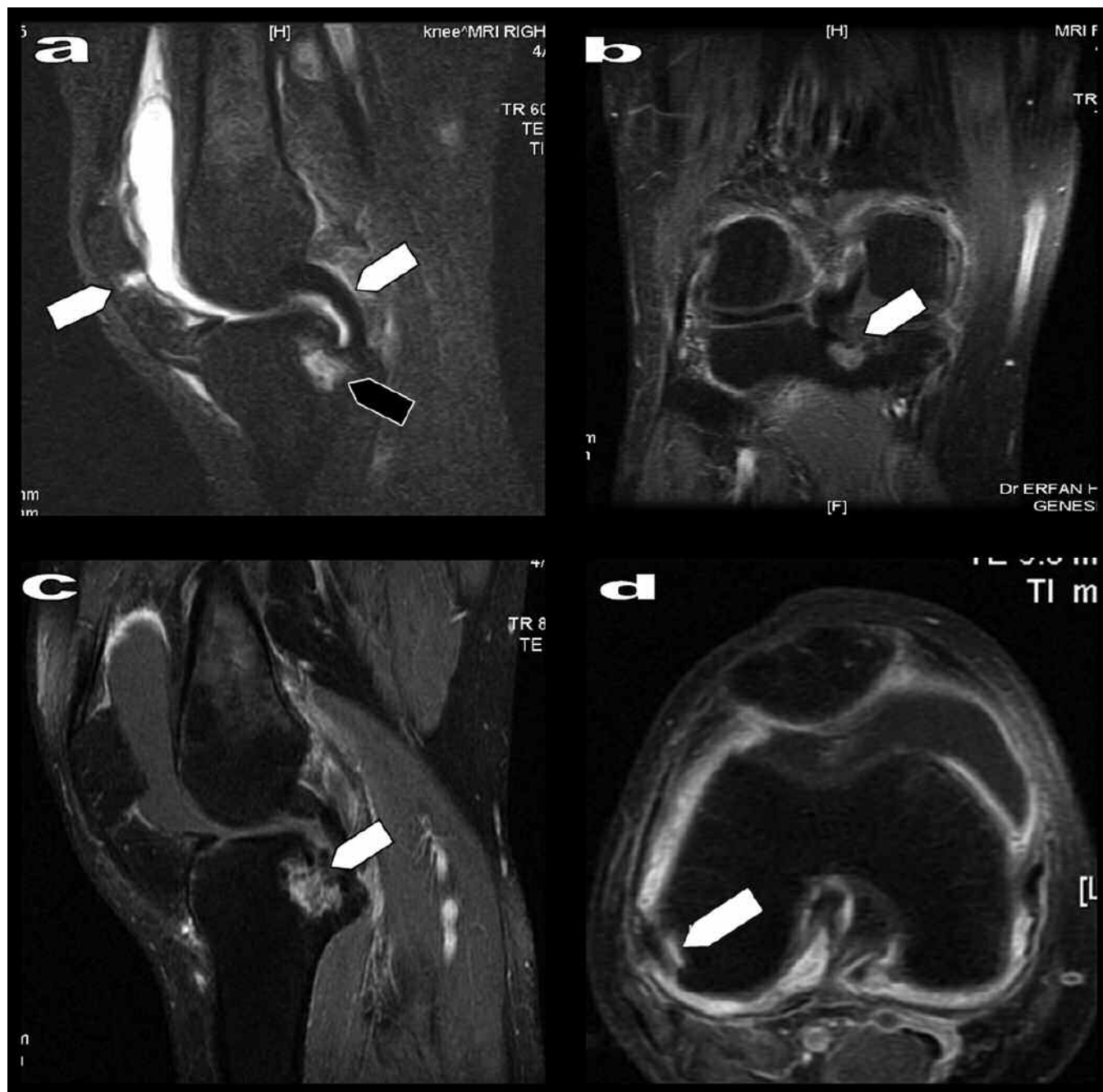


Figure 2. Psoriatic arthritis; Sagittal and Coronal STIR sequence images (a and b) showing enhancement close to the tibial insertion of posterior cruciate ligament (PCL) and moderate effusion. Sagittal and Axial post contrast Fat Sat images (c and d) showing enhancement at enthesal sites close to PCL and MCL and femoral insertions of biceps femoris tendon.

Our findings clearly show that the degree of synovial thickening was more aggressive in the RA group when compared with patients in the seronegative arthropathy group in terms of bone marrow edema, bone erosions, and the degree of synovial thickening. It was previously shown that PsA is characterized by a milder degree of synovitis than RA, with only 8% of patients developing erosions, but this observation was reported in the hand joints²⁴.

Cimmino, *et al*¹³, by using dynamic MRI, found similarity of the synovial membrane in PsA and RA in the wrist joints and concluded that the 2 conditions might be more similar than is usually believed, at least as far as disease activity is concerned. Their observation is in keeping with the fact that the same types of treatment, including sulfasalazine, methotrexate, leflunomide, and anti-tumor necrosis factor- α compounds, are effective in RA and PsA.

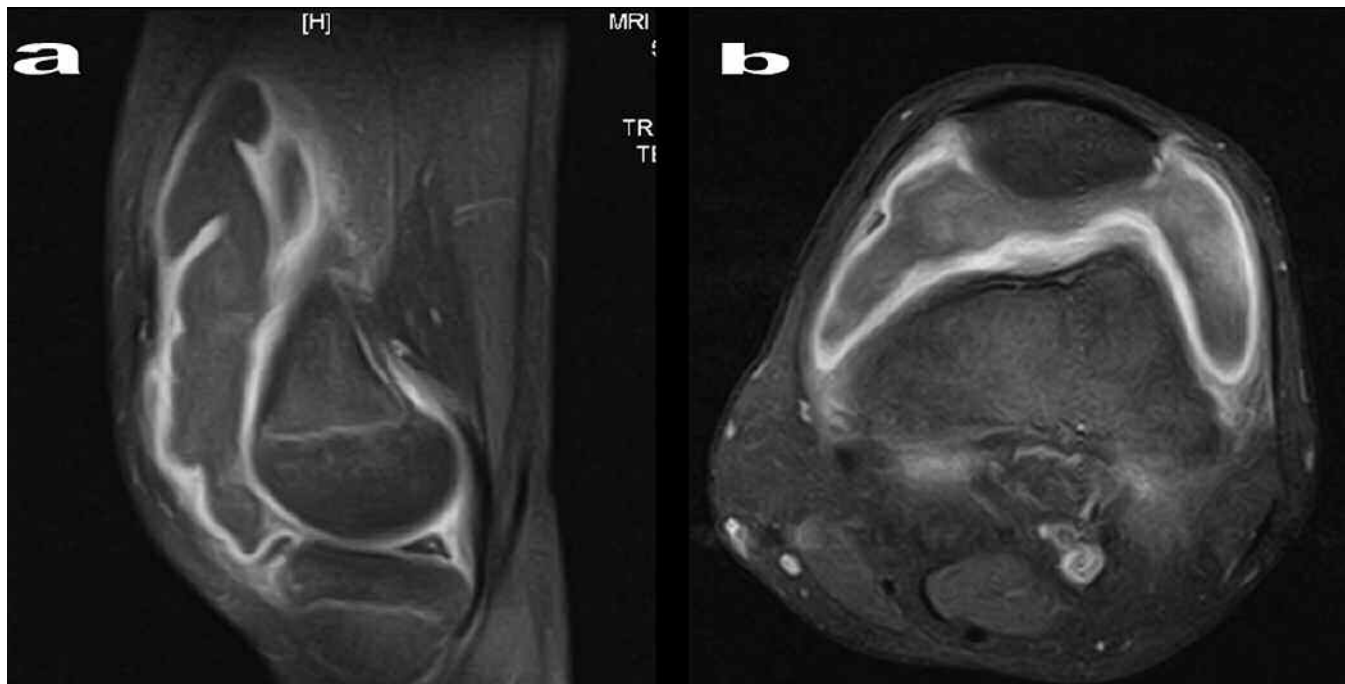


Figure 3. Undifferentiated arthritis: Post contrast T1 Fat Sat showing synovial proliferation and moderate effusion.

However, histopathological studies showed that the inflamed synovial membrane of PsA differs in certain subtle ways from rheumatoid synovium with less lining layer hyperplasia, more subsynovial edema, and a greater number of synovial vessels per square millimeter²⁵.

An important finding in our study is the perientheseal bone marrow edema (enthesitis), which was a common finding in all patients in the SpA group (100%) and in 3 patients in the UA group, all negative for RF and anti-CCP antibodies. In the RA group no perientheseal edema was found. Our findings are in accordance with and extend those observed by McGonagle, *et al*¹⁹, who examined 20 patients with recent onset knee effusion (10 with SpA and 10 with RA) and found that all 10 patients with SpA, but only 4 of the 10 patients with RA, had focal perientheseal high signal (compatible with fluid or edema) outside the joint ($p = 0.01$). The authors observed increased signal on T2-weighted images with characteristic focal extracapsular fluid/edema in enthesal portions of the patellar tendon, the iliotibial band, and adjacent to the posterior capsule of the knee. In their study perientheseal bone marrow edema (enthesitis) was present in 6 patients with PsA, including 1 in whom it involved bone at the tibial plateau as well as bony attachments of the patellar tendon and posterior cruciate ligament. The authors concluded that prominent enthesal abnormalities on MRI are a consistent feature of recent onset synovitis in SpA, but are a minor feature of RA. This finding has important implications for the diagnosis, classification, and mechanisms of synovitis in patients with SpA.

In our study, MRI examination showed enthesitis in all patients in the SpA group: fibular collateral ligament in 1

patient (6.7%), fibular insertion of biceps femoris in 2 (13.3%), posterior cruciate ligament in 4 (26.7%), medial collateral ligament in 7 (46.7%), and patellar tendon in 5 (33.3%). Moreover 3 patients (12%) in the UA group showed enthesitis of MCL, while in the RA group none of the patients showed such an abnormality ($p = 0.01$).

While evidence from MRI studies conducted so far suggests that PsA erosions are rather similar to RA erosions^{26,27}, in our study we observed more destructive changes in terms of cartilaginous and bony erosions in the RA group when compared with SpA group, and these findings are in accordance with those observed by Savnik and colleagues¹⁶. In their study, the authors found that MRI erosions in patients with PsA did not progress over time to the same extent as those in patients with early RA, raising the possibility that PsA bone disease may sometimes be less aggressive.

In our series we found in the UA group that 13 patients were anti-CCP positive of whom 4 were RF positive; these patients probably will evolve in time into RA. Anti-CCP antibodies serve as a powerful serologic marker for early diagnosis of RA and prognostic prediction of joint destruction²⁸. Apart from radiographically detected erosions, anti-CCP is the criterion with the highest odds ratio to discriminate between erosive and nonerosive arthritis²⁹.

Patients with RA showed more destructive changes in terms of synovial thickening, bone marrow edema, cartilaginous and bone erosions compared to UA and SpA groups. Evident enthesal abnormalities on MRI are a common feature in patients with seronegative arthropathy, and were absent in the patients with RA. This latter finding may have

important clinical implications for classification purposes, and can help to determine the evolving pattern of patients with UA of the knee joint.

REFERENCES

- McQueen F, Lassere M, Østergaard M. Magnetic resonance imaging in psoriatic arthritis: a review of the literature. *Arthritis Res Ther* 2006;8:207.
- Østergaard M, Duer A, Hørslev-Petersen K. Can magnetic resonance imaging differentiate undifferentiated arthritis? *Arthritis Res Ther* 2005;7:243–5.
- Vander Cruyssen B, Hoffman IE, Peene I, et al. Prediction models for rheumatoid arthritis during diagnostic investigation: evaluation of combinations of rheumatoid factor, anti-citrullinated protein/peptide antibodies and the human leucocyte antigen-shared epitope. *Ann Rheum Dis* 2007;66:364–9.
- Jevtic V, Watt I, Rozman B, Kos-Golja M, Demsar F, Jarh O. Distinctive radiological features of small hand joints in rheumatoid arthritis and seronegative spondyloarthritis demonstrated by contrast-enhanced (Gd-DTPA) magnetic resonance imaging. *Skeletal Radiol* 1995;24:351–5.
- Linn-Rasker SP, van der Helm-van Mil AH, Breedveld FC, Huizinga TW. Arthritis of the large joints in particular, the knee at first presentation is predictive for a high level of radiological destruction of the small joints in rheumatoid arthritis. *Ann Rheum Dis* 2007;66:646–50.
- Emad Y, Ragab Y, Shaarawy A, Raafat H, El-Kiki HA, Rasker JJ. Enhanced MRI in early-undifferentiated oligoarthritis of the knee joints: Improvements already visible after 2 months of DMARDs treatment. *Clin Rheumatol* 2008;27:1177–82.
- Hodgson RJ, O'Connor P, Moots R. MRI of rheumatoid arthritis image quantitation for the assessment of disease activity, progression and response to therapy. *Rheumatology* 2008;47:13–21. Epub 2007 Nov 28.
- Palosaari K, Vuotila J, Takalo R, et al. Bone oedema predicts erosive progression on wrist MRI in early RA—a 2-yr observational MRI and NC scintigraphy study. *Rheumatology* 2006; 45:1542–8. Epub 2006 May.
- Combe B, Landewe R, Lukas C, et al. EULAR recommendations for the management of early arthritis: report of a task force of the European Standing Committee for International Clinical Studies Including Therapeutics (ESCISIT). *Ann Rheum Dis* 2007;66:34–5.
- Arnett FC, Edworthy SM, Bloch DA, et al. The American Rheumatism Association 1987 revised criteria for the classification of rheumatoid arthritis. *Arthritis Rheum* 1988;31:315–24.
- Dougados M, van der Linden S, Juhlin R, et al. The European Spondylarthropathy Study Group preliminary criteria for the classification of spondylarthropathy. *Arthritis Rheum* 1991;34:1218–30.
- Giovagnoni A, Grassi W, Terelli F, et al. MRI of the hand in psoriatic and rheumatoid arthritis. *Eur Radiol* 1995;5:590–5.
- Cimmino MA, Parodi M, Innocenti S, et al. Dynamic magnetic resonance of the wrist in psoriatic arthritis reveals imaging patterns similar to those of rheumatoid arthritis. *Arthritis Res Ther* 2005;7:725–31.
- Malmkskov H, Thomsen HS, Graff LB, et al. Magnetic resonance imaging of the wrist and finger joints in patients with inflammatory joint diseases. *J Rheumatol* 2001;28:2193–200.
- Schoellnast H, Deutschmann HA, Hermann J, et al. Psoriatic arthritis and rheumatoid arthritis: findings in contrast-enhanced MRI. *AJR Am J Roentgenol* 2006;187:351–7.
- Savnik A, Malmkskov H, Thomsen HS, et al. MRI of the wrist and finger joints in inflammatory joint diseases at 1-year interval: MR features to predict bone erosions. *Eur Radiol* 2002;12:1203–10.
- Emad Y, Ragab Y, Shaarawy A. The diagnostic dilemma of undifferentiated inflammatory synovitis of the knee joint/joints: a comprehensive approach. *APLAR Journal* 2007;10:182–9.
- Narvaez J, Sirvent E, Antonio Narvaez J, et al. Usefulness of magnetic resonance imaging of the hand versus anticyclic citrullinated peptide antibody testing to confirm the diagnosis of clinically suspected early rheumatoid arthritis in the absence of rheumatoid factor and radiographic erosions. *Semin Arthritis Rheum* 2008;38:101–9. Epub 2008 Jan 25.
- McGonagle D, Gibbon W, O'Connor P, Green M, Pease C, Emery P. Characteristic magnetic resonance imaging enthesal changes of knee synovitis in spondylarthropathy. *Arthritis Rheum* 1998;41:694–700.
- Evangelisto A, Wakefield R, Emery P. Imaging in early arthritis. *Best Pract Res Clin Rheumatol* 2004;18:927–43.
- Tehranezhad J, Ashikyan O, Dascalos J. Magnetic resonance imaging in early detection of rheumatoid arthritis. *Semin Musculoskelet Radiol* 2003;7:79–94.
- Marsal S, Armadans-Gil L, Martinez M, Gallardo D, Ribera A, Lience E. Clinical, radiographic and HLA associations as markers for different patterns of psoriatic arthritis. *Rheumatology* 1999;38:332–7.
- McGonagle D, Conaghan PG, Emery P. Psoriatic arthritis: a unified concept twenty years on. *Arthritis Rheum* 1999;42:1080–6.
- Shbeeb M, Uramoto KM, Gibson LE, O'Fallon WM, Gabriel SE. Epidemiology of psoriatic arthritis in Olmsted County, Minnesota, USA, 1982–1991. *J Rheumatol* 2000;27:1247–50.
- Reece RJ, Canete JD, Parsons WJ, Emery P, Veale DJ. Distinct vascular patterns of early synovitis in psoriatic, reactive and rheumatoid arthritis. *Arthritis Rheum* 1999;42:1481–4.
- Backhaus M, Kamradt T, Sandrock D, et al. Arthritis of the finger joints. A comprehensive approach comparing conventional radiography, scintigraphy, ultrasound and contrast-enhanced MRI. *Arthritis Rheum* 1999;42:1232–4.
- Savnik A, Malmkskov H, Thomsen HS, et al. Magnetic resonance imaging of the wrist and finger joints in patients with inflammatory joint diseases. *J Rheumatol* 2001;28:2193–200.
- Mimori T. Clinical significance of anti-CCP antibodies in rheumatoid arthritis. *Intern Med* 2005;44:1122–6.
- Prujin GJM, Vossenaar ER, Drijfhout JW, van Venrooij WJ, Zendman AJW. Anti-CCP antibody detection facilitates early diagnosis and prognosis of rheumatoid arthritis. *Curr Rheum Rev* 2005;1:1–7.