Sensitivity and Specificity of Ultrasonography in Early Diagnosis of Metatarsal Bone Stress Fractures: A Pilot Study of 37 Patients

FRÉDÉRIC BANAL, FRÉDÉRIQUE GANDJBAKHCH, VIOLAINE FOLTZ, ALAIN GOLDCHER, FABIEN ETCHEPARE, SYLVIE ROZENBERG, ANNE-CLAUDE KOEGER, PIERRE BOURGEOIS, and BRUNO FAUTREL

ABSTRACT. ***Objective.*** To date, early diagnosis of stress fractures depends on magnetic resonance imaging (MRI) or bone scan scintigraphy, as radiographs are usually normal at onset of symptoms. These examinations are expensive or invasive, time-consuming, and poorly accessible. A recent report has shown the ability of ultrasonography (US) to detect early stress fractures. Our objective was to evaluate sensitivity and specificity of US versus dedicated MRI (0.2 Tesla), taken as the gold standard, in early diagnosis of metatarsal bone stress fractures.

Methods. A case-control study from November 2006 to December 2007 was performed. All consecutive patients with mechanical pain and swelling of the metatarsal region for less than 3 months and with normal radiographs were included. US and dedicated MRI examinations of the metatarsal bones were performed the same day by experienced rheumatologists with expertise in US and MRI. Reading was undertaken blind to the clinical assessment and MRI/US results.

Results. Forty-one feet were analyzed on US and dedicated MRI from 37 patients (28 women, 9 men, mean age 52.7 ± 14.1 yrs). MRI detected 13 fractures in 12 patients. Sensitivity of US was 83%, specificity 76%, positive predictive value 59%, and negative predictive value 92%. Positive likehood ratio was 3.45, negative likehood ratio 0.22.

Conclusion. In cases of normal radiographs, US is indicated in the diagnosis of metatarsal bone stress fractures, as it is a low cost, noninvasive, rapid, and easy technique with good sensitivity and specificity. From these data, we propose a new imaging algorithm including US. (First Release July 1 2009; J Rheumatol 2009;36:1715–9; doi:10.3899/jrheum.080657)

Key Indexing Terms:
STRESS FRACTURE METATARSAL BONE ULTRASONOGRAPHY
DEDICATED MAGNETIC RESONANCE IMAGING SENSITIVITY

Stress fractures are bone injuries occurring as a result of repeated cyclical loading of the bone. They represent a lack of adaptation of the bone to repetitive loading stress[1]. In athletes with stress fractures, metatarsal localization is estimated at 8.8% of cases[2]. An annual incidence of 10% in a 3-year prospective study confirmed these data[3]. Mechanical pain is the main revealing symptom. Examination generally shows tenderness in the affected area and pain on bone palpation. The surrounding soft tissues may become swollen, especially when the fracture affects superficial bones such as metatarsal bones. At this point, stress fractures can be misdiagnosed as arthritis, tendonitis, or vascular disease. Patient interviews often reveal a history of recent changes in the type, duration, or frequency in running or walking activities, but no specific trauma[1]. Early diagnosis of such injuries is important to stop the progression of disease, which may result in a complete fracture. Sensitivity of plain radiographs in the early stages of symptoms may be as low as 10%, and 30%–70% at followup[4-8]. To date, early diagnosis of stress fractures relies on magnetic resonance imaging (MRI) or bone scan scintigraphy, which are expensive, invasive, or poorly accessible[9]. A study suggested that ultrasound (US) may be of interest in early diagnosis of metatarsal stress fractures[10]. To date, no study has evaluated the sensitivity and specificity of this technique. Our aim was to evaluate the sensitivity and specificity of US versus dedicated MRI that is taken as the gold standard.

From the Faculty of Medicine, Paris Pierre et Marie Curie University; and APHP, Rheumatology Department, Pitié-Salpétrière Hospital, Paris, France.

F. Banal, MD; F. Gandjbakhch, MD; V. Foltz, MD; A. Goldcher, MD; F. Etchepare, MD; S. Rozenberg, MD; A-C. Koeger, MD; P. Bourgeois, MD, PhD; B. Fautrel MD, PhD.

Address correspondence to Prof. B. Fautrel, Rhumatologie, Hôpital Pitié-Salpétrière, 47-83 Boulevard de l'Hôpital, 75013 Paris, France. E-mail: bruno.fautrel@psl.aphp.fr

Accepted for publication January 4, 2009.

MATERIALS AND METHODS

This prospective study was performed in the rheumatology department of Pitié-Salpétrière Hospital, Paris, between November 2006 and December 2007. Inclusion criteria were clinical suspicion of metatarsal bone foot stress fracture, i.e., mechanical pain and swelling of the metatarsal region, symptom duration ≤ 3 months, and normal findings on plain radiographs. Exclusion criteria were any contraindication for dedicated MRI and refusal

to participate in the study. The gray cortex sign, endosteal callus, periosteal callus, and fracture line were the radiographic signs of a stress injury to bone. All radiographs were considered as normal.

All patients were informed and provided signed approval for participation. Because of the noninvasive examination method, no approval of the Medical Ethics Committee of the hospital was required.

All patients underwent US and dedicated MRI on the same day. US was performed on an Esaote® Technos MP system and a 7.5–13 MHz linear transducer. All metatarsal bones in the painful foot were investigated. Only the dorsal aspect of the foot was investigated, in longitudinal and axial views. Total duration of examination was about 15 minutes for each foot.

Positive diagnosis of acute metatarsal stress fracture was defined as the presence of 2 out of 3 of the following US signs: hypoechoic periosteal elevation above cortical bone, cortical disruption, and increased vascularity observed on positive power Doppler signal around the periosteal lesion[10]. All US scans were performed by the same experienced investigator (FB), blinded in regard to the clinical and radiological findings.

Dedicated MRI was done on a 0.2 Tesla unit E-scan XQ Esaote® device. A coil suitable for imaging of the foot was used. Routine coronal T1-weighted 3-D sequence images were obtained (TR 35 ms, TE 16 ms, with 1 signal averaged, and a 192 × 136 × 400 mm matrix) and followed by a coronal STIR sequence (1460/26, TI 85 ms, with 2 signals averaged and a 192 × 122 mm matrix). The field of view was 190 × 190 × 50 and 200 × 190 mm, respectively, and slice thickness was 0.8 mm with a 0.08 mm intersection gap and 4 mm with 0.4 mm gap. Routine axial T1-weighted 3-D sequence images were obtained (TR 50 ms, TE 16 ms, 1 signal averaged, 192 × 182 × 40 mm matrix), followed by an axial STIR sequence (980/26, TI 85 ms, 2 signals averaged, 192 × 144 mm matrix). The field of view was 180 × 180 × 90 and 200 × 200 mm, respectively, and slice thickness was 1.4 mm with an intersection gap of 0.01 mm and 4 mm with a gap of 0.4 mm. Total duration of the examination was 30–45 min for each foot. MRI were read by 2 rheumatologists (FG and VF) trained for reading of MR images who were unaware of the clinical and US findings. In cases of disagreement between the 2 readers, a third consensus reading was performed. Diagnosis of the metatarsal fracture was made upon edema of the bone marrow, periosteum, and muscle surrounding the bones, as well as a fracture line and callus in the cortical bone. Edema was represented as an intermediate signal intensity on T1-weighted images, and as high signal intensity on STIR images. A fracture line was defined as a low signal intensity line on all MR images.

The sensitivity, specificity, positive predictive value (PPV), negative predictive value (NPV), positive likehood ratio, and negative likehood ratio were calculated for US findings.

RESULTS

The series consisted of 37 consecutive patients who were referred for imaging diagnosis (28 women, 9 men, ages 22–80 yrs, mean 52.7 ± 14.1 yrs). Mean time of delay between initial symptoms and examination was 6.1 ± 3.2 weeks. Four of the 37 patients had bilateral foot pain, so a total of 41 feet were examined. All patients had undergone a conventional radiographic examination before being referred to our hospital. Radiographs had been obtained within an average of 19.2 ± 19.1 days (range 0–87 days). Seven of the 37 patients had radiographs performed after 1 month. The average time between onset of symptoms and acquisition of radiographs among the patients diagnosed with stress fractures was 3.6 ± 2.4 weeks. The average time between onset of symptoms and acquisition of radiographs among patients without stress fractures was 3.4 ± 2.8 weeks. Thus no significant difference was found between the 2 groups.

Dedicated MRI was regarded as the gold standard. A total of 13 stress fractures of the metatarsal bone were diagnosed in 12 patients. Seven fractures involved the second metatarsal bone (Figures 1 to 5), 3 the third metatarsal bone, 2 the first metatarsal bone, and one the fourth metatarsal bone. The final diagnosis of the remaining patients was mechanical metatarsalgia. Compared with findings from dedicated MRI scans, sonography depicted 11 true-positive, 21 true-negative, 2 false-negative, and 7 false-positive cases of metatarsal stress fractures. Sensitivity of US scans was 83.3%, specificity 75.9%, PPV 58.8%, and NPV 91.7%. The positive likehood ratio was 3.45, negative likehood ratio 0.22. Retrospectively, the localizations of suspected stress fractures determined by clinical examination were false and not confirmed on MRI in 3/12 cases. The main antecedent factors were rheumatoid arthritis in 2 cases, Crohn's disease in 1 case, previous foot surgery (hallux valgus) in 1 case, and short first metatarsal in 2 cases. No patient had any history of osteoporotic fracture. Those patients with rheumatoid arthritis and Crohn's disease all had positive MRI results and 2 had positive US.

On 2 false-negative cases of metatarsal stress fractures, one concerned the diaphysis of the left third metatarsal bone, and the other the diaphysis fracture of the right second metatarsal bone.

On 7 false-positive cases of metatarsal stress fractures, 3 concerned the proximal part of the fourth metatarsal bone, 3 the head part of the second metatarsal bone, and one the proximal part of the third metatarsal bone. The MRI diagnosis of the 7 false-positive cases was mechanical metatarsalgia.

DISCUSSION

Clinical diagnosis of stress bone injuries may be difficult, and requires morphologic confirmation by imaging techniques to prevent any misdiagnosis and eventual complete metatarsal fracture. Plain radiographs remain the primary imaging tool because the method is both widely available and inexpensive. However, for early detection of bone stress injuries, sensitivity of plain radiographs is too low, even at followup. For early detection of stress fractures, bone

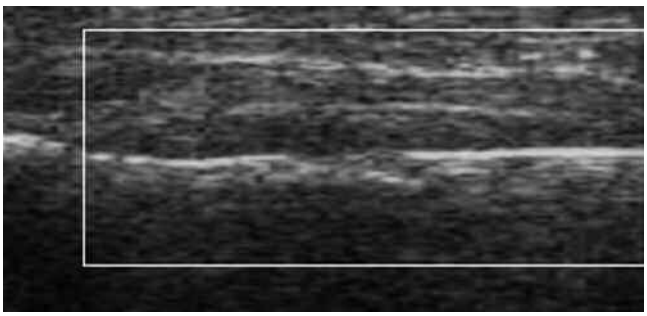

Figure 1. Longitudinal ultrasound image of second metatarsal bone diaphysis shows distinct cortical thickening with periosteal hematoma.

scintigraphy and MRI are the more usual imaging tools in daily practice; they have a higher diagnostic value than plain radiography. Bone scintigraphy has been considered the best diagnostic method for stress fractures since the 1970s, because it shows an increase in bone uptake 24–36 hours after the fracture and remains for several months[1]. This increase in bone uptake is related to the increase in bone remodeling, and although it is a very sensitive method, it is not specific for the diagnosis of stress fractures, which can be misdiagnosed as tumoral or infectious processes. Moreover, cases of false-negative bone scintigraphy results of bone stress injuries have been reported[11-15]. Given this limitation, bone scintigraphy examinations must be interpreted with close correlation of both plain radiographs and the patient's clinical history[9]. MRI identifies the line of fracture and also shows the surrounding edema. For these reasons, MRI seems to be more specific in stress fracture diagnosis, as described[16,17], and should be used as the gold standard in the assessment of bone stress injuries. Finally, this is a noninvasive and rapid examination (about 30–45 minutes), whereas 2-phase bone scintigraphy requires intravenous injection with a first acquisition 5 minutes later and a second 3 hours later. Dedicated MRI shows high agreement with conventional MRI in diagnosing and scoring synovitis, tenosynovitis, and erosions in rheumatoid arthritis and for the diagnosis of foot and ankle injuries[18-22]. Further, this imaging technique is more readily accepted than high-field MRI due to comfort, claustrophobia, and noise considerations[21]. For all these reasons, we chose dedicated MRI as the gold standard.

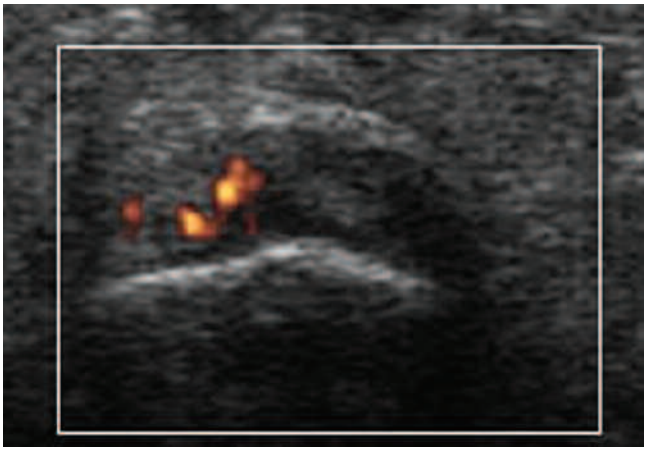

Figure 2. Axial ultrasound image of second metatarsal bone diaphysis shows distinct cortical thickening with periosteal hematoma and power Doppler signal.

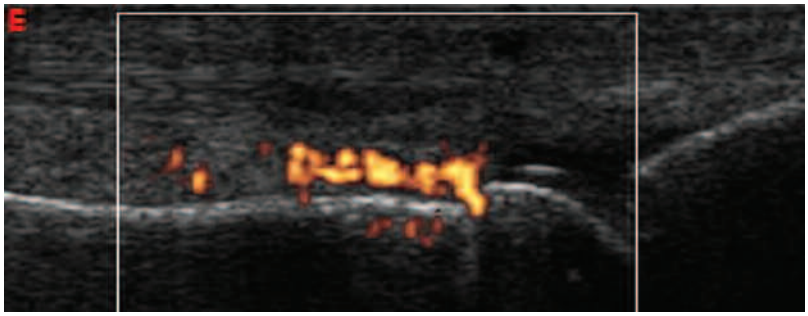

Figure 3. Longitudinal ultrasound image of second metatarsal bone head shows distinct power Doppler signal inside a periosteal hematoma and reactional synovitis.

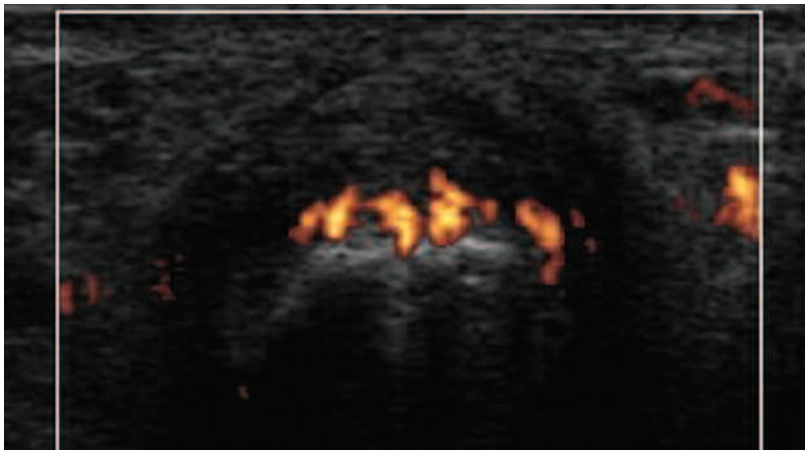

Figure 4. Axial ultrasound image of second metatarsal bone head shows distinct cortical thickening with periosteal hematoma and power Doppler signal.

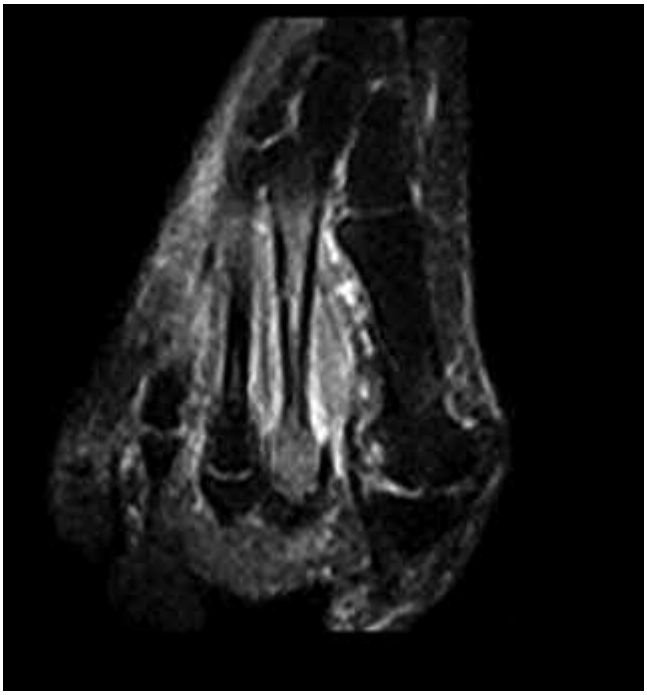

Figure 5. Coronal-STIR MRI demonstration of a stress fracture of the second metatarsal bone: hypersignal of the second metatarsal bone.

Regarding the inclusion criteria, we chose normal radiographs because they display the radiographic features of stress fracture, therefore sonography is not required to ascertain the diagnosis. As sensitivity of plain radiographs in the early stages of symptoms is low, even at followup, US appears to be more sensitive than radiographs to confirm the diagnosis in order to prevent the risk of a complete fracture. Moreover, sonography is as accessible as radiography.

As the average time between the onset of symptoms and acquisition of radiographs in the patients diagnosed with and without stress fracture was not significantly different, it could not be expected that a negative radiograph taken after 1 month from the onset of symptoms would have less probability of being associated with a fracture than an early one.

In addition, we chose a duration of less than 3 months to take into account the average time between the onset of symptoms and the consultation with the rheumatologist. Moreover, the average time between the onset of symptoms and sonography/MRI investigations was 6.1 ± 3.2 weeks, confirming that our choice was correct.

The expected incidence of stress fracture was 50%, and we found a 35% incidence in our study. The difference observed could partially be explained by the fact that patients who had a positive radiograph were not included.

The number of patients taking part in our study was low, but this allowed us to determine sensitivity and specificity. However, a preceding study over a 3-year period included only 35 patients[3], a prospective study of about 4 years gathered only 31 patients[17], and Kiuru, *et al*[16] found stress fractures in only 32 of 50 consecutive subjects with clinical signs of stress injury to bone, involving a bias of recruitment. Our study included only ambulatory patients over a period of 1 year, and was more representative of clinical daily practice. The medial and distal part of the second and third metatarsals were the most affected, as described[1]. This could be explained by medial, lateral, and soleus muscle fatigue generating an alteration of the rollover process with increased forefoot loading[23]. There were 7 patients who had false-positive results. This may reflect a lack of specificity in our US diagnosis criteria, or a lack of sensitivity in dedicated MRI corresponding to our dedicated MRI diagnosis criteria. For example, in the case of metatarsal head localization, it may be difficult to make an US diagnosis due to reactional synovitis masking US-specific signs, especially the cortical thickening. In addition, in the case of metatarsal proximal localization, an US misdiagnosis might be due to an anisotropic area and a frequent localization of vessels. However, no false-positive was diagnosed on the presence of a cortical thickening, suggesting that this US sign is most specific.

Both false-negative fractures were related to metatarsal diaphysis localization. This localization is usually well explored in US scans. We suppose that it is explained by the superiority of the MRI, which allows for a 3-D visualization, whereas US reveals only the dorsal aspect of the foot. Perhaps a complementary exploration of the plantar aspect of the foot would have allowed us to rectify the diagnosis.

Finally, sonography requires substantial experience on the part of the sonographer, and at least 70 examinations should be required to develop adequate competence, as demonstrated for synovitis[24]. Thanks to these data, we constructed a new imaging algorithm restricted to suspected metatarsal bone stress fracture, including US, as proposed by Anderson and Greenspan[25] some years ago (Figure 6). Plain radiography should be the first imaging study performed when a stress fracture is suspected. In the case of normal examination, sonography should be the second imaging study performed, detecting stress fractures in 80% of cases. In the case of normal US, and depending on the degree of clinical suspicion, MRI can be performed. In cases of diagnostic doubt, bone scintigraphy should be reserved to provide optimal delineation of a fracture when the fracture line is not depicted by MRI. In cases of normal MRI, bone scintigraphy might be advised.

In cases where radiographs are usually normal, US is indicated in the early diagnosis of metatarsal bone stress fractures for daily practice, as it is a low cost, noninvasive, rapid, and easy technique with good sensitivity and specificity. On consideration of these data, we propose a new imaging algorithm including US. We hope that further studies will confirm our results in order to consider US as the gold standard in daily practice.

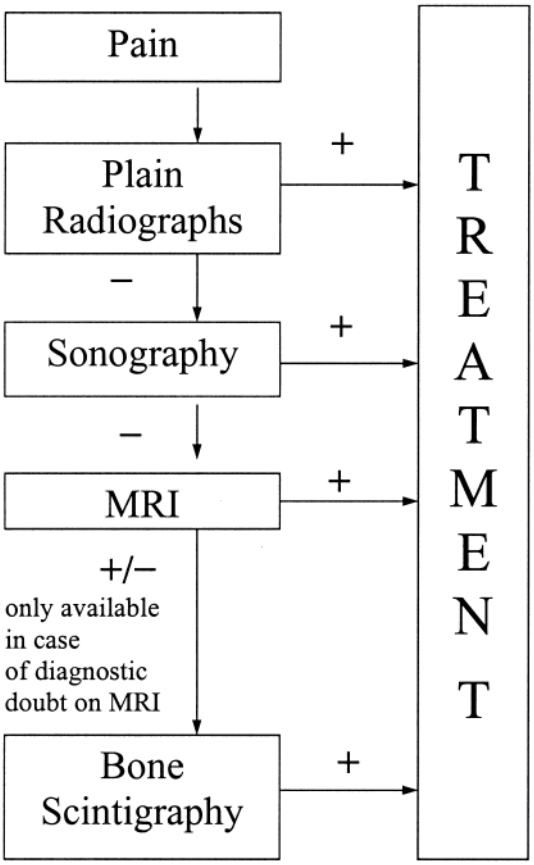

Figure 6. The imaging algorithm for suspected metatarsal bone stress fracture.

ACKNOWLEDGMENT

The authors thank all patients. As well, we thank Helen and Olivier Banal, who contributed to the English manuscript.

REFERENCES

1. Peris P. Stress fractures. Best Pract Res Clin Rheumatol 2003;17:1043-61.
2. Matheson GO, Clement DB, McKenzie DC, Taunton JE, Lloyd-Smith DR, Macintyre JG. Stress fractures in athletes. A study of 320 cases. Am J Sports Med 1987;15:46-58.
3. Peris P. Stress fractures in rheumatological practice: clinical significance and localizations. Rheumatol Int 2002;22:77-9.
4. Greaney RB, Gerber FH, Laughlin RL, et al. Distribution and natural history of stress fractures in U.S. Marine recruits. Radiology 1983;146:339-46.
5. Matheson GO, Clement DB, McKenzie DC, Taunton JE, Lloyd-Smith DR, Macintyre JG. Scintigraphic uptake of 99mTC at non-painful sites in athletes with stress fractures. The concept of bone strain. Sports Med 1987;4:65-75.
6. Nielsen MB, Hansen K, Holmer P, Dyrbye M. Tibial periosteal reactions in soldiers. A scintigraphic study of 29 cases of lower leg pain. Acta Orthop Scand 1991;62:531-4.
7. Prather JL, Nusynowitz ML, Snowdy HA, Hughes AD, McCartney WH, Bagg RJ. Scintigraphic findings in stress fractures. J Bone Joint Surg 1977;59:869-74.
8. Rupani HD, Holder LE, Espinola DA, Engin SI. Three-phase radionuclide bone imaging in sports medicine. Radiology 1985;156:187-96.
9. Sofka CM. Imaging of stress fractures. Clin Sports Med 2006;25:53-62.
10. Banal F, Etchepare F, Rouhier B, et al. Ultrasound ability in early diagnosis of stress fracture of metatarsal bone. Ann Rheum Dis 2006;65:977-8.
11. Keene JS, Lash EG. Negative bone scan in a femoral neck stress fracture. A case report. Am J Sports Med 1992;20:234-6.
12. Milgrom C, Chisin R, Giladi M, et al. Negative bone scans in impending tibial stress fractures. A report of three cases. Am J Sports Med 1984;12:488-91.
13. Sterling JC, Webb RF, Meyers MC, Calvo RD. False-negative bone scan in a female runner. Med Sci Sports Exerc 1993;25:179-85.
14. Bal BS, Sandow T. Bilateral femoral neck fractures with negative bone scans. Orthopedics 1996;19:974-6.
15. Wen DY, Propeck T, Singh A. Femoral neck stress injury with negative bone scan. J Am Board Fam Pract 2003;16:170-4.
16. Kiuru MJ, Pihlajamaki HK, Hietanen HJ, Ahovuo JA. MR imaging, bone scintigraphy, and radiography in bone stress injuries of the pelvis and the lower extremity. Acta Radiol 2002;43:207-12.
17. Ishibashi Y, Okamura Y, Otsuka H, Nishizawa K, Sasaki T, Toh S. Comparison of scintigraphy and magnetic resonance imaging for stress injuries of bone. Clin J Sports Med 2002;12:79-84.
18. Schirmer C, Scheel AK, Althoff CE, et al. Diagnostic quality and scoring of synovitis, tenosynovitis and erosions in low-field MRI of patients with rheumatoid arthritis: a comparison with conventional MRI. Ann Rheum Dis 2007;66:522-9.
19. Ejbjerg BJ, Narvestad E, Jacobsen S, Thomsen HS, Østergaard M. Optimised, low cost, low field dedicated extremity MRI is highly specific and sensitive for synovitis and bone erosions in rheumatoid arthritis wrist and finger joints: Comparison with conventional high field MRI and radiography. Ann Rheum Dis 2005;64:1280-7.
20. Taouli B, Zaim S, Peterfy CG, et al. Rheumatoid arthritis of the hand and wrist: Comparison of three imaging techniques. AJR Am J Roentgenol 2004;182:937-43.
21. Savnik A, Malmskov H, Thomsen HS, et al. MRI of the arthritic small joints: Comparison of extremity MRI (0.2 T) vs high-field MRI (1.5 T). Eur Radiol 2001;11:1030-8.
22. Hottya GA, Peterfy CG, Uffmann M, et al. Dedicated extremity MR imaging of the foot and ankle. Eur Radiol 2000;10:467-75.
23. Weist R, Eils E, Rosenbaum D. The influence of muscle fatigue on electromyogram and plantar pressure patterns as an explanation for the incidence of metatarsal stress fractures. Am J Sports Med 2004;32:1893-8.
24. D'Agostino MA, Maillefert JF, Said-Nahal R, Breban M, Ravaud P, Dougados M. Detection of small joint synovitis by ultrasonography: the learning curve of rheumatologists. Ann Rheum Dis 2004;63:1284-7.
25. Anderson MW, Greenspan A. Stress fractures. Radiology 1996;199:1-12.