

Correspondence



INSTRUCTIONS FOR LETTERS TO THE EDITOR

Editorial comment in the form of a Letter to the Editor is invited. The length of a letter should not exceed 800 words, with a maximum of 10 references and no more than 2 figures or tables; and no subdivision for an abstract, methods, or results. Letters should have no more than 4 authors. Financial associations or other possible conflicts of interest should be disclosed.

Letters should be submitted via our online submission system, available at the Manuscript Central website: <http://mc.manuscriptcentral.com/jrheum> For additional information, contact the Managing Editor, The Journal of Rheumatology, E-mail: jrheum@jrheum.com

Both Etanercept and Infliximab Can Elevate Tumor Necrosis Factor (TNF)- α and Be the Cause of Treatment Related New Onset Disease: the Need to Measure Circulating TNF- α

To the Editor:

We read with interest the documentation by Song, *et al* of new onset Crohn's disease (CD) in a patient after treatment of ankylosing spondylitis with etanercept¹. Their report is the latest addition to a long list of tumor necrosis factor (TNF)- α mediated disease, generated or worsened by anti-TNF- α treatment with etanercept or infliximab. We do not contest the several dozen carefully thought out and well documented risk-benefit assessments published over the last 10 years that show clear benefit from both agents for their respective indications. We simply add here 2 reminders: (1) Both etanercept and infliximab have numerous reports of increased circulating, soluble TNF (sTNF) after their use; and (2) We advocate continuous monitoring of sTNF levels using commercial testing laboratories during treatment with any drug or agent used with intent to influence TNF activity.

Regarding (1): Since a mechanistic explanation² for previously noted etanercept-mediated increased sTNF in myeloma patients was published in 2005, and since cases of increased sTNF after etanercept in general was reviewed in *The Journal* last year³ (although this review was partially contested by others, see "authors' reply" after³), several further reports of increased sTNF after both etanercept and infliximab have appeared. Of particular interest is the recent report of increased outer cell membrane (transmembrane) TNF, tmTNF, in bone of patients receiving infliximab for rheumatoid arthritis⁴ associated with salutary new bone formation. Dramatically increased circulating TNF was seen in renal cell carcinoma patients treated with infliximab⁵. This means that both increased sTNF and tmTNF can be seen after treatment with either TNF binding proteins, etanercept or infliximab. We therefore cannot say whether a given new onset disease after either etanercept or infliximab, of which there are over a dozen reports now, is due to an increase or decrease in sTNF, or in tmTNF, or in both, or in neither, or simply a shift in relative weighting between the 2 forms of TNF mediated signaling.

Regarding (2): Since new onset TNF-mediated disease is not common, but neither is it rare in etanercept or infliximab treated patients, we advo-

cate at least monitoring sTNF during treatment with either of these^{6,7}. Note that sTNF as determined currently by ELISA based techniques detects both biologically active as well as potentially physiologically inactive TNF (s or tm) bound to etanercept or infliximab⁸. The stoichiometry of TNF to either of these is clear⁸ but the biologic, signaling activity consequences of that binding are not. sTNF and tmTNF have differing signaling propensities at their 2 cognate receptors, TNFR1 and TNFR2^{2,3,6}.

At a minimum, total sTNF should be measured whenever biologic agents like etanercept or infliximab are used.

RICHARD E. KAST, MD, Department of Psychiatry, University of Vermont, 2 Church Street, Burlington, VT 05401; E-mail: hast887@hotmail.com;
ERIC L. ALTSCHULER, MD, Brain and Perception Laboratory, University of California at San Diego, La Jolla, CA 92093-0109, USA.

REFERENCES

1. Song IH, Appel H, Haibel H, et al. New onset of Crohn's disease during treatment of active ankylosing spondylitis with etanercept. *J Rheumatol* 2008;35:532-6. Epub 2008 Jan 15.
2. Kast RE. Evidence of a mechanism by which etanercept increased TNF-alpha in multiple myeloma: new insights into the biology of TNF-alpha giving new treatment opportunities—the role of bupropion. *Leuk Res* 2005;29:1459-63.
3. Bhatia A, Kast RE. Tumor necrosis factor (TNF) can paradoxically increase on etanercept treatment, occasionally contributing to TNF-mediated disease. *J Rheumatol* 2007;34:447-9; author reply 449-50.
4. Kanbe K, Inoue K, Inoue Y, Suzuki Y. Histological changes in bone marrow after treatment of infliximab for rheumatoid arthritis. *Clin Rheumatol* 2008;27:497-501. Epub 2007 Nov 27.
5. Harrison ML, Obermueller E, Maisey NR, et al. Tumor necrosis factor alpha as a new target for renal cell carcinoma: two sequential phase II trials of infliximab at standard and high dose. *J Clin Oncol* 2007;25:4542-9.
6. Kast RE. Aspirin, TNF-alpha, NFkB, and survival in multiple myeloma: the importance of measuring TNF-alpha. *Inflammopharmacology* 2006;14:256-9.
7. Kast RE. Aspirin use in myeloma: a note of caution regarding potential tumour necrosis factor-alpha elevation. *Br J Haematol* 2006;133:216.
8. Kim MS, Lee SH, Song MY, Yoo TH, Lee BK, Kim YS. Comparative analyses of complex formation and binding sites between human tumor necrosis factor-alpha and its three antagonists elucidate their different neutralizing mechanisms. *J Mol Biol* 2007;374:1374-88.

Drs. Rudwaleit and Song reply

To the Editor:

The interesting comments by Kast and Altschuler further illustrate the complexity of the mechanisms underlying immune mediated injuries that have been observed in patients treated with anti-TNF agents and can affect a variety of organs¹. As discussed in our case series² of 4 patients (3 patients described in detail in the manuscript and a fourth patient added in proof) with ankylosing spondylitis who developed new onset of Crohn's disease during etanercept therapy, we are currently far away from understanding the molecular pathways behind these unusual manifestations. Whether or not an increase of soluble TNF played a causative role in our cases cannot be decided, since soluble TNF was not measured in our case series. The serial measurement of CD4 and CD8 T cell production of the cytokines interferon- γ and TNF- α in one of our patients, however, did not provide conclusive information towards the underlying mechanism.

We agree with Kast and Altschuler that an increase of soluble serum TNF during anti-TNF therapy that may precipitate immune mediated injuries later on is an interesting hypothesis. However, this hypothesis is unproven at this stage since to our knowledge no systematic investigations

on this issue are available in patients with rheumatic diseases such as ankylosing spondylitis or rheumatoid arthritis. Large prospective registries of patients treated with anti-TNF agents, for example, would be needed to answer this research question.

Given the available information, we would not advocate routine measurement of soluble TNF in patients treated with anti-TNF agents in daily practice for the following reasons:

(1) Systematic studies demonstrating a temporal relationship between soluble TNF levels and the occurrence of immune mediated injuries are lacking in rheumatic diseases. (2) We have serious concerns about measuring soluble TNF- α serially (!) in too many patients too often (at what time intervals?) in order to detect one patient with an immune mediated injury (high number needed to test). This issue calls into question the cost effectiveness of such screening; although immune mediated injuries have been reported in a number of case reports by now, they still represent rather rare events among the 1 million patients treated with anti-TNF agents worldwide. The incidence of lupus-like syndromes and (cutaneous) vasculitis has been estimated to be 0.1–0.39% and 3.9%, respectively^{1,3,4}, whereas there are no estimates on the incidence of interstitial lung disease and inflammatory bowel disease, which appear to be even more rare^{1,2,5}. (3) Uncertainties about the consequences of detecting elevated soluble TNF- α . Should treatment with anti-TNF be stopped although the patient tolerates the drug very well and is doing fine regarding the rheumatic disease? For many patients, anti-TNF agents are very important drugs — sometimes the only class of drugs — to control the rheumatic disease. What would be a clinically relevant elevation of soluble TNF- α in serum? Two-fold above normal or 10-fold? Is there a need to have elevated soluble TNF on more than one occasion before taking steps?

Measurement of soluble TNF- α in patients taking anti-TNF agents might be an interesting research question. Currently, the many unanswered questions preclude recommendations on routine measurement of soluble TNF in daily practice.

MARTIN RUDWALEIT, MD; IN-HO SONG, MD. Department of Rheumatology, Charité Medical University, Hindenburgdamm 30, Berlin 12200, Germany.

REFERENCES

1. Ramos-Casals M, Brito-Zerón P, Muñoz S, et al. Autoimmune diseases induced by TNF-targeted therapies: analysis of 233 cases. *Medicine* Baltimore 2007;86:242-51.
2. Song IH, Appel H, Haibel H, et al. New onset of Crohn's disease during treatment of active ankylosing spondylitis with etanercept. *J Rheumatol* 2008;35:532-6. Epub 2008 Jan 15.
3. Schiff MH, Burmester GR, Kent JD, et al. Safety analyses of adalimumab (HUMIRA) in global clinical trials and US postmarketing surveillance of patients with rheumatoid arthritis. *Ann Rheum Dis* 2006;65:889-94.
4. Shakoar N, Michalska M, Harris CA, Block JA. Drug-induced systemic lupus erythematosus associated with etanercept therapy. *Lancet* 2002;359:579-80.
5. Braun J, Baraliakos X, Listing J, et al. Differences in the incidence of flares or new onset of inflammatory bowel diseases in patients with ankylosing spondylitis exposed to therapy with anti-tumor necrosis factor alpha agents. *Arthritis Rheum* 2007;57:639-47.



Hodgkin's Lymphoma and Tumor Necrosis Factor Inhibitors in Juvenile Idiopathic Arthritis

To the Editor:

Tumor necrosis factor (TNF)-blocking agents are widely used currently in treatment of juvenile idiopathic arthritis (JIA)¹, but there may be as-yet unknown longterm toxicities. There is controversy regarding the increased risk of lymphoma with anti-TNF agents in adults with rheumatoid arthritis (RA), but according to a recent metaanalysis based on 9 randomized controlled clinical trials, there were higher rates of malignancies in patients treated with TNF inhibitors (0.8%) compared to placebo or active controls (0.2%)². Additionally, there have been 8 cases reported of hepatosplenic T cell lymphoma occurring in patients with pediatric Crohn's disease treated with infliximab³, of only 100 patients reported with this lymphoma worldwide.

Although there have been a few case reports of children with JIA developing Hodgkin's lymphoma and other malignancies while taking methotrexate (MTX)⁴⁻⁸, malignancies have not been reported in association with anti-TNF use to date. To our knowledge, our case reports are the first describing Hodgkin's lymphoma associated with the use of a TNF antagonist for JIA.

Case 1. An 11-month-old boy of Portuguese descent was diagnosed with antinuclear antibody-positive, rheumatoid factor (RF)-negative extended oligoarthritis and uveitis. Although the arthritis responded well to MTX, the uveitis was inadequately controlled with topical steroids (used for 5 yrs), MTX (4 yrs), cyclosporine (6 mo), mycophenolate mofetil (7 mo), and etanercept (1 yr). He was then treated with infliximab infusions at doses ranging from 5 to 10 mg/kg/dose (average dosing interval was 6 wks; the uveitis flared when the interval was increased to 8 wks) over a 3.5-year period, with complete control of his uveitis and arthritis. At age 9 years (3.5 yrs after initiation of infliximab), he developed abdominal pain, lost 20 pounds, and erythrocyte sedimentation rate became elevated. In September 2006 an enlarged right axillary node was discovered. He had no fevers or night sweats, but had intermittent chest pain and cough. An excisional biopsy revealed classical Hodgkin's lymphoma, nodular sclerosis subtype, stage IV B. He was prescribed high intensity chemotherapy followed by radiation therapy, which he has completed with an excellent radiographic response. During the last cycle of chemotherapy, his uveitis flared but was controlled with topical therapy, and it has flared on and off since that time, when topical treatment was discontinued. Currently he is 8 months post-chemotherapy and 5 months post-radiation therapy, and the arthritis has now begun to flare along with the uveitis.

Case 2. An 11-year-old Caucasian girl presented with RF-positive polyarthritis of the shoulders, wrists, knees, and ankles and multiple metacarpophalangeal (MCP) and proximal interphalangeal (PIP) joints. She was treated initially with weekly oral MTX as well as a nonsteroidal antiinflammatory agent, but she had only a partial response. Etanercept was added 6 months after diagnosis at a dose of 0.4 mg/kg by subcutaneous injections twice weekly. She did well taking the combination of MTX and etanercept and went into clinical remission within 4 months after initiation of etanercept. At age 15 years 11 months, her pediatrician noted a 3 cm left anterior cervical node. At that time, she had been taking MTX for 4.25 years and etanercept almost 4 years. She had no associated fevers, organomegaly, or rashes. Because of the persistence of the node, an exci-

sional biopsy was performed that revealed stage II classical Hodgkin's lymphoma. She was examined 4 months after finishing chemotherapy and was found to have no active arthritis. However, she returned to clinic 8 months post-chemotherapy and was found to have active polyarthritis in the wrist and several MCP, PIP, and metatarsophalangeal joints.

Anti-TNF agents have been used in the treatment of adult RA for more than 10 years. There has been concern about possible increased risk of lymphoproliferative diseases with all 3 anti-TNF agents. Despite data from studies of adult RA patients indicating a possible association between anti-TNF use and lymphomas, a cause and effect relationship remains controversial. Disease duration, disease severity, chronic inflammation, and previous immunosuppressive therapy have all been suggested as possible confounding factors. Etanercept has been studied and approved for use in JIA, and one study suggests its long-term safety⁹. Etanercept and other anti-TNF agents are currently commonly used to treat JIA that is refractory to MTX.

These are the first reports of the occurrence of Hodgkin's lymphoma in patients with JIA who were treated with anti-TNF agents. Although the development of Hodgkin's lymphoma in these 2 patients may be unrelated to medication use, these cases and the cases of hepatosplenic T cell lymphoma reported in pediatric Crohn's disease raise the possibility that the use of anti-TNF agents could increase the risk of lymphoma in pediatric patients. Since the long-term risks in children are not fully known, it is important to establish a mechanism of reporting adverse events and careful long-term surveillance of all pediatric patients treated with these and other biologic agents.

CAGRI YILDIRIM-TORUNER, MD, Department of Pediatrics, UMDNJ—New Jersey Medical School; YUKIKO KIMURA, MD, Chief, Pediatric Rheumatology, Joseph M. Sanzari Children's Hospital, Hackensack University Medical Center, Hackensack, New Jersey; C. EGLA RABINOVICH, MD, Co-Chief, Pediatric Rheumatology, Duke University Medical Center, Durham, North Carolina, USA. Address reprint requests to Dr. Y. Kimura, Joseph M. Sanzari Children's Hospital, Hackensack University Medical Center, 30 Prospect Avenue, Hackensack, NJ 07601; e-mail: YKimura@hmed.com

Note added in proof

Case 3. After this case report was submitted, a third case of lymphoma occurred in another of our patients: a 10-year-old Caucasian girl who presented at 19 months of age with systemic JIA. She initially presented with typical systemic rash, daily fevers, and polyarthritis, and was ANA- and RF-negative. Her systemic features responded to ibuprofen, corticosteroids, and MTX, but her arthritis was resistant and progressive. She was treated with etanercept starting at age 2 years for 1 year, with only a partial response. She was subsequently treated with infliximab (3 mg/kg) at age 3, but it was discontinued after she developed an anaphylactic reaction after 3 doses. Multiple other therapeutic interventions, including leflunomide (for 18 mo), anakinra (1 mo), intravenous cyclophosphamide therapy (5 monthly doses), thalidomide (7 mo), and rituximab (2 doses), proved only partially effective. She continued to have progressive joint destruction and required a wheelchair except for short distances. She was clinically stable receiving MTX (taken for 3.7 yrs at 0.8 mg/kg), adalimumab (2.4 yrs at 1 mg/kg weekly), low-dose daily prednisone, naproxen, and methadone, when an enlarged cervical lymph node was discovered. Through biopsy and staging, she was found to have Hodgkin's lymphoma stage IIA. She began receiving standard ABVD therapy and is currently in her third cycle of chemotherapy.

This third case is similar to Case 1, in that this patient was also receiving multiple immunosuppressive therapies for over 7 years. A fourth patient with JIA who developed lymphoma is described in a separate letter in this issue of *The Journal*¹⁰. These additional cases emphasize the importance of having a large registry of all patients with JIA, in order to establish the actual incidence of malignancies in JIA, and to understand the impact of biologic therapies on this incidence.

REFERENCES

1. Hashkes PJ, Laxer RM. Medical treatment of juvenile idiopathic arthritis. *JAMA* 2005;294:1671-84.
2. Bongartz T, Sutton AJ, Sweeting MJ, Buchan I, Matteson EL, Montori V. Anti-TNF antibody therapy in rheumatoid arthritis and the risk of serious infections and malignancies: systematic review and meta-analysis of rare harmful effects in randomized controlled trials. *JAMA* 2006;295:2275-85.
3. Mackey AC, Green L, Liang LC, Dinndorf P, Avigan M. Hepatosplenic T cell lymphoma associated with infliximab use in young patients treated for inflammatory bowel disease. *J Pediatr Gastroenterol Nutr* 2007;44:265-7.
4. Londino AV Jr, Blatt J, Knisely AS. Hodgkin's disease in a patient with juvenile rheumatoid arthritis taking weekly low dose methotrexate. *J Rheumatol* 1998;25:1245-6.
5. Padeh S, Sharon N, Schiby G, Rechavi G, Passwell JH. Hodgkin's lymphoma in systemic onset juvenile rheumatoid arthritis after treatment with low dose methotrexate. *J Rheumatol* 1997; 24:2035-7.
6. Takeyama J, Sato A, Nakano K, Abukawa D, Ichinohazama R, Imaizumi M. Epstein-Barr virus associated Hodgkin lymphoma in a 9-year-old girl receiving long-term methotrexate therapy for juvenile idiopathic arthritis. *J Pediatr Hematol Oncol* 2006; 28:622-4.
7. Cleary AG, McDowell H, Sills JA. Polyarticular juvenile idiopathic arthritis treated with methotrexate complicated by the development of non-Hodgkin's lymphoma. *Arch Dis Child* 2002;86:47-9.
8. Yildirim Y. Primary ovarian large B-cell lymphoma in a patient with juvenile rheumatoid arthritis treated with low dose methotrexate. *Gynecol Oncol* 2005;97:249-52.
9. Lovell DJ, Reiff A, Jones OY, et al. Long-term safety and efficacy of etanercept in children with polyarticular-course juvenile rheumatoid arthritis. *Arthritis Rheum* 2006;54:1987-94.
10. Imundo L. Hodgkin's lymphoma associated with anti-tumor necrosis factor use in juvenile idiopathic arthritis: Supplemental case report [letter]. *J Rheumatol* 2008;35:1681-2.

Hodgkin's Lymphoma Associated with Anti-Tumor Necrosis Factor Use in Juvenile Idiopathic Arthritis: Supplemental Case Report

To the Editor:

We describe an additional patient with juvenile idiopathic arthritis (JIA) who developed a malignancy to augment the case series in the current issue of *The Journal*¹. Our patient was diagnosed with polyarticular JIA at the age of 14 years (rheumatoid factor, antinuclear antibodies, and HLA-B27 negative). She was treated with nonsteroidal antiinflammatory drugs and methotrexate (MTX), eventually at a dose of 25 mg/week, given subcutaneously. Her arthritis improved, but radiographs showed new erosions at the metacarpophalangeal joints; she had difficulty tolerating MTX because of nausea, and at 17 years 3 months of age, etanercept was started at 25 mg BIW. The patient's arthritis improved. MTX was continued at doses of between 7.5 to 15 mg/kg/week in addition to the etanercept, which was changed to 50 mg per week. At 18 years, her arthritis became active again, and it was discovered that although she was compliant with etanercept, she was only partially compliant with the MTX therapy. She also admitted to using multiple homeopathic and other nontraditional therapies. In 2007, at the age of 21 years 10 months (after 3.5 yrs of etanercept and 6 yrs of intermittent MTX therapy), the patient developed a large firm supraclavicular lymph node. After an appropriate evaluation she was diagnosed with Stage IIA Hodgkin's lymphoma. During the course of her evaluation, an asymptomatic ovarian cyst was

diagnosed as a papillary ovarian tumor of low malignant potential associated with ovarian stroma. We have been unable to find any association with this tumor and arthritis or Hodgkin's lymphoma. At this time, 4 months after completing chemotherapy, our patient's arthritis and malignancy are in remission.

This 21-year-old patient with 7 years of polyarticular JIA, 6 years of MTX therapy, and 3.5 years of etanercept therapy was diagnosed with stage II Hodgkins lymphoma and a second pre-malignant ovarian lesion. As stated in the case series, because we do not have reliable epidemiological data about arthritis in children, it is not possible to discern whether these cases of lymphoma represent a significant increase in incidence. In addition, we cannot determine the roles that arthritis therapy and poorly controlled inflammation play in triggering malignancy in these children. The second pre-malignant ovarian lesion was unexpected and is of unclear significance. We look forward to further epidemiologic studies to clarify the prevalence of malignancy in JIA and to investigate all possible etiologies.

LISA IMUNDO, MD, Director of Pediatric Rheumatology, Columbia University Medical Center, Pediatrics, 3959 Broadway, Suite 106N, New York, New York 10032, USA. E-mail: lfi1@columbia.edu

REFERENCE

1. Yildirim-Toruner C, Kimura Y, Rabinovich CE. Hodgkin's lymphoma and tumor necrosis factor inhibitors in juvenile idiopathic arthritis. *J Rheumatol* 2008;35:1680-1.

Imatinib Treatment of Seropositive Arthritis in a Young Woman with Chronic Myeloid Leukemia

To the Editor:

A 31-year-old woman was referred to our rheumatology department in February 2002 for tender ulnar styloids and decreased range of motion in her wrists. During the previous 3 years she had intermittent swelling of her second right proximal interphalangeal joint (PIP) and metacarpophalangeal (MCP) joints, with early morning stiffness treated with nonsteroidal anti-inflammatory drugs. Radiographs of hands and wrists were normal. Her rheumatoid factor (RF) was positive at 70 IU/ml (normal 0-14 IU/ml), erythrocyte sedimentation rate was 10 mm/h, antinuclear antibodies and extractable nuclear antigen were negative and serum complement levels were normal. The patient received depomedrone 120 mg/IM with little benefit.

In May 2002 early morning stiffness (EMS) became significant and clinical synovitis was noted in both 3rd PIP and wrists. The patient began taking hydroxychloroquine 200 mg/bid and sulfasalazine 1 g bid, the latter discontinued 2 months later for a rash. By October 2002 she improved 70%, but in April 2003 her symptoms flared and hand radiographs showed reduction of joint spaces, with minor erosions of the carpus and radiocarpal joints bilaterally. Her Disease Activity Score (DAS)28 was 2.87. She began taking oral methotrexate (MTX) 7.5 weekly, increased to 12.5 mg/week. There was a sustained improvement until July 2005 when the patient developed bilateral swelling of the 3rd MCP with a DAS28 of 4.1: increasing MTX to 17.5 mg/week led to clinical improvement.

In October 2005, neutrophilia with myelocytes, basophilia, and thrombocytosis were detected on a blood film. A bone marrow aspirate and cytogenetic studies confirmed the diagnosis of chronic myeloid leukemia (CML) with the typical Philadelphia chromosome and BCR-ABL rearrangement present in 79% of cells. MTX was stopped and imatinib started at 200 mg/day orally for 4 days, then increased to 400 mg/day. In January 2006 imatinib induced a hematological response, but her arthritis had remained active with a DAS28 of 3.2 since cessation of MTX. In May 2006 imatinib achieved a cytogenetic response (BCR-ABL/ABL ratio by

quantitative polymerase chain reaction 1.183) as well as an improvement in her arthritis that completely remitted in October 2006. At 17 months' followup, in March 2008, her arthritis is in remission with a DAS28 of 0.49 and no evidence of progressive disease on radiographs. Her RF had gone down to 27 IU/ml, but anti-cyclic citrullinated peptide was raised at 340 U/ml (NR < 7 U/ml). Her latest BCR-ABL/ABL ratio was 0.062.

The annual incidence of rheumatoid arthritis (RA) in the population of Northern Europe¹ ranges between 0.02-0.05% and that of CML in UK is around 1.09/100,000². This makes the coexistence of the 2 conditions rare. Apart from our patient, an elderly man developed CML 5 years after the diagnosis of RA; he improved after treatment with imatinib alongside inflammatory markers³. In recognition of its immunomodulatory potential, imatinib was specifically given to 3 patients with refractory RA who responded to treatment⁴.

Imatinib mesylate is an inhibitor of several tyrosine kinases that has dramatically changed the prognosis of patients with CML⁵. It is essentially a "designer drug" that specifically blocks the abnormal tyrosine kinase receptor created by the BCR-ABL rearrangement, pathognomonic of CML. It is given orally and is well tolerated, the main side effect being fluid retention. As well as its effect on CML, imatinib has shown efficacy in preventing and treating the arthritis induced by type II collagen in mice⁶, probably by modulating cytokine production by T cells⁷ and by inhibiting signal transduction pathways in T and B lymphocytes⁸, mast cells, and fibroblasts involved in the pathogenesis of joint destruction in RA⁹. These effects may account for the beneficial clinical effect of imatinib in the few patients with RA reported so far. Imatinib therefore may represent an additional therapeutic option for patients with RA.

PAUL R.J. AMES, MD, MSc; WIN WIN AYE, MRCP; CYNTHIA BEATTY, FRCP, FRCPath, Department of Haematology; DAVID O'REILLY, FRCP, Department of Rheumatology, West Suffolk Hospital, Bury St Edmunds, IP33 2QZ, UK. Address reprint requests to Dr. Ames. E-mail: paxmes@aol.com

REFERENCES

1. Alamanos Y, Drosos AA. Epidemiology of adult rheumatoid arthritis. *Autoimmun Rev* 2005;4:130-6.
2. Phekoo KJ, Richards MA, Møller H, Schey SA; South Thames Haematology Specialist Committee. The incidence and outcome of myeloid malignancies in 2,112 adult patients in southeast England. *Haematologica* 2006;91:1400-4.
3. Miyachi K, Ihara A, Hankins RW, Murai R, Maehiro S, Miyashita H. Efficacy of imatinib mesylate (STI571) treatment for a patient with rheumatoid arthritis developing chronic myelogenous leukemia. *Clin Rheumatol* 2003;22:329-32.
4. Eklund KK, Joensuu H. Treatment of rheumatoid arthritis with imatinib mesylate: clinical improvement in three refractory cases. *Ann Med* 2003;35:362-7.
5. Druker BJ, Guilhot F, O'Brien SG, et al. Five-year follow-up of patients receiving imatinib for chronic myeloid leukemia. *N Engl J Med* 2006;355:2408-17.
6. Koyama K, Hatsushika K, Ando T, et al. Imatinib mesylate both prevents and treats the arthritis induced by type II collagen antibody in mice. *Mod Rheumatol* 2007;17:306-10.
7. Leder C, Ortler S, Seggewiss R, Einsele H, Wiendl H. Modulation of T-effector function by imatinib at the level of cytokine secretion. *Exp Hematol* 2007;35:1266-71.
8. Paniagua RT, Sharpe O, Ho PP, et al. Selective tyrosine kinase inhibition by imatinib mesylate for the treatment of autoimmune arthritis. *J Clin Invest* 2006;116:2633-42.
9. Kameda H, Ishigami H, Suzuki M, Abe T, Takeuchi T. Imatinib mesylate inhibits proliferation of rheumatoid synovial fibroblast-like cells and phosphorylation of Gab adapter proteins activated by platelet-derived growth factor. *Clin Exp Immunol* 2006; 144:335-41.

Severe Nontuberculous Mycobacterial Infection in 2 Patients Receiving Rituximab for Refractory Myositis

To the Editor:

We describe 2 patients with inflammatory myopathies who developed severe nontuberculous mycobacterium (NTM) infections while undergoing treatment with rituximab.

Case 1. In 1998, a 55-year-old man presented with proximal weakness, heliotrope rash, nailbed vasculitis, and a diffuse erythematous maculopapular rash covering the back, buttocks, and legs. A skin biopsy was consistent with dermatomyositis. A comprehensive malignancy evaluation was negative. He initially improved with prednisone 1 mg/kg before later adding methotrexate (MTX) as a steroid-sparing agent. In 2003, relapses of weakness, weight loss, and refractory skin disease required the addition of hydroxychloroquine, fluctuating doses of prednisone, and MTX 20-25 mg per week. Subsequent intravenous (IV) immunoglobulin therapy resulted in a good clinical response but was discontinued after 9 months when he experienced 2 transient ischemic attacks. Four months later, the diffuse pruritic maculopapular rash returned and MTX was replaced with mycophenolate mofetil (MMF) with minimal benefit. Cancer screening, including chest computerized tomography (CT), was repeated in 2005 and was again unremarkable.

In April of 2006, while taking MMF 1000 mg twice daily and prednisone 7.5 mg daily, he presented with increasing fatigue, myalgia, lower extremity edema, persistent diffuse pruritic rash, and dyspnea. A plain radiograph (Figure 1) and CT of the chest revealed new moderate-sized bilateral pleural effusions without evidence of involvement of the lung parenchyma. A transthoracic echocardiogram was unremarkable. Pleural fluid studies were consistent with an exudative effusion [lactate dehydrogenase 1726 U/l (serum 246), protein 4.47 g/dl (serum 6.7), white blood cells 2,000 per mm³ with 26% lymphocytes, 69% macrophages, and 5% monocytes, and red blood cells 6050 per mm³]. Bacterial cultures, acid fast bacilli (AFB) staining, and cytology studies of the pleural fluid as well as fungal and AFB blood cultures were negative. Two weekly infusions of rituximab at a dose of 375 mg/m² were given. Further rituximab doses were suspended, however, after pleural fluid cultures grew *Mycobacterium avium* several weeks later. After consultation with infectious disease specialists from multiple institutions, the decision was made to follow the effusions closely without *M. avium* directed treatment.

The patient's skin disease responded well to therapy, and he received a

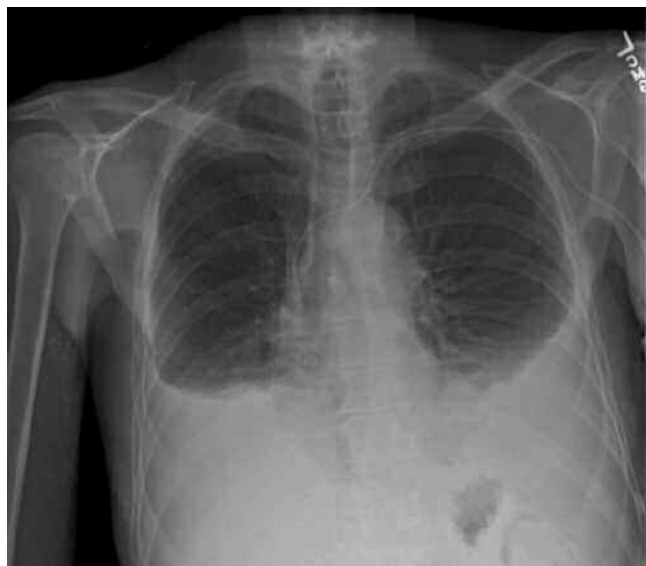

Figure 1. PA view of the chest showing bilateral pleural effusions with adjacent atelectasis.

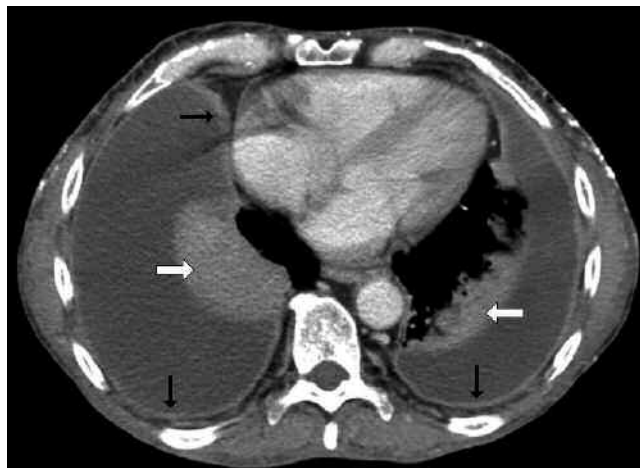

Figure 2. Contrast enhanced chest CT showing bilateral pleural effusions with extensive pleural enhancement (black arrows) and passive atelectasis (white block arrows).

repeat course of 2 rituximab infusions in June 2006. Four months later, however, while taking 20 mg of prednisone daily and no other immunosuppressive agents, he returned with weight loss of greater than 25% of body weight, increasing diffuse rash, and dyspnea, but no cough. Repeat CT scans of the chest, abdomen, and pelvis identified significant pleural effusions with pleural enhancement (Figure 2) and bibasilar compression atelectasis. Consistent with prior chest CT scans, there was no evidence of lung parenchymal abnormalities or pericardial effusion. Pleural fluid was obtained and *M. avium* was isolated on culture, while AFB blood cultures were negative. No susceptibility testing was performed. After *M. avium* was again isolated from pleural fluid as well as the development of recurrent pleural effusions and cachexia, the patient began therapy with ethambutol 1200 mg daily, azithromycin 250 mg daily, and rifampin 600 mg daily in April 2007. In the context of continued weight loss, moxifloxacin 400 mg daily was added in June, and amikacin 20 mg/kg IV thrice weekly was started in July. Despite 5 months of an aggressive 5 drug regimen, he continued to experience weight loss, dyspnea, and recurrent pleural effusions and eventually declined pleural decortication, artificial nutritional support, and further antimycobacterial therapy.

Case 2. A 34-year-old woman presented in 1997 with proximal muscle weakness and elevated creatinine phosphokinase (CPK) at 14,000 U/l. Electromyography and muscle biopsy were consistent with an inflammatory myopathy. She was initially treated with prednisone 60 mg/day, and azathioprine was added while the steroids were tapered to 5 mg/day. She did well with this regimen for 4 years; however, due to recurrent disease, MTX was added. Over the next 5 years she was treated with a combination of MTX (up to 35 mg/week), azathioprine 100-150 mg/day, and prednisone 10 mg/day. In 2006, she again experienced proximal muscle weakness and increased CPK to 3100 U/l. She was treated with 2 doses of rituximab 1000 mg administered 2 weeks apart. At that time, azathioprine was discontinued, and she continued taking MTX 25 mg/week IM and prednisone 7.5 mg/day, with normalization of her CPK over the next several months.

About 4 months after receiving rituximab, she developed erythema and pain in her left thigh with progressive difficulty ambulating. On examination, the affected anterolateral thigh was exquisitely tender to palpation, indurated, and erythematous. Magnetic resonance imaging of the proximal lower extremities revealed abnormal enhancement bilaterally consistent with myositis as well as enhancement within the left thigh indicative of fasciitis. She started receiving broad spectrum IV antibiotics, but the pain and induration progressed. Ultrasound of the painful thigh revealed a small fluid collection, and she underwent surgical debridement of grossly purulent material. Histologic examination demonstrated acute inflammation within the fibroadipose tissue extending to skeletal muscle. Rare bacterial

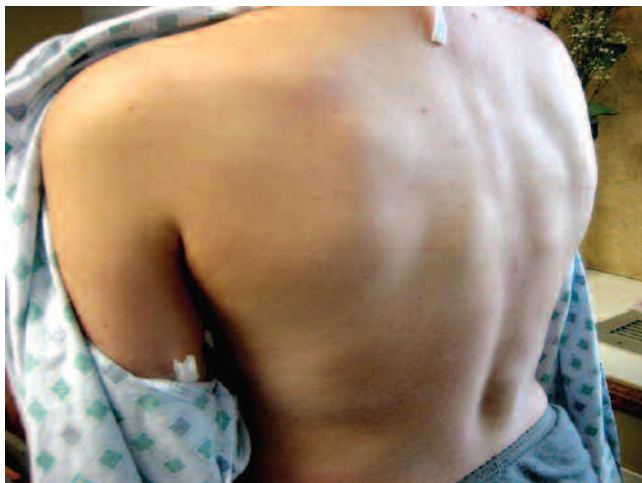

Figure 3. Scattered tender nodules covering the back at the time of the diagnosis of disseminated *M. kansasii* infection.

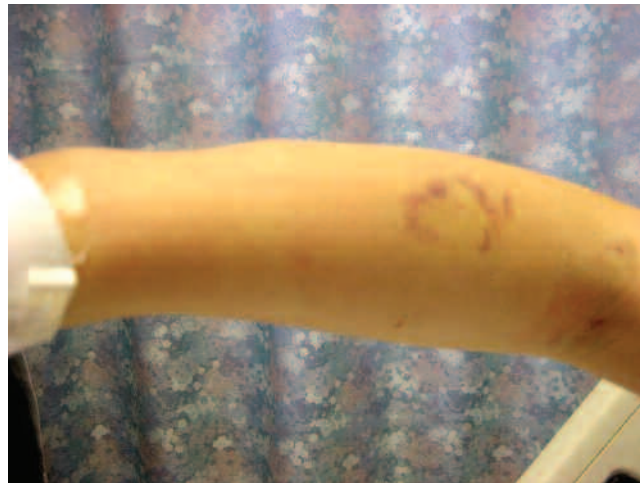

Figure 4. Profile of 2 forearm nodules.

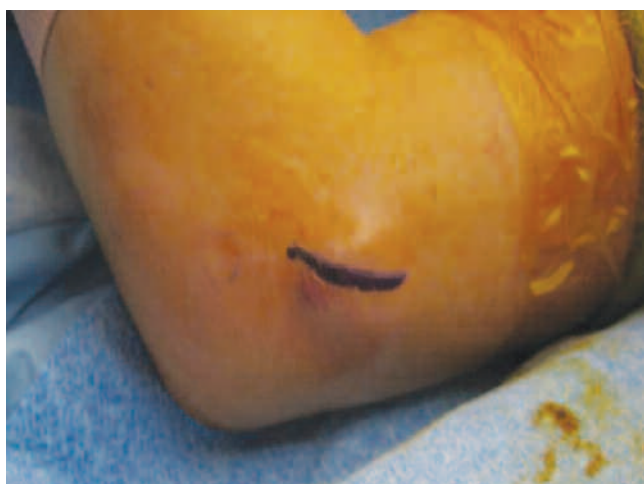

Figure 5. Elbow nodule.

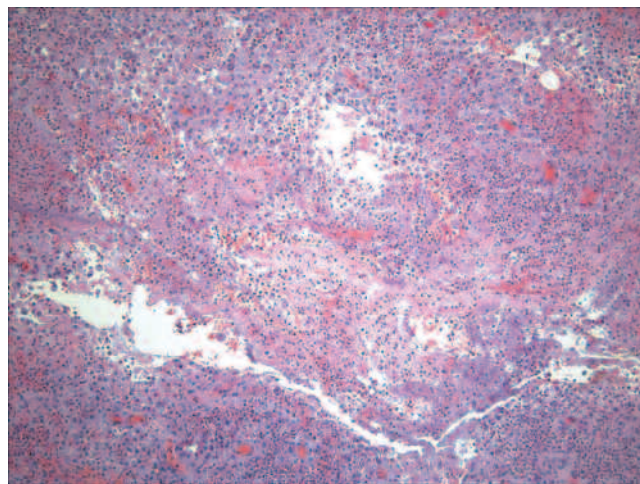


Figure 6. Deep skin biopsy showing a necrotic center with a predominance of neutrophils.

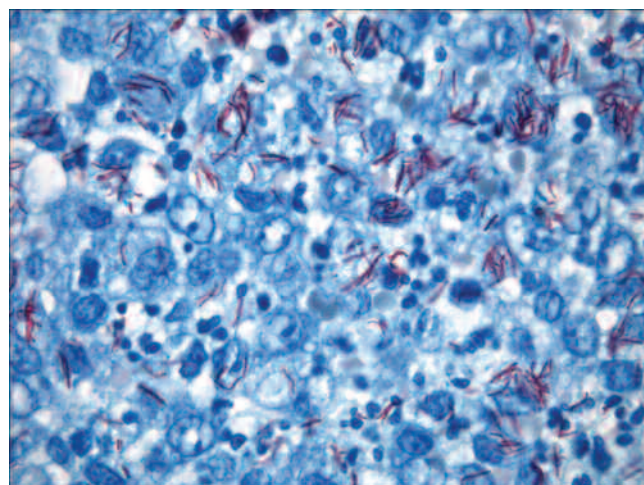


Figure 7. Skin biopsy revealing extensive acid fast bacilli.

forms were observed on gram stain; however, special stains (including AFB) as well as bacterial and mycobacterial cultures were negative. MTX was discontinued and her prednisone dose was decreased to 5 mg/day. She was treated with a 2 week course of IV vancomycin and oral levofloxacin with resolution of the local inflammation.

Unfortunately, her polymyositis flared 2 months later and her prednisone dose was increased to 10 mg/day with re-initiation of MTX 20 mg/wk. The CPK continued to rise to a peak of 1100 U/l and was accompanied by diffuse proximal muscle weakness, low-grade fever, and bilateral thigh discomfort. She was treated with another 2 doses of rituximab 750 mg for progressive polymyositis. Soon after the second dose, she developed hectic fevers to 39°C with emergence of diffuse subcutaneous nodules involving both her upper and lower extremities, which were tender and mobile but without overlying erythema or warmth. Due to concern for panniculitis, prednisone was transiently increased to 50 mg/day with initial improvement of her symptoms. Within a few days, however, she developed multiple subcutaneous nodules on her back, abdomen, and inguinal area as well as progression in size of the nodules on her extremities (Figures 3-5). Biopsy of a left forearm nodule demonstrated acute inflammation with extensive leukocytic infiltration and hemorrhagic necrosis consistent with

abscess formation involving the fascia, adipose tissue, and skeletal muscle. AFB stains revealed abundant acid-fast intracellular organisms (Figures 6 and 7).

She was treated with multiple antibiotics (rifampin, isoniazid, pyrazinamide, ethambutol, clarithromycin, imipenem, and amikacin) for empiric coverage of *M. tuberculosis* as well as NTM. Her immunosuppressive regimen was discontinued with the exception of low-dose prednisone. Her antimycobacterial regimen was modified after the growth of *M. kansasii* from both tissue and blood cultures. An HIV antibody test was negative and chest CT revealed no pulmonary disease. Her clinical course was complicated by *M. kansasii* osteomyelitis of her distal left clavicle requiring resection as well as rifampin-induced thrombocytopenia. The current treatment regimen includes azithromycin 500 mg (gastrointestinal intolerance to clarithromycin), moxifloxacin 400 mg, and isoniazid 900 mg daily. After 5 months of treatment, the subcutaneous nodules persist but are nontender and decreased in size, and her polymyositis is currently quiescent on prednisone 2.5 mg/day.

These are the first reported cases of NTM disease in patients treated with B cell depletion therapy. The presentation and clinical course of Case 1 was highly unusual given the isolated involvement of the pleural space with *M. avium* and the failure of aggressive antimycobacterial therapy in the face of rituximab treatment. In the second case, a patient with longstanding use of prednisone and MTX developed disseminated *M. kansasii* infection after beginning rituximab therapy. In both cases, we suspect the use of rituximab hindered the patient's immune response to appropriately combat the NTM infection.

NTM are slow-growing, intracellular environmental organisms that can cause chronic bronchopulmonary disease, lymphadenitis, skin and soft tissue disease, musculoskeletal infection, disseminated disease, and catheter-related infection¹. Pleural effusions due to *M. avium* are extremely rare, even in the case of pulmonary or disseminated disease. Pulmonary *M. avium* disease typically progresses slowly and most commonly affects individuals with a history of underlying lung pathology¹. Isolated *M. avium* pleural infections, as in Case 1, have been reported only twice in the literature^{2,3}. In these 2 cases of isolated *M. avium* pleuritis, both patients responded to antimycobacterial therapy with resolution of the effusions within 1.5 to 4.5 months^{2,3}. Isolated pleural effusions with other NTM are also rare, but infection with *M. fortuitum* and *M. kansasii* have been reported to improve with appropriate therapy^{4,5}. Similarly, *M. tuberculosis* pleural infections generally resolve with 6 months of therapy⁶, even in the face of prednisone therapy, which is recommended to decrease the scarring complications of such infections⁷.

The patient in Case 1 took prednisone throughout his antimycobacterial regimen, and received an aggressive course of 5 drug antimycobacterial therapy that included parenteral amikacin. One possible explanation for the treatment failure in this case is a lack of adherence to his oral antimycobacterial regimen. We were not able to evaluate this possibility with drug levels, although a pill count at 2 clinical visits suggested the patient was taking his medicine as recommended. Unfortunately, he declined surgical decortication that would have likely improved his chances of surviving the infection.

Case 2 describes a woman who developed disseminated *M. kansasii* infection with extensive soft tissue and bone involvement 4 months after receiving rituximab. She was also undergoing treatment with MTX and prednisone. Disseminated NTM occurs almost exclusively in the presence of severe immunosuppression, typically in the setting of HIV, organ transplantation, or malignancy^{8,9}. NTM infection has been reported in patients with systemic lupus erythematosus (SLE), most commonly resulting in soft tissue involvement but only rarely disseminated disease¹⁰. This report compared SLE patients with NTM to those with *M. tuberculosis* infections, and found that those with NTM disease had a higher cumulative dosage of prednisone and developed the infection later in the SLE disease course.

The regulation of mycobacterial infections is typically attributed to the CD4+ Th1 cells of the cellular immune response¹¹ with little known about the contribution of the humoral response. Rituximab, a monoclonal anti-

body that targets CD20 on the surface of late pro-, pre-, immature, mature, and memory B cells¹¹, has been used to treat refractory dermatomyositis and polymyositis¹²⁻¹⁹. Unlike the anti-tumor necrosis factor agents, thus far treatment with rituximab has not been associated with reactivation of latent tuberculosis²⁰. Several recent studies suggest that peripheral B cells are important in the host defense against mycobacteria, however. Maglione, *et al* recently found, in a murine tuberculosis model, that B cells were an important constituent of formed granulomas, and that B cell knockout mice failed to contain their tuberculosis infection and died²¹. Importantly, transfer of B cells to the infected knockout mice reversed the outcomes of mortality, lung bacterial burden, and pulmonary neutrophilia. Other recent work has highlighted the presence of B lymphocytes in the outer portion of granulomas in human lung tissue infected with *M. tuberculosis*²².

Together, our patients represent the first reports of severe NTM infection in patients receiving B cell depletion therapy. Because they were also treated with other immunosuppressants, it is not clear that rituximab therapy either promoted disease progression or caused NTM disease. Nonetheless, there is increasing evidence to support the importance of B cells in the response to these organisms, and the atypical nature of these cases suggests that clinicians should remain vigilant for NTM infections in patients selected for these therapies.

JOSEPH R. LUTT, MD, Fellow, Division of Arthritis and Rheumatic Diseases, 3181 SW Sam Jackson Park Road, Mail Code OP-09, Oregon Health and Science University, Portland, Oregon 97239, USA; MARY L. PISCULLI, MD, MPH, Fellow, Division of Infectious Disease, Brigham and Women's Hospital; MICHAEL E. WEINBLATT, MD, John R. and Eileen K. Riedman Professor of Medicine, Harvard Medical School, and Division of Rheumatology, Immunology and Allergy, Brigham and Women's Hospital, Boston, Massachusetts; ATUL DEODHAR, MD, Associate Professor of Medicine, Division of Arthritis and Rheumatic Diseases; KEVIN L. WINTHROP, MD, MPH, Assistant Professor of Medicine, Departments of Infectious Diseases, Ophthalmology, and Public Health and Preventive Medicine, Oregon Health and Science University.

Pathology slides courtesy of Dan Milner, MD (Boston, Massachusetts, USA).

REFERENCES

1. Mandell GL, Douglas RG, Bennett JE, Dolin R. Mandell, Douglas, and Bennett's principles and practice of infectious diseases. 5th ed. Philadelphia: Churchill Livingstone; 2000.
2. Nagaia T, Akiyama M, Mita Y, Tomizawa T, Dobashi K, Mori M. Mycobacterium avium complex pleuritis accompanied by diabetes mellitus. Diabetes Res Clin Pract 2000;48:99-104.
3. Okada Y, Ichinose Y, Yamaguchi K, Kanazawa M, Yamasawa F, Kawashiro T. Mycobacterium avium-intracellulare pleuritis with massive pleural effusion. Eur Respir J 1995;8:1428-9.
4. Baldi S, Rapellino M, Ruffini E, Cavallo A, Mancuso M. Atypical mycobacteriosis in a lung transplant recipient. Eur Respir J 1997;10:952-4.
5. Paull DE, Decker GR, Brown RL. Mycobacterium kansasii empyema in a renal transplant recipient case report and review of the literature. Transplantation 2003;76:270-1.
6. Canete C, Galarza I, Granados A, Farrero E, Estopa R, Manresa F. Tuberculous pleural effusion: experience with six months of treatment with isoniazid and rifampicin. Thorax 1994;49:1160-1.
7. Dooley DP, Carpenter JL, Rademacher S. Adjunctive corticosteroid therapy for tuberculosis: a critical reappraisal of the literature. Clin Infect Dis 1997;25:872-87.
8. Mok MY, Wong SS, Chan TM, Fong DY, Wong WS, Lau CS. Non-tuberculous mycobacterial infection in patients with systemic lupus erythematosus. Rheumatology Oxford 2007;46:280-4.
9. Zumla A, Grange J. Infection and disease caused by environmental

mycobacteria. *Curr Opin Pulm Med* 2002;8:166-72.

10. Lai CC, Lee LN, Ding LW, Yu CJ, Hsueh PR, Yang PC. Emergence of disseminated infections due to nontuberculous mycobacteria in non-HIV-infected patients, including immunocompetent and immunocompromised patients in a university hospital in Taiwan. *J Infect* 2006;53:77-84.
11. Janeway C. Immunobiology: the immune system in health and disease. 6th ed. New York: Garland Science; 2005.
12. Brulhart L, Waldburger JM, Gabay C. Rituximab in the treatment of antisynthetase syndrome. *Ann Rheum Dis* 2006;65:974-5.
13. Chiappetta N, Steier J, Gruber B. Rituximab in the treatment of refractory dermatomyositis. *J Clin Rheumatol* 2005;11:264-6.
14. Chung L, Genovese MC, Fiorentino DF. A pilot trial of rituximab in the treatment of patients with dermatomyositis. *Arch Dermatol* 2007;143:763-7.
15. Dinh HV, McCormack C, Hall S, Prince HM. Rituximab for the treatment of the skin manifestations of dermatomyositis: a report of 3 cases. *J Am Acad Dermatol* 2007;56:148-53.
16. Lambotte O, Kotb R, Maigne G, Blanc FX, Goujard C, Delfraissy JF. Efficacy of rituximab in refractory polymyositis. *J Rheumatol* 2005;32:1369-70.
17. Levine TD. Rituximab in the treatment of dermatomyositis: an open-label pilot study. *Arthritis Rheum* 2005;52:601-7.
18. Mok CC, Ho LY, To CH. Rituximab for Refractory Polymyositis: An Open-label Prospective Study. *J Rheumatol* 2007;34:1864-8.
19. Noss EH, Hausner-Sypek DL, Weinblatt ME. Rituximab as therapy for refractory polymyositis and dermatomyositis. *J Rheumatol* 2006;33:1021-6.
20. Looney RJ, Srinivasan R, Calabrese LH. The effects of rituximab on immunocompetency in patients with autoimmune disease. *Arthritis Rheum* 2007;58:5-14.
21. Maglione PJ, Xu J, Chan J. B cells moderate inflammatory progression and enhance bacterial containment upon pulmonary challenge with *Mycobacterium tuberculosis*. *J Immunol* 2007;178:7222-34.
22. Ulrichs T, Kosmiadi GA, Trusov V, et al. Human tuberculous granulomas induce peripheral lymphoid follicle-like structures to orchestrate local host defence in the lung. *J Pathol* 2004; 204:217-28.

Successful Treatment of Cardiac Sarcoidosis with Infliximab

To the Editor:

The clinical presentation of cardiac sarcoidosis may include arrhythmias, pericardial or valvular disease, congestive heart failure, or ventricular aneurysms¹. Cardiac sarcoidosis is regarded as an indication for corticosteroid therapy². Immunosuppressive agents are often combined with corticosteroids to reduce adverse effects. Anti-tumor necrosis factor- α (anti-TNF- α) therapy has been used to treat refractory sarcoidosis³, and TNF- α expression has been documented at sites where sarcoid granulomas are observed, and plays a critical role in granuloma formation⁴. Thus, anti-TNF- α therapy should result in suppression of disease manifestation and progression.

The use of infliximab in patients with cardiac sarcoidosis has been described in 3 case reports. One patient had pericardial disease but the outcome of treatment was not included in the report⁵. A patient with severe ocular involvement developed a malignant arrhythmia and did not experience any further ectopy after infliximab treatment⁶. In another report, a patient with biopsy-proven sarcoidosis and multiple conduction blocks responded to infliximab therapy and no longer requires backup pacing⁷.

We describe a patient with cardiac and muscle sarcoidosis who responded to infliximab. Cardiac status improved symptomatically and on magnetic resonance imaging (MRI).

A 58-year-old woman was initially assessed in October 2003 for management of biopsy-proven sarcoidosis in the right gastrocnemius muscle. Her history included refractory atrial fibrillation treated with amiodarone, type 2 diabetes mellitus, coronary artery disease, hypertension, celiac disease, glaucoma, and esophageal reflux. Initially no therapy was indicated as she was asymptomatic.

In April 2005, she reported episodes of tachycardia lasting up to 1 hour occurring once per week. An electrocardiogram showed first-degree atrioventricular block. She underwent a cardiac MRI, which showed normal cardiac chamber size and ejection fraction, without regional wall abnormalities. There was delayed enhancement of the mid-left ventricle cavity wall, particularly in the inferolateral segment, consistent with myocardial fibrosis of nonischemic origin and the diagnosis of cardiac sarcoidosis. Cardiac MRI markers of inflammation included an early enhancement ratio of 5.8 (normal < 4.0)⁸ and a T2 ratio for myocardial edema of 2.3 (normal < 2.0)⁹ (Figure 1).

She had developed extensive nodularity and pain in the extensor muscles of the forearms and calves. She was treated with prednisone 50 mg per day. Her muscle pain and palpitations improved, but blood glucose management deteriorated and she became markedly cushingoid. She also developed proximal muscle weakness and pain with distal paresthesias. These symptoms were initially ascribed to corticosteroid therapy and the prednisone was tapered to 10 mg per day. Nerve conduction studies, however, showed her symptoms to be due to diabetic amyotrophy and a peripheral neuropathy. Repeat cardiac MRI in March 2006 showed inferolateral wall abnormalities with loculated organizing pericardial fluid over the right ventricle.

Infliximab therapy was initiated in May 2006 at 3 mg/kg at Weeks 0, 2, and 6, and then every 8 weeks. She continues to receive prednisone 5 mg per day (due to adrenal insufficiency). The nodularity in her extremities has improved clinically and on imaging. Repeat cardiac MRI showed improvement of the early enhancement ratio to 2.4 and the T2 ratio to 1.9, consistent with resolution of active inflammation and no progression in fibrosis (Figure 2).

We report this case to show that infliximab may be effective in the treatment of cardiac sarcoidosis in patients in whom corticosteroids are either ineffective or are associated with unacceptable adverse effects. We recognize that there may be issues concerning infliximab use in patients with heart failure, as increased mortality has been reported¹⁰. Such patients would require close monitoring if a decision is made to use infliximab. Further study of infliximab in treating sarcoidosis is also required to determine the appropriate dose and duration of therapy.

A high index of suspicion is required to diagnose cardiac sarcoidosis. Preliminary investigations of patients with sarcoidosis should include a thorough evaluation of the cardiovascular system for conduction defects and valvular and pericardial abnormalities. Cardiac MRI holds promise in the diagnosis and monitoring of patients with cardiac sarcoidosis. However, the prognostic significance of changes in markers of myocardial inflammation identified on cardiac MRI remains to be determined.

CHERYL BARNABE, MD, FRCPC, Resident, Division of Rheumatology, University of Calgary; JAMES McMEEKIN, MD, FRCPC, Clinical Professor of Medicine, Libin Cardiovascular Institute of Alberta, University of Calgary; ANDREW HOWARTH, MD, PhD, FRCPC, Assistant Professor, Libin Cardiovascular Institute of Alberta, University of Calgary; LIAM MARTIN, MB, MRCPI, FRCPC, Professor of Medicine, Division of Rheumatology, Department of Medicine, University of Calgary, Room 410, Heritage Medical Research Building, 3350 Hospital Drive NW, Calgary, Alberta T2N 2T9, Canada. Address reprint requests to Dr. Martin. E-mail: lmartin@ucalgary.ca

REFERENCES

1. Mori M, Hanon S, Rachko M. Cardiac sarcoidosis presenting with ventricular arrhythmias: Case report and review of the literature. *Int J Cardiol* 2007;120:e21-3.

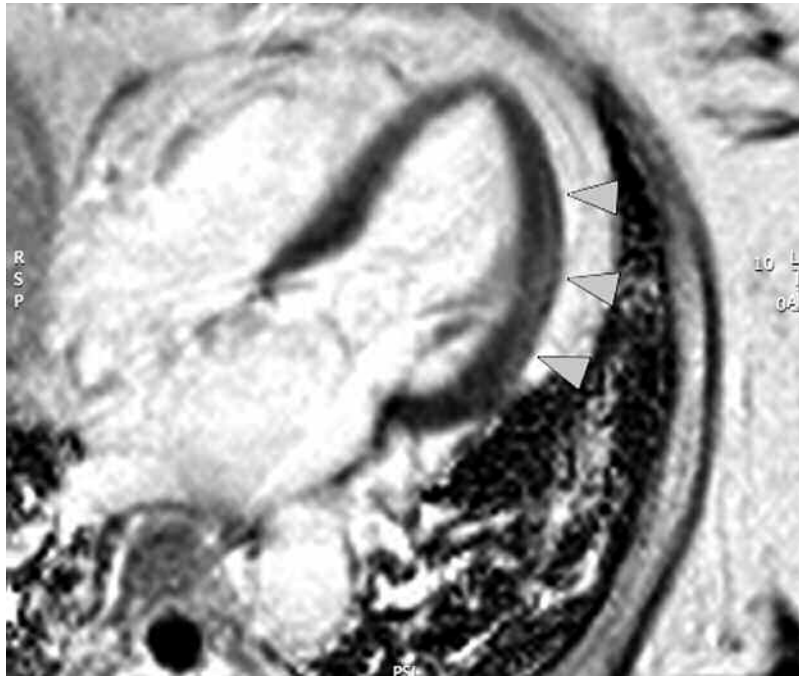


Figure 1. Initial cardiac MRI. Arrows indicate area of increased late enhancement in the mid-posterolateral wall region consistent with myocardial fibrosis of nonischemic origin and the diagnosis of cardiac sarcoidosis.

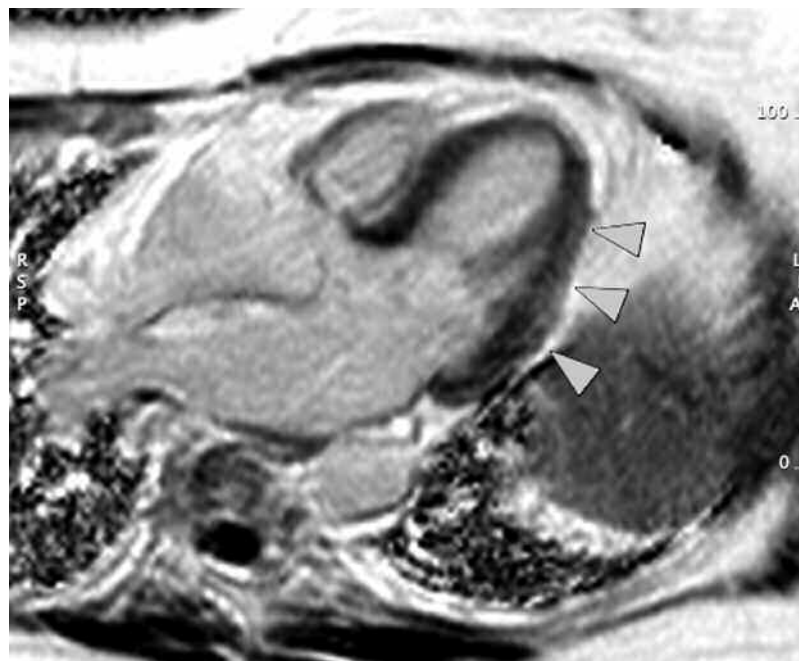


Figure 2. Repeat cardiac MRI 13 months later. No interval change in late enhancement.

2. Chapelon-Abric C, de Zuttere D, Duhaut P, et al. Cardiac sarcoidosis: a retrospective study of 41 cases. *Medicine Baltimore* 2004;83:315-34.
3. Ulbricht KU, Stoll M, Bierwirth J, Witte T, Schmidt RE. Successful tumor necrosis factor alpha blockade treatment in therapy-resistant sarcoidosis. *Arthritis Rheum* 2003;48:3542-3.
4. Moller DR. Treatment of sarcoidosis — from a basic science point of view. *J Intern Med* 2003;253:31-40.
5. Doty JD, Mazure JE, Judson MA. Treatment of sarcoidosis with infliximab. *Chest* 2005;127:1064-71.
6. Roberts SD, Wilkes DS, Burgett RA, Knox KS. Refractory sarcoidosis responding to infliximab. *Chest* 2003;124:2028-31.

7. Uthman I, Touma Z, Khoury M. Cardiac sarcoidosis responding to monotherapy with infliximab. *Clin Rheumatol* 2007;26:2001-3.
8. Walker PM, Marie PY, Danchin N, Bertrand A. Comparison of T1 estimation techniques in cardiac MRI. *Magn Reson Imaging* 1994;12:43-50.
9. Marie PY, Angioi M, Carreaux JP, et al. Detection and prediction of acute heart transplant rejection with the myocardial T2 determination provided by black blood magnetic resonance imaging sequence. *J Am Coll Cardiol* 2001;37:825-31.
10. Chung ES, Packer M, Lo KH, Fasanmade AA, Willerson JT. Randomized, double-blind, placebo-controlled, pilot trial of infliximab, a chimeric monoclonal antibody to tumor necrosis factor-alpha, in patients with moderate to severe heart failure: results of the Anti-TNF Therapy Against Congestive Heart Failure (ATTACH) trial. *Circulation* 2003;107:3133-40.

Corrections

Linde L, Sørensen J, Østergaard M, Hørslev-Petersen K, Hetland ML. Health-related quality of life: validity, reliability, and responsiveness of SF-36, EQ-15D, EQ-5D, RAQoL, and HAQ in patients with rheumatoid arthritis. *J Rheumatol* 2008;35:1528-37. The title should read Health-related quality of life: validity, reliability, and responsiveness of SF-36, 15D, EQ-5D, RAQoL, and HAQ in patients with rheumatoid arthritis. We regret the error.

Khan AA, Sándor GBK, Dore E, et al. Canadian consensus practice guidelines for bisphosphonate associated osteonecrosis of the jaw. *J Rheumatol* 2008;35:1391-7. Acknowledgment of funding sources should have included the Canadian Association of Oral and Maxillofacial Surgeons Foundation for Continuing Education and Research. We regret the error.