

Color Doppler Ultrasonography of Hand and Finger Arteries to Differentiate Primary from Secondary Forms of Raynaud's Phenomenon

WOLFGANG A. SCHMIDT, ANDREAS KRAUSE, BERND SCHICKE, AND DIRK WERNICKE

ABSTRACT. *Objective.* Modern ultrasound (US) equipment allows rheumatologists to directly visualize hand and finger arteries. How does US aid in diagnosis of Raynaud's phenomenon (RP)?

Methods. Color Doppler US of the proper and common palmar digital, radial, and ulnar arteries and the superficial palmar arch of both hands was performed in 135 consecutive patients who presented with suspected RP.

Results. US was pathologic in 63% of patients with secondary RP, in 6% with primary RP, and in none with pseudo-RP ($p < 0.0001$). We found 3 types of vascular pathology: Type 1 showed narrowing or chronic occlusion of some proper digital arteries; Type 2 was characterized by the same finding in all proper digital arteries; and Type 3 involved acute occlusions. Type 1 was found in 3 of 53 patients with primary RP and in 19 patients with secondary RP including 5 of 9 patients with anti-centromere positive systemic sclerosis (SSc); Type 2 occurred in 16 patients with SSc, MCTD, and dermatomyositis; and Type 3 was found in 8 patients with antiphospholipid antibody syndrome, thromboangiitis obliterans, vibration trauma, or vasculitis. The ulnar arteries were more commonly affected than the radial arteries. The 2nd radial, 3rd radial, 4th ulnar, and 5th ulnar proper palmar digital arteries were most commonly involved.

Conclusion. Aiding in differentiating primary versus secondary RP, severe versus less severe disease, and acute versus chronic vascular occlusion, digital artery US depicts the same anatomical structures as angiography, but it is cheaper, faster, and noninvasive. (First Release July 15 2008; J Rheumatol 2008;35:1591-8)

Key Indexing Terms:

ULTRASONOGRAPHY
RAYNAUD'S DISEASE

COLOR DOPPLER ULTRASONOGRAPHY
SYSTEMIC SCLEROSIS
CONNECTIVE TISSUE DISEASE
PERIPHERAL ARTERIAL DISEASE

Rheumatologists, who often see patients with Raynaud's phenomenon (RP), need to be able to differentiate between primary and secondary forms of this disease. In primary RP no definable cause for an increased episodic vasoconstriction to cold exposure can be found. Secondary RP is characterized by an underlying cause or an associated disease. Secondary RP occurs in connective tissue diseases (CTD) such as systemic sclerosis (SSc) and mixed connective tissue disease (MCTD), antiphospholipid syndrome (APS), and vasculitis, among other diseases. Primary RP is usually entirely reversible with application of heat. Complications like finger necroses are almost always associated with sec-

ondary RP. Further, some patients with arthritis of finger joints complain of symptoms that may be misinterpreted as RP (pseudo-RP).

In secondary RP, like in SSc, the overproduction of collagen leads to intimal hyperplasia and fibrosis of digital arteries. This often results in structural narrowing or occlusion¹. The vasculopathy is not atherosclerotic. In other CTD the cause of finger artery narrowing or occlusion is less clear. It may also be caused by acute thrombosis or vasculitis.

Rheumatologists are increasingly using ultrasound (US). They are particularly interested in knowing about structural pathologies of hands and fingers. In addition, color and power Doppler US allow rheumatologists to demonstrate intraarticular vascularity. Increased intraarticular blood flow corresponds well with the inflammatory activity. The hand and finger arteries are localized closely to standard scans for examining wrist and finger joints. Although pathologic finger arteries contribute to considerable symptoms that send patients to the rheumatologist, little attention has yet been paid to their assessment by US.

Modern US equipment allows rheumatologists to easily visualize the finger arteries. Spatial resolution of modern

From the Medical Center for Rheumatology Berlin-Buch; and Department of Statistics, Tumor Centrum Berlin, Berlin, Germany.

W.A. Schmidt, MD, Rheumatologist, Deputy Director; A. Krause, MD, Rheumatologist, Director, Medical Center for Rheumatology Berlin-Buch; B. Schicke, Statistician, Tumor Centrum Berlin; D. Wernicke, MD, Rheumatologist, Medical Center for Rheumatology Berlin-Buch.

Address reprint requests to Dr. W.A. Schmidt, Medical Center for Rheumatology Berlin-Buch, Karower Str. 11, 13125 Berlin, Germany. E-mail w.schmidt@immanuel.de

Accepted for publication March 19, 2008.

Personal non-commercial use only. The Journal of Rheumatology Copyright © 2008. All rights reserved.

transducers is about 0.1 to 0.2 mm. This is far superior to what is necessary to depict these anatomical structures. Doppler US is primarily used for the hemodynamic assessment of blood vessels. This technique relies on the Doppler effect to detect the movement of red blood cells in the vessels by analyzing the change in frequency of the returning echoes. The Doppler effect is the apparent change in frequency and wavelength of a wave that is perceived by an observer moving relative to the source of the waves. In color Doppler US the Doppler effect is combined with real-time imaging. The information from the Doppler ultrasonograph is integrated onto the gray-scale image as a color signal².

This study investigates the following objectives: To what extent can color Doppler US aid in distinguishing primary from secondary forms of RP? Can color Doppler US estimate the severity of digital artery disease? Do various patterns of artery involvement relate to different rheumatic diseases? This study describes this new application of color Doppler US in patients with primary and secondary RP who present at a rheumatologic institution.

MATERIALS AND METHODS

Patients. We examined all consecutive patients between January 1 and December 31, 2006, who presented with suspected RP to the Medical Center for Rheumatology Berlin-Buch, Berlin, Germany, a large tertiary rheumatologic referral center. All patients reported episodic digital blanching or cyanosis associated with cold exposure. In total we examined 270 hands of 135 patients. Rheumatologists at the center who conducted diagnostic investigations did not also perform US examinations.

Ultrasound examination. The patients bathed both hands in hot water (about 40°C) for about 5 minutes to induce vasodilatation just before the US examination, and to allow to delineate all 10 proper palmar digital arteries of each hand, between the metacarpophalangeal and proximal interphalangeal (PIP) joints and between the PIP and distal interphalangeal joints. Thereafter, the sonographer, an experienced sonologist and rheumatologist, assessed the 3 common palmar digital arteries, the superficial palmar arch, and the radial and ulnar arteries at the wrists.

Figure 1 describes the anatomy of the hand arteries³. The diameters of the radial and ulnar arteries at the level of the wrist are about 2.5–3.5 mm^{4,5}. The ulnar artery continues to the superficial palmar arch. Eighty to 90% of the arches are complete, i.e., they communicate with the radial artery⁴. The diameters of the superficial palmar arch and the common palmar digital arteries are about 1.5–2 mm^{4,5}. Each finger has 2 proper palmar digital arteries that are localized on the radial and ulnar palmar aspect. The diameter of the proper palmar digital arteries is about 0.9–1.5 mm^{6,7}.

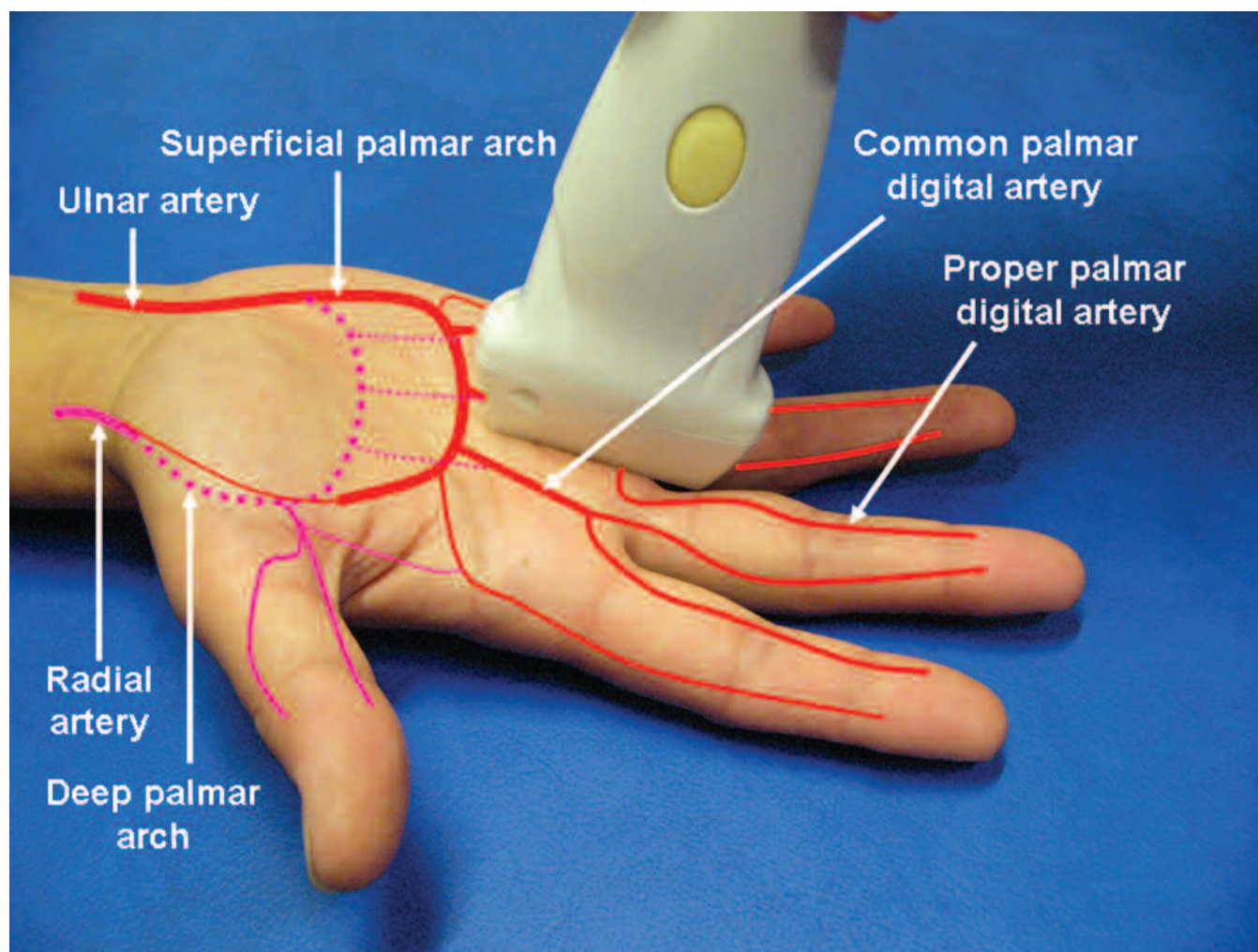


Figure 1. Ultrasound examination and anatomy of hand and finger arteries [original size 254 × 190 mm (72 × 72 DPI)].

We applied an 8–14 MHz linear probe (LA 424; length of probe, 38 mm; Esaote Technos MPX; Esaote SP, Genoa, Italy). The scanner settings were uniform for all examinations: B mode frequency setting, 13 MHz; B mode gain, 115%; one focus point position just below the region of interest; procession parameter, PB 3; scan correlation parameter, SCC 5; enhancing parameter, ENH 5; color Doppler frequency: 10 MHz; pulse repetition frequency, PRF 1.2 KHz; color gain, 200%.

A complete bilateral examination lasted 5–10 minutes in case of normal findings and 10–20 minutes in case of pathologic findings.

Statistical analysis. The SPSS-V14 statistical package was used for statistical analysis. The Mann-Whitney U test, or the chi-square test was applied to compare the results.

RESULTS

The mean age of the 135 patients was 46 years ($SD \pm 16$; range 16–83), 106 patients were female. Fifty-three patients (39%) had primary RP. They had a mean age of 45 years ($SD \pm 16$; range 16–83; 44 females). Secondary RP occurred in 67 patients (50%). Nineteen (14%) of these patients had SSc, 34 (25%) had other CTD, 14 (10%) had other potential

vascular occlusive diseases like APS, thromboangiitis obliterans, Sneddon's syndrome, vibration trauma, and digital artery vasculitis. These patients had a mean age of 46 years ($SD \pm 15$; range 17–77; 52 females). Further, 15 patients (11%) had arthritis mimicking RP (pseudo-RP). Their mean age was 49 years ($SD \pm 16$; range 22–74; 10 females). There was no significant difference between the 3 groups with regard to age and sex.

US depicted either normal arteries, markedly narrowed arteries, or chronically or acutely occluded arteries (Figure 2). Normal arteries could be easily and quickly detected showing homogeneous color signals and pulsation (Figure 2A). Narrowed arteries exhibited considerably reduced flow and pulsation. The arteries were often twisted and difficult to delineate (Figure 2B). Chronically occluded arteries could be seen neither by gray scale nor by color Doppler US in their expected anatomical course (Figure 2C). Acutely occluded arteries could be delineated in the gray scale image

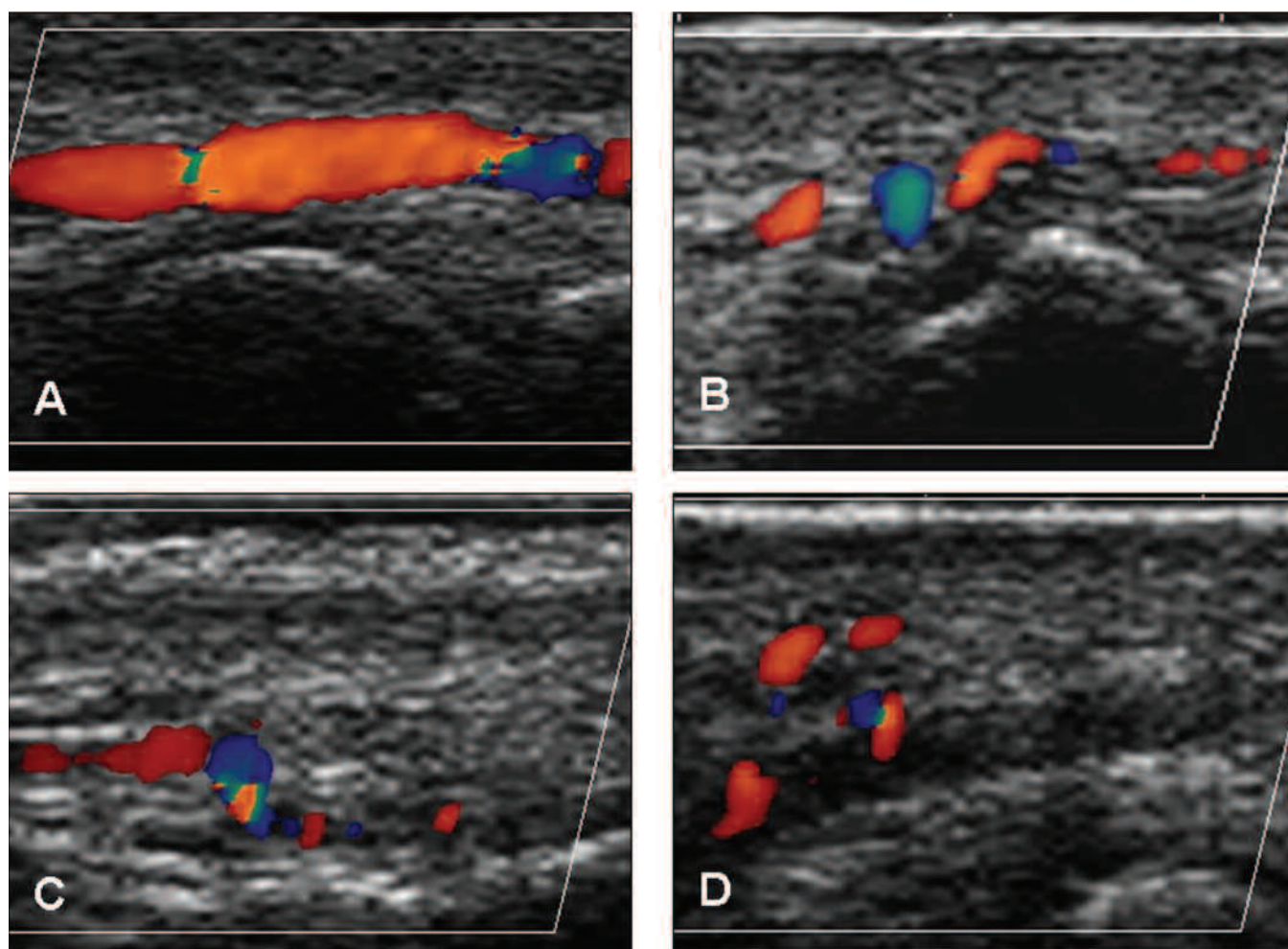


Figure 2. Color Doppler ultrasound longitudinal images of finger arteries proximally to or at the PIP joint. A. Normal left second ulnar proper palmar digital artery; B. Narrowing of the right fourth radial proper palmar digital artery in systemic sclerosis (patient with type 2 pathology); C. Chronically occluded right second ulnar proper palmar digital artery in APS. Collateral flow appears in the lower part of the image (patient with type 1 pathology); D. Acute occlusion of the right fourth radial proper palmar digital artery in Wegener's granulomatosis (patient with type 3 pathology). The dark structure in the middle of the image represents the occluded artery. The color above the artery represents collateral flow [original size: 254 × 190 mm (72 × 72 DPI)].

as a hypoechoic area without color signals representing thrombotic material as also can be seen in acute arterial embolism, acute vasculitis, or acute phlebothrombosis (Figure 2D). Acutely occluded arteries were defined by their ultrasonographic appearance, not by duration of symptoms. Pulsating color signals outside the former arteries represented collateral flow.

Pathologic finger arteries occurred in 63% of patients with secondary RP, in 6% with primary RP, and in none of those with pseudo-RP. The difference between findings in primary and secondary RP was significant ($p < 0.0001$).

Forty-six patients (34%) had pathologic findings. It was possible to distinguish 3 types of pathology. Table 1 provides further details.

Type 1: Chronic occlusion or narrowing of some digital arteries together with other normal proper palmar digital arteries. We found this type in different diseases and in 3 patients with primary RP. Table 2 describes the distribution of the involved arteries in these patients. In 10 patients US detected involvement of arteries proximal to the proper palmar digital arteries. The ulnar arteries were involved in 3 patients.

Type 2: Narrowing or complete chronic occlusion of all proper palmar digital arteries. Narrowed arteries showed reduced pulsation and slightly hyperechoic vessel walls, with or without complete chronic occlusion of some of these arteries. We found this type in all 10 patients with SSc who had antibodies other than anti-centromere antibodies, and in 6 other patients with CTD (Table 1).

In 5 SSc patients with type 2 pattern the arteries proximal to the proper palmar digital arteries were involved. Table 3 shows the distribution of artery involvement in these patients.

Type 3: Acute occlusion of digital arteries together with other normal, narrowed, or occluded arteries. In 2 of these 8 patients the acute occlusions were restricted to the proper palmar digital arteries (Table 3). Four patients had acutely occluded ulnar arteries.

Only 3 of the 53 patients with primary RP had chronic occlusion and/or narrowing of 1 to 3 digital and/or palmar arteries. All cases with pseudo-RP had normal findings.

There were no statistically significant differences between left and right hands. Eight right and 6 left ulnar arteries were involved. The numbers of pathologic super-

Table 1. Normal and pathologic color Doppler ultrasound findings of hand and finger arteries.

	N	N	Normal	Pathology, Type 1*	Pathology, Type 2**	Pathology, Type 3***
Primary Raynaud's phenomenon	53		50	3	—	—
Systemic sclerosis	19		—	5	13	1
Anti-centromere antibodies		9	—	5	3	1
Anti-Ku antibodies		3	—	—	3	—
Anti-Scl 70 antibodies		2	—	—	2	—
Anti-PM-Scl antibodies		1	—	—	1	—
No antibody		4	—	—	4	—
Other connective tissue diseases	34		24	7	3	—
Dermatomyositis: 1		1	—	—	1	—
Systemic lupus erythematosus		7	7	—	—	—
Mixed connective tissue disease		6	—	4	2	—
Undifferentiated connective tissue disease		9	6	3	—	—
Circumscribed scleroderma		2	2	—	—	—
Sjögren's syndrome		9	9	—	—	—
Other potential occlusive diseases	13		1	6	—	6
APS		6	1	2	—	3
Thromboangiitis obliterans		4	—	2	—	2
Sneddon's syndrome		1	—	1	—	—
Vibration trauma		2	—	1	—	1
Vasculitis	2		—	1	—	1
Wegener's granulomatosis		1	—	—	—	1
Rheumatoid vasculitis		1	—	1	—	—
Pseudo Raynaud's phenomenon	14		14	—	—	—
Rheumatoid arthritis		7	7	—	—	—
Osteoarthritis		4	4	—	—	—
Gout		2	2	—	—	—
Reactive arthritis		1	1	—	—	—
Total	135		89	22	16	8

* Type 1: Narrowing or chronic occlusion of some proper digital arteries. ** Type 2: Narrowing or chronic occlusion of all proper digital arteries. *** Type 3: Presence of acute occlusions.

Table 2. Patients with type 1 pathology (each bullet represents one patient).

Diagnosis	Pathology
Primary Raynaud's phenomenon	<ul style="list-style-type: none"> • 2 PPDA (occluded), left CPDA 2/3 (occluded) • left CPDA 2/3 (occluded) • left CPDA 2/3 (narrowed)
Anti-centromere antibody positive systemic sclerosis	<ul style="list-style-type: none"> • 17 PPDA (narrowed or occluded) • 5 PPDA (narrowed or occluded) • 1 PPDA (occluded) • 1 PPDA (occluded) • right UA (occluded) right SPA (occluded)
Mixed connective tissue disease	<ul style="list-style-type: none"> • 6 PPDA (narrowed), both CPDA 2/3 (narrowed) • 2 PPDA (occluded), both CPDA 2/3 (occluded) • 1 PPDA (occluded) • 1 PPDA (occluded)
Undifferentiated connective tissue disease	<ul style="list-style-type: none"> • 2 PPDA (occluded), right CPDA 2/3 (occluded) • 1 PPDA (occluded), left CPDA 2/3 (narrowed) • 2 PPDA (occluded)
Antiphospholipid antibody syndrome	<ul style="list-style-type: none"> • 8 PPDA (occluded), both UA (occluded) • 1 PPDA (occluded)
Thromboangiitis obliterans	<ul style="list-style-type: none"> • 10 PPDA (occluded) • 3 PPDA (occluded), 3 CPDA (occluded), left UA (occluded), right UA (narrowed), right SPA (narrowed)
Sneddon's syndrome	<ul style="list-style-type: none"> • 2 PPDA (occluded)
Vibration trauma	<ul style="list-style-type: none"> • 4 PPDA (occluded)
Rheumatoid vasculitis	<ul style="list-style-type: none"> • 4 PPDA (occluded), 3 PPDA (narrowed)

PPDA: Proper palmar digital arteries; CPDA: common palmar digital arteries; UA: ulnar arteries; SPA: superficial palmar arch.

Table 3. Patients with type 2 and type 3 pathology (each bullet represents one patient).

Diagnosis	Pathology
Anti-Scl-70 antibody positive systemic sclerosis	<ul style="list-style-type: none"> • Type 2: both CPDA 2/3 (chronically occluded), all PPDA narrowed or chronically occluded
Anti-Ku antibody positive systemic sclerosis	<ul style="list-style-type: none"> • Type 2: left CPDA 2/3 (chronically occluded), all PPDA narrowed or chronically occluded
Systemic sclerosis without antibodies	<ul style="list-style-type: none"> • Type 2: left CPDA 3/4 (chronically occluded), all PPDA narrowed or chronically occluded
Anti-centromere antibody positive systemic sclerosis	<ul style="list-style-type: none"> • Type 2: right UA right CPDA (chronically occluded), all PPDA narrowed or chronically occluded • Type 2: both UA, both SPA, all CPDA except 2/3 left (chronically occluded), all PPDA narrowed or chronically occluded • Type 3: 1 PPDA (acutely occluded), 2 PPDA (chronically occluded), 17 PPDA (narrowed), right CPDA 3/4, 4/5, right SPA, right UA (acutely occluded)
Antiphospholipid antibody syndrome	<ul style="list-style-type: none"> • Type 3: 1 PPDA, both SPA, both UA (acutely occluded), 2 PPDA (chronically occluded) • Type 3: 4 PPDA (acutely occluded), 2 PPDA (chronically occluded), 8 PPDA (narrowed) • Type 3: 2 PPDA (acutely occluded), 8 PPDA, left CPDA 2/3 (chronically occluded)
Thromboangiitis obliterans	<ul style="list-style-type: none"> • Type 3: 16 PPDA, right CPDA 2/3, 3/4, both SPA, both UA (acutely occluded), 1 PPDA, all left CPDA (narrowed) • Type 3: 4 PPDA (acutely occluded)
Vibration trauma	<ul style="list-style-type: none"> • Type 3: 2 PPDA, left CPDA 3/4, left UA (acutely occluded), 2 PPDA, left CPDA 2/3 (chronically occluded)
Wegener's granulomatosis	<ul style="list-style-type: none"> • Type 3: 11 PPDA and right CPDA 2/3 acutely occluded

PPDA: Proper palmar digital arteries; CPDA: common palmar digital arteries; UA: ulnar arteries; SPA: superficial palmar arch.

ficial palmar arches were 6 and 9, of common palmar digital arteries 14 and 20, and proper palmar digital arteries 236 and 245, respectively. No patient exhibited narrowed or occluded radial arteries (significance compared to ulnar artery involvement, $p < 0.01$). Figure 3 describes the number of involved arteries of both hands. The 2nd and 3rd radial and the 4th and 5th ulnar proper palmar digital arteries were more commonly involved than the other proper palmar digital arteries ($p < 0.01$). The common palmar digital arteries that supply the second and third fingers were more frequently involved than the other common palmar digital arteries ($p < 0.05$).

DISCUSSION

Easy and quick to perform in the diagnosis of RP using equipment that is available to an increasing number of rheumatologists, color Doppler US of the hand and finger arteries can depict the arteries and show pulsation, and the sonographer can explain the findings to patients directly during the examination. Bathing both hands in hot water right before the US examination makes the injection of vasodilators unnecessary.

Our approach of examining all hand and finger arteries directly with color Doppler US differs from previous strategies for assessing the vasculature of the hand in RP. We focussed on the direct morphologic appearance of the arteries.

We defined 3 types of vascular pathology to further distinguish entities for clinical practice. Type 2 represents more severe findings than type 1, since all proper palmar digital arteries are affected. All patients with SSc exhibited severe pathology, whereas only some patients with anti-centromere

antibody positive SSc had type 1 pathology. Type 3 represents acute occlusions. These occur less frequently in CTD unless associated with APS, but occlusions were also found in thromboangiitis obliterans, vibration trauma, or vasculitis.

We recently described 3 patients with vasculitis (2 with Wegener's granulomatosis and one with an overlap syndrome of rheumatoid arthritis and systemic lupus erythematosus) who exhibited acute digital artery occlusion⁸. Following therapy complete or partial reperfusion occurred. Some patients in whom chronic occlusions were visualized by ultrasound may have had an earlier acute occlusion or embolism. In our experience it takes an acutely occluded artery about 3 to 6 months to take on the appearance of a chronically occluded artery. These findings are indicative that finger artery US is sensitive enough to detect change.

The ulnar arteries were more frequently involved than the radial arteries. This difference has also been described in studies using angiography in SSc and in MCTD^{9,10}. The reason for this difference remains unclear. Angiographic studies in these diseases also revealed that the superficial palmar arch is more frequently affected in severe cases than the deep palmar arch (87% vs 13%)¹⁰. A study that examined ulnar and radial arteries with US found that 10 of 20 SSc patients but none of the controls exhibited lumen reduction with smooth, slightly hyperechoic wall thickening of ulnar arteries¹¹. This morphology is not specific for SSc. It has also been described in thromboangiitis obliterans¹², and it usually occurs in late disease. Therefore, vascular US is not as important for the diagnosis of SSc as it is for the diagnosis of giant cell arteritis and Takayasu arteritis, where a homogenous wall swelling is almost pathognomonic¹³.

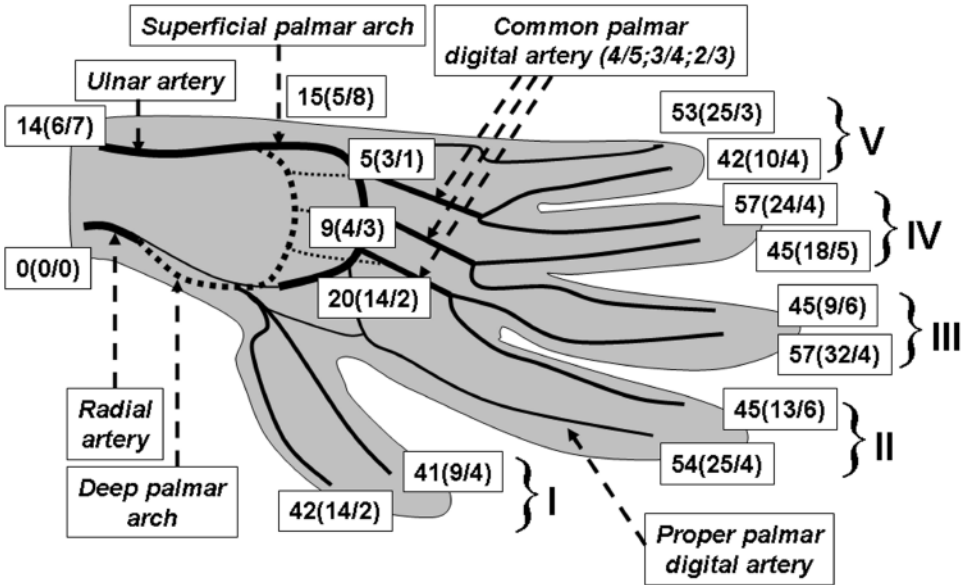


Figure 3. Number of pathologic hand and finger arteries, i.e., occluded or narrowed arteries. The first and second numbers shown in brackets represent the number of chronically and acutely occluded arteries, respectively [original size 254 × 190 mm (72 × 72 DPI)].

US technology, and thus the resolution of US images, has considerably improved in recent years. A report from 1993 on color Doppler US of normal proper palmar digital arteries described average diameters of 0.9 mm to 1.3 mm and stated that the accuracy and ease of use of this technique in measurement of vessels are limited when vessels are less than 1.5 mm in diameter¹⁴. To date, modern transducers provide resolutions of 0.1 to 0.2 mm. The following numbers indicate diameters measured by angiography / in cadavers in proper palmar digital arteries: 1.0 mm / 1.0 mm (2nd radial artery); 1.4 mm / 1.5 mm (2nd ulnar artery); 1.2 mm / 1.3 mm (3rd radial artery); 1.4 mm / 1.4 mm (3rd ulnar artery); 1.2 mm / 1.4 mm (4th radial artery); 1.1 mm / 1.3 mm (4th ulnar artery); 1.2 mm / 1.3 mm (5th radial artery); 0.9 mm / 0.9 mm (5th ulnar artery)⁷. The second and third radial and the fourth and fifth ulnar proper palmar digital arteries, which were most commonly involved in our study, are smaller than the respective other proper palmar digital artery of the same finger. Another study used A-mode US, a simple one dimensional method, to measure diameters of the proper digital arteries of the 2nd finger¹⁵. The authors concluded that the diameter increased from 1.1 mm to 1.2 mm with temperature change from 20° to 30°C. We did not examine the deep palmar arch because it is difficult to delineate using US. Further, this site is rarely affected¹⁰.

Another study applied duplex US to the second ulnar proper palmar digital artery and the most proximal portion of the deep radial palmar arch before and after a cooling test. Blood flow velocity curves of patients with RP displayed higher resistance and pulsatility indexes but lower peak systolic and end-diastolic velocities¹⁶. Blood flow characteristics depend, among others, on sympathicotonia, respiratory phase, and venous pressure. Further, measurements are time-consuming, particularly if applied to all arteries of both hands.

Color Doppler US of the nailbed of the second and third right finger after cold and warm challenge helped to differentiate primary from secondary RP¹⁷. Patients with primary RP had normal vascularity at ambient temperature but reduced vascularity after cold challenge. Patients with CTD had reduced vascularity at ambient temperature as well as after cold and warm challenge.

How does color Doppler US correlate with angiography? One study, published in 1997, compared the examinations of 45 hands in 41 symptomatic patients at high risk for finger artery impairment¹⁸. Sensitivities and specificities of US to detect occlusions were 86% and 93%, respectively. To date one can expect even better results as US image quality has improved.

Two newer studies found agreements of 100% between continuous wave- (cw-) Doppler US and angiography¹⁹ and cw-Doppler US and magnetic resonance angiography (MRA)²⁰ to detect occluded arteries.

Most experience exists with angiography²¹. It provides a

good overview with high resolution. Drawbacks are the need of arterial puncture, the use of contrast agent, intraarterial injection of a vasodilator and ionizing load. Further, the investigation is usually restricted to one hand.

Contrast-enhanced magnetic resonance angiography dispenses with arterial puncture. It also provides an excellent overview of the vasculature of the hand. Nevertheless, it is rather expensive, and again, examination is usually restricted to one hand. It has limitations concerning spatial and temporal resolution when compared with angiography²², but the imaging quality is increasing with newer technology. Further, it less clearly differentiates acute from chronic finger artery occlusion versus US⁶.

Digital plethysmography, nailfold capillary microscopy, laser Doppler blood flow monitoring, thermography, and finger systolic blood pressure measurements are indirect methods that have been used in the diagnosis of RP²³.

Plethysmography relies on the measurement of volume change. In one study with MCTD patients, sensitivity and specificity findings compared to angiography were 92% and 42%, respectively¹⁰. In another study with SSc patients angiography and plethysmography both correlated only in 50%²⁴.

Capillaroscopy detects characteristic nailfold capillary abnormalities such as capillary dilatation and microhemorrhages in several CTD, particularly SSc. It is simple, noninvasive and inexpensive, and it aids in differentiating primary from secondary RP²⁵. Nevertheless, when applied to detect occlusions of both proper palmar digital arteries of a finger, its sensitivity and specificity were only 50% and 63%, respectively¹⁰.

Laser Doppler flowmetry measures cutaneous microperfusion by determining the global amount of blood flow. It is simple and noninvasive. It does not directly delineate the finger arteries. Reproducibility is poor because the results largely depend on the orientation of the probe²³. Laser Doppler skin perfusion pressure was lower in patients with secondary RP due to SSc compared to patients with primary RP and controls²⁶.

Thermography is also an indirect method that measures the skin surface temperature with heat and cold challenge. It has value to confirm diagnosis of RP, but does not provide information about single hand- and finger arteries²⁷. As it is looking at different properties, it may serve as a complementary technique.

Finger artery blood pressure can be measured with the aid of cw-Doppler US. Reliable exclusion of digital arterial occlusions is not possible²⁸.

Our study shows that color Doppler US of finger arteries is feasible with widely available technology in rheumatologic practice to differentiate between primary and secondary RP. Further, color Doppler US aids to distinguish severe from less severe disease and acute from chronic vascular occlusion. It depicts the same anatomical structures as

angiography, but it is cheaper, faster, and noninvasive. Further studies could compare color Doppler US findings in larger cohorts with distinct diseases causing secondary RP. In addition, studies could compare color Doppler ultrasound with other imaging techniques.

REFERENCES

1. Youssef PP, Englert H, Bertouch JV. Large vessel occlusive disease in CREST and scleroderma. *Ann Rheum Dis* 1993;27:403-6.
2. Schmidt WA. The role of color and power Doppler sonography in rheumatology. *Nat Clin Pract Rheumatol* 2007;3:35-42.
3. Bruyn GAW, Schmidt WA. Introductory guide to musculoskeletal ultrasound for the rheumatologist. Houten NL: Bohn Stafleu van Loghum; 2006.
4. Bilge O, Pinar Y, Özer A, Gövsa F. A morphometric study on the superficial palmar arch of the hand. *Surg Radiol Anat* 2006;28:343-50.
5. Fazan VP, Borges CT, Da Silva JH, Caetano AG, Filho OA. Superficial palmar arch: an arterial diameter study. *J Anat* 2004;204:307-11.
6. Connell DA, Koulouris G, Thorn DA, Potter HG. Contrast-enhanced MR angiography of the hand. *Radiographics* 2002;22:583-99.
7. Leslie BM, Ruby LK, Madell SJ, Wittenstein F. Digital artery diameters: an anatomic and clinical study. *J Hand Surg Am* 1987;12:740-3.
8. Schmidt WA, Wernicke D, Kiefer E, Gromnica-Ihle E. Colour duplex sonography of finger arteries in vasculitis and in systemic sclerosis. *Ann Rheum Dis* 2006;65:265-7.
9. Taylor MH, McFadden JA, Bolster MB, Silver RM. Ulnar artery involvement in systemic sclerosis (scleroderma). *J Rheumatol* 2002;29:102-6.
10. Peller JS, Gabor GT, Porter JM, Bennett RM. Angiographic findings in mixed connective tissue disease. Correlation with fingernail capillary photomicroscopy and digital photoplethysmography findings. *Arthritis Rheum* 1985;28:768-74.
11. Stafford L, Englert H, Gover J, Bertouch J. Distribution of macrovascular disease in scleroderma. *Ann Rheum Dis* 1998;57:476-9.
12. Pokrovski AV, Kuntsevich GI, Dan VN, et al. Diagnosis of occlusive lesions of upper extremity arteries in patients with thromboangiitis obliterans. *Angiol Sosud Khir* 2003;9:86-94.
13. Schmidt WA, Kraft HE, Vorpahl K, Völker L, Gromnica-Ihle EJ. Color duplex ultrasonography in the diagnosis of temporal arteritis. *N Engl J Med* 1997;337:1336-42.
14. Trager S, Pignataro M, Anderson J, Kleinert JM. Color flow Doppler: imaging the upper extremity. *J Hand Surg Am* 1993;18:621-5.
15. Singh S, de Trafford JC, Goss DE, Baskerville PA, Roberts VC. Ultrasound imaging of digital arteries. *Clin Phys Physiol Meas* 1990;11:313-7.
16. Chikui T, Izumi M, Eguchi K, Kawabe Y, Nakamura T. Doppler spectral waveform analysis of arteries of the hand in patients with RP as compared with healthy subjects. *AJR Am J Roentgenol* 1999;172:1605-9.
17. Keberle M, Tony HP, Jahns R, Hau M, Haerten R, Jenett M. Assessment of microvascular changes in Raynaud's phenomenon and connective tissue disease using colour doppler ultrasound. *Rheumatology Oxford* 2000;39:1206-13.
18. Langholz J, Ladleif M, Blank B, Heidrich H, Behrendt C. Colour coded duplex sonography in ischemic finger artery disease — a comparison with hand arteriography. *Vasa* 1997;26:85-90.
19. Lee CH, Han SK, Dhong ES, Kim HP, Kim WK. The fate of microanastomosed digital arteries after successful replantation. *Plast Reconstr Surg* 2005;116:805-10.
20. Winterer JT, Ennker J, Scheffler K, Rosendahl U, Schafer O, Wanner M, et al. Gadolinium-enhanced elliptically reordered three-dimensional MR angiography in the assessment of hand vascularization before radial artery harvest for coronary artery bypass grafting: first experience. *Invest Radiol* 2001;36:501-8.
21. Menanteau BP, Treutenaere JM, Marcus C, Ladam V, Gausserand F. Imaging of the digital arteries: digital subtraction angiography versus conventional arteriography. *Can Assoc Radiol J* 1989;40:34-7.
22. Krause U, Pabst T, Kenn W, Hahn D. High resolution contrast enhanced MR-angiography of the hand arteries: preliminary experiences. *Vasa* 2002;31:179-84.
23. Herrick AL, Clark S. Quantifying digital vascular disease in patients with primary Raynaud's phenomenon and systemic sclerosis. *Ann Rheum Dis* 1998;57:70-8.
24. Dabich L, Bookstein JJ, Zweifler A, Zarafonitis CJ. Digital arteries in patients with scleroderma. *Arch Intern Med* 1972;130:708-14.
25. Cutolo M, Pizzorni C, Sulli A. Capillaroscopy. *Best Pract Res Clin Rheumatol* 2005;19:437-52.
26. Kanetaka T, Komiyama T, Onozuka A, Miyata T, Shigematsu H. Laser Doppler skin perfusion pressure in the assessment of Raynaud's phenomenon. *Eur J Endovasc Surg* 2004;27:414-6.
27. Cherkas LF, Carter L, Spector TD, Howell KJ, Black CM, MacGregor AJ. Use of thermographic criteria to identify Raynaud's phenomenon in a population setting. *J Rheumatol* 2003;30:720-2.
28. Heidrich H, Blank B. Does the measurement of digital arterial pressure using the Doppler ultrasonic technique without testing for vasospasm to detect digital arterial occlusions make good sense? *Vasa* 1998;27:158-62.