

Correspondence



INSTRUCTIONS FOR LETTERS TO THE EDITOR

Editorial comment in the form of a Letter to the Editor is invited. The length of a letter should not exceed 800 words, with a maximum of 10 references and no more than 2 figures or tables; and no subdivision for an abstract, methods, or results. Letters should have no more than 4 authors. Financial associations or other possible conflicts of interest should be disclosed.

Letters should be submitted via our online submission system, available at the Manuscript Central website: <http://mc.manuscriptcentral.com/jrheum> For additional information, contact the Managing Editor, The Journal of Rheumatology, E-mail: jrheum@jrheum.com

Duration of Treatment After Eye Involvement in Giant Cell Arteritis

To the Editor:

We read with great interest the letter by Arashvand, *et al* in a recent issue¹. These authors investigated whether the presence of eye involvement significantly lengthens the duration of steroid therapy in giant cell arteritis (GCA). The mean duration of treatment in 16 patients with permanent eye involvement (25.69 ± 12.8 months) was significantly longer than in 14 patients without eye involvement (11.2 ± 3.25 months; $p = 0.0018$). This result prompted the authors to conclude that physicians can better estimate the length of treatment period required depending on the presence or absence of eye involvement. In an inception cohort of patients with temporal (giant cell) arteritis, we similarly investigated which of 33 characteristics, including severe eye involvement, were significantly associated with a longer duration of treatment.

From 1976 through 2007, we diagnosed and followed 334 patients with temporal arteritis (255 biopsy-proven cases). Only negative biopsy cases fulfilling at least 3 of the American College of Rheumatology criteria for GCA² and showing good, sustained response to corticosteroid treatment were regarded as true GCA³. Pretreatment clinical, laboratory, and pathological data were recorded prospectively at the time of diagnosis using in each case a specifically designed, comprehensive questionnaire⁴. All the patients but 8 were treated according to the same protocol⁴. Patients without severe ischemic symptoms received prednisone 0.7 mg/kg/day until the patient was symptom-free and the C-reactive protein concentration had fallen below 5 mg/l. The prednisone dose was then planned to be progressively tapered to 0.35 mg/kg within 4 to 6 weeks, then more slowly. Patients with ischemic symptoms or threat to their vision (transient ischemic symptoms, abnormal fundus, or abnormal ophthalmic artery flow on Doppler studies) received prednisone 1 mg/kg initially, often preceded by pulse methylprednisolone, then tapered similarly. Recovery from GCA was defined as no clinical or laboratory relapses for at least 9 months after the cessation of treatment.

In all, 148 patients achieved recovery (mean age at diagnosis 73.2 ± 7 yrs, 93 women). These patients, 12 of whom were treated 1 year or less, were followed for 95 ± 54 months. Using univariate analysis, we compared

the initial and followup characteristics of 59 patients who were treated for less than 2 years (mean 17.2 ± 4.7 mo) with those of 89 patients who were treated 2 years or more (mean 37.8 ± 15.9 mo). As depicted in Table 1, patients treated for the short period were indistinguishable from patients who required a longer period of treatment, with regard to all pretreatment characteristics except for a lower frequency of physical changes of temporal arteries ($p = 0.01$). The frequency of severe eye involvement was similar in both groups (8.5% vs 12.4%; $p = 0.45$). The initial prednisone dose was slightly higher in patients treated longer, and fewer patients in this subset received dapsone as a steroid-sparing agent ($p = 0.018$). In addition, short-treatment patients had a significantly lower mean daily dose of prednisone at 3, 6, and 12 months ($p < 0.001$), and had fewer relapses during treatment or after its cessation, than patients who required longer treatment ($p < 0.001$). The proportion of patients initially receiving pulse steroids and the mean number of serious corticosteroid side effects were distributed equally between the 2 groups. As shown in Table 2, a stepwise logistic regression model performed on selected therapeutic and outcome characteristics showed that the mean prednisone dose at 1 year and the mean number of relapses per patient were the only independent outcome predictors of longer treatment duration. Finally, the mean duration of treatment in 16 patients with severe eye involvement (28.3 ± 15.2 mo), including 15 with anterior ischemic optic neuropathy, did not differ from that of patients without this problem (29.9 ± 16.4 mo; $p = 0.57$).

Our study, performed on a large series of unselected patients with GCA treated homogeneously and followed until recovery, did not validate the assumption that eye involvement can reliably predict the length of treatment, and otherwise revealed the finding of abnormal temporal arteries on examination as the only helpful marker of difficult-to-treat GCA. Moreover, the potential role of dapsone as an effective steroid-sparing agent is presented⁵. The discrepancy between our results and those of Arashvand, *et al* can be explained by the different sizes of populations studied, different study designs and therapeutic protocols, and perhaps the patient's or physician's fear of occurrence of late fellow-eye involvement after early unilateral vision loss, emphasizing the role of prudent steroid tapering.

In a study from Spain, a strong initial systemic inflammatory response was associated with higher corticosteroid requirements and a longer duration of therapy in patients with GCA⁶. Our results do not confirm this finding. While it may be difficult to predict with accuracy the total duration of treatment of GCA on clinical and laboratory grounds, as well as the results of immunogenetic studies⁷, the slope of prednisone dose-tapering may identify at an early stage those patients who are at risk of undertaking a long period of treatment.

ERIC LIOZON, MD; GUILLAUME GONDRAN, MD; KIM LY, MD; VÉRONIQUE LOUSTAUD, MD; ELISABETH VIDAL, MD, Department of Internal Medicine, Dupuytren University Hospital, Limoges, France. Address reprint requests to Dr. E. Liozon, Service de Médecine Interne A, CHRU Dupuytren, 2 rue Martin Luther King, 87042 Limoges, France. E-mail: eric.liozon@unilim.fr

REFERENCES

1. Arashvand K, Alexander WL, Dasgupta B. Duration of treatment after eye involvement in giant cell arteritis [letter]. *J Rheumatol* 2007;34:1945.
2. Hunder GG, Bloch DA, Michel BA, et al. The American College of Rheumatology 1990 criteria for the classification of giant cell arteritis. *Arthritis Rheum* 1990;33:1122-8.
3. Duhaut P, Pinede L, Bornet H, et al. Biopsy proven and biopsy negative temporal arteritis: differences in clinical spectrum at the onset of the disease. Groupe de Recherche sur l'Arterite a Cellules Geantes. *Ann Rheum Dis* 1999;58:335-41.
4. Liozon E, Herrmann F, Ly K, et al. Risk factors for visual loss in giant cell (temporal) arteritis: a prospective study of 174 patients. *Am J Med* 2001;111:211-7.

Table 1. Baseline, therapeutic, and outcome characteristics of patients who recovered from temporal arteritis, by treatment period less or more than 2 years (univariate analysis).

Variable	Patients Treated < 2 Years (n = 59)		Patients Treated ≥ 2 Years (n = 89)	
	No. Assessed		No. Assessed	
Age, yrs	59	73.7 ± 7.7	89	72.9 ± 6.7
Male, %	59	35.6	89	38.2
Comorbid conditions, mean no./patient	56	0.88 ± 0.85	85	0.76 ± 0.75
Concurrent malignancy, %	59	10.2	89	6.7
Positive TAB, %	59	81.4	88	84
Acute onset of GCA, %	59	40.7	86	39.5
Constitutional symptoms, %	58	79.3	88	69.3
Systemic symptoms alone, %	59	13.6	89	6.7
Headaches, %	59	86.4	89	90
Occipitalgia, %	59	42.4	87	46
Scalp tenderness, %	56	50	86	52.3
Jaw claudication, %	59	27.1	89	36
ENT symptoms, mean no./patient	59	0.81 ± 1.2	88	1.1 ± 1.13
Physical changes of temporal arteries, %	59	42.4	86	64*
Upper limb artery involvement, %	59	15.3	89	18
Ischemic symptoms, %	58	27.6	89	38.2
Transient visual ischemic symptoms, %	59	20.3	89	24.7
Permanent visual loss, %	59	8.5	89	12.4
Polymyalgia rheumatica, %	59	23.7	89	32.6
ESR, mm/h	57	89.1 ± 35.1	87	92.7 ± 24
C-reactive protein, mg/l	55	97 ± 56	74	101 ± 67
Hemoglobin, g/dl	58	11.6 ± 0.17	85	11.5 ± 0.16
Platelet count, g/l	57	424 ± 142	84	435 ± 125
Positive IgG anticardiolipin antibodies, %	29	24.1	48	41.7
Liver enzyme abnormalities, %	51	43.1	71	49.3
Initial prednisone dose, mg/kg	59	0.73 ± 0.14	89	0.78 ± 0.15**
Initial use of pulse methylprednisolone, %	59	18.6	89	23.6
Mean prednisone dose at 3 mo	55	17.9 ± 4.6	78	22 ± 7.3***
6 mo	54	12.3 ± 4.3	73	16.4 ± 5 [†]
12 mo	53	5.3 ± 3.8	72	10 ± 4.7 [†]
Use of dapsone as steroid-sparing agent, %	59	32.2	89	15.7 ^{††}
Mean no. relapses per patient	59	0.41 ± 0.59	89	1.02 ± 1 [†]
Steroid-related complications, mean no./patient	57	1.14 ± 1.26	84	1.45 ± 1.43

TAB: temporal artery biopsy; ENT: ear/nose/throat; ESR: erythrocyte sedimentation rate. p values calculated using chi-square test or Mann-Whitney U test, as needed. * p = 0.01; ** p = 0.046; *** p = 0.0004; [†] p < 0.0001; ^{††} p = 0.018

Table 2. Forward stepwise logistic regression model to demonstrate which of 5 treatment and outcome characteristics were independently associated with treatment duration ≥ 2 years.

Characteristic	OR (95% CI)	p
Mean prednisone dose at 3 mo	1.016 (0.879–1.173)	0.83
6 mo	1.014 (0.835–1.231)	0.89
12 mo	1.293 (1.041–1.605)	0.02
Use of dapsone as steroid-sparing agent	0.252 (0.059–1.078)	0.06
Mean no. relapses per patient	4.916 (2.408–10.472)	< 0.001

- Liozon F, Vidal E, Barrier J. Does dapsone have a role in the treatment of temporal arteritis with regard to efficacy and toxicity? *Clin Exp Rheumatol* 1993;11:694-5.
- Hernandez-Rodriguez J, Garcia-Martinez A, Casademont F, et al. A strong initial systemic inflammatory response is associated with higher corticosteroid requirements and longer duration of therapy

in patients with giant-cell arteritis. *Arthritis Rheum* 2002;47:29-35.

- Genetic markers of disease susceptibility and severity in giant cell arteritis and polymyalgia rheumatica. *Semin Arthritis Rheum* 2003;33:38-48.

Arashvand, et al reply

To the Editor:

We thank Liozon, et al for their useful and expert opinion on our recent article¹. The mean duration of treatment in our 16 patients with permanent eye involvement was 25.69 ± 12.8 months compared to the mean duration of 28.3 ± 15.2 months in 16 patients with severe eye involvement in the Liozon cohort. The duration of treatment for our patients with permanent eye involvement is therefore no different from the corresponding cases reported by Liozon, et al. The main difference appears to be that our patients without eye involvement are treated with a much shorter duration of steroid therapy. The discrepancy between our results can be best explained by different study designs and objectives. Our patients all had temporal artery biopsy-positive giant cell arteritis (GCA), and Liozon, et al

recruited patients with both positive and negative temporal artery biopsy results. Also, Liozon, *et al* chose to analyze the result of a selected group of 148 patients with full recovery from 334 patients with temporal arteritis (less than 45% of the total). It is more interesting to know about the duration of treatment in all patients and possible correlation with eye involvement.

In addition, Liozon, *et al* concluded their result based on duration of treatment of more or less than 2 years. There is a great difference in duration of treatment in their 2 chosen groups — 17 months versus 37 months. They have a sufficient number of cases that we would suggest they look at their results after dividing their patients into more groups, e.g., duration of treatment 1 year or less, 1–2 years, 2–3 years, and more than 3 years. It is interesting that their patients with visual symptoms needed a longer duration of treatment (12.4% vs 8.5%), although this was not statistically significant.

This calculation differs fundamentally from our calculation, which was based on assessing duration of treatment individually for each of our patients. Finally, Liozon, *et al* found that higher starting dose of steroids was related to longer duration of treatment. We agree that this might be one of the reasons patients with eye involvement have longer duration of treatment — as they needed higher doses of corticosteroids — the same as the protocol of Liozon, *et al*.

There is some histopathological evidence that the presence of eye manifestations in GCA is associated with more advanced disease². Our study clinically supports this histopathological evidence, which might be more apparent in patients with positive temporal artery biopsy. A multicenter analysis with more compatible and homogenous sample size would elucidate the value of eye involvement in duration of treatment in giant cell arteritis.

KAYVAN ARASHVAND, MD, MRCP(h), MRCEd(Ophth); WILLIAM LESLIE ALEXANDER, FRCS, FRCOphth, Consultant Ophthalmic Surgeon; BHASKAR DASGUPTA, MD, FRCP, Consultant Rheumatologist, Honorary Professor, Eye Department, Rheumatology Department, Southend University Hospital NHS, Foundation Trust, Prittlewell Chase, Westcliff-on-Sea, Essex, United Kingdom, SS0 0RY. Address reprint requests to Dr. K. Arashvand, Birmingham and Midland Eye Centre, City Hospital, Dudley Road, Birmingham, United Kingdom, B18 7QH.
E-mail: k_arashvand@yahoo.com

REFERENCES

1. Arashvand K, Alexander WL, Dasgupta B. Duration of treatment after eye involvement in giant cell arteritis [letter]. *J Rheumatol* 2007;34:1945.
2. Diaz VA, DeBroff BM, Sinard J. Comparison of histopathologic features, clinical symptoms, and erythrocyte sedimentation rates in biopsy-positive temporal arteritis. *Ophthalmology* 2005;112:1293–8.



(*J Rheumatol* First Release April 15 2008)

Cutaneous Granulomas During Infliximab Therapy for Spondyloarthropathy

To the Editor:

Tumor necrosis factor- α (TNF- α) antagonists are highly effective drugs that have radically improved the functional outcomes and quality of life of many patients with inflammatory diseases. Although TNF- α antagonists

are generally well tolerated and safe, the list of reported adverse events is growing steadily. The most common adverse events are infectious diseases including potentially severe infections due to intracellular organisms; allergic reactions including urticaria, rash, and stomatitis¹; and biological autoimmune disorders. In addition, dermatological events not reported in premarketing clinical trials but seen in everyday rheumatologic and dermatology practice² include acne³, eczema^{4,5}, psoriasis^{6–8}, vasculitis⁹, bullous lesions¹⁰, ulcers, skin tumors, xerosis cutis, stasis dermatitis, and edema¹¹. We describe a case of cutaneous granuloma and pulmonary symptoms in a patient taking infliximab therapy for spondyloarthropathy (SpA), and we also review the few similar cases reported to date.

A 54-year-old woman presented at our department in 2003 for diffuse back pain of many years' duration. SpA was diagnosed based on the inflammatory pain pattern, with marked morning stiffness, inflammatory heel pain with an irregular spur on radiograph, good response to nonsteroidal antiinflammatory drug (NSAID) therapy, and history of psoriasis and psoriatic arthritis in the sister and father. B27 typing was negative.

Despite conventional treatment with NSAID and low-dose prednisone (10 mg daily), the disease was still active in August 2004, and infliximab therapy was therefore started. She was in contact with a patient with tuberculosis (TB) in 1986 but did not receive antituberculous treatment, despite a positive intradermal tuberculin test. Although a repeat intradermal tuberculin test was negative in 2004, she was given a 3-month course of anti-tuberculous medications prior to initiation of infliximab, according to national recommendations for the prophylaxis and management of tuberculosis occurring during treatment with anti-TNF- α .

The initial clinical response to infliximab (5 mg/kg) was excellent. However, pruritic, round erythematous-squamous lesions ranging in size from 1 to 5 mm developed over the arms, legs, and face 7 months after initiation of infliximab and persisted over the following months. The clinical diagnosis made by a dermatologist was psoriasis in a patient with no history of cutaneous psoriatic lesions. Topical calcipotriol and betamethasone improved the lesions and were continued despite an incomplete effect.

Fourteen months after infliximab initiation, multiple nodular cutaneous lesions appeared on the left arm and leg. There were about 10 red-brown, round, inflammatory lesions ranging in size from 10 to 20 mm. Simultaneously, deep-vein thrombosis occurred in the left lower leg, with no detectable causal factor, and mild dyspnea with a dry cough developed. Infliximab was discontinued and 2 skin biopsies were performed 1 month apart. Both biopsies showed hypodermis and noncaseating granulomas composed of epithelioid giant cells surrounded by lymphocytic infiltrates. Findings were normal from standard laboratory tests (renal function, liver enzymes, serum calcium, and 24-h urinary protein). There was no inflammatory syndrome (C-reactive protein < 5 mg/dl and erythrocyte sedimentation rate < 20 mm/h). Tests for antinuclear antibodies (ANA) were positive at 1/1280, compared to only 1/320 on previous occasions. The level of ANA decreased after clinical recovery and it reached the previous level, 1/320. There were no abnormalities in DNA or complement levels. Standard bacteriological studies and cultures for mycobacteria (*M. tuberculosis* and atypical Mycobacterium) were performed on the skin biopsy material and on the pulmonary secretions, and remained negative. Computed tomography (CT) of the chest showed a mild interstitial syndrome in both lung bases with ground-glass attenuation and a pseudonodular infiltrate in the left base, as well as a subcarinal lymph node measuring 23 mm in diameter. However, the respiratory symptoms resolved rapidly, prompting a decision to postpone further evaluation by bronchoscopy or lung biopsy. Clinical and CT followup was scheduled.

The skin granulomas resolved shortly after the pulmonary symptoms, 5 months after discontinuation of infliximab. Repeat CT scan showed regression of the bibasal interstitial syndrome and absence of lymphadenopathy. However, an SpA flare developed. After a multidisciplinary discussion, etanercept was started 7 months after discontinuation of infliximab. A marked clinical response was obtained within a few weeks. The inflamma-

tory back pain was well controlled 12 months later, and no additional symptoms developed.

We have described a case of noninfectious granulomatous disease with skin lesions and mild pulmonary involvement during infliximab therapy for SpA. This event was preceded by the development of psoriatic lesions during the treatment.

Noninfectious granulomatous disease in patients undergoing TNF- α antagonist therapy is rarely reported. Skin granulomas were described in 4 publications¹²⁻¹⁵ and rheumatoid nodulosis in 3¹⁶⁻¹⁸. The first case of cutaneous granuloma formation and pulmonary involvement was published in 2002¹³. A 50-year-old woman with rheumatoid arthritis (RA) started experiencing a cough and dyspnea 2 months after initiation of etanercept. The symptoms worsened over the ensuing months. Examination showed scattered nonpruritic skin lesions on the plantar surfaces of both feet and at the site of superficial scars located on the extremities. Transbronchial and acute skin lesion biopsies showed noncaseating granulomas containing birefringent particles. Etanercept discontinuation and prednisone treatment was followed by a rapid improvement. Development of cutaneous sarcoidosis was reported in 2006 in a 79-year-old patient after 21 months of etanercept therapy for ankylosing spondylitis (AS)¹⁵. Red-brown lesions ranging in size from 1 to 1.5 cm developed over the forehead, right eyebrow, and nasolabial area. The skin biopsy showed sarcoidal noncaseating granuloma extending through the entire thickness of the dermis. Bilateral hilar and paratracheal lymphadenopathies were found, further supporting a diagnosis of sarcoidosis. A rapid improvement was obtained after discontinuation of etanercept. Also in 2006, 4 cases of interstitial granulomatous dermatitis associated with TNF- α antagonist therapy were described¹². The patients were 2 women and 2 men aged 34 to 65 years (mean 50.2 yrs). Three patients had RA and one had psoriatic arthritis. The drug used was infliximab in 2 patients, etanercept in 1, and adalimumab in 1 patient. The lesions were pruritic or nonpruritic annular nodules, papules, or plaques with elevated borders on the trunk and extremities. Skin biopsies showed diffuse interstitial granulomatous infiltrates. Withdrawal of the medications led to complete resolution of the skin lesions in 3 patients. The lesions persisted in the remaining patient, who continued to take etanercept for severe RA. In 2007, the case was reported of a 39-year-old man who had development of cutaneous granulomatous lesions on the blue pigment area of an old tattoo¹⁴. He had been taking etanercept for 1 month for AS. The skin biopsy showed a noncaseating granuloma in the dermis. Topical glucocorticoid therapy with continued etanercept therapy ensured resolution of the lesions. In summary, 7 cases of cutaneous granulomatosis developing during TNF- α antagonist therapy have been reported, 4 in men and 3 in women. The medications were etanercept in 4 cases, infliximab in 2, and adalimumab in 1 case. Patients were aged 39 to 79 years (mean 52.7 yrs). The reason for treatment was RA in 4 patients, AS in 2, and psoriatic arthritis in 1.

Another intriguing feature of our case was the development of 2 rare cutaneous events during infliximab therapy, namely, psoriasis and granulomatosis. We found no similar reports in the literature. A causal link between dermatological or pulmonary disease and exposure to a medication has always been difficult to prove. In our patient, the onset of the skin lesions after initiation of infliximab and their resolution after discontinuation support a causal association with the medication.

Our patient developed granulomatous skin lesions and pulmonary involvement, similarly to a previous case¹¹, although in our patient the pulmonary involvement was mild and bronchoscopy was unnecessary. Withdrawal of infliximab was followed by complete resolution of the symptoms and, interestingly, the introduction of another TNF- α antagonist, etanercept, did not trigger a recurrence.

A few cases of pulmonary granuloma developing during TNF- α antagonist therapy have been reported. They were described as allergic pulmonary granulomatous¹⁹ or pulmonary sarcoidosis^{20,21} on infliximab; necrotizing pulmonary nodules with vasculitis¹⁶ or pulmonary granulomatous reaction^{22,23} on etanercept; and lung necrotizing granulomas²⁴ on adalimumab. Three cases of pulmonary rheumatoid nodulosis²⁵ have been

reported in patients taking etanercept. The manifestations resolved after discontinuation of TNF- α antagonist combined, in some cases, with glucocorticoid therapy. In the patient with necrotizing pulmonary nodules and vasculitis¹⁶, azathioprine treatment was necessary.

In addition to these cases of granulomatous disease apparently induced by TNF- α antagonist, several instances of granulomatous disease resolving during TNF- α antagonist therapy have been reported²⁶. A number of case reports and small case series described successful treatment of refractory sarcoidosis with infliximab²⁷⁻²⁹. Preliminary evidence from a randomized controlled trial of infliximab in pulmonary sarcoidosis suggested a modest improvement in functional and radiological manifestations²⁹. Sarcoidosis improved during etanercept therapy in several patients^{30,31}, although the overall results were somewhat disappointing, perhaps reflecting differences in the mechanism of TNF- α blockade compared to infliximab³². Studies of the pathogenesis of tuberculosis support a critical role for TNF- α in immunity and granuloma formation. Further, the 2 forms of TNF- α , soluble and transmembrane, are not equivalent, since mice expressing only transmembrane TNF- α initiated cell migration and granuloma formation, which was effective in controlling acute tuberculosis, but subsequently died from chronic tuberculosis³³. Patients treated with anti-TNF- α antibodies (e.g., infliximab), which block both soluble TNF- α and transmembrane TNF- α , might be at greater risk of reactivation of tuberculosis than patients treated with the soluble receptor (etanercept), which blocks soluble TNF- α but binds weakly to transmembrane TNF- α ³⁴. Further, binding avidities, clearances, and routes of administration vary across TNF- α antagonists, potentially explaining some of the differences in granuloma formation³⁵. Infliximab and adalimumab have somewhat different mechanisms of action than etanercept, being associated with antibody-mediated cell lysis, in contrast to etanercept. Etanercept, but not infliximab, binds lymphotoxin- α and may therefore be more effective in preventing granuloma formation by this mechanism than infliximab. Finally, adalimumab and infliximab seem to inhibit interferon- γ expression (probably indirectly), whereas etanercept does not³⁵. However, these data fail to explain the mechanism by which TNF- α antagonists may induce the development of noninfectious granulomas.

In conclusion, noninfectious granulomatous reaction may be a rare side effect of TNF- α antagonists, with the lung being the most common site of involvement, followed by the skin. Most of the reported cases seem related to etanercept, although our patient had no evidence of granulomatosis one year after switching from infliximab to etanercept. The pathophysiological role of TNF- α and TNF- α antagonists in granuloma formation is unclear. Paradoxically, TNF- α antagonists may be able to induce granuloma formation in some patients and to suppress granulomatous diseases in others.

ANDRA ECONOMU DUBOSC, MD, Department of Rheumatology; ANNE-MARIE PERROUD, MD; MARTINE BAGOT, MD, PhD, Department of Dermatology; VALÉRIE FARENQ, MD; XAVIER CHEVALIER, MD, PhD, Department of Rheumatology; BERNARD MAITRE, MD, PhD, Department of Pneumology; PASCAL CLAUDE-PIERRE, MD, Department of Rheumatology, Hôpital Henri-Mondor, APHP, Créteil, France. Address reprint requests to Prof. P. Claudepierre, Service de Rhumatologie, Hôpital Henri Mondor, 51 Avenue du Maréchal de Lattre de Tassigny, 94010 Créteil cedex, France.

REFERENCES

1. Maini R, St. Clair EW, Breedveld F, et al. Infliximab (chimeric anti-tumour necrosis factor alpha monoclonal antibody) versus placebo in rheumatoid arthritis patients receiving concomitant methotrexate: a randomised phase III trial. ATTRACT Study Group. *Lancet* 1999;354:1932-9.
2. Lee HH, Song IH, Friedrich M, et al. Cutaneous side-effects in patients with rheumatic diseases during application of tumour necrosis factor-alpha antagonists. *Br J Dermatol* 2007;156:486-91.
3. Bassi E, Poli F, Charachon A, Claudepierre P, Revuz J. Infliximab-induced acne: report of two cases. *Br J Dermatol* 2007;156:402-3.

4. Seneschal J, Lepreux S, Bouyssou-Gauthier ML, et al. Psoriasiform drug eruptions under anti-TNF treatment of arthritis are not true psoriasis. *Acta Derm Venereol* 2007;87:77-80.
5. Wright R. Atopic dermatitis-like eruption precipitated by infliximab. *J Am Acad Dermatol* 2003;49:160-1.
6. Cohen JD, Bournerias I, Buffard V, et al. Psoriasis induced by tumor necrosis factor-alpha antagonist therapy: a case series. *J Rheumatol* 2007;34:380-5.
7. Dereure O, Guillot B, Jorgensen C, Cohen JD, Combes B, Guilhou JJ. Psoriatic lesions induced by antitumor necrosis factor- α treatment: two cases. *Br J Dermatol* 2004;150:506-8.
8. Kary S, Worm M, Audring H, et al. New onset or exacerbation of psoriatic skin lesions in patients with definite rheumatoid arthritis receiving tumour necrosis factor alpha antagonists. *Ann Rheum Dis* 2006;65:405-7.
9. Saint Marcoux B, De Bandt M. Vasculitides induced by TNF antagonists: a study in 39 patients in France. *Joint Bone Spine* 2006;73:710-3.
10. Kent PD, Davis JM 3rd, Davis MD, Matteson EL. Bullous skin lesions following infliximab infusion in a patient with rheumatoid arthritis [letter]. *Arthritis Rheum* 2002;46:2257-8; Maini RN, Charles P. Reply: 2259.
11. Flendrie M, Vissers WH, Creemers MC, de Jong EM, van de Kerkhof PC, van Riel PL. Dermatological conditions during TNF- α -blocking therapy in patients with rheumatoid arthritis: a prospective study. *Arthritis Res Ther* 2005;7:R666-76.
12. Deng A, Harvey V, Sina B, et al. Interstitial granulomatous dermatitis associated with the use of tumor necrosis factor alpha inhibitors. *Arch Dermatol* 2006;142:198-202.
13. Peno-Green L, Lluberas G, Kingsley T, Brantley S. Lung injury linked to etanercept therapy. *Chest* 2002;122:1858-60.
14. Bachmeyer C, Blum L, Petitjean B, Kemiche F, Pertuiset E. Granulomatous tattoo reaction in a patient treated with etanercept. *J Eur Acad Dermatol Venereol* 2007;21:550-2.
15. Gonzalez-Lopez MA, Blanco R, Gonzalez-Vela MC, Fernandez-Llaca H, Rodriguez-Valverde V. Development of sarcoidosis during etanercept therapy. *Arthritis Rheum* 2006;55:817-20.
16. Cunnane G, Warnock M, Fye KH, Daikh DI. Accelerated nodulosis and vasculitis following etanercept therapy for rheumatoid arthritis. *Arthritis Rheum* 2002;47:445-9.
17. Kekow J, Welte T, Kellner U, Pap T. Development of rheumatoid nodules during anti-tumor necrosis factor alpha therapy with etanercept. *Arthritis Rheum* 2002;46:843-4.
18. Mackley CL, Ostrov BE, Ioffreda MD. Accelerated cutaneous nodulosis during infliximab therapy in a patient with rheumatoid arthritis. *J Clin Rheumatol* 2004;10:336-8.
19. Braun J, Brandt J, Listing J, et al. Treatment of active ankylosing spondylitis with infliximab: a randomised controlled multicentre trial. *Lancet* 2002;359:1187-93.
20. O'Shea FD, Marras TK, Inman RD. Pulmonary sarcoidosis developing during infliximab therapy. *Arthritis Rheum* 2006;55:978-81.
21. Almodovar R, Izquierdo M, Zarco P, Javier Quiros F, Mazzucchelli R, Steen B. Pulmonary sarcoidosis in a patient with ankylosing spondylitis treated with infliximab. *Clin Exp Rheumatol* 2007;25:99-101.
22. Yousem SA, Dacic S. Pulmonary lymphohistiocytic reactions temporally related to etanercept therapy. *Mod Pathol* 2005; 18:651-5.
23. Phillips K, Weinblatt M. Granulomatous lung disease occurring during etanercept treatment. *Arthritis Rheum* 2005;53:618-20.
24. Vavricka SR, Wettstein T, Speich R, Gaspert A, Bachli EB. Pulmonary granulomas after tumour necrosis factor alpha antagonist therapy. *Thorax* 2003;58:278-9.
25. Hubscher O, Re R, Iotti R. Pulmonary rheumatoid nodules in an etanercept-treated patient. *Arthritis Rheum* 2003;48:2077-8.
26. Denys BG, Bogaerts Y, Coenegrachts KL, De Vriese AS. Steroid-resistant sarcoidosis: is antagonism of TNF-alpha the answer? *Clin Sci Lond* 2007;112:281-9.
27. Roberts SD, Wilkes DS, Burgett RA, Knox KS. Refractory sarcoidosis responding to infliximab. *Chest* 2003;124:2028-31.
28. Ulbricht KU, Stoll M, Bierwirth J, Witte T, Schmidt RE. Successful tumor necrosis factor alpha blockade treatment in therapy-resistant sarcoidosis. *Arthritis Rheum* 2003;48:3542-3.
29. Baughman RP, Drent M, Kavuru M, et al. Infliximab therapy in patients with chronic sarcoidosis and pulmonary involvement. *Am J Respir Crit Care Med* 2006;174:795-802.
30. Khanna D, Liebling MR, Louie JS. Etanercept ameliorates sarcoidosis arthritis and skin disease. *J Rheumatol* 2003;30:1864-7.
31. Tuchinda C, Wong HK. Etanercept for chronic progressive cutaneous sarcoidosis. *J Drugs Dermatol* 2006;5:538-40.
32. Utz JP, Limper AH, Kalra S, et al. Etanercept for the treatment of stage II and III progressive pulmonary sarcoidosis. *Chest* 2003;124:177-85.
33. Saunders BM, Tran S, Ruuls S, Sedgwick JD, Briscoe H, Britton WJ. Transmembrane TNF is sufficient to initiate cell migration and granuloma formation and provide acute, but not long-term, control of Mycobacterium tuberculosis infection. *J Immunol* 2005;174:4852-9.
34. Ehlers S. Role of tumour necrosis factor (TNF) in host defence against tuberculosis: implications for immunotherapies targeting TNF. *Ann Rheum Dis* 2003;62 Suppl 2:ii37-42.
35. Furst DE, Wallis R, Broder M, Beenhouwer DO. Tumor necrosis factor antagonists: different kinetics and/or mechanisms of action may explain differences in the risk for developing granulomatous infection. *Semin Arthritis Rheum* 2006;36:159-67.

Multiple Autoimmune Diseases in a Young Woman: Tuberculosis and Splenectomy as Possible Triggering Factors? Another Example of the "Mosaic" of Autoimmunity

To the Editor:

The concept of the mosaic of autoimmunity was introduced¹ to describe the existence of multiple autoimmune diseases, among other characteristics, in the same individual. It is also well documented that the same clinical example of disturbed autoimmunity may be seen in various family members, e.g., familial antiphospholipid syndrome (APS). By rearranging components of the autoimmune system diverse patterns of autoimmunity become evident², and the integration of many genetic, hormonal, and environmental factors (e.g., infections) is expressed as overlapping autoimmune diseases. The amelioration of one disease may result in the appearance of another autoimmune disorder, such as women with myasthenia gravis undergoing thymectomy who have an increased risk of developing systemic lupus erythematosus (SLE) or APS³. Another example is of patients undergoing splenectomy for idiopathic thrombocytopenic purpura (ITP) who then have developed autoimmune hepatitis (AIH)⁴. Coexistent hematological disorders such as thrombotic thrombocytopenic purpura (TTP) as well as other autoimmune diseases have been described not only with SLE, but also with AIH⁵. We describe a patient with a long history of vitiligo and ITP who was found to have tuberculosis (TB) of the spleen on histological examination of a surgically removed spleen, and who then developed several other autoimmune diseases including thyroiditis and myasthenia gravis, indeed, a unique series of events in a single patient.

A 34-year-old African woman, who had had vitiligo since childhood, was first diagnosed with ITP at the age of 20 years. She was relatively asymptomatic and never experienced significant bleeding except for occasional mild episodes of epistaxes. She was maintained continuously with steroids at varying doses for over 10 years.

She presented to a neurologist at the age of 31 years in 2005 with prox-

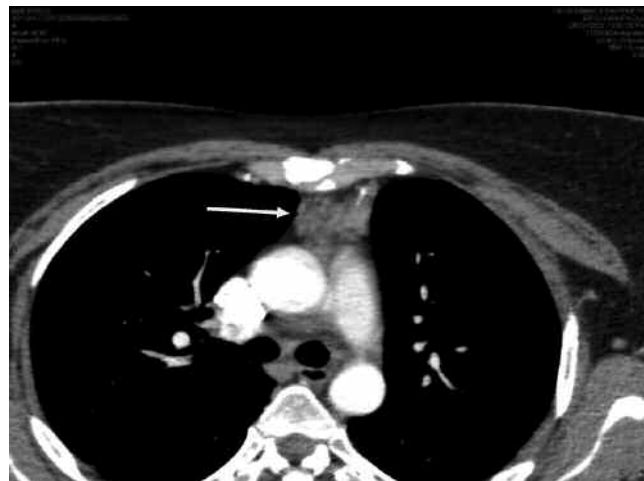imal weakness of both upper and lower limbs. An electromyogram (EMG) showed evidence of active denervation with fibrillation potentials and positive potentials. Motor unit morphology revealed low amplitude, short duration, and polyphasic potentials indicative of a myopathic process. The compound muscle action potential (CMAP) was normal with no associated abnormalities of the electrodecremental response.

In view of the clinical history, the combination of findings was attributed to steroid-induced myopathy and not to myositis. No muscle biopsy had been performed. As she had also developed non-insulin-dependent diabetes mellitus as a complication of the steroid therapy, a decision was made to taper her from steroids and perform a splenectomy. Following the splenectomy, she showed normalization of the platelet counts. Despite a normal chest radiograph and the absence of any specific symptoms of tuberculous infection, splenic histology revealed several tuberculoid granulomata in the splenic parenchyma. It was considered likely that miliary tuberculosis had arisen because of the prolonged steroid usage. She therefore began a 6-month course of anti-TB therapy.

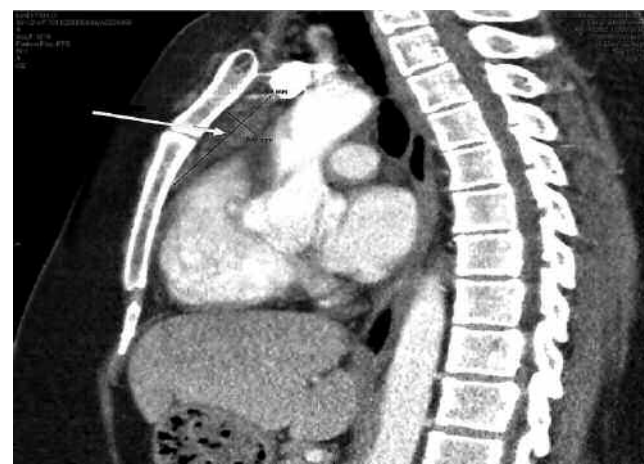
She remained well post-surgery until 1 year later, when her platelet count again decreased to approximately $34 \times 10^9/l$ and she developed severe menorrhagia. At this stage, she had developed an associated iron deficiency anemia (hemoglobin 9.9 g/dl). She was initially treated symptomatically with iron supplementation for the iron deficiency and epsilon-aminocaproic acid for the bleeding. However, the platelet count continued to fall, with increasing bleeding, particularly from the gums and oral mucosa, which necessitated a blood transfusion and eventually resulted in admission to hospital 3 months later. At this stage her full blood count confirmed a persistent severe thrombocytopenia ($31 \times 10^9/l$) and moderate anemia (Hb 10.2 g/dl). Red cell fragmentation (schistocytes) was seen on the peripheral smear and the level of lactic acid dehydrogenase (LDH) was elevated (282 U/l, normal 96–200 U/l) in keeping with a microangiopathic hemolytic anemia. TTP was diagnosed. She was also in acute renal failure (urea 29 mmol/l, creatinine 690 mmol/l).

Soon after admission, she experienced rapid onset of increasing difficulty breathing. A spiral computerized tomography scan confirmed the presence of multiple pulmonary emboli. She was dialyzed and ventilated and underwent plasma exchange, and responded rapidly, with normalization of the platelet counts and LDH levels and resolution of symptoms within 1 week. An HIV test and autoimmune screen (including antinuclear factor, anti-dsDNA antibodies, and extractable nuclear antigens) were all negative as was a screen for a lupus anticoagulant test and all antiphospholipid antibodies. These were retested on 2 further occasions and were persistently negative. She was extubated after 1 week and discharged. She remained in complete remission, was asymptomatic with normal peripheral counts, off all therapy except for warfarin, which was continued in view of the history of pulmonary emboli.

However, she returned several months later with a history of increasing muscle weakness. Thyroid anti-microsomal antibodies (234.6 IU/ml; normal 0.16–5.61) indicative of Hashimoto's thyroiditis were highly positive, while thyroid function was normal. She was also noted to have an elevated erythrocyte sedimentation rate (ESR) of 60 mm/h during this admission. She had been unable to walk, climb stairs, and sit on high chairs and also had difficulty swallowing, chewing, and focusing (diplopia) for several months. On examination, she had extensive vitiligo affecting her face, upper limbs, and chest. (Apparently there had been no change in the vitiligo since it initially appeared.) She demonstrated proximal muscle weakness. Her ESR was now elevated to 70 mm/h, platelet counts were elevated to $462 \times 10^9/l$, rheumatoid factors were positive at 246.90 IU/ml. The antinuclear antibodies were negative but serum immunoglobulins were abnormal (260 IU/ml, normal 74–182) with elevation of the gammaglobulin fraction to 20 g/l (normal 6–15). Antibodies to the acetylcholine receptor were highly elevated at 13.40 nmol/l (normal 0.00–0.02). HLA studies revealed a haplotype of A2, B8, DR10. The EMG was normal. A diagnosis of myasthenia gravis was made and 5 days of intravenous immunoglobulin therapy administered (Polygam) in a dose of 28 g/day. Chest radiograph followed by computed tomography scanning (Figures 1A, 1B) revealed the



A



B

Figure 1. A. Axial CT slice through upper superior mediastinum showing mediastinal mass. B. Midline sagittal slice through chest, again showing thymic mass.

presence of a thymoma measuring 23×22 mm, and she underwent thymectomy. Histology showed hyperplasia of the thymus gland. She is now receiving pyridostigmine (Mestinon) therapy and is doing well.

An attempt to “subset” multiple autoimmune syndromes into Types 1–3 was first proposed by Humbert and Dupond in 1988⁶; patients falling into this classification had 3 or more autoimmune diseases. The documentation of our patient clearly shows that this classification is not absolute. Some patients indeed may have autoimmune diseases from several groups. Somers, *et al*⁷ documented disease clusters differing from the Humbert classification, and Anaya, *et al*⁸ have also focused admirably on this problem in a recent review. They reviewed multiple autoimmune diseases in the same individual, polyglandular autoimmune syndrome type 11 (Schmidt's syndrome), as well as familial autoimmune diseases.

It has also been documented in case reports that treatment of one autoimmune disease may result in the emergence of yet another disease such as SLE or an APS^{9–11}. In our patient, splenectomy for treatment of the ITP was associated with the emergence of myasthenia gravis as well as Hashimoto's thyroiditis. The term “kaleidoscope” of autoimmunity has recently been used to describe the shift of one autoimmune disease to another, and that more than one autoimmune disease may coexist in a single patient or in the same family^{8–10}.

Vitiligo is a benign cosmetic condition characterized by depigmentation with the loss of melanocytes from the cutaneous epidermis and the demonstration of circulating antibodies and T lymphocytes, which react against melanocyte antigens¹². It is well known to associate with a diverse number of autoimmune diseases such as autoimmune thyroiditis, insulin-dependent diabetes mellitus, Sjögren's syndrome, primary biliary cirrhosis, ulcerative colitis, autoimmune polyglandular syndromes, and autoimmune gastritis¹³⁻¹⁸, characterized by anti-intrinsic and anti-parietal cell antibodies as well as myasthenia gravis, demonstrated in our patient¹⁹⁻²¹.

An increase in vitiligo has also been reported in patients with SLE by Nath, *et al*²², who first reported a susceptibility gene, SLEV1, on chromosome 17p13 in families with vitiligo-related SLE, and their findings have now been confirmed in the report by Jin, *et al* showing that this same gene characterizes patients with vitiligo and multiple autoimmune diseases, implicating the innate immune system in the pathogenesis of these disorders²³. Yet a question is raised in this particular patient whether environmental factors may be associated with a change in the risk for development of these diseases.

Autoimmune thyroid disease (AITD) occurs in 5%–10% of patients with myasthenia gravis^{24,25}, and the topic of thyroid autoimmunity with other autoimmune disorders has recently been well reviewed by Szyper-Kravitz, *et al*²⁶. It also seems as if AITD is found in excess in patients with SLE and secondary Sjögren's syndrome, as well in SLE-unaffected relatives with a diagnosis of primary Sjögren's syndrome²⁷.

Our patient developed TB following prolonged corticosteroid usage, and the association of TB with autoimmunity has been previously postulated. The adjuvant effect of mycobacteria for the development of autoimmunity is also well described, raising the possibility of an infective "trigger" mechanism for the evolution of myasthenia gravis in our patient. We have previously alluded to the induction of diverse autoantibodies following TB infections²⁸⁻³⁶.

Our case represents another intriguing example of multiple autoimmune diseases occurring in the same patient. However, the haplotype of A2, B8, DR10 did not correspond with the usual one seen in patients with a predisposition to develop autoimmune diseases, i.e., HLA-A1, B8, DR3, which confers a 10× increased risk for the development of these conditions. This has, however, not been confirmed in non-Caucasian populations. Our patient also presented a combination of disturbed humorally-mediated autoimmunity (ITP, autoimmune hemolytic anemia, and myasthenia gravis) as well as cellular-mediated autoimmune disease (vitiligo, Hashimoto's thyroiditis).

We have previously reported a case of a middle aged, B8/DR3-positive patient who, in addition to having a mild complement deficiency, had then inhaled a chemical (poly-anethol sulfonic acid, a compound with polyclonal B cell-activating properties) and who, following this exposure, developed 5 different autoimmune diseases³⁷. That case, as well as the patient we describe here, supports our theory of the "mosaic of autoimmunity"^{1,2,38-40}. This concept supports the hypothesis that not only may a variety of autoimmune diseases be seen in the same family, but that patients with one autoimmune disease have a greater tendency to develop yet another autoimmune disease(s). These patients apparently have a genetic predisposition to develop such diseases, and this may be augmented by hormones (e.g., sex hormones, prolactin) and immune deficiencies, as well as multiple and varied environmental factors.

RONALD A. ASHERSON, MD, FRCP, FACP, FCP, FACR, Professor of Immunology (Hon), Division of Immunology, School of Pathology, University of the Witwatersrand, Consultant Rheumatologist, The Netcare Rosebank Hospital; KARIN GUNTER, MB, ChB, MMed, Consultant Haematologist, Floracliffe, Mayo Clinic; DHARMESH DAYA, MB, BCh, FC Rad (SA), Consultant Radiologist, The Netcare Rosebank Hospital, Johannesburg, South Africa; YEHUDA SHOENFELD, MD, FRCP (Hon), Head, Department of Medicine B, Center for Autoimmune Diseases (affiliated to Tel-Aviv University), Sheba Medical Center, Tel-Hashomer, Israel.

Address reprint requests to Prof. R.A. Asherson, Netcare Rosebank Hospital, 14 Sturdee Avenue, Rosebank, Johannesburg, South Africa 2196. E-mail:ashron@icon.co.za

REFERENCES

1. Brickman CM, Shoenfeld Y. The mosaic of autoimmunity. *Scand J Clin Lab Invest* 2001;61:3-15.
2. Amital H, Gershwin E, Shoenfeld Y. Reshaping the mosaic of autoimmunity. *Semin Arthritis Rheum* 2006;35:341-3.
3. Mevorach D, Perrot S, Buchanan NM, et al. Appearance of systemic lupus erythematosus after thymectomy; four case reports and review of the literature. *Lupus* 1995;4:33-7.
4. Levene NA, Varon D, Shtalrid M, Berrebi A. Chronic active hepatitis following splenectomy for autoimmune thrombocytopenia. *Isr J Med Sci* 1991;27:199-201.
5. Yamaike N, Saigo K, Imoto S, et al. Autoimmune hepatitis accompanied by idiopathic thrombocytopenic purpura and Sjogren's syndrome. *Intern Med* 2002;41:72.
6. Humbert P, Dupond JL. Multiple autoimmune syndromes. *Ann Med Interne (Paris)* 1988;139:159-68.
7. Somers EC, Thomas SI, Smeeth L, Hall AJ. Autoimmune diseases co-occurring within individuals and within families: a systematic review. *Epidemiology* 2006;17:202-17.
8. Anaya J-M, Corena R, Castiblanco J, Rojas-Villarago A, Shoenfeld Y. The kaleidoscope of autoimmunity: multiple autoimmune syndromes and familial autoimmunity. *Future Drugs* 2007; (in press).
9. Weiss P, Shoenfeld Y. Shifts in autoimmune disease; the kaleidoscope of autoimmunity. *Isr J Med Sci* 1991;27:216-7.
10. Shoenfeld Y. The kaleidoscope of autoimmunity. *Autoimmunity* 1993;15:245-51.
11. Shoenfeld Y, Lorber M, Yucel T, Yazici H. Primary antiphospholipid syndrome emerging after thymectomy for myasthenia gravis: additional evidence for the kaleidoscope of autoimmunity. *Lupus* 1997;6:474-6.
12. Fishman P, Merlinsky O, Baharav E, Shoenfeld Y. Autoantibodies to tyrosine — the bridge between melanoma and vitiligo. *Cancer* 1997;79:1461-4.
13. Kemp EH, Waterman A, Weetman AP. Autoimmune aspects of vitiligo. *Autoimmunity* 2001;34:65-77.
14. Hegedus L, Heidenheim M, Gervil M, Hjalgrim H, Holer-Madsen M. High frequency of thyroid dysfunction in patients with vitiligo. *Acta Derm Venereol* 1994;74:120-3.
15. Dervis E, Acbay O, Barut G, Karaoglu A, Ersoy L. Association of vitiligo, morphea and Hashimoto's thyroiditis. *Int J Dermatol* 2004;43:236-7.
16. Montes LF, Pfister R, Elizalde F, Wilborn W. Association of vitiligo with Sjogren's syndrome. *Acta Derm Venereol* 2003;83:293.
17. McCann P, Pramanik A. Dysphagia and unexpected myasthenia gravis associated with primary biliary cirrhosis, ulcerative colitis and vitiligo. *J Am Geriatr Soc* 2004;52:1407-8.
18. Amerio P, Tracanna M, De Remigia P, et al. Vitiligo associated with other autoimmune diseases; polyglandular autoimmune syndrome types 3B+C and 4. *Clin Exp Dermatol* 2006;31:246-9.
19. Topaktas S, Dener S, Kenis M, Dalkara T. Myasthenia gravis and vitiligo. *Muscle Nerve* 1993;16:566-7.
20. Kubota A, Komiyama A, Tanigawa A, Hasigawa O. Frequency and correlates of vitiligo in myasthenia gravis. *J Neurol* 1997;244:388-9.
21. Cruz MW, Maranhao Filho PA, Andre C, Mattos JP, Novis SA. Myasthenia gravis and vitiligo. *Muscle Nerve* 1994;17:559-60.
22. Nath SK, Kelly JA, Namjou B, et al. Evidence for a susceptibility gene, SLEV1, on chromosome 17p13 in families with vitiligo-related systemic lupus erythematosus. *Am J Hum Genet* 2001;6:1401-6.
23. Jin Y, Mailloux CM, Gowan K, et al. NALP1 in vitiligo-associated

- multiple autoimmune diseases. *N Engl J Med* 2007;356:1216–25.
24. Peacey SR, Belchetz PE. Graves' disease associated with ocular myasthenia gravis and thymic cyst. *J R Soc Med* 1993;86:297–8.
 25. Marino M, Barbasino G, Manetti L, et al. Mild clinical expression of myasthenia gravis associated with autoimmune thyroid disease — author's response. *J Clin Endocrinol Metab* 1997;82:3905–6.
 26. Szyper-Kravitz M, Marai A, Shoenfeld Y. Coexistence of thyroid autoimmunity with other autoimmune diseases: Friend or foe? Additional aspects of the mosaic of autoimmunity. *Autoimmunity* 2005;38:247–55.
 27. Scofield H, Bruner R, Gail R, Harley JB. Autoimmune thyroid disease is associated with a diagnosis of secondary Sjogren's syndrome in familial systemic lupus. *Ann Rheum Dis* 2007;66:410–3.
 28. Tishler M, Shoenfeld Y. Tuberculose et auto-immunite: ou en sommes-nous? *Annals de L'Institute Pasteur* 1996;7:133–6.
 29. Shoenfeld Y, Wilner Y, Coates AR, Rauch J, Lavie G, Pinkhas J. Infection and autoimmunity: Monoclonal anti-tuberculosis antibodies react with DNA and monoclonal anti-DNA autoantibodies bind to mycobacterial derived glycolipids. *Clin Exp Immunol* 1986;66:255–61.
 30. Sela O, El-Roeiy A, Isenberg DA, et al. A common anti-DNA antibody idiotype in sera of patients with active pulmonary tuberculosis. *Arthritis Rheum* 1987;30:50–5.
 31. Isenberg DA, Maddison P, Swana G, et al. Profile of autoantibodies in the sera of patients with tuberculosis, Klebsiella and other gram-negative infections. *Clin Exp Immunol* 1987;67:516–23.
 32. Teplizki H, Alkan M, Coates ARM, Shoenfeld Y. ELISA measurement of antibodies titer to PPD and mycobacteria derived phosphoglycolipids as an aiding tool to the diagnosis of active pulmonary tuberculosis. *Isr J Med Sci* 1987;23:1121–4.
 33. Teplizki H, Buskila D, Alkan M, Coates ARM, Baumgarten A, Shoenfeld Y. Elisa measurements of antibody titer to purified protein derivative and mycobacteria-derived phosphoglycolipids: tool for diagnosing active pulmonary tuberculosis. *Isr J Med Sci* 1988;23:1121–4.
 34. Teplizki H, Buskila D, Argov S, et al. Low serum antimycobacterial glycolipid antibody titers in the sera of patients with systemic lupus erythematosus associated with central nervous system involvement. *J Rheumatol* 1987;14:507–11.
 35. Shoenfeld Y, Isenberg DA. Mycobacteria and autoimmunity. *Immunol Today* 1988;9:178–82.
 36. Amital-Teplizki H, Avnoach I, Coates ARM, Kooperman O, Blank M, Shoenfeld Y. Binding of monoclonal anti-DNA and anti-TB glycolipid to brain tissue. *Autoimmunity* 1989;4:277–87.
 37. Rahamim-Cohen D, Shoenfeld Y. The mosaic of autoimmunity. A classical case of inhalation of a polyclonal activating factor in a genetically and hormonally susceptible patient leading to multiple autoimmune diseases. *Isr Med Assoc J* 2001;3:381–2.
 38. Shoenfeld Y, Isenberg D. The mosaic of autoimmunity. Research monographs on immunology. Vol 12. Amsterdam: Elsevier Science Publishers; 1989.
 39. Shoenfeld Y, Isenberg D. The mosaic of autoimmunity. *Immunol Today* 1989;10:123–6.
 40. Amital H, Shoenfeld Y. Autoimmunity and autoimmune diseases such as systemic lupus erythematosus. In: Lahita RG, editor. *Systemic lupus erythematosus*. 4th ed. Amsterdam: Elsevier; 2004:3–27.

Tuberculosis of the Knee Complicating Seronegative Arthritis

To the Editor:

The diagnosis of tubercular arthritis can be challenging, particularly in the presence of confounding factors such as preexisting arthritis. We describe one such case.

A 22-year-old South Asian woman presented to the Orthopaedic Service with an intermittently painful and swollen right knee. The symptoms dated from a fall 7 years previously. On examination in the Orthopaedic Clinic, blood test results and knee radiograph were normal. A synovial fluid aspirate was obtained; standard culture was negative and no acid-fast bacilli (AFB) were isolated from prolonged culture. On her entry to the UK 12 months earlier, a routine Heaf test had shown a grade 3 reaction. At screening in the local tuberculosis (TB) clinic she had denied constitutional symptoms, systemic complaints, and exposure to TB. A series of chest radiographs at 0, 3, and 9 months were normal, leading to discharge from the TB clinic.

Upon referral to the rheumatology clinic 6 months later, examination revealed an effused, painful, restricted right knee with synovitis of the right wrist and metacarpophalangeal joints. Systemic examination was normal. Radiographs of hands and feet and acute-phase indicators were normal. Autoimmune screening tests including rheumatoid factor, antinuclear antibodies, and HLA-B27 genotyping were negative. A diagnosis of seronegative arthritis was made. As pregnancy was planned, disease modifying agents were deferred; intraarticular steroid injection was administered to the right knee followed by physiotherapy, with complete remission.

Within 1 month of a successful full-term pregnancy the right knee and hand joints relapsed. Sulfasalazine was introduced, with complete symptom relief for 18 months. However, the right knee then relapsed, requiring 2 further steroid injections over 12 months. Although magnetic resonance imaging (MRI) showed extensive erosions (Figure 1), the patient chose to discontinue sulfasalazine in preparation for a second pregnancy.

During the second pregnancy the joint was persistently inflamed and painful, with an extension lag of 45°, rendering her increasingly dependent and requiring repeated hospital admissions. An attempt at aspiration was dry; however, sterile-water lavage fluid revealed AFB on microscopy, a result confirmed on polymerase chain reaction (PCR) testing. The culture grew *M. tuberculosis*. Early morning urine also grew AFB simultaneously. Chest radiograph was normal. Anti-TB therapy was commenced immediately after a cesarean delivery, initially for 6 months but extended a further 3 months in view of the degree of joint destruction.

After intensive rehabilitation, this patient now walks without aids and has achieved functional independence.

Tubercular arthritis is characteristically monoarticular¹ and most commonly affects the spine and weight-bearing joints such as the knee and hip. The mode of transmission is hematogenous from visceral foci such as the lung or kidneys². Immunosuppressed patients are at greatest risk. Arthritis and/or osteomyelitis may be the first manifestation of tubercular disease. A subclinical or quiescent extraarticular focus must be actively investigated. In our patient, AFB was isolated from urine despite normal renal excretion studies and ultrasound imaging.

Articular disease often starts as a synovitis progressing to arthritis, with demineralization, marginal erosions, and ultimate joint destruction³. While the time period from synovitis to arthritis and erosions may be long, progression to joint destruction can be rapid, particularly in weight-bearing joints. MRI is the investigation of choice to reveal both extent and severity of damage. Tissue necrosis facilitates superadded infection with secondary organisms such as *Staphylococcus aureus*, resulting in accelerated joint destruction and systemic toxicity⁴. Conversely, joint sepsis can mask tubercular arthritis.

An underlying arthropathy may predispose to tubercular infection⁵, as reported in osteonecrotic joints, due to sickle cell disease and chondrocalcinosis^{6,7}. In our case, the knee was damaged over a 4-year period by seronegative arthritis and vulnerable to tubercular infection by hematogenous transfer. Also, our patient had sustained trauma to the joint, a known predisposing factor especially in high-risk groups⁸.

Submission of synovial or lavage fluid for standard and TB culture is recommended when possible in any at-risk patient, even where previous cultures have been negative. Synovial fluid culture is positive in roughly 80% of cases. PCR analysis is faster⁹ and more specific, but less sensitive and less widely available. The gold standard for diagnosis is synovial biop-

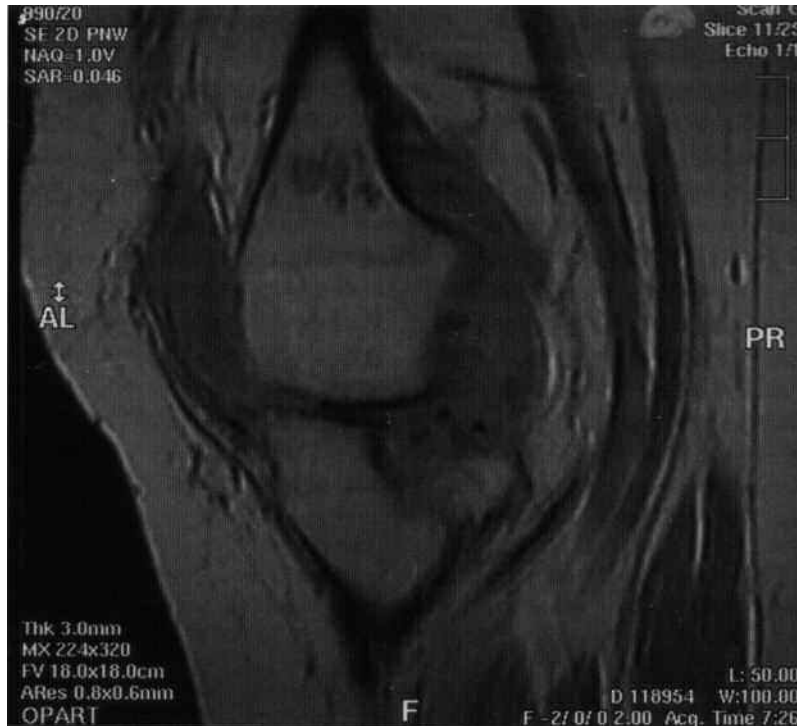

Figure 1. MRI scan of the right knee. The articular surfaces of both femur and tibia show significant cartilage loss. There is pannus formation, synovial thickening, erosions, and a minor effusion. The patellofemoral joint space is reduced. The medial and lateral menisci are severely damaged.

sy, with positive results in 90% of cases. Two consecutive pregnancies made arthroscopy impractical in our patient. The case also illustrates the value of early morning urine examination as a screening tool for tubercular disease in all clinical settings.

The cornerstone of treatment is antituberculous quadruple drug therapy for 2 months followed by dual therapy with rifampicin and isoniazid for a further 4 months¹⁰ or longer, as in our case, depending on the clinical response, particularly in bone disease¹⁻³. Early antimicrobial therapy can result in near-complete resolution and preservation of function.

The World Health Organization reports the global incidence of TB at around 8.8 million and prevalence at 14 million; of this 1%–3% is skeletal disease². A low threshold of suspicion even in the developed world, and especially in the context of immunosuppression and preexisting arthritis, is essential for early identification, appropriate treatment, and limitation of joint damage.

SUBHA ARTHANARI, MRCP(UK), Staff Grade Medical Officer; SIRAJ YUSUF, MBBS, Senior House Officer; MOHAMED NISAR, FRCP(UK), Consultant Rheumatologist, Department of Rheumatology, Queen's Hospital, Burton Hospital NHS Trust, Burton on Trent DE130RB, United Kingdom. Address reprint requests to Dr. M. Nisar. E-mail: mohamed.nisar@burtonh-tr.wmids.nhs.uk

REFERENCES

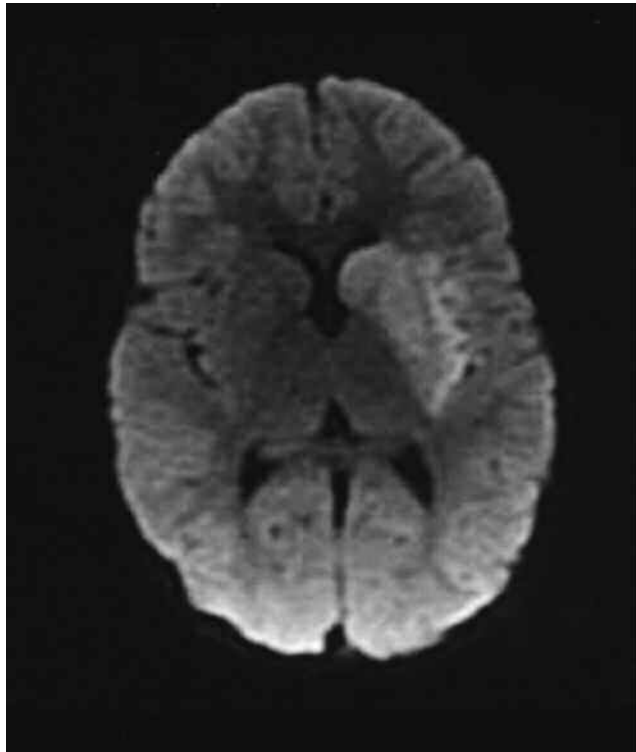
1. Sequeira W, Co H, Block JA. Osteoarticular tuberculosis: current diagnosis and treatment. *Am J Ther* 2000;7:393-8.
2. Tuli SM. General principles of osteoarticular tuberculosis. *Clin Orthop* 2002;398:11-9.
3. Furia JP, Box GG, Litner DM. Tubercular arthritis of the knee presenting as a meniscal tear. *Am J Orthop* 1996;25:138-42.
4. Al-Shaikh R, Goodman SB. Delayed onset mycobacterium tuberculosis infection with staphylococcal super-infection after total knee replacement. *Am J Orthop* 2003;32:302-5.

5. Bryan WJ, Doherty JH Jr, Sculco TP. Tuberculosis in a rheumatoid patient, a case report. *Clin Orthop* 1982;171:206-8.
6. Varango G, Bamba I, Kodo M, Dao A, Lambin Y. Osteonecrosis of the hip in sickle cell disease associated with tubercular arthritis. A review of 15 cases. *Int Orthop* 1998;22:384-9.
7. Pointud P, Prudat M, Lалуque S, Amaroux J. Tuberculous arthritis and chondrocalcinosis. Report of 2 cases. *Rev Rheum Ed Fr* 1993;60:617-20.
8. Ferris BD, Goldie B, Weir W. An unusual presentation of tuberculosis-injury TB. *Injury* 1987;18:347-9.
9. Verettas D, Kazakos C, Dermon A, Petrov H, Galanis V. Polymerase chain reaction for the detection of Mycobacterium tuberculosis in synovial fluid, tissue samples, bone marrow aspirate and peripheral blood. *Acta Orthop Belg* 2003;69:396-9.
10. Joint Tuberculosis Committee of the British Thoracic Society. Chemotherapy and management of tuberculosis in the United Kingdom: Recommendations 1998. *Thorax* 1998;53:536-48.

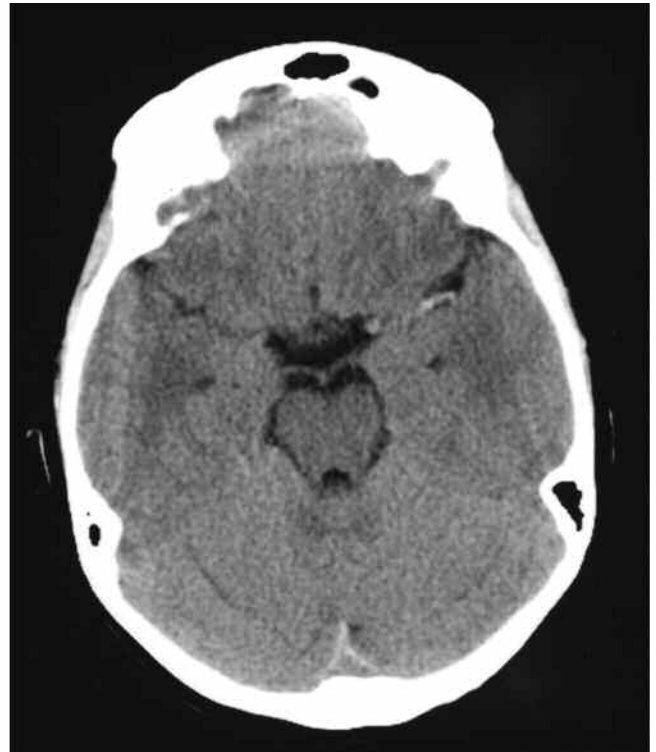Childhood Stroke as the Presentation of Takayasu's Arteritis: Diagnostic Delay Can Cause Catastrophic Complications

To the Editor:

Takayasu's arteritis (TA) is a chronic, potentially progressive, granulomatous inflammation of the aorta and its main branches and it is the most frequent pediatric large-vessel vasculitis¹. Typical manifestations of TA in adults are diminished or absent pulses associated with claudication, vascular bruits, or hypertension²⁻⁴. The incidence in children is 1/million/year. No ethnic differences are known². The diagnosis in children is based on the European League Against Rheumatism (EULAR)/PRES criteria: angiographic abnormalities plus decreased peripheral artery pulse(s) and/or clau-



A



B

Figure 1. Nonhemorrhagic infarct of the left middle cerebral artery (MCA) territory involving caudate nucleus, putamen, globus pallidus, insula, and internal capsule and white matter of the left frontal lobe (A). Occlusive thrombus in the left MCA (distance 5.5 cm) (B).

dication of extremities OR a blood pressure difference > 10 mm Hg OR bruits over aorta and/or its major branches OR hypertension⁵.

A 9.5-year-old girl presented to a hospital with a 1-month history of an orbital mass and a drooping left eyelid in April 2005. The computerized tomography (CT) scan revealed an orbital mass. The lesional biopsy revealed granulomatous inflammation with necrosis and giant cells in the arterial adventitia. The blood cell count, erythrocyte sedimentation rate (ESR), chest radiograph, and chest CT were normal. The mass minimized. In March 2006 the girl presented with right-sided facial droop, weakness, and expressive dysphasia. Magnetic resonance imaging (MRI) revealed a nonhemorrhagic infarct of the left middle cerebral artery (MCA) involving caudate nucleus, putamen, globus pallidus, insula, internal capsule, and white matter of the left frontal lobe (Figure 1A). The MRI showed abnormal flow patterns of the left common carotid artery (CCA) and the left MCA. CT angiogram demonstrated an occlusive thrombus in the left CCA (distance 5.5 cm; Figure 1B) and an irregular narrowing of the left MCA. The aortic arch was thickened. Therapy with oral prednisone, methotrexate, and low molecular weight heparin was started.

In April 2006 a right-sided weakness occurred. Four days later she developed an increased weakness of the right arm and leg. MRI revealed a new hypodensity in the left posterior parietal lobe, and volume loss in the region of the previous infarct.

In May 2006, she experienced a brief episode of vertigo, expressive dysphasia, and a right-sided weakness. The cranial MRI showed progressive gliosis in the region of the old infarct.

In June 2006 she had 4 short episodes of right facial droop, right-sided weakness, and expressive dysphasia. MRI showed no changes. Aspirin and gabapentin were added.

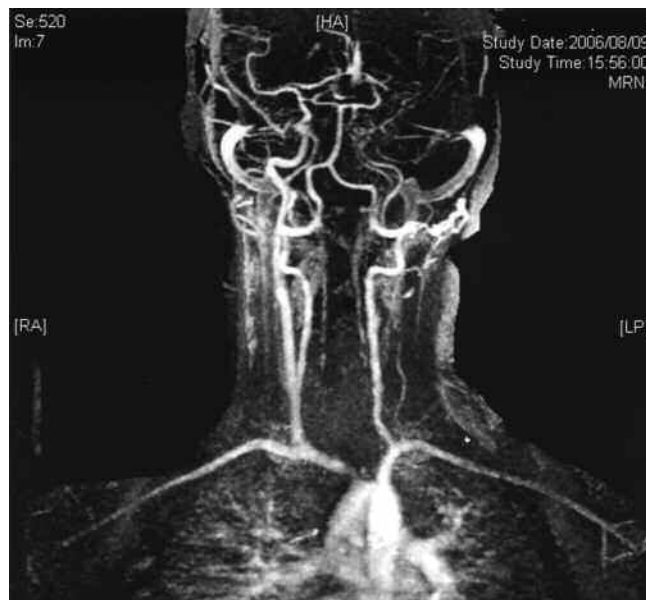In August 2006, 3 episodes of binocular diplopia and unsteadiness occurred. She had decreased pulses in her right arm but no significant drop from her arm to leg. A blood pressure difference of 10 mm Hg between the

arms was evident. There were no carotid or abdominal bruits. She had problems with repetitions and a right-sided facial weakness and hemiparesis affecting the arm more than the leg and distal more than proximal. She had a coarse tremor that was present with activity in the right arm and slightly in the right leg. Her deep tendon reflexes were more pronounced on the right side. ESR and C-reactive protein (CRP) were negative. MRI showed new infarcts in the left caudate nucleus and hypothalamus. There was an occlusion of the left CCA from its origin to just inferior to the carotid bulb. The left internal carotid artery was small but was seen filling from the bulb to the region of the ICA terminus, likely in a retrograde fashion via collaterals (Figure 2A). The chest CT revealed a filling defect in the left CCA (Figure 2B).

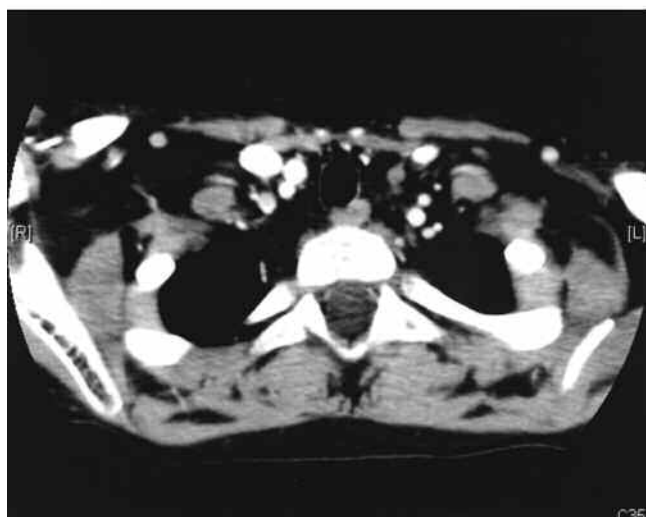
According to the EULAR/PRES criteria the diagnosis of TA was established⁵. Antiinflammatory treatment with methylprednisolone pulses for 3 days and monthly cyclophosphamide for 6 months was started. Acetylsalicylic acid and heparin were continued.

The diagnosis of childhood-onset TA was established only after a 16-month delay. TA is a treatable disease but can potentially produce disability and death². The tissue biopsy of the orbital mass in our patient revealed perivascular and adventitial inflammation, which can be present in early TA⁶.

The clinical presentation of TA in children is more heterogeneous than in adults. Pediatric patients may present with fever, dyspnea, weight loss, vomiting, and abdominal pain^{2,3,7-9}. The most common neurological manifestation in children is severe headache, although dramatic cases of stroke and seizures are also observed^{8,10-13}. When a child presents with stroke, TA or another vasculitis should be considered, if more common diagnoses such as coarctation, Marfan syndrome, or fibromuscular dysplasia and other vasculitides and tuberculosis have been excluded. Glucocorticoids remain an effective agent for patients with TA^{14,15}. If the disease is relapsing, induction with cyclophosphamide and corticosteroids followed by methotrexate



A



B

Figure 2. Occlusion of the left common carotid artery (CCA) from its origin to just inferior to the carotid bulb (A). The chest CT scan revealed a filling defect in the left CCA (B).

is an effective therapeutic option for childhood TA^{2,16,17}. Earlier treatment with a more immunosuppressive therapy might have prevented ongoing strokes. Platelet and coagulation activities are increased in TA. Therefore anticoagulation is indicated. Biologic agents represent a new therapeutic option^{2,15}.

JUERGEN BRUNNER, MD, MSc, Division of Pediatric Rheumatology/Neurology, The Hospital for Sick Children, Toronto, Ontario, Canada, and Pediatric Rheumatology, Department of Pediatrics, Medical University of Innsbruck, Innsbruck, Austria; DEREK ARMSTRONG, MD, Professor, Diagnostic and Interventional Paediatric Neuroradiology, Department of Diagnostic Imaging, Hospital for Sick Children; BRIAN M. FELDMAN, MD, Professor, Health Policy Management and Evaluation, and Public Health Sciences, University of

Toronto, Division of Pediatric Rheumatology, Hospital for Sick Children; RAYFEL SCHNEIDER, MD, Professor; SUSE BENSELER, MD, Division of Pediatric Rheumatology/Neurology, Hospital for Sick Children. Address reprint requests to Dr. J. Brunner, Pediatric Rheumatology, Department of Pediatrics, Medical University of Innsbruck, Anichstrasse 35, 6020 Innsbruck, Austria. E-mail: juergen.brunner@uki.at

REFERENCES

1. Dedeoglu F, Sundel RP. Vasculitis in children. *Pediatr Clin North Am* 2005;52:547-75.
2. Kerr GS, Hallahan CW, Giordano J, et al. Takayasu arteritis. *Ann Intern Med* 1994;120:919-29.
3. Johnston SL, Lock RJ, Gompels MM. Takayasu arteritis: a review. *J Clin Pathol* 2002;55:481-6.
4. Arend WP, Michel BA, Bloch DA, et al. The American College of Rheumatology 1990 criteria for the classification of Takayasu arteritis. *Arthritis Rheum* 1990;33:1129-34.
5. Ozen S, Ruperto N, Dillon MJ, et al. EULAR/PreS endorsed consensus criteria for the classification of childhood vasculitides. *Ann Rheum Dis* 2006;65:936-41.
6. Gravanis MB. Giant cell arteritis and Takayasu aortitis: morphologic, pathogenetic and etiologic factors. *Int J Cardiol* 2000;75 Suppl 1:21-33, discussion 35-6.
7. Hahn D, Thomson PD, Kala U, Beale PG, Levin SE. A review of Takayasu's arteritis in children in Gauteng, South Africa. *Pediatr Nephrol* 1998;12:668-75.
8. Morales E, Pineda C, Martinez-Lavin M. Takayasu's arteritis in children. *J Rheumatol* 1991;18:1081-4.
9. Ozen S, Bakkaloglu A, Dusunsel R, et al. Childhood vasculitides in Turkey: a nationwide survey. *Clin Rheumatol* 2007;26:196-200.
10. Hong CY, Yun YS, Choi JY, et al. Takayasu arteritis in Korean children: clinical report of seventy cases. *Heart Vessels Suppl* 1992;7:91-6.
11. Jain S, Kumari S, Ganguly NK, Sharma BK. Current status of Takayasu arteritis in India. *Int J Cardiol* 1996;54 Suppl:111-6.
12. Muranjan MN, Bavdekar SB, More V, Deshmukh H, Tripathi M, Vaswani R. Study of Takayasu's arteritis in children: clinical profile and management. *J Postgrad Med* 2000;46:3-8.
13. Benseler SM, Silverman E, Aviv RI, et al. Primary central nervous system vasculitis in children. *Arthritis Rheum* 2006;54:1291-7.
14. Hall S, Barr W, Lie JT, Stanson AW, Kazmier FJ, Hunder GG. Takayasu arteritis. A study of 32 North American patients. *Medicine (Baltimore)* 1985;64:89-99.
15. Hoffman GS. Takayasu arteritis: lessons from the American National Institutes of Health experience. *Int J Cardiol* 1996;54 Suppl:99-102.
16. Sikaroodi H, Motamedi M, Kahnooji H, Gholamrezanezhad A, Yousefi N. Stroke as the first manifestation of Takayasu arteritis. *Acta Neurol Belg* 2007;107:18-21.
17. Ozen S, Duzova A, Bakkaloglu A, et al. Takayasu arteritis in children: preliminary experience with cyclophosphamide induction and corticosteroids followed by methotrexate. *J Pediatr* 2007;150:72-6.

Longlasting Remissions After Treatment with Rituximab for Autoimmune Myositis

To the Editor:

In autoimmune myositis, inflammatory involvement of skin and muscles is often refractory to conventional immunosuppressive therapy, and no standardized guidelines exist for the management of progressive and debilitating disease. We describe complete remission of dermatomyositis (DM) after B cell depletion therapy for more than 4 years.

In July 2002, a 54-year-old male patient was admitted to our depart-

ment with a 6-month history of dermatitis on the face, hands, elbows, and ankles, with Gottron's papules. On examination, marked symmetrical and proximal reduction in muscle strength was evident. Electrophysiologic examination revealed pathologic spontaneous activity of all examined muscle groups; magnetic resonance imaging of both upper legs confirmed severe myositis. Positron-emission tomography showed no evidence of a focal hypermetabolic process; however, significant metabolic activity of proximal arms, shoulders, and neck muscles was consistent with active myositis (Figure 1).

Autoantibody analysis on HEp-2 cells revealed a positive antinuclear antibody (ANA) titer of 1:5120 with a homogeneous, fine-speckled pattern. ELISA revealed positive antibodies against 20S proteasomes, while other myositis related autoantibodies were negative. Consistent with the muscle damage, concentrations of creatinine kinase (1545 U/l, normal range 0–80), myoglobin (1158 µg/l, normal range 0–70), lactate dehydrogenase (505 U/l, normal range 0–240), and transaminases were elevated.

Muscle biopsy from the upper leg revealed focal muscle cell necrosis surrounded by lymphocytes and macrophages, as well as predominantly perivascular infiltrates characteristic for DM.

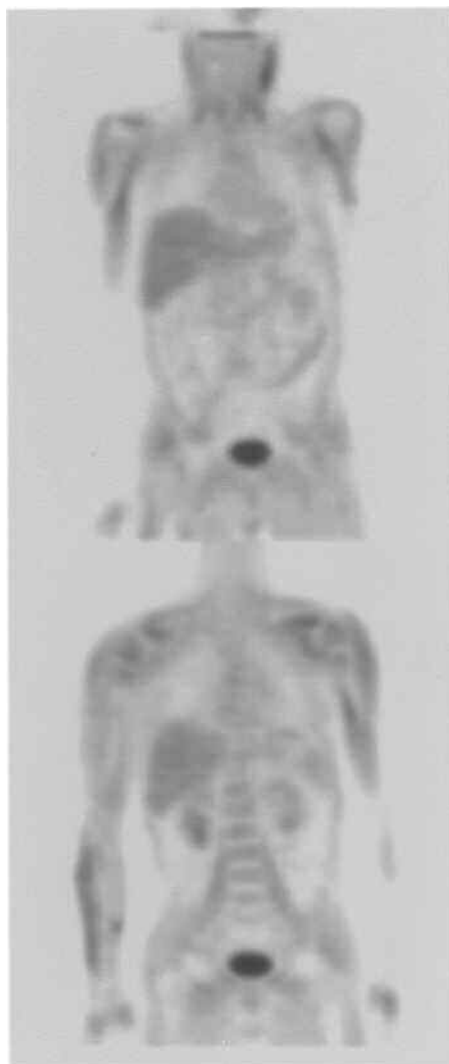


Figure 1. Positron-emission tomography revealed strong enhancement of glucose metabolism in the musculature of proximal arms, shoulders, and neck, confirming active myositis. No detection of a focal hypermetabolic process.

The clinical and laboratory findings were consistent with severe DM, therefore immunosuppressive treatment was started with high-dose corticosteroids (initially 500 mg methylprednisolone with tapered doses) in combination with intravenous (IV) cyclophosphamide (7×1000 mg monthly). However, after an initial improvement of all clinical symptoms, recurrent flares of disease were accompanied by progressive muscle weakness and persistently elevated muscle enzymes [creatinine phosphokinase (CPK) repeatedly > 1500 U/l]. After inadequate effect of a last bolus of cyclophosphamide plus a second course of methylprednisolone 500 mg IV in February 2003, the patient was considered as nonresponding to conventional treatment options. Anti-CD20 therapy with rituximab was administered (3 courses of 1000 mg IV with standard comedications, biweekly), with approval of the local ethics committee, from April to May 2003. The symptoms and laboratory signs of disease activity responded within a few weeks, and longterm remission was achieved for more than 52 months (Figure 2). Immunosuppressive treatment was initially continued with prednisolone monotherapy (≤ 10 mg/day). In September 2004, methotrexate was added (15 mg/wk, escalation to 25 mg/wk in January 2005), leading to reduction of prednisolone to < 10 mg/day. During the observation period, no serious adverse events or infections were observed. B cell (CD19+) counts remained negative until October 2004 (3.8%, 32/ μ l), and were fully reconstituted only in February 2006 (9%, 91/ μ l). Interestingly, antiproteasome antibodies were not detectable after June 2004, and ANA titers decreased to 1:640 in November 2004. In October 2007, he presented with progressive generalized myalgias without a significant reduction in muscle strength and recurrent Gottron's papules. These symptoms were also accompanied by a slight increase in CPK levels for the first time after May 2003, and therefore disease activity of DM was considered to be increasing.

Anti-CD20 therapy with rituximab has been approved for treatment of rheumatoid arthritis (RA) refractory to tumor necrosis factor- α blockers. In addition, evidence for effectiveness of anti-CD20 treatment was provided by several off-label strategies in other autoimmune disorders including systemic vasculitides and connective tissue diseases. In this context, B cell depletion therapy was shown to be an encouraging option also in patients with polymyositis and DM as well as in juvenile DM¹⁻⁶. However, no data are available from controlled clinical trials of rituximab for treatment of autoimmune myositis.

In RA, the average duration of benefit from a single cycle of treatment with rituximab was 15 months, with a time to retreatment of 20 months⁷. However, the maximum reported duration of response was 43 months, comparable to our case. Since no clinical or serological predictors for dura-

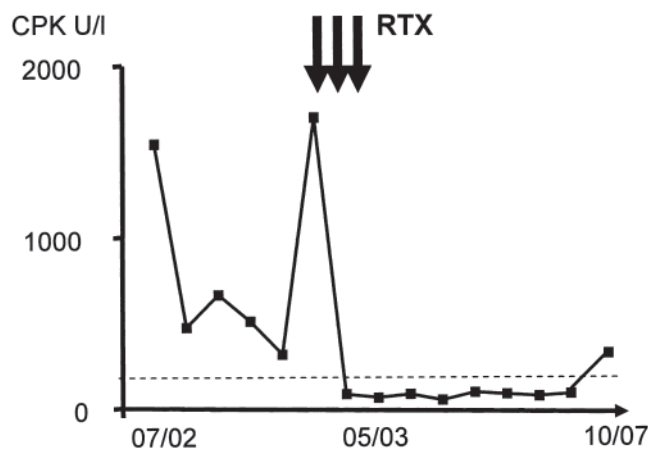


Figure 2. Normalization of CPK levels was accompanied by a complete and longlasting clinical remission over more than 4 years after administration of rituximab (RTX; cumulative dosage 3 g IV).

tion of response to rituximab are known, retreatment is dependent on a subsequent increase of disease activity, as in our patient. We found that long-lasting clinical remission of DM could be achieved after B-cell depletion and continuation of an immunosuppressive treatment, e.g., with corticosteroids in combination with methotrexate. In our patient, low B cell counts were achieved for almost 3 years, and no evidence of disease activity was seen even 1 year after reconstitution of B cells. In RA and other autoimmune disorders, it is well documented that B cell depletion lasts for a period of about 6 months, and B cell reconstitution is typically accompanied by increasing disease activity. Therefore, the unusual B cell recovery in our patient and the continuation of an immunosuppressive regime might explain the longterm remission after a single course of rituximab.

EUGEN FEIST, MD, Department of Rheumatology and Clinical Immunology; THOMAS DÖRNER, MD, Institute of Transfusion Medicine, Charité — Universitätsmedizin Berlin; HELMUT SÖRENSEN, MD, Gesundheitszentrum PrimaVita Berlin; GERD-R. BURMESTER, MD, Department of Rheumatology and Clinical Immunology, Charité — Universitätsmedizin Berlin, Berlin, Germany. Address reprint requests to Dr. E. Feist, Department of Rheumatology and Clinical Immunology, Charité — Universitätsmedizin Berlin, Charitéplatz 1, D-10117 Berlin, Germany. E-mail: eugen.feist@charite.de

REFERENCES

1. Levine TD. Rituximab in the treatment of dermatomyositis: an open-label pilot study. *Arthritis Rheum* 2005;52:601-7.
2. Noss EH, Hausner-Sypek DL, Weinblatt ME. Rituximab as therapy for refractory polymyositis and dermatomyositis. *J Rheumatol* 2006;33:1021-6.
3. Chiappetta N, Steier J, Gruber B. Rituximab in the treatment of refractory dermatomyositis. *J Clin Rheumatol* 2005;11:264-6.
4. Stringer E, Feldman BM. Advances in the treatment of juvenile dermatomyositis. *Curr Opin Rheumatol* 2006;18:503-6.
5. Ytterberg SR. Treatment of refractory polymyositis and dermatomyositis. *Curr Rheumatol Rep* 2006;8:167-73.
6. Brulhart L, Waldburger JM, Gabay C. Rituximab in the treatment of antisynthetase syndrome. *Ann Rheum Dis* 2006;65:974-5.
7. Popa C, Leandro MJ, Cambridge G, Edwards JC. Repeated B lymphocyte depletion with rituximab in rheumatoid arthritis over 7 yrs. *Rheumatology Oxford* 2007;46:626-30.

Book Review

Osteoarthritis: A Companion to Rheumatology

Leena Sharma and Francis Berenbaum, editors, Philadelphia: Mosby, Inc., 2007, 279 pages, US \$129.00.

This “Companion to Rheumatology” on osteoarthritis (OA) is a detailed, up-to-date review on the epidemiology, pathogenesis, and radiological, clinical and treatment perspectives of the disorder, written by an international cast of leaders in their fields.

The chapters on pathogenesis provide an excellent discussion on the role of changes in the subchondral bone, chondrocytes, and adipokines (especially leptins) in OA. A section on biochemical markers and discussion on predictors and measurement of disease progression are particularly relevant. The chapter on management is comprehensive and appropriately includes a section on complementary and alternative medicine that is in widespread use among patients. A section on mechanical issues in disease management with discussion on exercises, gait retraining, bracing, and footwear modifications is of particular value for treating physicians. Surgical interventions, however, received only a brief mention.

The book is comprehensive but succinctly written, easy to read, and well referenced and includes black and white but clear illustrations. The authors’ goal of providing a “source of information and ideas for those already involved in osteoarthritis investigation and patient care” has been achieved. This is an excellent text that clearly summarizes the current state of knowledge in OA and is recommended reading for all involved in the study and management of the disease.

Veerapong Phumethum, MD, Clinical Fellow in Rheumatology;
Peter Lee, MD, FRCPC, FRACP, Professor of Medicine, University of Toronto, Mount Sinai Hospital, Toronto, Canada.