

## Usefulness of Multidetector Computed Tomography to Assess Calcinosis in Systemic Sclerosis

YANNICK ALLANORE, MD, PhD; ANTOINE FEYDY, MD, PhD; GERALDINE SERRA-TOSIO, MD; ANDRE KAHAN, MD, PhD, Université Paris Descartes, Rhumatologie A et Radiologie B, Hôpital Cochin, APHP, Paris, France. Address reprint requests to Dr. Y. Allanore, INSERM U781, Necker Hospital, 149 rue de Sevres, Paris, 75015 France. E-mail: yannick.allanore@cch.aphp.fr. J Rheumatol 2008; 35:2274–5; doi:10.3899/jrheum.080325

Calcinosis is common in systemic sclerosis (SSc) and can cause disability; hand calcinosis was found to affect 23% of patients with SSc of the largest series<sup>1</sup>.

A 39-year-old man with diffuse cutaneous SSc, present for 8 years, was referred with a history of chronic hand calcinosis that had failed to respond to all therapies and was

seriously disabling. To assess distribution and tissue involvement of calcium deposits, multidetector computed tomography (CT) was performed including 2D coronal images of the wrist and hand (Figure 1A) and 3D volume-rendering images (Figure 1B: coronal view, and C: palmar view). These images showed extensive calcified deposits

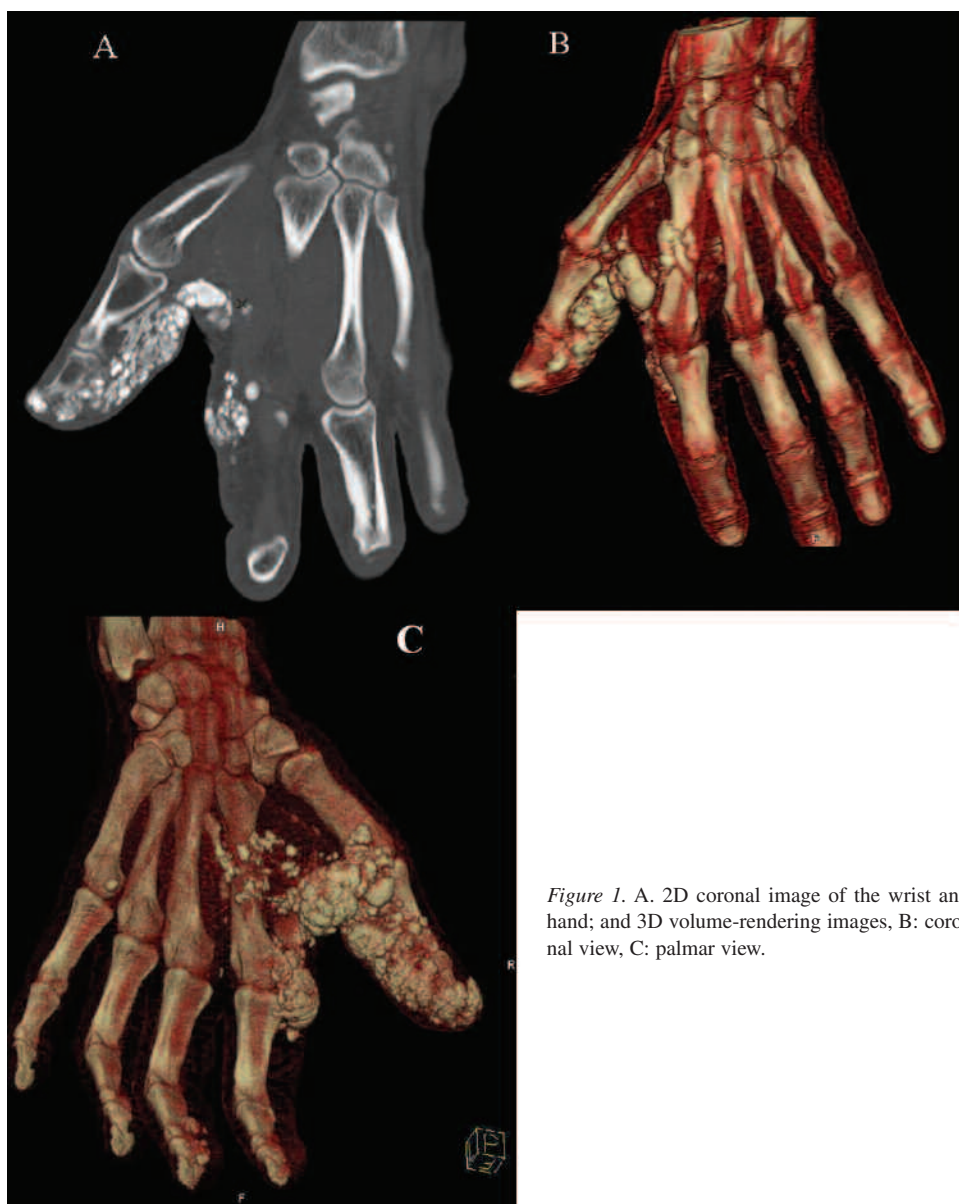


Figure 1. A. 2D coronal image of the wrist and hand; and 3D volume-rendering images, B: coronal view, C: palmar view.

involving mainly the palmar aspects of the thumb and also of the second finger. They revealed that multinodular calcifications were in very close relationship with the flexor tendons, which did not support an indication for surgical treatment.

No effective therapy for calcinosis in SSc seems to be available. Multidetector CT with multiplanar 2D and 3D

images appears to be very useful to assess this condition and very helpful regarding evaluation of the benefit/risk ratio of surgery.

## REFERENCE

1. Avouac J, Guerini H, Wipff J, et al. Radiological hand involvement in systemic sclerosis. *Ann Rheum Dis* 2006;65:1088-92.