

# Lupus Erythematosus Tumidus Induced by Sex Reassignment Surgery

GISELE ZANDMAN-GODDARD, MICHAL SOLOMON, AVIV BARZILAI, and YEHUDA SHOENFELD

**ABSTRACT.** We describe a case of sex reassignment surgery and the subsequent development of lupus erythematosus tumidus (LET). LET is characterized clinically by erythematous, succulent, edematous, nonscarring plaques in sun-exposed areas. Results of histological examination show perivascular and periadnexal lymphocytic infiltration and interstitial mucin deposition. This report emphasizes that environmental triggers, including prolonged exposure to significant doses of estrogens as part of sex reassignment surgery, may lead to the development of lupus in a nonpredisposed individual. (First Release August 1 2007; *J Rheumatol* 2007;34:1938–40)

*Key Indexing Terms:*

SEX REASSIGNMENT SURGERY ESTROGEN SYSTEMIC LUPUS ERYTHEMATOSUS  
LUPUS ERYTHEMATOSUS TUMIDUS SILICONE AUGMENTATION MAMMOPLASTY

The etiology of systemic lupus erythematosus (SLE) is multifactorial: intrinsic (genetic predisposition) and extrinsic (environmental) triggers contribute to disease progression and pathogenesis. The intrinsic abnormalities are complicated, with diverse genetic polymorphisms described in different ethnic groups, strongly suggesting that the actual pathology underlying the immunologic disarray might not be the same for each patient<sup>1</sup>. Potential causes for the female predilection for SLE include the effects of estrogen and its hydroxylation, decreased androgen levels, hyperprolactinemia, and differences in gonadotropin-releasing hormone signaling. Environmental exposures include drugs capable of modulating immune responses such as exogenous estrogens. The amount and timing of exposure to different environmental factors may play a significant and complex role in the onset of disease<sup>2</sup>.

We describe the first report of a man who underwent sex reassignment surgery and developed lupus erythematosus tumidus (LET). Sontheimer's classification<sup>3</sup> includes lupus tumidus as a specific lupus erythematosus skin disease, a form of chronic cutaneous lupus erythematosus, with urticarial plaque morphology. The clinical presentation usually involved

erythematous, edematous plaques located on the face, chest, back, or extremities, related to sun exposure. A dermal lymphocytic infiltrate with a perivascular disposition and differing degrees of mucin deposition is common.

## CASE REPORT

A 40-year-old individual who had undergone sex reassignment surgery (male to female) was referred to the Lupus Clinic. Recently, she had developed a diffuse rash on the face, chest, and back, and was diagnosed as having cutaneous lupus. During the following months, she complained of muscle weakness, symmetric joint pain involving the knees and the hands, chest pain that was exacerbated by deep inspiration, and mood swings.

The history included sex reassignment surgery and silicone augmentation mammoplasty in 2000. As preparation for the operation, she was treated with estradiol ethinylestradiol, conjugated estrogens, and cyproterone acetate/ethinylestradiol (combination antiandrogen and estrogen). Since reassignment surgery she had been taking a continuous regimen of estradiol valerate. For the recent symptoms, she received monthly intramuscular betamethasone dipropionate. She did not receive any other medications during this period.

On examination, the patient had female characteristics. Remarkable erythematous confluent papules on the presternal, shoulders, abdomen, and back, without alopecia or oral ulcers, were noted. Additionally, tenderness of the wrists and metacarpophalangeal joints of the second and third digits bilaterally without evidence of swelling was present. There was evidence of silicone implant rupture. The remainder of the examination was unremarkable.

Laboratory tests including erythrocyte sedimentation rate, complete blood count, chemistry, serology [antinuclear antibodies (ANA), anti-DNA, anti-Ro/La, anti-ribonucleoprotein, anti-smooth-muscle antibody titers, c- and p-antineutrophil cytoplasmic antibodies, cryoglobulins, C4], and urinalysis were within the normal limits. The hormonal profile [elevated follicle-stimulating hormone (FSH) and luteinizing hormone, low testosterone] was compatible with a menopausal woman or Klinefelter's syndrome (Table 1). No genetic profile was performed and she did not harbor a Klinefelter's (XXY) phenotype.

The skin biopsy revealed mild interface vacuolar changes and dense perivascular lymphocytic infiltrates in the superficial and mid-dermis (Figure 1). The alcian blue histochemical stain demonstrated deposits of mucin among the collagen fibers of the reticular dermis, diagnostic of tumid lupus (Figure 2). Therapy with hydroxychloroquine 200 mg bid was initiated, leading to improvement of the cutaneous and joint manifestations.

---

*From the Department of Medicine C, Wolfson Medical Center, Holon; Department of Dermatology, Department of Medicine B, and The Center for Autoimmune Diseases, Sheba Medical Center, Tel-Hashomer; and Sackler Faculty of Medicine, Tel Aviv University, Tel Aviv, Israel.*

*G. Zandman-Goddard, MD, Head, Department of Medicine C, Wolfson Medical Center; M. Solomon, MD; A. Barzilai, MD, Department of Dermatology, Sheba Medical Center; Y. Shoenfeld, MD, Department of Medicine B, Center for Autoimmune Diseases, Sheba Medical Center, and Sackler Faculty of Medicine, Tel Aviv University.*

*Address reprint requests to Dr. G. Zandman-Goddard, Department of Medicine C, Wolfson Medical Center, Holon, Israel 58100.*

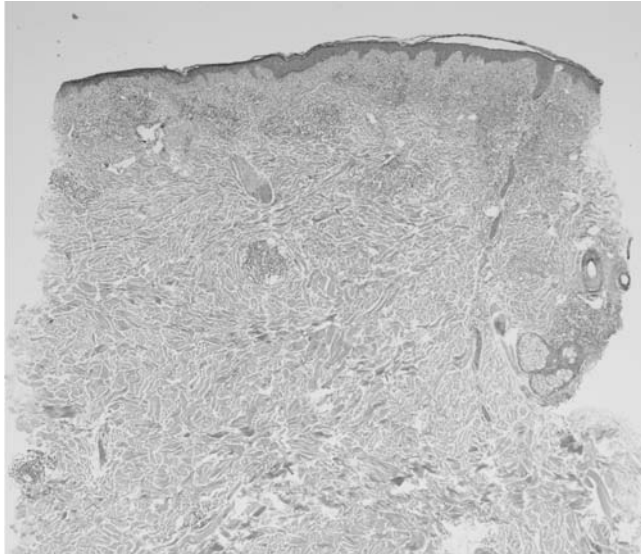
*E-mail: goddard@wolfson.health.gov.il*

*Accepted for publication April 17, 2007.*

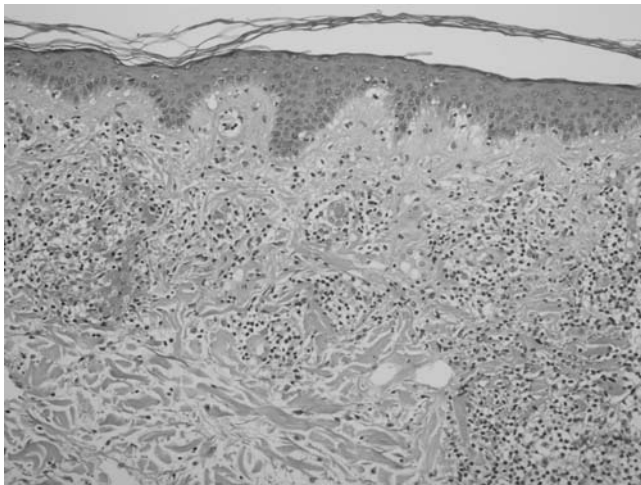
Table 1. The patient's hormonal profile.

Test	Result	Normal
LH	3.85 mIU/ml	0.6–19 mIU/ml (luteal phase); 2–12 mIU/ml (male)
FSH	573 mIU/ml	18–153 mIU/ml (postmenopausal); 2–12 mIU/ml (male)
E2	< 200	70–220 pmol/L (female); < 180 pmol/l (male)
Testosterone	0.15 nmol/l	0.21–2.98 (female); 9.36–37.1 (male)
Cortisol	474 µg/dl	5–25 mg/dl
Prolactin	139 ng/ml	1.9–25.9 ng/ml (female); 1.6–23.0 ng/ml (male)

FSH: follicle-stimulating hormone; LH: luteinizing hormone; E2: estradiol.



A



B

Figure 1. Skin biopsy results from the patient. A. Scanning magnification reveals superficial and deep perivascular and periadnexal lymphocytic infiltration (H&E, original magnification  $\times 40$ ). B. Higher magnification reveals vacuolar degeneration at the dermoepidermal junction and mucin deposits between the collagen bundles (H&E, original magnification  $\times 200$ ).

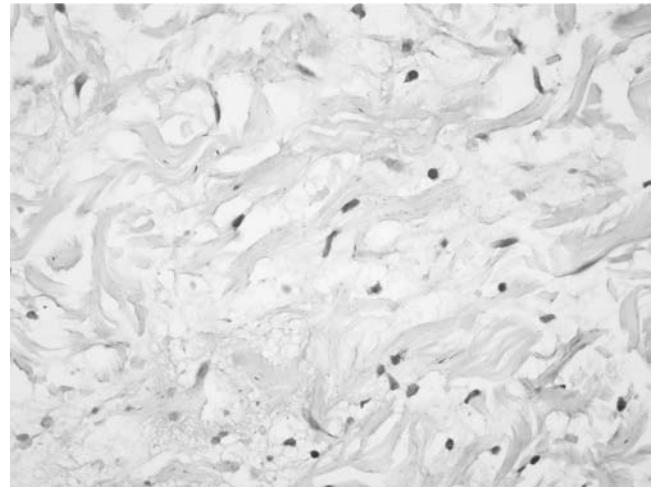


Figure 2. Alcian blue stain for mucin revealed granular fibrillary material between collagen bundles (H&E, original magnification  $\times 600$ ).

## DISCUSSION

This is the first reported case of LET in a patient following sex reassignment surgery (male to female) treated with estrogens and antiandrogens. The definite diagnosis of SLE is based on the American College of Rheumatology guidelines requiring 4 of 11 criteria<sup>4</sup>. The combination of rash (biopsy-proven tumidus LE), arthritis, and serositis is highly suspicious for SLE. However, with negative serology (ANA and anti-DNA), the diagnosis remains that of cutaneous LE or SLE-like disease.

LET is characterized clinically by erythematous, succulent, edematous, nonscarring plaques in sun-exposed areas. Results of histological examination show perivascular and periadnexal lymphocytic infiltration and interstitial mucin deposition. LET has been documented rarely in the literature, and its clinical importance has not been fully appreciated. The onset of the disease, in 40 patients followed for 14 years, clustered in summer because of sun exposure, and 70% of the patients showed a remarkable photosensitivity confirmed by results of provocative phototesting. A complete resolution of the skin lesions was seen after systemic therapy with antimalarials. In 10% of the patients, ANA were detected; however, there was no evidence of underlying systemic involvement in any of the patients<sup>5,6</sup>. A key controversial question in LET is the histologic picture. A lymphocytic perivascular and periadnexal infiltrate, dermal mucin deposition, and often negative direct immunofluorescence test are typical. Nevertheless, the possible existence of minimal epidermal and dermal-epidermal junction changes was described<sup>6</sup>.

The effect of estrogens on the immune system is significant. Not only natural hormones, but also endocrine disruptors, such as environmental estrogens, may act in conjunction with other factors to override immune tolerance to self-antigens. In the B cell compartment, both prolactin and estrogen are immunomodulators that affect maturation, selection, and antibody secretion. Their influence may be based on their capacity to allow autoreactive B cells to escape the normal

mechanisms of tolerance and to accumulate in sufficient numbers to cause clinically apparent disease. Estrogen leads to the survival and activation of autoreactive B cells, by eliciting T cell-independent autoreactive marginal-zone B cells<sup>2,7,8</sup>.

Hyper-estrogenic states can affect SLE disease activity. Ingestion of oral contraceptives high in estrogen content and hormone replacement therapy for postmenopausal women may be associated with mild disease flare<sup>9</sup>. Ovarian stimulation may lead to the induction of SLE<sup>10</sup>.

Female patients with SLE have lower plasma androgen levels than their healthy counterparts. The closest natural hormonal counterpart in a male patient would be Klinefelter's syndrome, where low androgen levels are detected and a few case reports describe concomitant SLE<sup>11</sup>.

The patient's hormonal profile at the development of lupus was equivalent to a woman during the menopausal period, with a very elevated FSH level. The low testosterone level was probably a result of castration and feminizing hormone therapy. In addition, while maintaining female hormone therapy, she had elevated levels of prolactin. Hyperprolactinemia has been reported in 20%–30% of patients with lupus. Moreover, prolactin has a direct effect on B cells enhancing autoimmunity. Importantly, cutaneous lupus developed in this case in a female hormonal milieu, one that is more optimal for B cell dysregulation<sup>12</sup>.

Anecdotal reports have appeared of individuals where autoimmune diseases developed after mammary augmentation with silicone gel-filled elastomer envelope-type prostheses. However, many large studies and metaanalyses did not provide significant statistical evidence for any correlation between the development of SLE and silicone augmentation mammoplasty. We have described an array of autoantibodies found in autoimmune diseases in individuals following silicone mammoplasty in individuals with or without symptoms<sup>13,14</sup>. Although not proven, the fact that our patient underwent silicone mammoplasty could be yet another environmental trigger in the development of SLE.

This is the first reported case of sex reassignment surgery and the subsequent development of cutaneous lupus. Although a genetic component was not sought, and SLE can appear in men, we present this first report to emphasize that environmental triggers including high doses of estrogens as part of sex reassignment surgery may lead to the development of lupus in a nonpredisposed individual.

## REFERENCES

1. Brickman CM, Shoenfeld Y. The mosaic of autoimmunity. *Scand J Clin Lab Invest Suppl* 2001;235:3-15.
2. Peeva E, Zouali M. Spotlight on the role of hormonal factors in the emergence of autoreactive B-lymphocytes. *Immunol Lett* 2005;101:123-43.
3. Sontheimer RD. The lexicon of cutaneous lupus erythematosus—a review and personal perspective on the nomenclature and classification of the cutaneous manifestations of lupus erythematosus. *Lupus* 1997;6:84-95.
4. Tan EM, Cohen AS, Fries JF, et al. The 1982 American College of Rheumatology revised criteria for the classification of systemic lupus erythematosus. *Arthritis Rheum* 1982;25:1271-7.
5. Kuhn A, Hintz D, Oslislo C, Ruzicka T, Megahed M, Lehmann P. Lupus erythematosus tumidus — a neglected subset of cutaneous lupus erythematosus: report of 40 cases. *Arch Dermatol* 2000;136:1033-41.
6. Vieira V, Del Pozo J, Yebra-Pimentel MT, Martinez W, Fonseca E. Lupus erythematosus tumidus: a series of 26 cases. *Int J Dermatol* 2006;45:512-7.
7. Grimaldi CM, Michael DJ, Diamond B. Cutting edge: expansion and activation of a population of autoreactive marginal zone B cells in a model of estrogen-induced lupus. *J Immunol* 2001;167:1886-90.
8. Grimaldi CM, Cleary J, Dagtas AS, Moussai D, Diamond B. Estrogen alters thresholds for B cell apoptosis and activation. *J Clin Invest* 2002;109:1625-33.
9. Buyon J, Petri MA, Kim MY, et al. The effect of combined estrogen and progesterone hormone replacement therapy on disease activity in systemic lupus erythematosus: a randomized trial. *Ann Intern Med* 2005;142:953-62.
10. Ben-Chetrit A, Ben-Chetrit E. Systemic lupus erythematosus induced by ovulation induction treatment. *Arthritis Rheum* 1994;37:1614-7.
11. Lahita RG, Bradlow HL. Klinefelter's syndrome: hormone metabolism in hypogonadal males with systemic lupus erythematosus. *J Rheumatol* 1987;14 Suppl:154-7.
12. Grimaldi CM, Hill L, Xu X, Peeva E, Diamond B. Hormonal manipulation of B cell development and repertoire selection. *Mol Immunol* 2005;42:811-20.
13. Bar-Meir E, Teuber SS, Lin HC, et al. Multiple autoantibodies in patients with silicone breast implants. *J Autoimmunity* 1995;8:267-77.
14. Zandman-Goddard G, Blank M, Ehrenfeld M, Gilburd B, Peter J, Shoenfeld Y. A comparison of autoantibody production in asymptomatic and symptomatic women with silicone breast implants. *J Rheumatol* 1999;26:73-7.