Dactylitis of the Thumb and the Little Finger Extending to the Carpal Tunnel

IGNAZIO OLIVIERI, MD, Consultant, Director, Rheumatology Department of Lucania, San Carlo Hospital, Potenta and Madonna delle Grazie Hospital, Matera; ENRICO SCARANO, MD, Researcher, Radiology Department, San Carlo Hospital, Potenta; ANGELA PADULA, MD, Researcher; VINCENZO GIASI, MD, Researcher, Rheumatology Department of Lucania, San Carlo Hospital, Potenta and Madonna delle Grazie Hospital, Matera, Italy. Address reprint requests to Dr. I. Olivieri, Rheumatology Department of Lucania, San Carlo Hospital, Contrada Macchia Romana, 85100 Potenza, Italy. E-mail: ignazioolivieri@tiscalinet.it

Two synovial sheaths enclose the digital flexor tendons in the canalis carpi (carpal tunnel). One envelops the flexor pollicis longus, the other the flexores digitorum superficialis and profundus. Occasionally these communicate with each other in the canal. The sheath of the flexor pollicis longus is continued along the thumb as far as the insertion of the tendon. The common sheath of the flexores digitorum tendons ends about halfway down the metacarpal bones of the index, middle, and ring fingers. It usually communicates with the digital synovial sheath of the little finger. When the common sheath of digital flexors joins the sheath of flexor pollicis longus in the carpal canal, liquid or air injected into the digital flexor sheath of the little finger spreads into the common sheath of the flexorum digitorum, thus to the sheath of the flexor pollicis longus, and to its digital sheath, as well. Similarly, an infection starting in the digital synovial sheath of the little finger may spread by this route to the thumb or vice versa. We describe a patient showing that the tenosynovial inflammation of spondyloarthritis dactylitis[1-4] may also diffuse in similar ways.

A 57-year-old man with a 3-year history of psoriatic arthritis came in for a followup visit showing "sausage-like" swelling in his right thumb and little finger. Examination disclosed dactylitis of the thumb and the little finger of his right hand, together with swelling and tenderness involving the volar aspect of his right forearm. Pain was also present when the thenar eminence and the ulnar border of the palm of the right hand were pressed. Magnetic resonance imaging disclosed fluid in the synovial sheath of the flexor pollicis longus extending without interruption from the thumb to the carpal tunnel (Figure 1A). Similarly, the fluid in the digital sheath of the flexor tendons of the lit-

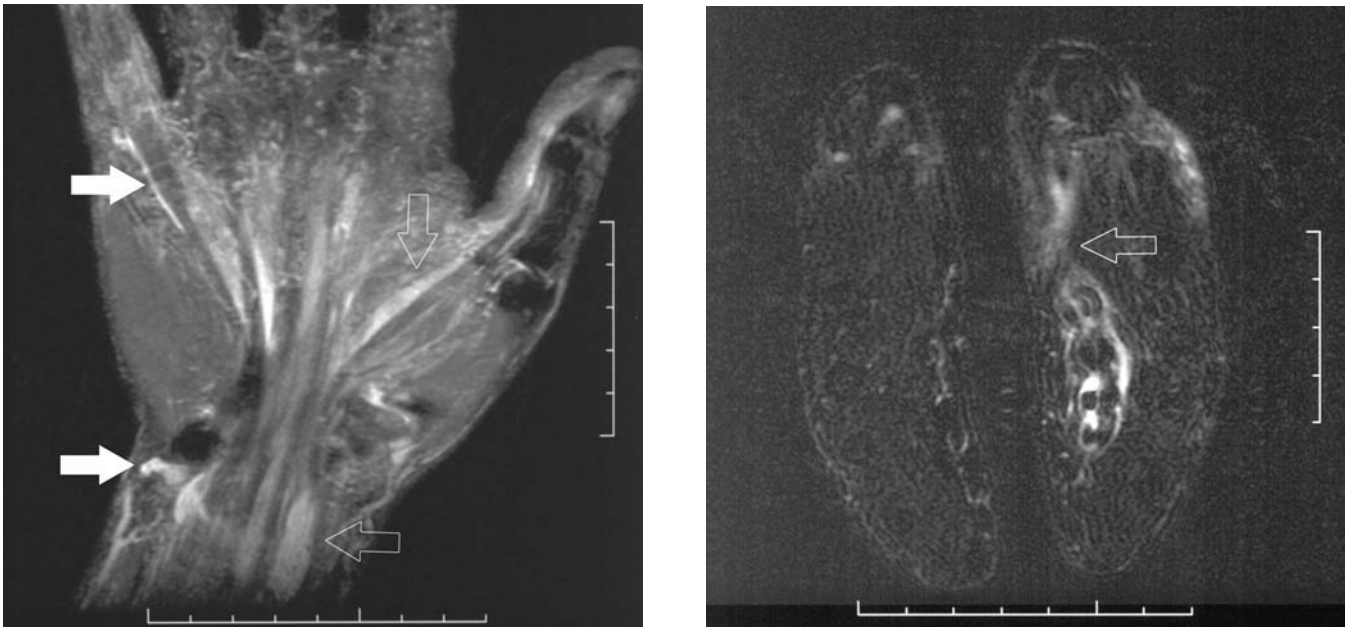

A B

Figure 1. Coronal short-tau inversion recovery T2-weighted 2-dimensional image. Sequences were reformatted with maximum intensity projection on pathological fingers. A. There is fluid in the digital synovial sheath of the flexor pollicis longus extending without interruption into the carpal tunnel (open arrows). There is also fluid in the sheath of the flexor tendons of the little finger extending without interruption into the common sheath of the flexores digitorum down to the canalis carpi (white arrows). B. Axial T2-weighted image with fat saturation showing the communication between the common sheath of the digital flexors and the sheath of the flexor pollicis longus in the carpal tunnel (arrow).

Personal non-commercial use only. The Journal of Rheumatology Copyright © 2007. All rights reserved.

Downloaded on April 24, 2024 from www.jrheum.org

tle finger continued into the common sheath of the flexores digitorum down to the carpal tunnel. A communication between the common sheath of digital flexors and the sheath of the flexor pollicis longus was also present in the carpal tunnel (Figure 1B).

Our report confirms that involvement of the common sheath of the flexores digitorum and of the sheath of the flexor pollicis longus should be looked for in patients with spondyloarthritis finger dactylitis involving the thumb and the little fingers[5]. This could be useful in directing the location for steroid injections.

REFERENCES

1. Gladman DD. Psoriatic arthritis. In: Khan MA, editor. Ankylosing spondylitis and related spondyloarthropathies. Spine: State of the art review. Philadelphia: Hanley and Belfus, Inc; 1990:637-56.
2. Olivieri I, Barozzi L, Favaro L, et al. Dactylitis in patients with seronegative spondylarthropathy: assessment by ultrasonography and magnetic resonance imaging. Arthritis Rheum 1996;39:1524-8.
3. Olivieri I, Barozzi L, Pierro A, De Matteis M, Padula A, Pavlica P. Toe dactylitis in patients with spondyloarthropathy: assessment by magnetic resonance imaging. J Rheumatol 1997;24:926-30.
4. Olivieri I, Salvarani C, Cantini F, et al. Fast spin echo (FSE)-T2-sequences with fat saturation in dactylitis of spondyloarthritis: no evidence of entheseal involvement of flexor digitorum tendons. Arthritis Rheum 2002;46:2964-7.
5. Olivieri I, Scarano E, Padula A, Giasi V. Dactylitis of the thumb extending to the radial bursa. J Rheumatol 2003;30:1626-7.

Personal non-commercial use only. The Journal of Rheumatology Copyright © 2007. All rights reserved.

Downloaded on April 24, 2024 from www.jrheum.org