



INSTRUCTIONS FOR LETTERS TO THE EDITOR

Editorial comment in the form of a Letter to the Editor is invited. The length of a letter should not exceed 800 words, with a maximum of 10 references and no more than 2 figures or tables; and no subdivision for an abstract, methods, or results. Letters should have no more than 4 authors. Financial associations or other possible conflicts of interest should be disclosed.

Letters should be submitted via our online submission system, available at the Manuscript Central website: <http://mc.manuscriptcentral.com/jrheum> For additional information, contact the Managing Editor, The Journal of Rheumatology, E-mail: jrheum@jrheum.com

Neurosarcoidosis in a Patient with Rheumatoid Arthritis During Treatment with Infliximab

To the Editor:

We describe a 41-year-old woman with erosive rheumatoid arthritis (RA) that was positive for rheumatoid factor (RF) and anti-cyclic citrullinated peptide; she was given successful treatment with infliximab combined with methotrexate (MTX), without side effects. During treatment she developed sarcoidosis, mainly involving the eyes and the central nervous system (CNS).

Case report. The patient, born in 1965, had undergone a splenectomy due to thrombocytopenia at age 16 years. At the age of 23 she was diagnosed with RA based on widespread polyarthritis, rheumatoid nodules, erosions of small joints in her feet, and RF positivity. During the following years several courses of antirheumatic treatment were given, including injectable gold, sulfasalazine, MTX, and cyclosporin A. Due to erosiveness and increased disease activity, infliximab infusions were started in March 2000 at a dosage of 3 mg/kg body weight at 6–8 week intervals together with MTX, and she responded well to this treatment. During October 2005 the patient and her husband spent 17 days in China adopting a child, during which time she remained healthy, and she received an infliximab infusion on November 18. However, during the first days of December she felt tired and had low-grade fever (38°C) and headache. At examination 2 weeks later she presented no neurological symptoms besides headache. Routine laboratory variables showed erythrocyte sedimentation rate 22 mm/h, C-reactive protein 5.3 mg/l, hemoglobin 138 g/l, white blood cell count 7.2, S-creatinine 53 μ mol/l, and a slightly increased S-ALT of 1.2 μ kat/l (reference value < 0.7 μ kat/l). She was hospitalized at the Infectious Diseases Clinic 1 week later. At admission, physical examination was unremarkable and there was no nuchal rigidity. However, cerebrospinal fluid (CSF) analysis revealed slight pleocytosis with mononuclear leukocytes of $49 \times 10^6/l$ and polynuclear leukocytes $4 \times 10^6/l$, normal CSF/blood glucose ratio, and slightly increased CSF protein concentration of 0.78 g/l. A tentative diagnosis of meningoencephalitis in an immunosuppressed patient with a recent history of travel in China prompted an extensive investigation for infectious etiology. However, all analyses for bacterial, viral, fungal, or protozoan infection were negative (Table 1), and no specific antimicrobial therapy was given. On repeat CSF analyses 1 and 3 weeks after admission,

Table 1. Microbiological analyses of CSF and/or serum with negative results.

Bacteria: Culture, 16SrDNA [polymerase chain reaction(PCR)], Lues (WR, TPPA), <i>Mycobacterium tuberculosis</i> (culture, acid-fast staining, PCR), <i>Borrelia</i> , <i>Ehrlichia</i> , <i>Brucella</i> , <i>Bartonella</i> , <i>Leptospira</i>
Virus: Culture, HSV, VZV, CMV, EBV, HHV-6, enterovirus, polyoma virus (BKV, JCV), parvovirus, HIV-1, HTLV-1 and 2, hepatitis B and C, TBE, Denguevirus, Japanese encephalitis B
Fungi: Culture, <i>Cryptococcus</i> , <i>Histoplasma capsulatum</i> , <i>Blastomyces dermatitidis</i> , <i>Coccidioides immitis</i>
Protozoa: <i>Acanthamoeba</i> , <i>Toxoplasma</i> , <i>gnathostomiasis</i> , <i>angiostrongyliasis</i>

pleocytosis and protein level remained unchanged. Neuroradiologic investigation by computed tomography of the brain, magnetic resonance imaging (MRI) of the brain and spinal cord, and MR angiography was normal, and an electroencephalogram showed no abnormalities. Chest radiograph was unremarkable, and there was no hilar lymphadenopathy. However, the headache remained unchanged and 4 weeks after admission she developed diplopia. At neuro-ophthalmological examination 1 week later nerve palsy of the left eye and a severe papilledema in both eyes were discovered. Transcranial Doppler analysis confirmed a high intracranial pressure. Further, bilateral granulomatous iridocyclitis and retinal periphlebitis, typical for sarcoidosis, were noted. The sarcoidosis diagnosis was supported by the increased activity in the mediastinal lymph nodes bilaterally and in the parotid glands observed with ^{111}In -DTPA-octreotide scintigraphy. Serum angiotensin-converting enzyme (ACE) was normal, but CSF ACE showed an increased value of 5.75 kE/l (reference value < 3.0 kE/l). High-dose (4 mg bid) betamethasone was instituted, but notably without effect on high intracranial pressure. Therefore she received a ventriculoperitoneal shunt 5 weeks after admission. Following surgery she became free of headache and the pathologic ophthalmologic changes slowly subsided. She was treated with high-dose glucocorticoids (prednisolone 1 mg/kg), and MTX was started and gradually increased to 25 mg/week (injectable). There was low activity of the arthritis symptoms during summer 2006, and ophthalmologic examination revealed no papilledema and her eye muscle function was normal. She was able to return to work full-time during autumn 2006.

Tumor necrosis factor- α (TNF- α) is a proinflammatory cytokine that together with interleukin 1 β plays a major role in the pathogenesis of both RA and sarcoidosis¹. Anti-TNF therapy is recommended for treatment of active RA that is nonresponsive to disease modifying antirheumatic drugs (DMARD) such as MTX and sulfasalazine³. TNF-blocking agents are usually given in combination with other DMARD, often MTX, but are sometimes used as monotherapy⁴.

Etanercept and infliximab have been reported to improve skin and joint involvement of sarcoidosis^{5,6}. However, the effect of anti-TNF treatment in ocular sarcoidosis has been questioned⁷. Baughman, *et al*⁸ performed a placebo-controlled trial in sarcoidosis showing that infliximab improved lung function but was not efficacious in several other outcome variables. Recently, there have been 2 reports of pulmonary sarcoidosis developing during infliximab treatment in patients with ankylosing spondylitis^{9,10}. Further, there are reports of sarcoidosis development during treatment of RA with etanercept^{11–13}. Thus the efficacy and safety of TNF antagonists in sarcoidosis remain unclear. The time course of development of sarcoidosis from start of TNF inhibitor varies from 6 months up to 5 years in these reports.

The diagnosis of RA in our patient was considered definite, with erosive polyarthritis, presence of rheumatoid nodules, and RF, thus fulfilling American College of Rheumatology classification criteria. A key question is the validity of the diagnosis of sarcoidosis. This was based on typical eye findings, i.e., granulomatous iridocyclitis (mutton-fat keratic precipitate) and retinal periphlebitis (“candle wax drippings”), positive ^{111}In -DTPA-octreotide scintigraphy, high CSF ACE level, and clinical response to therapy. Unfortunately, no histological confirmation of the diagnosis was possible.

In our experience coexistence of RA and sarcoidosis occasionally occurs and has been reported¹⁴. Prior to the institution of infliximab therapy in our patient there were no clinical or radiological (repeated chest radiographs) signs of sarcoidosis. However, it cannot be entirely excluded that sarcoidosis occurred concomitantly with RA and it is possible that infliximab, not crossing the blood-brain barrier, in fact contributed to some control of sarcoidosis outside the CNS. Another possibility is that immunomodulation caused by anti-TNF treatment facilitated, or at least did not protect from, development of sarcoidosis. This is supported by the increased uptake outside the CNS in lymph nodes and parotid glands found with the octreotide scintigraphy. Aseptic meningitis has been reported during infliximab treatment, but without signs of sarcoidosis¹⁵.

The etiology of sarcoidosis remains unknown, although some observations suggest interactions between genetic inheritance and environmental or infectious agents. Several microorganisms have been implicated as potential causes of sarcoidosis, i.e., mycobacteria, *Borrelia burgdorferi*, *Propionibacterium acnes*, and *Rickettsia helvetica*¹⁶⁻¹⁹. However, their role in the pathogenesis of sarcoidosis remains obscure, although it cannot be excluded that immunomodulating therapy such as TNF antagonists may trigger a disease related to a dormant microorganism.

Our case, together with previous reports on sarcoidosis manifestations developing during treatment with TNF antagonists for RA and spondyloarthropathies, stresses the importance of careful vigilance in monitoring patients treated with these drugs. These observations may contribute to understanding of the pathogenesis of autoimmune inflammatory diseases, especially sarcoidosis.

GUNNAR STURFELT, MD, PhD, Rheumatology Section; BERTIL CHRISTENSSON, MD, PhD, Clinical and Experimental Infection Medicine Section; GUNNEL BYNKE, MD, PhD, Ophthalmology Section; TORE SAXNE, MD, PhD, Rheumatology Section, Department of Clinical Sciences, University Hospital of Lund, 22185 Lund, Sweden. Address reprint requests to Dr. Sturfelt. E-mail: gunnar.sturfelt@reum.lu.se

REFERENCES

- Moller DR. Treatment of sarcoidosis: from a basic science point of view. *J Intern Med* 2003;253:31-40.
- Symmons DPM, Silman AJ. The world of biologics. *Lupus* 2006;15:122-6.
- Furst DE, Breedfeld FC, Kalden JR, et al. Updated consensus statement on biological agents for the treatment of rheumatic diseases. *Ann Rheum Dis* 2006;65 Suppl:iii2-15.
- White ES, Lynch JP. Pharmacological therapy for Wegener's granulomatosis. *Drugs* 2006;66:1209-28.
- Khanna D, Liebling MR, Louie JS. Etanercept ameliorates sarcoidosis arthritis and skin disease. *J Rheumatol* 2003;30:1864-7.
- Swiss NJ, Welsch MJ, Curran JJ, Ellman MH. Tumor necrosis factor inhibition as a novel treatment for refractory sarcoidosis. *Arthritis Rheum* 2005;53:788-91.
- Baughman RP, Lower EL, Bradley DA, Raymond LA, Kaufman A. Etanercept for refractory ocular sarcoidosis: results of a double-blind randomized study. *Chest* 2005;128:1062-7.
- Baughman RP, Drent M, Kavuru M, et al. Infliximab therapy in patients with chronic sarcoidosis and pulmonary involvement. *Am J Respir Crit Care Med* 2006;174:795-802.
- O'Shea FD, Marras TK, Inman RD. Pulmonary sarcoidosis developing during infliximab therapy. *Arthritis Rheum* 2006;55:978-81.
- Almodovar R, Izquierdo M, Zarco P, Javier Quiros F, Mazzucchelli R, Steen B. Pulmonary sarcoidosis in a patient with ankylosing spondylitis treated with infliximab. *Clin Exp Rheumatol* 2007;25:99-101.
- Verschuere K, Van Essche E, Verschuere P, Taelman V, Westhovens R. Development of sarcoidosis in etanercept-treated rheumatoid arthritis patients. *Clin Rheumatol* 2007 Mar 6; Epub ahead of print.
- Kudrin A, Chilvers ER, Ginawi A, et al. Sarcoid-like granulomatous disease following etanercept treatment for RA. *J Rheumatol* 2007;34:648-9.
- Gonzalez-Lopez MA, Blanco R, Gonzalez-Vela MC, Fernandez-Llaca H, Rodriguez-Valverde V. Development of sarcoidosis during etanercept therapy. *Arthritis Rheum* 2006;55:817-20.
- Fallahi S, Collins D, Miller RK, Halla JT. Coexistence of rheumatoid arthritis and sarcoidosis: difficulties encountered in the differential diagnosis of common manifestations. *J Rheumatol* 1984;11:526-9.
- Marotte H, Charrin EC, Miossec P. Infliximab-induced aseptic meningitis. *Lancet* 2001;358:1784.
- Thomas KW, Hunninghake GW. Sarcoidosis. *JAMA* 2003;289:3300-3.
- Mangiapan G, Hance A. Mycobacteria and sarcoidosis: an overview and summary of recent molecular biological data. *Sarcoidosis* 1995;12:20-37.
- Yamada T, Eishi Y, Ikeda S, et al. In situ localization of *Propionibacterium acnes* DNA in lymph nodes from sarcoidosis patients by signal amplification with catalysed reporter deposition. *J Pathol* 2002;198:541-7.
- Nilsson K, Pahlson C, Lukinius A, Eriksson L, Nilsson L, Lindquist O. Presence of *Rickettsia helvetica* in granulomatous tissue from patients with sarcoidosis. *J Infect Dis* 2002; 185:1128-38.

Idiopathic Osteonecrosis of Femur in Adult Morquio Type B Disease

To the Editor:

Morquio syndrome is one of the mucopolysaccharidoses (type IV). Glycosaminoglycans accumulate within the cells, leading to many systemic alterations and skeletal abnormalities. There is shortening of the trunk and limbs, spinal curvature, odontoid hypoplasia with cervical instability, and lower-limb alignment problems¹. We describe a young man originally diagnosed with idiopathic osteonecrosis of femur.

A male patient born in 1975 had dystonia since he was 11 years of age. It was first localized to the upper limbs, but progressively generalized, with an axial predominance, when he reached age 20 years. The dystonia caused walking difficulties, but he had no mental problems and he worked normally in a computer business. No dysmorphic features (height 1.69 m, weight 57 kg) or visceral or other neurological abnormalities were found, cerebral magnetic resonance imaging examination was normal, and the dystonia was considered idiopathic.

At age 23 years, he suddenly complained of a pain in the right hip, when walking. On the pelvic radiograph there was a typical aspect of osteonecrosis of the right femoral head with a normal left hip and absence of dysplasia on both sides (Figure 1A, 1B). Radiographs of other joints (knees, shoulders, hands, wrists, ankles, feet) were normal, and the necrosis was thought to be probably idiopathic. Comorbidities known to be associated with osteonecrosis were ruled out. Surgery was not considered, as the hip lesion did not affect his quality of life.

After 4 years of regular followup, he mentioned that a recently born niece presented a progressive psychomotor retardation, and the possibility of a genetic disorder of mucopolysaccharide metabolism was suspected. His ophthalmologic examination was normal, but spine radiographs revealed vertebral dysplasia at the cervical, dorsal, and lumbar level. There was moderate dorsal scoliosis, and at the dorsal and lumbar level platyspondyly, mild anterior tonguing, concavity of the vertebral bodies, and irregular endplates. The craniocervical junction was normal, but C5 was pear-shaped, centering a cervical kyphosis, with platyspondyly of the adjacent vertebrae (Figure 2).

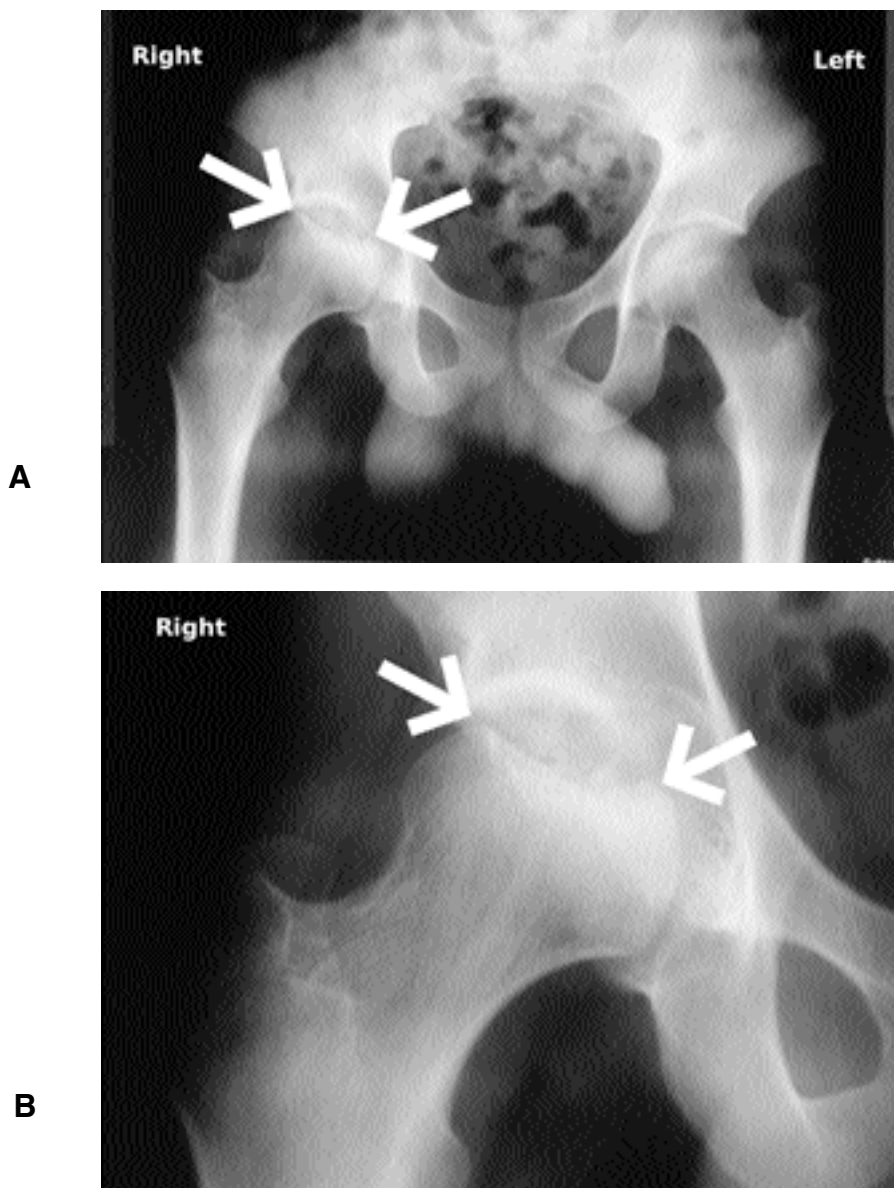


Figure 1. A. Full pelvis view showing absence of dysplasia and necrosis of the right femoral head (arrows). B. Detail of the necrosis (arrows).

Blood samples and a skin biopsy for fibroblast culture were sent to the Laboratoire de Génétique et pathologie métabolique at Hôpital Cochin, Paris (Prof. L. Poenaru, Dr. C. Caillaud), and the Laboratoire de Génétique, Hôpital Necker-Enfants malades (Dr. D. Geneviève), Paris. Screening for enzyme deficiency showed a very low level of leukocyte β -galactosidase (15 nmol/h/mg proteins) representing 7.5% of the low normal range (200–700). The skin fibroblast culture confirmed the deficient β -galactosidase activity (4 nmol/h/mg protein instead of 617 nmol/h/mg).

At age 30 years, the pain at walking had increased but was still acceptable, and the appearance of the right hip remained stable. The clinical problem was then dominated by the dystonia, which was resistant to treatment. The dystonia involved the entire body but was predominantly axial. In September 2006 a pallidal deep-brain stimulation was carried out (Prof. A.L. Benabid, Prof. P. Pollak) and after this, his walking improved significantly. A diagnosis of Morquio B was determined.

The usual form of Morquio disease is known as Morquio A^{2,3}. There is stunted growth, spondyloepiphyseal dysplasia, and frequently a cranio-

cervical junction malformation requiring a surgical fixation⁴. The β -galactosidase is normal, but α -galactose 6-sulfatase is undetectable. Morquio B disease is much rarer, and tends to be less severe. Lysosomal storage disorder is caused by β -galactosidase deficiency due to mutations in the *GLB1* gene. Three major forms have been established on the basis of age of onset and severity of symptoms: infantile, juvenile, and adult⁵. The adult form is characterized, as in our patient, by a progressive and generalized dystonia with speech and gait disturbance and slowly progressing dementia^{2,3}.

The physiopathology of femoral head osteonecrosis is still controversial. In most cases there is a conjunction of local blood flow reduction and increased fragility of bone⁶. Femoral head collapse is often seen — in Gaucher disease — due to an accumulation of Gaucher cells in bone marrow⁷. In most of the other inherited metabolic diseases there is a joint dysplasia with more or less destruction of bone extremities³, but isolated femoral head osteonecrosis is quite rare. A few cases have been reported in Fabry's disease⁸. A case of Morquio disease was diagnosed as Perthes dis-

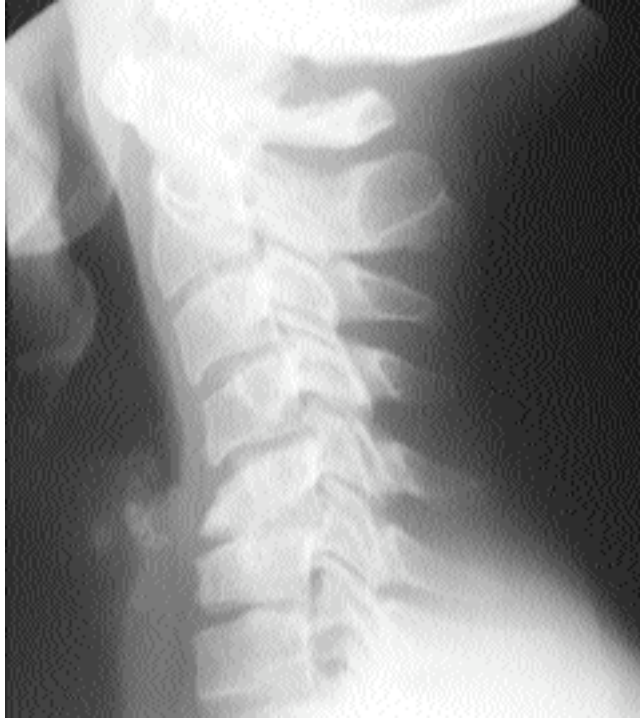

Figure 2. Cervical spine radiograph shows pear-shaped dysplasia of C5, platyspondyly, and kyphosis.

ease for 38 years⁹, and a mild form of Morquio A disease with bilateral Perthes disease was recognized only when the patient reached adulthood¹⁰.

The association of Morquio B disease with femoral head necrosis may be coincidental, although no other risk factors were found in our patient. The accumulation of undegraded substrate in lysosomes of the affected tissues, such as bone marrow, chondrocytes, and osteocytes, may induce bone fragility, with microfractures responsible for the osteonecrosis.

CHARLES J. MENKÈS, MD, Professor Emeritus; PIERRE RONDOT, MD, Université René Descartes, Paris V, Department of Rheumatology, Hospital Cochin, 95 rue de Passy, 75016 Paris, France.

Address reprint requests to Prof. Menkès. E-mail: charles.menkes@wanadoo.fr

REFERENCES

1. Montano AM, Tomatsu S, Gottesman GS, Smith M, Oril T. International Morquio A Registry: clinical manifestation and natural course of Morquio A disease. *J Inherit Metab Dis* 2007;30:165-74.
2. Muthane U, Chickabasaviah Y, Kaneski C, et al. Clinical features of adult GM1 gangliosidosis: report of three Indian patients and review of 40 cases. *Mov Disord* 2004;19:1334-41.
3. van Gemund JJ, Giesberts MA, Eerdmans RF, Blom W, Kleijer WJ. Morquio-B disease, spondyloepiphyseal dysplasia associated with acid beta-galactosidase deficiency. Report of three cases in one family. *Hum Genet* 1983;64:50-4.
4. Chirossel JP, Passagia JG, Gay E, Palombi O. Management of craniocervical junction dislocation. *Childs Nerv Syst* 2000; 16:697-701.
5. Santamaria R, Chabas A, Coll MJ, Miranda CS, Vilageliu L, Grinberg D. Twenty-one novel mutations in the GLB1 gene identified in a large group of GM1-gangliosidosis and Morquio-B patients: possible common origin for the prevalent p.R59H mutation among gypsies. *Hum Mutat* 2006;27:1060.
6. Jones LC, Hungerford DS. Osteonecrosis: etiology, diagnosis and treatment. *Curr Opin Rheumatol* 2004;16:443-9.
7. Katz K, Horev G, Grunebaum M, Yosipovitch Z. The natural history of osteonecrosis of the femoral head in children and adolescents who have Gaucher disease. *J Bone Joint Surg Am* 1996;78:14-9.
8. Lien YH, Lai LW. Bilateral femoral head and distal tibial osteonecrosis in a patient with Fabry disease. *Am J Orthop* 2005;34:192-4.
9. Fang-Kircher SG, Bock A, Fertschak W, Schwagerl W, Paschke E. Morquio disease in a patient diagnosed as having Perthes disease for 38 years. *J Inherit Metab Dis* 1995;18:94-5.
10. Kanazawa T, Yasunaga Y, Ikuta Y, Harada A, Kusaka O, Sukegawa K. Femoral head dysplasia in Morquio disease type A: bilateral varus osteotomy of the femur. *Acta Orthop Scand* 2001;72:18-1.

Book Review

Crystal-Induced Arthropathies, Gout, Pseudogout and Apatite-Associated Syndromes

Robert L. Wortmann, H. Ralph Schumacher Jr, Michael A. Becker, Lawrence M. Ryan, editors, New York: Taylor & Francis Group, 2006, 427 pages, price US\$217.00

Crystal-associated syndromes are common events in the emergency room and at rheumatology and orthopedic clinics. Often satisfying to treat because of the rapidity of clinical response, they are more often a challenge because of chronicity and progressive destruction, deformity, and disability. The editors of this volume, all respected clinician-scientists, along with 35 other experts in their fields, present historical reviews, prevalence, natural history, associated clinical conditions, epidemiology, clinical aspects, pathophysiology, diagnostic tools, biochemistry, pathology, and approaches to older established and newer therapies for gout (urate), pseudogout (calcium pyrophosphate dehydrate, CPPD), and basic calcium phosphate (BCP, calcium apatite) deposition diseases.

The identification and association of urate crystals with acute arthritis is a recent (1960) event. The editors write that "much of the present understanding of these diseases is the result of observations that have occurred during the span of our careers." Population-based investigations suggest that the prevalence of gout is rising and that hyperuricemia is a strong, independent marker of mortality in coronary heart disease. Asymptomatic hyperuricemia and the concept of urate as a biomarker of endothelial dysfunction and vascular disease is intriguing although controversial. Prevalence data for CPPD and BCP deposition are derived from autopsy and radiographic reviews. The descriptions of the clinical aspects and genetics of the familial forms of crystal-associated arthropathies are interesting reading.

The management of crystal-associated arthropathies includes chapters on colchicine, nonsteroidal antiinflammatory drugs, corticosteroids, uricosuric agents, xanthine oxidase inhibitors, uricase, and therapeutic strategies.

The editors are to be congratulated on the presentation of this concise, in-depth, and current review. It is recommended reading for trainees and their mentors in rheumatology, orthopedic surgery, and physiatry, and others who have a particular interest in these common crystal-associated arthropathies.

Joseph B. Hout, MD, 49 Sunnyside Crescent, Toronto, ON, Canada M4N 3J5