Nail and Distal Interphalangeal Joint in Psoriatic Arthritis

RAFFAELE SCARPA, ERNESTO SOSCIA, ROSARIO PELUSO, MARIANGELA ATTENO, FRANCESCO MANGUSO, ANTONIO DEL PUENTE, ANGELO SPANÒ, CESARE SIRIGNANO, ALFONSO ORIENTE, MATTEO NICOLA DARIO DI MINNO, SALVATORE IERVOLINO, and MARCO SALVATORE

ABSTRACT. ***Objective.*** To study distal interphalangeal (DIP) joints in patients with psoriatic arthritis (PsA) with or without onychopathy, using magnetic resonance imaging (MRI).

Methods. Twenty-three patients with PsA (9/14 F/M, median age 47 yrs), 12 with onychopathy (2/10 F/M, median age 44 yrs) and 11 without (7/4 F/M, median age 52 yrs), and 10 control subjects (5/5 F/M, median age 43.2 yrs) were enrolled. MRI of nail and distal phalanx (DP) including examination of DIP joints was carried out. MRI was performed with a surface coil in a 1.5 T device. For each selected finger, both longitudinal and axial scans were performed. The involvement of nail, DP, and DIP joint was scored.

Results. Nail thickening with or without surface irregularity occurred in 95.7% of cases (100% with onychopathy and 90.9% without). MRI nail involvement was more frequent in patients with clinical evidence of onychopathy than in those without ($p = 0.003$). Similarly, 95.7% of patients showed MRI abnormalities of DP (100% with onychopathy and 90.9% without). MRI DP abnormalities were more marked in patients with clinical evidence of onychopathy than in those without ($p = 0.009$). Involvement of DIP joints was present in 34.8% of cases (58.3% with onychopathy and 9.1% without), and onychopathic patients showed marked MRI DIP joint involvement in 5 cases and mild in 2, while patients without onychopathy showed minimal changes in one case ($p = 0.03$). Considering the entire group of patients, MRI involvement of DIP joints was always associated with MRI DP changes, and in no case was it present alone.

Conclusion. MRI nail involvement was present in almost all patients with PsA studied, even in those without clinically evident onychopathy. MRI involvement of DP always overlapped with nail involvement, since it was present in all psoriatic cases showing MRI nail involvement. In contrast, MRI DIP joint involvement was almost exclusively in a lower percentage of the patients with clinical nail involvement and was always associated with MRI DP changes. Our results suggest that DIP joint involvement is always secondary to nail and DP involvement. (First Release June 1 2006; J Rheumatol 2006;33:1315–9)

Key Indexing Terms:
DISTAL INTERPHALANGEAL JOINT
PSORIATIC ONYCHOPATHY
PSORIATIC ARTHRITIS
PSORIASIS

A direct correlation between nail and articular involvement in psoriatic arthritis (PsA) has been described. In particular, a topographical association between distal interphalangeal (DIP) joint arthritis and dystrophy of the adjacent nail is widely reported[1-3]. Bone changes of the distal phalanx (DP) are generally considered in the context of DIP arthritis and are frequently associated with more severe arthritic changes. In a recent study[4], however, we were unable to confirm this concept. Indeed, although the occurrence of DIP arthritis seemed dependent on the duration of nail involvement, we found no statistical difference in the distribution of DIP arthritis in patients with PsA with or without onychopathy.

We then hypothesized a topographical association between bone changes in the DP and dystrophy of the adjacent nail. Indeed, our results showed that, irrespective of the presence of DIP arthritis, patients with PsA with onychopathy had a more marked bone involvement at the level of the DP than those without nail involvement.

We evaluated nail, DP, and DIP joints in patients with PsA with or without onychopathy using magnetic resonance imaging (MRI). Our aim was to demonstrate that, in PsA, nail involvement is more frequently associated with involvement of the DP than with involvement of the adjacent DIP joint.

From the Department of Clinical and Experimental Medicine, Rheumatology Research Unit and the Radiology Unit, University "Federico II," and the Biostructures and Bioimaging Institute of the National Council of Research, Naples, Italy.

R. Scarpa, MD, Associate Professor of Rheumatology, Department of Clinical and Experimental Medicine, Rheumatology Research Unit; E. Soscia, MD, Radiology Unit, University "Federico II"; R. Peluso, MD; M. Atteno, MD; F. Manguso, MD, PhD; A. del Puente, MD; A. Spanò, MD; A. Oriente, MD, PhD, Department of Clinical and Experimental Medicine, Rheumatology Research Unit, University "Federico II"; C. Sirignano, MD, Biostructures and Bioimaging Institute of the National Council of Research; M.N. Dario Di Minno, Medical Student; S. Iervolino, Medical Student, Department of Clinical and Experimental Medicine, Rheumatology Research Unit; M. Salvatore, MD, Professor of Radiology, Biostructures and Bioimaging Institute of the National Council of Research.

Address reprint request to Dr. R. Scarpa, Rheumatology Research Unit, University Federico II, via Sergio Pansini 5, 80131 Naples, Italy. E-mail: rscarpa@unina.it

Accepted for publication February 22, 2006.

MATERIALS AND METHODS

Twenty-three consecutive, unselected, unrelated patients with PsA attending the outpatient clinic of the Rheumatology Unit from May to September 2004 (14 male, 9 female, median age 47 yrs, range 24–74 yrs), 12 with onychopathy (10 male, 2 female, median age 44 yrs, range 32–74 yrs; median duration of onychopathy 49 mo, range 8–300 mo), and 11 without onychopathy (4 male, 7 female, median age 52 yrs, range 24–69 yrs) were included. A control group of healthy subjects was also studied (5 male, 5 female, mean age 43.2 yrs, range 25–75). Controls were nonsmokers without onychopathy who were recruited from the hospital staff. Nail changes were scored with the Nail Psoriasis Severity Index (NAPSI) according to Rich and Scher[5]. All patients and controls provided informed consent.

MRI examination of the nail and DP including the DIP joint was carried out. MRI was performed with a surface coil in a 1.5 T device (Philips Gyroscan Intera). For each selected finger, both longitudinal (TSE T1-T2 weighted) and axial (3D FFE T1-T2 weighted) scans were performed, with a slice thickness of 1.5 mm and an interslice gap ≤ 0.1 mm. Vaseline was applied on the nail to locate external margins exactly.

In the presence of a clinically evident nail involvement, we performed MRI to evaluate nail, DP, and DIP joint of fingers or one of the fingers with evident ungual lesions. In cases where nail involvement was absent, we performed MRI to evaluate nail, DP, and DIP joint of fingers or one of the fingers with referred arthritic symptoms. In the controls, we evaluated nail, DP, and DIP joint of the index finger of the nondominant hand.

MRI involvement of the nail, DP, and DIP joint was arbitrarily scored by 2 different radiologists who were unaware of the diagnosis. In particular, abnormal findings were recorded when radiologists achieved 100% agreement in evaluation of specific changes. Consequently, final diagnostic categories were obtained with the consensus of radiologists on the basis of the analysis of different results derived from examined MR scans, read independently. Included scores are detailed in Tables 1, 2 and 3.

Statistical analysis. Results are reported as median and range except when otherwise indicated. Fisher's exact test and Mann-Whitney U test were applied for categorical and continuous variables, respectively. The statistical analysis was performed with the statistical software SPSS for Windows, release 13.0.1.

RESULTS

Based on the NAPSI, nail changes were classified into changes in the nail matrix or the nail bed. Matrix changes included pitting in 8 cases, leukonychia in 4 cases, crumbling in 4 cases, and red spots in the lunula in 2 cases, while bed changes included onycholysis in 10 cases, hyperkeratosis in 9 cases, and oil-drop discoloration in 5 cases. Median NAPSI was 5 (range 3–8). Among controls no subjects showed nail changes.

Thickening, with or without surface irregularity, was the commonest MRI finding of nail involvement, occurring in 95.7% of cases (100% of patients with onychopathy and 90.9% of patients without onychopathy; Figures 1B, 1C). In addition, MRI nail involvement score was higher in patients with clinical evidence of onychopathy than in those without ($p = 0.003$; Table 1). Among controls no abnormal findings were recorded (Table 1).

Similarly, 95.7% of the patients showed MRI abnormalities of DP (100% of patients with onychopathy and 90.9% of patients without onychopathy; Figures 2B, 2C, 3D, and 3C). In particular, MRI DP abnormalities were more marked in patients with clinical evidence of onychopathy than in those without ($p = 0.009$; Table 2). Among controls, abnormal bone resorption (score 2) was recorded in only one subject, while in the remaining cases no abnormal finding was found (Table 2).

Involvement of DIP joints was present in 34.8% of the cases (58.3% of patients with onychopathy and 9.1% of patients without onychopathy). In particular, onychopathic patients had marked MRI DIP joint involvement in 5 cases and mild involvement in 2, while patients without onychopathy showed only minimal changes in one case ($p = 0.03$;

Table 1. Distribution and grading of nail involvement demonstrated with magnetic resonance imaging (MRI) in psoriatic patients with and without onychopathy and in controls.

Patient	Total	With MRI Positive Features	Grading* (%) Score 2	Score 1	Score 0
With onychopathy, no. (%)	12	12	9 (75)	3 (25)	0 (0)
Without onychopathy, no. (%)	11	10	1 (9)	9 (82)	1 (9)
Controls, no. (%)	10	0	0 (0)	0 (0)	10 (100)

* Score: 0 = no changes; 1 = nail thickness; 2 = nail thickness and surface irregularity.

Table 2. Distribution and grading of distal phalanx involvement demonstrated with MRI in psoriatic patients with and without onychopathy and in controls.

Patients	Total	With MRI Positive Features	Grading* (%) Score 2	Score 1	Score 0
With onychopathy, no. (%)	12	12	8 (67)	4 (33)	0 (0)
Without onychopathy, no. (%)	11	10	1 (9)	9 (82)	1 (9)
Controls, no. (%)	10	1	1 (10)	0 (0)	9 (90)

* Score: 0 = no changes; 1 = minimal bone abnormalities (bone edema, subchondral geodes); 2 = severe bone abnormalities (marginal erosions, bone resorption, bone proliferation).

Table 3. Distribution and grading of DIP joint involvement demonstrated with MRI in psoriatic patients with and without onychopathy and in controls.

Patients	Total	With MRI Positive Features	Grading* (%) Score 2	Score 1	Score 0
With onychopathy, no. (%)	12	7	5 (42)	2 (17)	5 (42)
Without onychopathy, no. (%)	11	1	0 (0)	1 (9)	10 (91)
Controls, no. (%)	10	2	1 (10)	1 (10)	8 (80)

* Score: 0 = no changes; 1 = minimal joint abnormalities (bone edema, subchondral geodes); 2 = severe joint abnormalities (marginal erosions, bone resorption, bone proliferation, joint space narrowing).

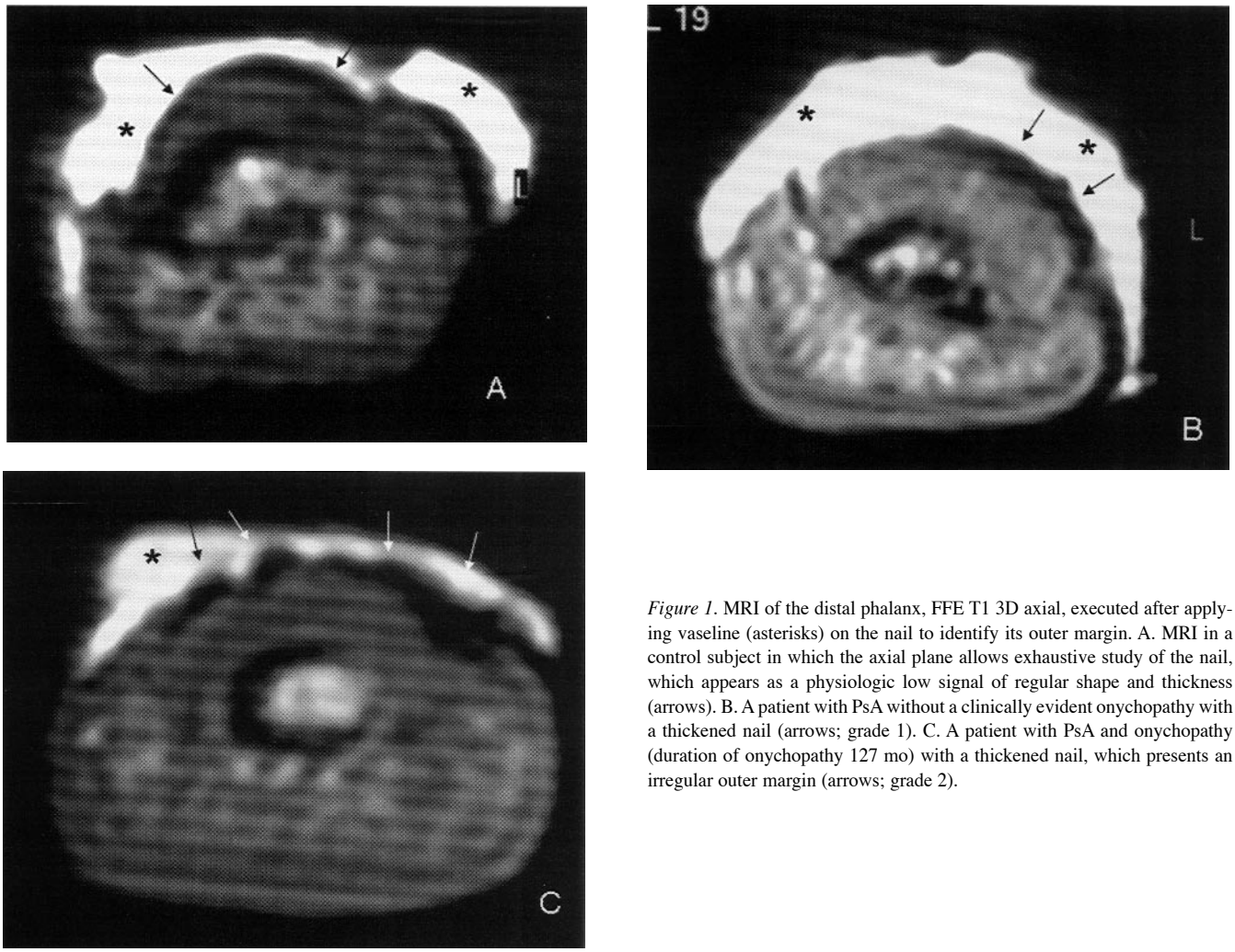

Figure 1. MRI of the distal phalanx, FFE T1 3D axial, executed after applying vaseline (asterisks) on the nail to identify its outer margin. A. MRI in a control subject in which the axial plane allows exhaustive study of the nail, which appears as a physiologic low signal of regular shape and thickness (arrows). B. A patient with PsA without a clinically evident onychopathy with a thickened nail (arrows; grade 1). C. A patient with PsA and onychopathy (duration of onychopathy 127 mo) with a thickened nail, which presents an irregular outer margin (arrows; grade 2).

Table 3, Figures 2C, 3B, and 3C). Among controls, joint space narrowing (score 2) and subchondral geodes (score 1) were detected in 2 cases, respectively, while no abnormal findings were recorded in the remaining subjects (Table 3).

In addition, patients without a clinically evident onychopathy showed marked MRI involvement of DP, which in one case was also associated with involvement of the DIP (in 90% and 10% of the cases, respectively). On the other hand, patients with clinically evident onychopathy always showed MRI involvement of the DP, which was also associated with involvement of the DIP in 58% of the cases. This distribution was statistically significant ($p = 0.03$).

Considering the entire group of patients, MRI involvement of the DIP joint was always associated with MRI DP changes, and in no case was MRI DIP joint involvement present alone.

Our results showed that MRI nail involvement score was higher in patients with clinically evident psoriatic onychopathy than in those without (median value 2, range 1–2 vs medi-

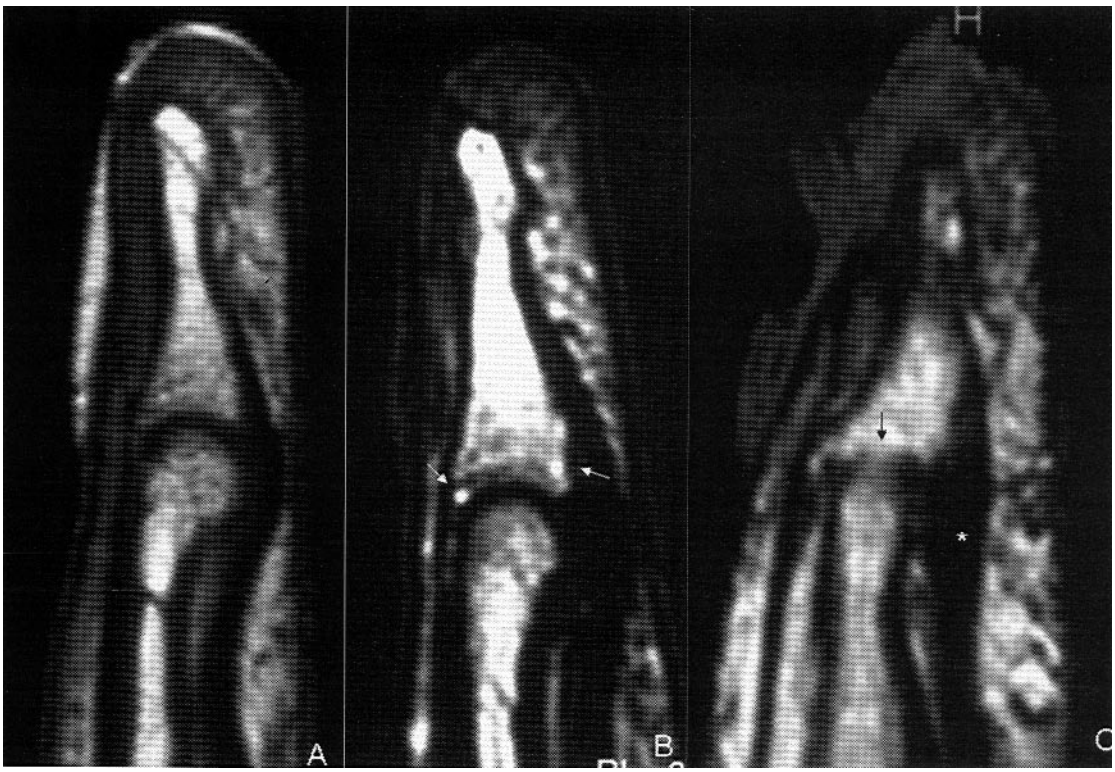

Figure 2. MRI of the distal phalanx: TSE T1 sagittal (A) and TSE T2 sagittal (B and C) images. A. Normal DIP joint in a control subject. B. Patient with PsA without onychopathy. There are focal abnormalities of bone signaling at the base of the DP (arrow) due to arthritis (grade 1). C. Patient with PsA and onychopathy. An advanced structural modification of the DIP joint is shown, with morphological alteration of the articular surfaces and narrowing of the joint space (arrow; grade 2). Enthesopathy of the flexor tendon is also detectable (asterisk).

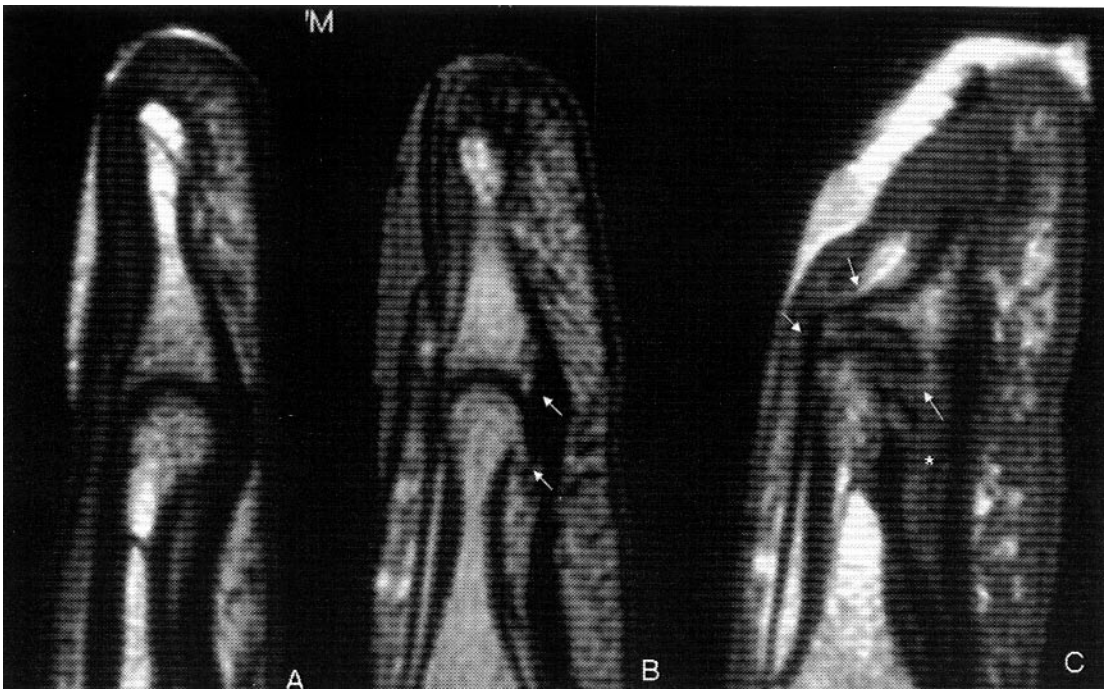

Figure 3. MRI of the distal phalanx: TSE T1 sagittal (A and C) and TSE T2 sagittal (B) images. A. Normal DIP joint structure in a control subject. B and C. In a patient with PsA with no onychopathy (B) marginal syndesmophytosis (arrows) can be detected; in a PsA patient with onychopathy (C) there is advanced morphological abnormality of the DIP joint (arrows), with anterior partial luxation and capping. A reaction of the nearer soft tissue is also evident (asterisk), with enthesopathy of the flexor tendon.

an value 1, range 0–2; p = 0.004). On the other hand, NAPSI score was higher in patients with increased MRI nail involvement score versus those with lower values (median 6, range 5–8 vs median 3, range 3–4; p = 0.009).

DISCUSSION

In our recent study[4] we were unable to confirm a direct correlation between nail and articular involvement of DIP joints, which has been described in patients with PsA. Using standard radiographic films we hypothesized a topographical association between bone changes in DP and dystrophy of the adjacent nail. Therefore, we studied a group of patients with PsA with or without onychopathy using MRI of nail, DP, and DIP joints, with the aim of investigating the pathological relationships between all these structures in PsA. This approach was possible because MRI of the nail unit is now available with small dedicated surface coils that use a modified imaging strategy of ungual and subungual diseases[6].

Our results outline clinical aspects that are useful topics for further discussion: (1) We found MRI nail involvement in almost all cases of patients with PsA studied, even in the cases without clinically evident onychopathy. In particular, MRI nail score was higher in patients with increased NAPSI score. (2) MRI involvement of the DP always overlapped with that of the nail. Indeed, this was found in all PsA cases showing MRI nail involvement. (3) MRI DIP joint involvement was demonstrated almost exclusively in a lower percentage of the patients with clinical nail involvement. This point could suggest a strict relationship between nail involvement and DIP arthritis. However, in no case was MRI DIP joint involvement present alone, but was always associated with MRI DP changes. This aspect may change our perspective of the problem. On the basis of this result, the involvement of the DIP joint seems to be secondary to that of DP and only subsequently to that of the nail.

We realize that our results come from a cross-sectional approach and that conclusive findings require a longitudinal study. However, our data seem to strongly support the hypothesis of sequential involvement, i.e., involvement of the nail and the DP bone first, and only subsequently of the adjacent DIP joint.

Our results give great prominence to nail involvement of patients with PsA, which seems to be the main lesion, present in all cases. Psoriatic onychopathy pathogenetically implies the involvement of DP. This point may be explained on the basis of a direct anatomical link between the nail and the DP. The nail is linked to the DP bone by several entheses, which diffuse PsA inflammatory changes from nail to bone through cellular fat tissue[7,8], in patients with or without onychopathy.

From our results, involvement of the DIP joint seems always to be secondary to that of DP. This may be explained by considering the anatomical structure of the DP, which may be thought of as a voluminous enthesis[7,8]. The DP is surrounded by several entheses, which envelop the DIP joint, an articulation that is more fibrous than it is synovial. The inflammation of DP caused by the inflammation of nail may diffuse, through these entheses, to the adjacent DIP joint.

The peculiar anatomical structure and the relationships between nail, DP, and the adjacent DIP joint explain our results in psoriatic arthritis, which is primarily an entheseal disease; this may also explain why the DIP joint is usually spared in rheumatoid arthritis, which is primarily a synovial disease[9,10].

REFERENCES

1. Bauer W, Bennett GA, Zeller JW. Pathology of joint lesions in patients with psoriasis and arthritis. Trans Assoc Am Physicians 1941;56:349-51.
2. Dawson MH, Tyson TL. Psoriasis arthropathica with observations on certain features common to psoriasis and rheumatoid arthritis. Trans Assoc Am Physicians 1938;53:303-6.
3. Sherman M. Psoriatic arthritis: observations of the clinical roentgenographic and pathological changes. J Bone Joint Surg 1952;34:831-52.
4. Scarpa R, Manguso F, Oriente A, Peluso R, Atteno M, Oriente P. Is the involvement of the distal interphalangeal joint in psoriatic patients related to nail psoriasis? Clin Rheumatol 2004;23:27-30.
5. Rich P, Scher RK. Nail Psoriasis Severity Index: a useful tool for evaluation of nail psoriasis. J Am Acad Dermatol 2003;49:206-12.
6. Drapé JL, Chevrolet A, Bittoun J. Ungual and subungual disease. In: Guglielmi G, Van Kuijk C, Genant HK, editors. Fundamentals of hand and wrist imaging. Berlin: Springer; 2001:481-505.
7. Fournie B, Viraben R, Durroux R, Lassoued S, Gay R, Fournié A. L'onycho-pachydermo-périostite psoriasique du gros orteil. Rev Rhum Mal Ostéoartic 1989;56:579-82.
8. Fournie B, Granel J, Bonnet M, et al. Fréquences des signes évocateurs d'un rhumatisme psoriasique dans l'atteinte radiologique des doigts et des orteils. A propos de 193 cas d'arthropathie psoriasique. Rev Rhum Mal Ostéoartic 1992;59:177-80.
9. McGonagle D, Gibbon W, Emery P. Classification of inflammatory arthritis by enthesitis. Lancet 1998;352:1137-40.
10. McGonagle D, Conaghan PG, Emery P. Psoriatic arthritis: A unified concept twenty years on. Arthritis Rheum 1999;42:1080-6.