

Nonthrombotic Manifestations of the Antiphospholipid Syndrome: Away from Thrombosis?

With the discovery of the anticardiolipin antibodies and the subsequent definition of the antiphospholipid syndrome (APS), their effects on the coagulation pathway were at first thought to be responsible for the occurrence of thromboses. Over the ensuing few years it became clear that the actions of the antiphospholipid antibodies (aPL) were multifactorial, and also involved effects on the endothelium and platelets, and possibly on neural tissues and hormonal and complement pathways¹. Moreover, the primary APS has overtaken systemic lupus erythematosus (SLE) in frequency, as recently reported by the Euro-Phospholipid Project group².

Although many of the clinical associations are explicable on the basis of thrombotic occlusions of not only large vessels (as in the simple/classic systemic APS — Hughes's syndrome) but also predominantly small vessels, as in catastrophic APS (CAPS; Asherson's syndrome^{3,4}), many others are not.

International preliminary classification criteria (Sapporo) for the APS were first formulated in 1999; these were subsequently revised at the Eleventh International Congress on aPL in Sydney in 2005⁵. It is now clear that new definitions will have to be formulated that will eliminate the diagnostic difficulties encountered in attempting to include patients as examples of an APS where no certain thrombotic occlusions have been demonstrated.

It is also clear that in some conditions, such as fetal loss and livedo reticularis, several mechanisms may be involved, and while in some cases thrombosis is evident, in others "APS vasculopathy" in the absence of thrombosis exists. In other conditions there is complement activation (e.g., fetal loss) with neutrophilic invasion of tissues (as in pulmonary alveolar hemorrhage with "capillaritis"), while in patients with valve lesions there is now convincing evidence of valve damage by immune complexes containing cardiolipin, anticardiolipin, and complement. The conditions discussed here are listed in Table 1.

PULMONARY HYPERTENSION (PHT)

The prevalence of PHT in the APS has been estimated to be between 1.8% and 3.5%, and the prevalence of positive aPL estimations in patients with chronic thromboembolic PHT has varied between 10% and 20%. In an analysis of patients with APS by the Euro-Phospholipid Project group, the prevalence of PHT was found to be 2.2%⁶, and in a cohort of primary APS patients, McCarty found that 3% had PHT⁷.

It is clear that although thromboembolic PHT is the most frequent type of PHT seen in patients with the APS, non-

thromboembolic PHT may also be encountered in the presence of the aPL, thus implying that factors other than the thromboembolism or *in situ* thrombosis might be responsible. As the APS is part of the connective tissue disease spectrum, this type of PHT may have the same pathogenesis as seen with other connective tissue disorders, for example, excessive vasoreactivity, deposition of immune complexes in lung tissue, and perhaps a disturbance of endothelin I, produced by pulmonary vascular endothelium. If this latter mechanism has any role in APS, the aPL and its effect on endothelium (i.e., activation) may perhaps be responsible. In the early 1980s it was well documented that autoimmune phenomena (e.g., positive antinuclear antibodies) might accompany this condition, and some investigators questioned whether "primary" PHT was in fact a connective tissue disorder. In 1983 we documented an association between SLE, PHT, and the aPL⁸, and since then many reports have appeared confirming this association not only in patients with SLE but also in those with the primary APS. Other features of the APS were absent in some case reports, implying a different pathogenesis to that causing the thrombotic manifestations. It should be borne in mind, however, that the presence of thrombosis in the pulmonary vasculature does not exclude a "primary" nonthrombotic etiopathogenesis, as these thromboses may be "secondary."

DIFFUSE ALVEOLAR HEMORRHAGE (DAH)

DAH has been described in a number of systemic autoimmune diseases⁹; to this list the APS must now be added. Vascular damage and rupture of small pulmonary vessels must be the basic pathogenesis in the group of patients with DAH and systemic autoimmune diseases. In other conditions associated with "bland" alveolar hemorrhage (e.g., severe mitral stenosis, inhaled toxins, severe infections and coagulopathies), the etiopathogenetic mechanisms and histopathological findings in the lungs are clearly different. Deane and West¹⁰ recently reviewed all aPL-associated cases in the literature including their own 4, a total of 17. Of these, the majority had had previous thrombotic complications and were examples of the APS. In the 2 patients documented by these authors in whom biopsies were performed, a "vasculitis" was presumed to be present; but they did not, however, describe perivascular or vascular infiltrates indicative of a true vasculitis, but instead septal and alveolar neutrophilic infiltrates. Recent studies have elegantly demonstrated the mechanisms that may be responsible for this neutrophilic infiltration, and it is indeed complement-mediated^{11,12}. In a gastrointestinal ischemia-

Table 1. Nonthrombotic manifestations of the antiphospholipid antibody syndrome.

1. Pulmonary	Pulmonary hypertension, diffuse alveolar hemorrhage, acute respiratory distress syndrome
2. Cardiac	Valve lesions
3. Central nervous system	Chorea, epilepsy, transverse myelitis, "pseudo" multiple sclerosis
4. Bone	Osteonecrosis
5. Skin	Livedo reticularis, pseudovasculitis, anetoderma
6. Obstetric	Fetal loss (recurrent)

reperfusion (I/R) model, Hart, *et al*¹¹ found that complement activation played an important role not only in local injury but also in remote injury (e.g., the lung). They used C1q-deficient (C1qKO), MBL-A/C deficient (MBL-null), complement factor 2 and factor B-deficient (C2/fBKO), and wild-type (WT) mice. The gastrointestinal injury was followed by 3-hour reperfusion. Local and distant lung injury was induced in the C1qKO and WT mice, but not in the C2/fBKO mice. Addition of human C2 to the C2/fBKO mice restored the injury, demonstrating that it is mediated via the lectin pathway of complement activation. The injury significantly increased serum alanine aminotransferase, gastrointestinal barrier dysfunction, and neutrophil infiltration into the lung and gut in the C1qKO and WT mice, but not in the C2/fBKO mice. These researchers showed that C2 and mannose-binding lectin (MBL), but not C1q, are necessary for gut injury after gastrointestinal-reperfusion. Lung injury in mice is MBL and C1q-independent, but C2-dependent. They suggested a role for ficolins in this model¹¹. In addition to MBL, the lectin pathway can be activated by H-ficolin and L-ficolin. Although ficolins are mainly synthesized in the liver, L-ficolin is also produced in the lung by alveolar type-11 cells and unciliated bronchial epithelial cells. Importantly, L-ficolins bind to *Escherichia coli* as well as to lipoteichoic acid, a cell-wall constituent of Gram-positive bacteria. Gut barrier translocation may lead to bacterial translocation to the lung, resulting in increased pulmonary neutrophil infiltration as a result of lectin complement pathway activation via ficolins. Fleming, *et al*¹² found that aPL could bind to tissues subjected to the I/R insult, thus mediating tissue damage. aPL represent members of the natural injury-inducing antibody repertoire of antibodies missing in complement receptor 2-deficient mice. Antibodies to B2GP1 restored both local and remote tissue damage in complement receptor 2-deficient mice. The authors proposed that multiple neoantigens are expressed in response to I/R on the endothelial and epithelial surfaces and are recognized by natural antibodies/autoantibodies, which can fix complement, thereby inducing tissue damage.

Of more than passing interest is that none of the 4 patients documented by Deane and West¹⁰ developed an acute (adult) respiratory distress syndrome (ARDS), so prevalent in patients with CAPS¹¹. They were only able to list 17 patients with DAH and aPL (including their own 4 cases) in the entire APS literature. This is a small result, indeed, considering that

worldwide there may be thousands of patients with APS. In a recent series of 200 patients with CAPS documented on the CAPS Registry website [http://www.med.uh.edu/MIMMUN/FORUM/CAPS.HTM], 18 such patients have been registered to date¹³. There is, therefore, a significant difference in prevalence between its occurrence in the simple APS and in the CAPS.

ACUTE RESPIRATORY DISTRESS SYNDROME

This differing prevalence is also evident with ARDS. Few cases have been reported with the simple or classic APS, whereas 47 patients out of 250 with CAPS had this condition¹⁴. It is also very uncommon in SLE; one patient has been documented with ARDS and severe PHT accompanying SLE, which is an extremely rare combination¹⁵.

It has been hypothesized that its occurrence is dependent on the systemic inflammatory response syndrome (SIRS), that it is cytokine-mediated, and that it is caused by the extensive tissue necrosis, occurring particularly in organs such as the bowel, that is the hallmark of this condition.

VALVULAR DISEASE

Valve thickening, resulting in valve dysfunction and incompetence, is common in the APS, and the mitral valve is most frequently affected. Several reports describe valvulopathy in patients with the primary APS^{16,17}, as well as in SLE^{18,19}. Nonbacterial vegetations may be combined with valve thickening and are thought to reflect the same pathological process²⁰. Libman-Sacks endocarditis, as these lesions are named, may eventually heal with a fibrous plaque, sometimes with focal calcification and marked scarring, thickening, and deformity leading to valve dysfunction. In patients with APS, these valve lesions are not usually of clinical or hemodynamic significance; but with extensive deformity, surgical replacement may be necessary. Thromboembolic events constitute the major danger to the patient with Libman-Sacks endocarditis, and can damage brain, kidney, and other organs.

It had been suggested that the procoagulant effect of the aPL promotes valve thrombus on the damaged valves, the organization of which resulted in fibrosis and calcification. Recently, a study on valves derived from patients with secondary APS as well as primary APS showed that subendothelial immunoglobulin deposits contained aPL and complement, that is, an immune complex situation for which pri-

mary steroid administration rather than anticoagulation may be useful²¹.

CHOREA

Chorea is another clinical manifestation infrequently associated with SLE (occurring in less than 4% of cases) that has been strongly linked to the presence of aPL; it does not differ from chorea encountered with rheumatic fever (Sydenham's chorea) or the inherited form (Huntington's chorea). It may antedate other manifestations or be seen during the course of the APS. The chorea may appear without any obvious precipitating factors or may be induced by oral contraceptives^{22,23}. In a review of 50 cases, Cervera, *et al*²⁴ found that one episode of chorea was seen in 66% of the patients, while in 34% it was recurrent. Oral contraceptive-induced chorea, chorea gravidarum, and post-partum chorea occurred in 2%–6% of patients. It was seen bilaterally or unilaterally; it occasionally commenced on one side, to reappear on the other side within weeks to months.

Computed tomography scanning is usually normal, but infarcts outside the basal ganglia themselves might be seen. Magnetic resonance imaging (MRI) findings were reported in only 13 of the 50 cases, and infarcts in the caudate nuclei were seen in only 3. Steroids, haloperidol, aspirin, and anticoagulation were used in several patients, and all patients recovered, but recovery time varied from days to as long as a few months. Some authors²⁵ have suggested that reversible immune-mediated response, hormonally influenced in some, is the most likely pathogenesis of chorea, rather than a vascular hypothesis with thrombosis and infarction occurring. Binding of autoantibodies to striatal interneurons may cause hypermetabolic dysfunction of these cells. Striatal hypermetabolism has been observed²⁶.

AVASCULAR NECROSIS (AVN) OF BONE

The etiology of AVN of bone in patients with SLE is probably multifactorial²⁶ and several risk factors have been suggested, including Raynaud's phenomenon²⁷, glucocorticoid therapy²⁸, particularly in patients developing features of Cushing's syndrome²⁹, and vasculitis³⁰. A possible link between AVN and aPL was first postulated in 1983 and several years later strengthened by reports of AVN in patients with the primary APS who had not been exposed to glucocorticoid therapy³¹⁻³³. The relationship therefore had remained unproven; however, the occurrence of AVN in primary APS patients with no other risk factors other than aPL is certainly linked to their effects in some way. The observations by Tektonidou, *et al*³⁴ using MRI provided credence to this relationship. It is possible that vasculopathy of the major vessels supplying particular areas of bone and caused by reaction of the aPL with endothelium might be responsible, as no definitive evidence of thrombosis has been forthcoming.

EPILEPSY

The prevalence of epilepsy in patients with APS is 7% to

8.6%^{6,35}. SLE may cause epilepsy by a number of APS-independent mechanisms, including vasculitis, metabolic disorders, and cerebritis. The prevalence of epilepsy in primary APS is clearly higher than the 0.5%–1% expected in the general population, and argues for a direct association of APS and epilepsy. The pathogenesis of epilepsy in APS patients is not entirely clear. Possible explanations include focal brain ischemic lesions, autoimmune disease, or direct effects of aPL on the brain. The most likely etiology is probably ischemia. There is a highly significant association between epilepsy and stroke in patients with APS, suggesting that this is the key mechanism in the pathogenesis of epileptogenic foci in these patients³⁶. Small foci of abnormal signalling in the subcortical white matter are observed in many APS patients with seizures. Most APS patients with seizures and normal brain imaging will have a pathological positron emission tomography result, with decreased glucose metabolism in the perivascular areas, suggesting a subtle ischemic insult. Further, a pathological examination in a young patient with APS who had complex partial seizures and transient ischemic events showed widespread small cerebral arterial thrombi³⁷. There is a significant association ($p < 0.02$) between epilepsy and valvular disease in patients with primary APS, also suggesting a cardioembolic mechanism for stroke. However, ischemia is not the exclusive cause of epilepsy in patients with primary APS ischemic pathology. In numerous studies patients with idiopathic epilepsy were found to have autoantibodies in their sera. Anti-central nervous system antibodies have been found in frontal cortex immunoblots, but not in cerebellar immunoblots, in children with epilepsy. The specific identity of these antibodies is unknown, but other investigators have reported autoantibodies to glutamic acid decarboxylase in epilepsy patients³⁸, as well as aPL and aCL antibodies³⁹. Perhaps epilepsy is caused by a direct effect of autoantibodies on brain tissue. This hypothesis is strongly supported by reports that IgG aPL can directly permeabilize and depolarize brain synaptosomes⁴⁰.

TRANSVERSE MYELITIS

Transverse myelitis is an uncommon, but well known neurological complication of SLE, and aPL have been indicated as having a pathogenic role in myelopathy in secondary and primary APS⁴¹. However, the prevalence of transverse myelitis among patients with APS is only 0.4%, and the reported cases associating primary APS with transverse myelitis are extremely rare^{6,42-44}. Several of the APS patients with transverse myelitis had recurrent episodes. The exact etiologic role of autoantibodies in APS-associated transverse myelitis remains to be established. A direct interaction between aPL and cellular elements of the central nervous system, rather than aPL-associated thrombosis, seems to be a more plausible mechanism. Patients with an APS-related transverse myelitis, especially those with recurrent episodes, may have an unrecognized myelin-specific antibody.

MULTIPLE SCLEROSIS (MS)- LIKE SYNDROME (“PSEUDO” MS)

A significant number of patients with APS are misdiagnosed as having MS due to similar characteristics (i.e., young, previously healthy women) and potentially similar presentation⁴⁵. Neurological manifestations and MRI can be indistinguishable and there are no specific diagnostic tools, although evoked-potential studies provide the answer⁴⁶. Treatment and prognosis of the 2 conditions are quite different. There is controversy about the prevalence and significance of aPL in MS. When assessing patients with MS, clinicians should consider APS, especially if the MS has atypical features. As in transverse myelitis, the mechanism causing MS-like symptoms in APS patients is unclear and remains to be established, although an antibody-mediated mechanism seems more plausible than aPL-associated thrombosis. It is suggested that this condition be referred to as “pseudo multiple sclerosis.”

CUTANEOUS MANIFESTATIONS

Cutaneous manifestations are the first clinical presentation of many patients with APS, up to 41% according to some reviews. The main cutaneous manifestations of APS are livedo reticularis (LR), skin ulcers, pseudovasculitic lesions⁴⁷, and anetoderma. LR is caused by blood flow disturbances in small and medium-size blood vessels in the dermal-subdermal junction. The histopathology of LR shows endothelitis and obliterating endarteritis with no evidence of true vasculitis. The combination of LR and stroke is called Sneddon’s syndrome, and many of these patients will have aPL antibodies⁴⁸. In most cases the LR precedes the stroke by many years. The syndrome may also be associated with hypertension, valvular pathology, renal artery pathology, and epilepsy⁴⁹. In most cases microthrombosis of dermal capillaries is lacking. In many cases, an APS “vasculopathy,” that is, endothelitis and obliterating endarteritis, has been demonstrated histopathologically.

FETAL LOSS

Pregnancy loss (often recurrent) is one of the 3 major clinical criteria for the diagnosis of APS. It has long been assumed that impaired blood supply and thrombosis of placental vessels results in placental infarction, with heparin being the standard treatment advised because of its antithrombotic action. Recent investigation by Girardi, *et al*⁵⁰ has shown that this concept may be incorrect, and this explains the phenomenon that many placentae from APS patients who had had miscarriages were devoid of thromboses⁵¹. The additional observation that many patients with PAPS and recurrent miscarriages do not suffer from the usual recurrent venous and arterial thrombosis seen in APS also perhaps reinforces the concept that other mechanisms may be operating, and that these are not necessarily associated with thrombosis. The authors demonstrated⁵⁰ that the complement pathway may play an

integral and important role in the pathogenesis of fetal loss, totally unrelated to a thrombotic or gonadotrophic hormonal blocking effects of the aPL. Activation of the C3 component of complement is needed for fetal loss to occur⁵² and C5 is also required⁵³. They suggested that local complement activation could be a mechanism for damage not only to the trophoblast but also for vascular endothelium. Low molecular weight and unfractionated heparin prevented complement activation *in vivo* and *in vitro* and protected mice from aPL-induced pregnancy complications, whereas neither fondaparinux nor hirudin (both anticoagulants only) inhibited the generation of complement split products or prevented pregnancy losses⁵⁰. This anticomplementary activity of heparin has been known since 1929. What Girardi, *et al* have proposed is that preferentially targeted aPL, directed towards the decidua and placenta, lead to the generation of potent anaphylotoxins and mediators of effector-cell activation. Recruitment of inflammatory cells accelerates the alternative pathway activation and creates a proinflammatory amplification loop that enhances complement C3 activation and deposition, generates additional C3a and C5a, and results in further inflammatory cell migration into the placenta. Indeed, inflammatory changes have been described by other authors⁵⁴ in placentae from women with the APS and, prior to 2005, elevated levels of complement split products were also observed in serum from patients with APS-related cerebral events. After describing endothelial cell activation by aPL, Pierangeli, *et al*⁵⁶ confirmed that mice deficient in complement components C3 and C5 were resistant to the enhanced thrombosis, and had shown that endothelial cell activation induced by injected aPL was responsible for the activation of complement.

In several of the conditions discussed here, some patients have not had any of the usual thrombotic manifestations of the APS, either large-vessel occlusions (venous or arterial) or small-vessel thrombosis. This suggests that possibly differing pathogenic idiotypes of the aPL may exist, and that what occurs depends perhaps on differing specificity of these idiotypes. While most pathogenic aPL result in large-vessel thrombosis, others may only cause fetal loss and/or the hematological accompaniments of the syndrome (e.g., thrombocytopenia, hemolytic anemia). Some aPL-positive patients only present with essentially “nonthrombotic” manifestations (e.g., chorea, pulmonary hypertension, pulmonary alveolar hemorrhage, osteonecrosis; and many cases of recurrent fetal loss where no thromboses are detected on placental histopathological examination).

Hemolytic anemia and thrombotic microangiopathy may denote yet another subset of the APS, that is, microangiopathic APS (MAPS), which would comprise thrombotic thrombocytopenic purpura-like syndromes, HELLP syndrome (hemolysis, elevated liver enzymes, and low platelet count), thrombotic microangiopathic hemolytic anemia, etc.⁵⁷. In CAPS

there is an “overlap” between MAPS and large-vessel occlusions (in a minority of cases), and there may also be evidence of complicating disseminated intravascular coagulation.

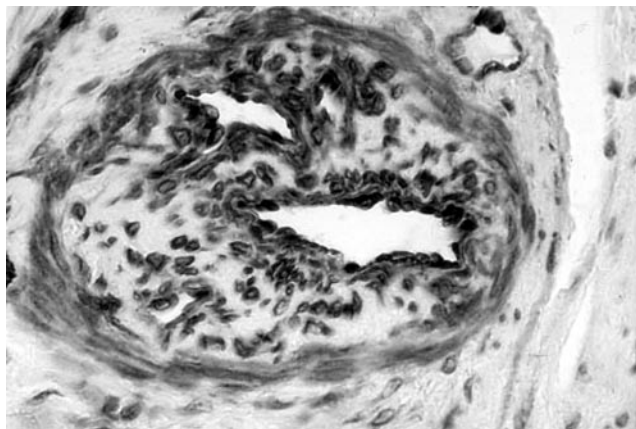
The APS “vasculopathy” or endotheliopathy is an intriguing histopathological feature, which may be seen in many aPL-associated manifestations. It may be clearly and easily demonstrable in tissues readily accessible to biopsy (e.g., the skin and kidney) and in brain vessels examined at autopsy.

Clearly, complement activation, induced by ischemia or aPL-induced endothelial cell activation, is intimately involved in the pathogenesis of the syndrome.

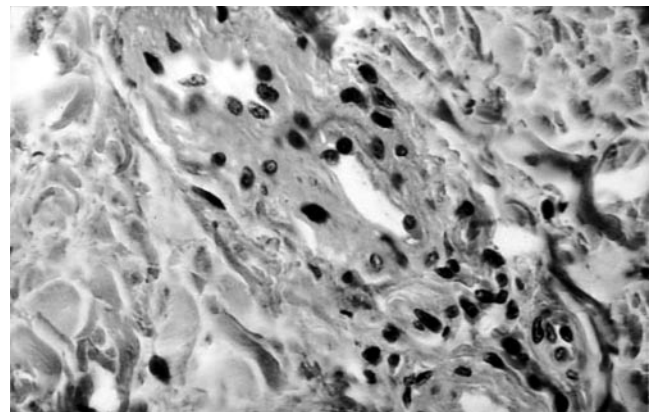
This multifactorial concept is not new in the field of autoimmune diseases, and such a hypothesis has also been postulated to explain the diversity of manifestations that characterize SLE, a closely related condition. These multiple pathogenetic factors are only now beginning to be unravelled.

In practical terms, however, we as clinicians are still

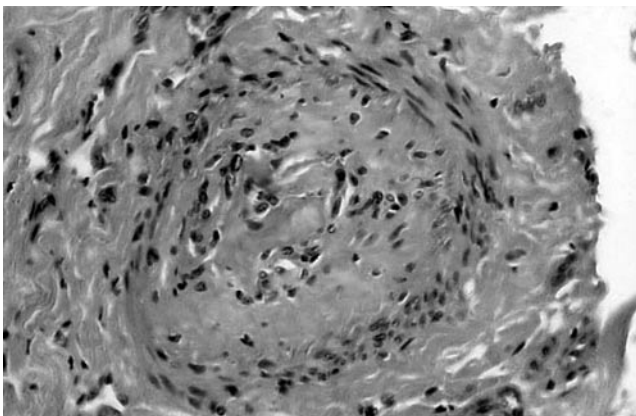
unable to distinguish which complications are caused by mechanisms other than thrombosis, for example, complement activation and phospholipid antibodies reacting with neural tissues, etc. Complement activation may occur as a result of thrombosis because of ischemia and may also predispose to thrombosis, for example, when deposited on the inner surface of heart valves together with phospholipid and antiphospholipid antibodies, thereby causing valve damage. In APS pregnancies, heparin still has to be administered in doses sufficient to influence coagulation. It is hoped that in the future other compounds may be forthcoming. Therapies inhibiting complement activation (e.g., anti-C5 antibodies, inactivated derivative of C3a, C3adesArg, and C3d fragments) are presently being investigated. Their advent may then obviate the necessity of once or twice daily injections now being prescribed for patients with recurrent fetal losses, and they may also prove to be useful in preventing some of the distressing and potentially fatal complications of CAPS.



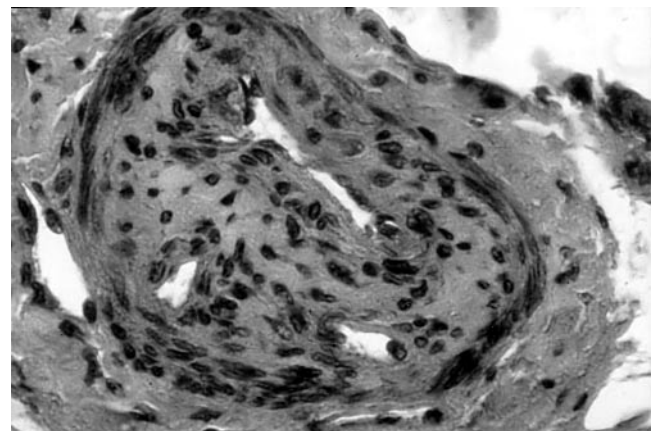
A



B



C



D

Figure 1. These tissue samples were obtained either from the center of the livedo or from surrounding areas with the characteristic violaceous “fishnet” appearance. Immunostaining for vimentin and actin were positive. Staining for desmin was negative. Some arteriolar lesions were partially or completely occluded by cellular plugs with numerous mononuclear cells containing regular round or oval nuclei. Others seemed to be occluded by acellular plugs. Small-vessel hyperplasia only was observed in the reticular network. No thrombotic lesions were observed. Courtesy of Prof. C. France, Paris, France.

RONALD A. ASHERSON, MD (Hon), FRCP, FACP, FCP, FACR,
Professor of Pathology,
School of Pathology,
University of the Witwatersrand,
Johannesburg, South Africa;

RICARD CERVERA, MD, FRCP,
Department of Autoimmune Diseases,
Institut Clínic de Medicina i Dermatologia,
Hospital Clínic,
Barcelona, Catalonia, Spain;

DANIEL SHEPSHELOVICH, MD,
Department of Medicine B,
Sackler School of Medicine,
Tel Hashomer, Israel;

YEHUDA SHOENFELD, MD, FRCP (Hon),
Department of Medicine B,
Sackler School of Medicine,
Tel Hashomer, Israel.

Address reprint requests to Dr. R.A. Asherson; E-mail: ashron@icon.co.za

REFERENCES

1. Mackworth-Young CG. Antiphospholipid syndrome: Multiple mechanisms. *Clin Exp Immunol* 2004;136:393-401.
2. Cervera R, Piette JC, Font J, Khamashta MA, Shoenfeld Y, Campo MT. Antiphospholipid syndrome: Clinical and immunologic manifestations and patterns of disease expression in a cohort of 1000 patients. *Arthritis Rheum* 2002;46:1019-27.
3. Asherson RA. The catastrophic antiphospholipid syndrome. *J Rheumatol* 1992;19:508-12.
4. Piette JC, Cervera R, Levy RA, Nasonov EL, Triplett D, Shoenfeld Y. The catastrophic antiphospholipid syndrome — Asherson's syndrome. *Ann Med Interne* 2003;154:195-6.
5. Miyakis S, Lockshin MD, Atsumi T, et al. International consensus statement on an update of the classification criteria for definite antiphospholipid syndrome (APS). *J Thromb Haemost* 2006; 4:295-306.
6. Cervera R, Piette JC, Font J, Khamashta MA, Campo MT. Antiphospholipid syndrome: clinical and immunologic manifestations and patterns of disease expression in a cohort of 1000 patients. *Arthritis Rheum* 2002;46:1019-27.
7. McCarty GA. Vascular pathology of the antiphospholipid syndrome. In: Khamashta MA, editor. *Hughes syndrome, the antiphospholipid syndrome*. London: Springer; 2000:539-44.
8. Asherson RA, Mackworth-Young CG, Boey ML, et al. Pulmonary hypertension in systemic lupus erythematosus. *BMJ* 1983;287:1024-5.
9. Zandman-Goddard G. Diffuse alveolar hemorrhage in autoimmune diseases. *J Isr Med Assoc* 2002;4:461-2.
10. Deane KD, West SG. Antiphospholipid antibodies as a cause of pulmonary capillaritis and diffuse alveolar hemorrhage: A case series and literature review. *Semin Arthritis Rheum* 2005;35:154-65.
11. Hart ML, Ceonzo KA, Shaffer LA, et al. Gastrointestinal ischemia-reperfusion injury is lectin complement pathway dependent without involving C1q. *J Immunol* 2005;174:6373-80.
12. Fleming SD, Egan RE, Chai C, et al. Anti-phospholipid antibodies restore mesenteric ischemia reperfusion-induced injury in complement receptor 2/complement receptor 1-deficient mice. *J Immunol* 2004;173:7055-61.
13. Cervera R, Gómez-Puerta JA, Espinosa G, et al. "CAPS Registry": A review of 200 cases from the international registry of patients with catastrophic antiphospholipid syndrome (CAPS). *Ann Rheum Dis* 2003;62 Suppl 1:88.
14. Bucciarelli S, Espinosa G, Asherson RA, et al. The acute respiratory distress syndrome in catastrophic antiphospholipid syndrome: Analysis of a series of 47 cases. *Ann Rheum Dis* 2006;65:81-6. Epub 2005 May 26.
15. Kim WU, Kim SI, Yoo WH, et al. Adult respiratory distress syndrome in systemic lupus erythematosus: causes and prognostic factors: a single centre retrospective study. *Lupus* 1999;8:552-7.
16. Cervera R, Khamashta MA, Font J, et al. High prevalence of significant heart valve lesions in patients with 'primary' antiphospholipid syndrome. *Lupus* 1992;1:43-7.
17. Garcia-Torres R, Amigo M-C, De la Rosa A, Moron A, Reyes PA. Valvular heart disease in primary antiphospholipid syndrome: clinical and immunological findings. *Lupus* 1995;5:56-61.
18. Galve E, Ordi J, Barquinero J, Evangelista A, Vilardell M, Soler-Soler J. Valvular heart disease in the primary antiphospholipid syndrome. *Ann Intern Med* 1992;116:293-8.
19. Khamashta MA, Cervera R, Asherson RA, et al. Association of antibodies against phospholipids with heart valve disease in systemic lupus erythematosus. *Lancet* 1990;335:1541-4.
20. Kelion AD, Cockroft M, Ritter JM. Antiphospholipid syndrome in a patient with rapidly progressive fibrosing alveolitis. *Postgrad Med J* 1995;71:2333-5.
21. Ziporen L, Goldberg I, Arad M, et al. Libman-Sacks endocarditis in the antiphospholipid syndrome: Immunopathologic findings in deformed heart valves. *Lupus* 1995;5:196-205.
22. Asherson RA, Harris EN, Gharavi AE, Hughes GRV. Systemic lupus erythematosus, antiphospholipid antibodies, chorea and oral contraceptives. *Arthritis Rheum* 1986;29:1535-6.
23. Asherson RA, Harris EN, Hughes GRV, Farquharson RG. Complications of oral contraceptives and antiphospholipid antibodies: reply to the letter by Bruneau, et al. *Arthritis Rheum* 1988;31:575-6.
24. Cervera R, Asherson RA, Font J, et al. Chorea in the antiphospholipid syndrome. Clinical, neurologic and immunologic characteristics of 50 patients from our clinics and the recent literature. *Medicine Baltimore* 1997;76:203-12.
25. Furie R, Ishikawa T, Dhawan V, Eidelberg D. Alternating hemichorea in primary antiphospholipid syndrome. Evidence for contralateral striatal hypermetabolism. *Neurology* 1994;44:2197-9.
26. Sundén-Cullberg J, Tedroff J, Aquilonius SM. Reversible chorea in primary antiphospholipid syndrome. *Mov Disord* 1998;13:147-9.
27. Liote F, Meyer O. Osteoarticular manifestations in the antiphospholipid syndrome. In: Asherson RA, Cervera R, Piette J-C, Shoenfeld Y, editors. *The antiphospholipid syndrome*. Boca Raton: CRC Press; 1996:195-200.
28. Klippel TM, Stevens MB, Zizic TM, Hungerford DS. Ischemic necrosis of bone in systemic lupus erythematosus. *Medicine Baltimore* 1976;55:251-7.
29. Zizic TM, Marcor K, Hungerford DS, Dansereau JV, Stevens MB. Corticosteroid therapy associated with ischemic necrosis of bone in systemic lupus erythematosus. *Lancet* 1987;i:902-6.
30. Massando L, Jacobelli S, Leissner M, Gonzalez M, Villarroel L, Rivero S. High dose intravenous methylprednisone therapy associated with osteonecrosis in patients with systemic lupus erythematosus. *Lupus* 1992;2:401-5.
31. Asherson RA, Liote F, Page B, et al. Avascular necrosis of bone and antiphospholipid antibodies in systemic lupus erythematosus. *J Rheumatol* 1993;20:284-8.
32. Asherson RA, Khamashta MA, Ordi-Ros J, et al. The primary antiphospholipid syndrome: major clinical and serological features. *Medicine Baltimore* 1989;68:366-74.
33. Seleznick MJ, Silveira LH, Espinoza LR. Avascular necrosis associated with anticardiolipin antibodies. *J Rheumatol* 1991;18:1416-7.
34. Tektonidou MG, Malagari K, Vlachoyiannopoulos PG, Kelekis DA,

- Moutsopoulos HM. Asymptomatic avascular necrosis in patients with primary antiphospholipid syndrome in the absence of corticosteroid use: a prospective study by magnetic resonance imaging. *Arthritis Rheum* 2003;48:732-6.
35. Mont MA, Glueck CJ, Pacheco IH, Wang P, Hungerford DS, Petri M. Risk factors for osteonecrosis in systemic lupus erythematosus. *J Rheumatol* 1997;24:654-62.
 36. Hilker R, Thiel A, Geisen C, et al. Cerebral blood flow and glucose metabolism in multi-infarct dementia related to primary antiphospholipid antibody syndrome. *Lupus* 2000;9:311-6.
 37. Leach IH, Lennox G, Jaspan T, et al. Antiphospholipid antibody syndrome presenting with complex partial seizures and transient ischaemic attacks due to widespread small cerebral arterial thrombosis. *Neuropathol Appl Neurobiol* 1989;15:579-84.
 38. Lampropoulos CE, Koutroumanidis M, Reynolds PP, Manidakis I, Hughes GR, D'Cruz DP. Electroencephalography in the assessment of neuropsychiatric manifestations in antiphospholipid syndrome and systemic lupus erythematosus. *Arthritis Rheum* 2005;52:841-6.
 39. Plioplys AV, Greaves A, Yoshida W. Anti-CNS antibodies in childhood neurologic diseases. *Neuropediatrics* 1989;20:93-102.
 40. Chapman J, Cohen-Armon M, Shoenfeld Y, Korczyn AD. Antiphospholipid antibodies permeabilize and depolarize brain synaptoneuroosomes. *Lupus* 1999;8:127-33.
 41. Kim JH, Lee SI, Park SI, Yoo WH. Recurrent transverse myelitis in primary antiphospholipid syndrome — case report and literature review. *Rheumatol Int* 2004;24:244-6.
 42. Kim JH, Lee SI, Park SI, Yoo WH. Recurrent transverse myelitis in primary antiphospholipid syndrome — case report and literature review. *Rheumatol Int* 2004;24:244-6.
 43. Shaharao V, Bartakke S, Muranjan MN, Bavdeker MS, Udani VP. Recurrent acute transverse myelitis: association with antiphospholipid antibody syndrome. *Indian J Pediatr* 2004;71:559-61.
 44. Lee DM, Jeon HS, Yoo WH. Transverse myelitis in a patient with primary antiphospholipid syndrome. *Yonsei Med J* 2003;44:323-7.
 45. Ferreira S, D'Cruz DP, Hughes GR. Multiple sclerosis, neuropsychiatric lupus and antiphospholipid syndrome: Where do we stand? *Rheumatology Oxford* 2005;44:434-42.
 46. Paran D, Chapman J, Korczyn AD, et al. Evoked potential studies in the antiphospholipid syndrome: differential diagnosis from multiple sclerosis. *Ann Rheum Dis* 2005 Aug 17; Epub ahead of print.
 47. Asherson RA, Jacobelli S, Rosenberg H, et al. Skin nodules and macules resembling vasculitis in the antiphospholipid syndrome. *Clin Exp Dermatol* 1992;17:266-9.
 48. Frances C, Papo T, Wechsler B, et al. Sneddon syndrome with and without antiphospholipid antibodies: a comparative study in 46 patients. *Medicine Baltimore* 1999;78:209-19.
 49. Toubi E, Krause I, Fraser A, et al. Livedo reticularis is a marker for predicting multi-system thrombosis in antiphospholipid syndrome. *Clin Exp Rheumatol* 2005;23:499-504.
 50. Girardi G, Redecha P, Salmon JE. Heparin prevents antiphospholipid-induced fetal loss by inhibiting complement activation. *Nature Med* 2004;10:1222-6.
 51. Out HJ, Kooijman CD, Bruinse HW, Derksen RH. Histopathological findings in placentae from patients with intra-uterine fetal death and Antiphospholipid antibodies. *Eur J Obstet Gynaecol Reprod Biol* 1991;41:179-86.
 52. Holers VM, Girardi G, Mo L, et al. Complement C3 activation is required for antiphospholipid antibody-induced fetal loss. *J Exp Med* 2002;195:211-20.
 53. Girardi G, Berman J, Redecha P, et al. Complement C5a receptors and neutrophils mediate fetal injury in the antiphospholipid syndrome. *J Clin Invest* 2003;112:1644-54.
 54. Magid MS, Kaplan C, Sammaritano LR. Placental pathology in systemic lupus erythematosus: a prospective study. *Am J Obstet Gynaecol* 1998;179:226-34.
 55. Davis WD, Brey RL. Antiphospholipid antibodies and complement activation in patients with cerebral ischemia. *Clin Exp Immunol* 1992;10:455-60.
 56. Pierangeli SS, Girardi G, Vega-Ostertag M, Liu X, Espinola RG, Salmon J. Requirement of activation of complement C3 and C5 for antiphospholipid antibody mediated thrombosis. *Arthritis Rheum* 2005;52:2120-4.
 57. Asherson RA, Cervera R, Merrill JT. The microangiopathic antiphospholipid syndrome (MAPS). A continuum between several conditions? *Future Rheumatology* 2006; (in press).