

Chondrocyte Apoptosis and Expression of Bcl-2, Bax, Fas, and iNOS in Articular Cartilage in Patients with Kashin-Beck Disease

SHI JIE WANG, XIONG GUO, HONG ZUO, YIN GANG ZHANG, PENG XU, ZHI GUANG PING, ZENTIE ZHANG, and DONG GENG

ABSTRACT. *Objective.* Kashin-Beck disease (KBD) is a chronic, endemic osteochondropathy principally occurring in children. We investigated apoptotic chondrocyte death and the expression of Bcl-2, Bax, Fas, and inducible nitric oxide synthase (iNOS) in articular cartilage from patients with KBD in order to determine the pathogenesis of chondronecrosis in KBD.

Methods. Samples of articular cartilage were divided into 2 groups: control children (15 samples from 15 cases), and children with KBD (15 samples from 15 cases). KBD patients were diagnosed according to "Pathological Criteria to Diagnose KBD in China." Chondrocyte apoptosis was detected by TUNEL staining, and Bcl-2, Bax, Fas, and iNOS-positive articular chondrocytes were stained by immunohistochemistry. Articular cartilage was classified in 3 zones, and positive findings were counted by light microscopy for cytoplasmic staining by polyclonal antibodies of Bcl-2, Bax, Fas, and iNOS and apoptotic chondrocytes by TUNEL.

Results. The percentage of positive apoptotic chondrocytes stained by TUNEL in the middle zone of articular cartilage from the KBD patient group ($33.60\% \pm 2.71\%$) was higher than that of controls ($1.33\% \pm 0.41\%$; $p < 0.01$). The percentages of chondrocytes staining for Bcl-2, Bax, Fas, and iNOS in KBD patients were significantly higher than in controls ($p < 0.01$); the remarkable difference in Bcl-2, Bax, Fas, and iNOS expression among the upper, middle, and deep cartilage zones was also seen in KBD articular cartilage ($p < 0.01$); and staining for Bcl-2, Bax, Fas, and iNOS in KBD patients was prominent in the upper zone ($41.93\% \pm 12.26\%$, $45.60\% \pm 15.78\%$, $53.60\% \pm 16.49\%$, $45.47\% \pm 14.02\%$, respectively) and the middle zone ($14.93\% \pm 3.50\%$, $13.87\% \pm 4.32\%$, $23.27\% \pm 4.83\%$, $21.67\% \pm 6.82\%$) of articular cartilage.

Conclusion. The apoptotic chondrocytes and Bcl-2, Bax, Fas, and iNOS-positive chondrocytes were significantly more numerous in patients with KBD than in controls. (J Rheumatol 2006;33:615–9)

Key Indexing Terms:

KASHIN-BECK DISEASE
FAS

BAX

CHONDROCYTE

APOPTOSIS
INDUCIBLE NITRIC OXIDE SYNTHASE

Bcl-2

Kashin-Beck disease (KBD) is a chronic, endemic osteochondropathy affecting over 0.81 million patients, with 101 million people at risk in China¹. The basic pathological features of KBD are chondrocytic degeneration and necrosis in the deep zone of articular cartilage and growth plate cartilage, which can result in secondary osteoarthritis (OA). The ultrastructural

al changes show condensation and vacuolization of cytoplasm, and calcium granules were found to be deposited on plasma membranes. Clinically, the disease manifests as deformed enlarged interphalangeal joints with shortened fingers, and limited range of motion of joints in the extremities, which develop in 4 stages, that is, the early stage, followed by the first, second, and third degrees². Radiographic signs of KBD that reflect the clinical process include thinning, blurring, interruption, and disappearance of the calcification zone in the phalanges of the hands in the early stage; irregularity and coarseness with sclerosis in the middle stage; and bone defects and deformity in the late stage².

KBD in China is mainly distributed geographically in a diagonal belt from the northeast to the southwest, in which selenium is deficient in soil and cereals, and where mycotoxins such as T-2 toxin, moniliformin, and butenolide (BUT) are present in high quantities in cereal. A multifactorial model of interactions of these risk factors has been considered for KBD³⁻⁵. Investigations have shown that environmental factors exist in the KBD area that can damage DNA. For example,

From the Key Laboratory of Environment and Gene Related Diseases, Xi'an Jiaotong University, Ministry of Education; and the Department of Imaging, Second Hospital of Xi'an Jiaotong University, Xi'an, Shaanxi Province, China.

Supported by the National Natural Science Foundation of China (No. 30371252, 30571616, 2002BA711A08) and the Natural Science Foundation of Xi'an Jiaotong University (No. XJJ-2004133).

S.J. Wang, MD, PhD, Department of Imaging, Second Hospital of Xi'an Jiaotong University; X. Guo, MD, Professor; H. Zuo, MD, PhD; Y.G. Zhang, MD, PhD; P. Xu, MD, PhD; Z.G. Ping, MD, PhD; Z. Zhang, Technician; D. Geng, Technician, Key Laboratory of Environment and Genes Related to Diseases, Xi'an Jiaotong University.

Address reprint requests to Dr. X. Guo, Medical School of Xi'an Jiaotong University, No. 76 West Road of Yanta, Xi'an 710061, China.

E-mail: guoxiong_xjtu@163.net

Accepted for publication October 19, 2005.

T-2 toxin and BUT can induce DNA ladder in chicken and human articular cartilage. We reported⁶ that apoptotic chondrocytes appeared in the articular cartilage of young rats fed a selenium-deficient diet. Although recent reports⁷ show some relationship between these environmental factors and chondrocyte apoptosis and chondronecrosis, little is known about chondrocyte apoptosis in human KBD.

OA is a degenerative joint disease characterized by articular cartilage degradation. Correlation between chondrocyte apoptosis and the degree of severity in human OA cartilage has recently been reported⁸. The clinical, radiographic, and pathological changes of the advanced stage of KBD are similar to those of OA, but it is not clear whether there is abnormal chondrocyte apoptosis in KBD. We investigated the expression of chondrocyte apoptosis by TUNEL staining, as well as expression of Bcl-2, Bax, Fas, and inducible nitric oxide synthase (iNOS) for evidence of the pathogenesis of chondronecrosis in patients with KBD.

MATERIALS AND METHODS

Tissue preparation and patient groups. Cartilage samples were collected from 2 groups. The control group consisted of 15 articular cartilage samples from phalanges of children; samples were obtained from autopsy cases with no history of joint disease, 7 male and 8 female cases 3 to 12 years of age. The KBD group consisted of articular cartilage samples of the distal end of the middle phalanges in the second or third fingers obtained at autopsy from 15 cases of KBD from the disease-affected area; these included 5 male and 10 female cases aged 3 to 15 years who had died from diseases such as acute diarrhea. All samples were obtained with consent and approved by the Human Ethics Committee, Medical School of Xi'an Jiaotong University.

Patients had been diagnosed as early stage KBD (5 cases) and first (2 cases) or second degree (8 cases) based on the "Pathological Criteria to Diagnose KBD in China" (Ministry of Public Health, China; 2004; unpublished) by H&E staining of articular cartilage sections.

Cartilage slices of 0.5–1 cm thickness were fixed with 4% paraformaldehyde for 24 h after removal of the tissue and decalcified in 3% EDTA. Samples were dehydrated in an alcohol series, cleared in xylene, and embedded in paraffin. Paraffin sections (6–8 µm) were cut, mounted on slides, pre-treated with 10% poly-L-lysine, and stored at room temperature until used.

In situ apoptosis analysis by TUNEL staining. Detection of apoptotic nuclei in cartilage was performed using the *in situ* cell death detection kit (Roche Diagnostics, Indianapolis, IN, USA). Briefly, the preserved cartilage sections were treated with proteinase K (25 µg/ml) for 20 min and quenched of endogenous hydrogen peroxidase activity with 3% H₂O₂. After rinsing, DNA was end-labeled with terminal deoxynucleotidyl transferase (TdT) and digoxigenin-11-dUTP. After 60 min incubation with anti-digoxigenin-peroxidase at 37°C, color was developed with diaminobenzidine tetrahydrochloride. Incubation without TdT served as the negative control.

Immunohistochemistry. Staining for Bcl-2, Bax, Fas, and iNOS. Deparaffinized cartilage sections were quenched of endogenous hydrogen peroxidase activity in 0.3% H₂O₂ for 10 min according to the protocol recommended by the manufacturer of the immunohistochemical staining kits for Bcl-2, Bax, Fas, and iNOS (Santa Cruz Biotechnology, Santa Cruz, CA, USA). For detection of Bcl-2, Bax, Fas, and iNOS, sections were incubated overnight at 4°C with primary antibodies and visualized using alkaline-phosphatase labeled secondary antibodies. Color development was continued for 30 min at room temperature using 3-hydroxy-2-naphtholic acid 2,4-dimethyl-anilide as substrate. Finally, nuclei were counterstained with hematoxylin. Each staining section included the control sections incubated with normal rabbit nonimmune serum.

H&E staining. Paraffin embedded tissue (6 µm thickness) was stained with hematoxylin and eosin.

Antibodies and reagents. The rabbit polyclonal immunohistochemistry kits for Bcl-2, Bax, Fas, and iNOS were purchased from Santa Cruz Biotechnology. Biotin labeled IgG mouse anti-human antibodies were purchased from Sigma Chemical Co., St. Louis, MO, USA.

Classification of cartilage zones. Articular cartilage chondrocytes were divided into 3 cell morphologies by light microscopy criteria⁹, namely the upper, middle, or deep zone. Chondrocytes in the upper zone were relatively small and flat, and oriented with the long axis parallel to the surface; larger and rounded cell profiles in the middle zone were randomly distributed in a matrix with fibers running in oblique directions; cells in the deep zone were of increasing size and were arranged in columnar manner perpendicular to the surface.

Statistic analysis. Tissue sections were examined and counted by light microscopy for apoptotic nuclei by TUNEL staining and cytoplasmic staining by polyclonal antibodies of Bcl-2, Bax, Fas, and iNOS. Six randomly chosen fields in each zone were counted at 400× magnification. The average rate in different zones was calculated in each case, and then for the different groups. Values were analyzed as statistically significant if *p* value was < 0.05, by *t* tests in the different groups and by ANOVA in the different cartilage zones.

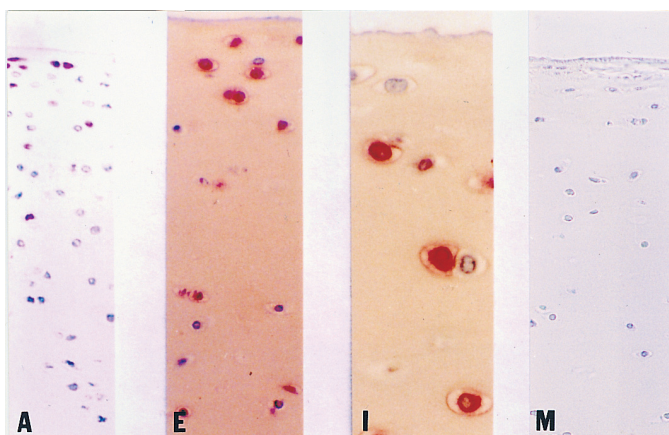
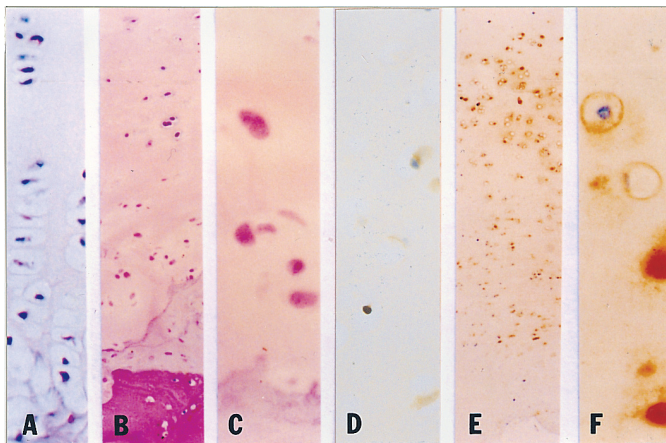
RESULTS

Localization of KBD and control chondrocyte apoptosis and chondronecrosis in articular cartilage. Pathological changes of hyaline cartilage in KBD have been described by Mo¹⁰ and Sokoloff¹¹. In contrast to controls (Figure 1A), large chondronecrotic areas without cells were observed in the deep zone in articular cartilage from KBD patients (Figure 1B). The chondrocyte size was significantly reduced, but the cell membrane was intact. Nuclei were dissolved, broken, and compressed, associated with a red staining in the chondrocyte cytoplasm, and acellular fibrillated areas were visible (Figure 1C). In the control samples, apoptotic chondrocytes by TUNEL staining were occasionally observed in the deep zone of articular cartilage, and no chondrocyte apoptosis was seen in the upper and middle articular cartilage zones (Figure 1D). In KBD samples, apoptotic chondrocytes were mainly located in the middle zone of articular cartilage, and then in the deep zone (Figure 1E). KBD cartilage revealed apoptotic chondrocytes with typical condensed, pyknotic nuclei and deeply shrunken cytoplasm (Figure 1F).

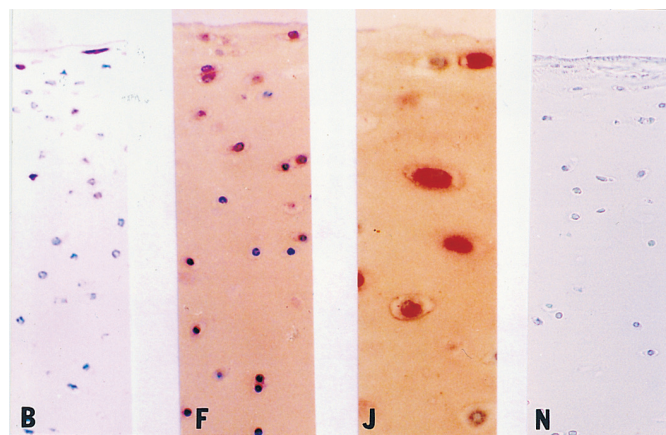
Localization of Bcl-2, Bax, Fas, and iNOS. Control cartilage samples contained very low numbers of Bcl-2, Bax, Fas, and iNOS-positive chondrocytes, which were almost exclusively located in the upper zone (Figures 2A–2D). In contrast, expression of Bcl-2, Bax, Fas, and iNOS was found throughout the KBD cartilage samples, and was prominent in the upper zone and middle zone (Figures 2E–2P).

Histomorphological analysis of apoptotic cells, Bcl-2, Bax, Fas, and iNOS in KBD cartilage. The percentage of apoptotic chondrocytes positively stained by TUNEL in the middle zone of KBD cartilage samples (33.60% ± 2.71%) was higher than that of controls (1.33% ± 0.41%; *p* < 0.01), while there was no difference between the 2 groups in the upper zone (Table 1). The percentage of apoptotic cells was also significantly higher in the middle zone than in the upper and deep

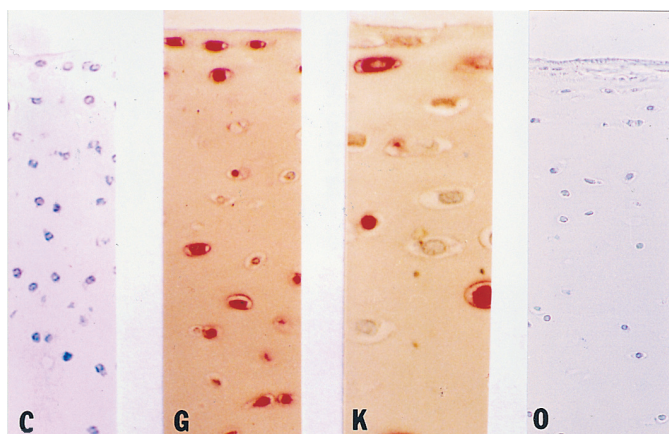
Figure 1. H&E staining (A, B, C) and TUNEL staining (D, E, F) of articular cartilage in fingers from a control patient (5-year-old male from a non-KBD area) and a KBD patient (4-year-old with clinical manifestations of first-degree KBD). A: Control deep zone cartilage shows no chondronecrosis. B: KBD deep zone cartilage shows large chondronecrotic areas without cells. C: Detail of B. D: Control middle zone cartilage shows no TUNEL-positive chondrocytes. E: KBD cartilage show occasional TUNEL-positive chondrocytes. F: Detail of E. (Original magnification A and D $\times 200$; B and E $\times 100$; C and F $\times 400$)



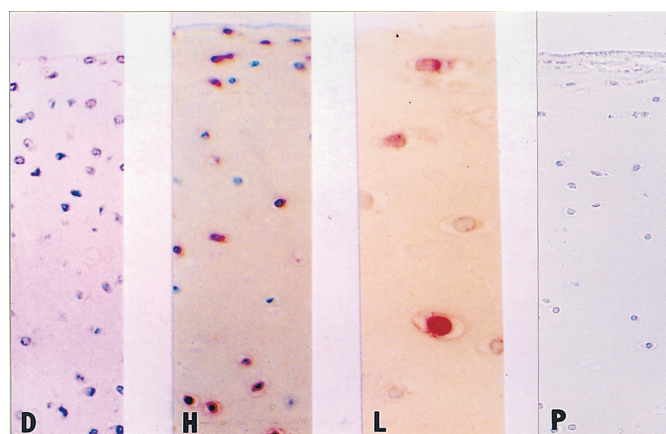
Panel 1: Staining for Bcl-2.



Panel 2: Staining for Bax.



Panel 3: Staining for Fas.



Panel 4: Staining for iNOS.

Figure 2. Immunohistochemical staining for Bcl-2, Bax, Fas, and iNOS as described in Materials and Methods. Representative sections of articular cartilage from fingers of control patients (A to D) and a KBD patient (4-year-old with clinical manifestations of first-degree KBD; E to P). Panel 1: A, E, and I: staining for Bcl-2. Panel 2: B, F, and J: staining for Bax. Panel 3: C, G, and K: staining for Fas. Panel 4: D, H, and L: staining for iNOS. A to D: Control cartilage shows low numbers of Bcl-2, Bax, Fas, and iNOS-positive chondrocytes, which were almost exclusively located in the upper zone. E to H: KBD cartilage shows strong cytoplasmic staining for Bcl-2, Bax, Fas, and iNOS, with maximal intensity in the upper and middle zone. I to L: Detail of E to H. M to P: Nonimmune serum-stained negative control for Bcl-2, Bax, Fas, and iNOS shows only background staining. (Original magnification A to H and M to P $\times 200$; I to L $\times 400$)

Table 1. Percentage of chondrocytes staining positive for apoptotic cells, Bcl-2, Bax, Fas, and iNOS in articular cartilage of KBD patients and the controls.

Groups	n	Upper Zone	Middle Zone	Deep Zone
Apoptotic cells				
Control	15	0.00 ± 0.00 ^a	1.33 ± 0.41 ^a	3.33 ± 0.82 ^a
KBD	15	0.00 ± 0.00 ^a	33.60 ± 2.71 ^{**b}	7.67 ± 2.41 ^{**a}
Bcl-2				
Control	15	2.47 ± 0.74 ^a	0.00 ± 0.00 ^a	0.07 ± 0.26 ^a
KBD	15	41.93 ± 12.26 ^{**a}	14.93 ± 3.50 ^{**b}	2.00 ± 0.85 ^{**c}
Bax				
Control	15	1.13 ± 0.35 ^a	0.00 ± 0.00 ^a	0.00 ± 0.00 ^a
KBD	15	45.60 ± 15.78 ^{**a}	13.87 ± 4.32 ^{**b}	0.00 ± 0.00 ^c
Fas				
Control	15	1.87 ± 0.83 ^a	0.00 ± 0.00 ^a	0.00 ± 0.00 ^a
KBD	15	53.60 ± 16.49 ^{**a}	23.27 ± 4.83 ^{**b}	5.60 ± 1.84 ^{**c}
iNOS				
Control	15	2.87 ± 0.92 ^a	0.00 ± 0.00 ^a	0.00 ± 0.00 ^a
KBD	15	45.47 ± 14.02 ^{**a}	21.67 ± 6.82 ^{**b}	5.67 ± 1.63 ^{**c}

p < 0.05 if letters a,b,c were different and p > 0.05 if letters were the same among zones by ANOVA. * p < 0.05;

** p < 0.01 among groups, t test.

zones in KBD cartilage (p < 0.01; Table 1). Histomorphometric analysis of Bcl-2, Bax, Fas, and iNOS distribution in KBD cartilage showed striking differences between the control and KBD samples, as well as between the different zones. Bcl-2, Fas, and iNOS-positive cells in the upper, middle, and deep zones of KBD cartilage were significantly more numerous than in controls (Table 1). In the upper and middle zones of KBD samples, the percentage of chondrocytes staining for Bax was significantly higher than in controls. Significant differences in Bcl-2, Bax, Fas, and iNOS expression among the upper, middle, and deep zones were also seen in KBD samples (p < 0.01), and staining for Bcl-2, Bax, Fas, and iNOS in KBD samples was prominent in the upper zone (41.93% ± 12.26%, 45.60% ± 15.78%, 53.60% ± 16.49%, and 45.47% ± 14.02%, respectively) and the middle zone (14.93% ± 3.50%, 13.87% ± 4.32%, 23.27% ± 4.83%, and 21.67% ± 6.82%) of articular cartilage.

DISCUSSION

We observed an increase of apoptotic chondrocytes in the middle zones of KBD articular cartilage samples in comparison to the control samples, suggesting the signal for apoptotic cell death had already occurred in the middle zone of articular cartilage in children with KBD. Compared to controls, Bcl-2, Bax, and Fas were expressed in enhanced amounts in the upper and middle zones, and iNOS expression was more abundant in the entire articular cartilage. This finding suggests the abnormal expression of molecules relevant to chondrocyte apoptosis in KBD cartilage.

There is increasing evidence that chondrocyte apoptosis and the regulation of chondrocyte-specific gene expression plays an important role in cartilage development, aging, and disease¹². Abnormal chondrocyte apoptosis can not only affect the development of bone and cartilage, but also lead to

achondroplasia and OA. Chondrocyte apoptosis is involved in the hypertrophic zone during the development of cartilage, which accounts for 5%–10% of chondrocytes¹³. We show evidence of apoptosis of chondrocytes in middle zone articular cartilage in KBD, except for multiple focal chondronecrotic areas in the deep cartilage zone of KBD samples. A diminished content of DNA (about 50%) and obvious reduction in tissue cellularity of articular cartilage and growth plate cartilage in children in the early stage of KBD have been observed¹⁴. Whether the reduction in cartilage may result from increased chondrocyte apoptosis or chondrocyte necrosis, however, remains to be investigated. The role of the extracellular matrix in the regulation of cell survival is also likely to be of importance in cartilage apoptosis. Type II collagen synthesized by chondrocytes, the major component of the extracellular matrix, was found to be decreased in the upper and middle zones in KBD articular cartilage samples¹⁵. The degradation of type II collagen was regarded as the loss of a survival signal, which was correlated with chondrocyte apoptosis¹⁶. We speculate that chondrocyte apoptosis is increased in patients with KBD, which may be associated with chondrocyte necrosis.

A number of specific proteins and protein families appear to play a role in regulating apoptosis. Bcl-2, Bax, Fas, and iNOS were investigated in this experiment. The protooncogene protein Bcl-2 protects cells from apoptosis and ensures their survival *in vitro* by inhibiting the action of the apoptosis inducer, Bax. We observed that Bcl-2 expression was strongly enhanced in the upper, middle, and deep zones of KBD articular cartilage in comparison to control cartilage. The enhanced Bcl-2 expression seen in KBD cartilage is similar to that in OA cartilage, which also has been shown to contain increasing amounts of Bcl-2 in lesional areas compared to non-lesional areas⁸. Upregulation of Bcl-2 may represent an

attempt to protect chondrocytes from apoptosis. Bcl-2 mRNA was reported to be upregulated in OA cartilage by Erlacher, *et al*¹⁷. Cell death and acceleration of Sindbis virus-induced apoptosis *in vitro* can be triggered by the carboxyl-terminal Bcl-2 cleavage product of caspase-3¹⁸. In other words, Bcl-2 conversion product might actually ensure the inevitability of cell death.

Bax, which is a member of the same protooncogene family as Bcl-2, can induce cell death by forming homocomplexes in a manner somewhat similar to that of transcription factors. The balance between Bax and Bcl-2 forms an apoptotic rheostat, and the level of this rheostat is a major determinant of sensitivity toward apoptosis. The pattern of immunohistochemical staining for Bax is similar to the results we found for Bcl-2, with a predominance in the upper zone and middle zone in comparison to the control cartilage from non-KBD areas. In contrast to OA, we found a significant difference in expression of Bax between KBD samples and controls. Chondrocyte apoptosis in KBD is coregulated by both Bax and Bcl-2, which may contribute to the chronic pathologic process in KBD.

It was reported by Hashimoto, *et al*¹⁹ that chondrocyte apoptosis in OA can be induced by nitric oxide (NO) and by antibodies to the Fas antigen. Agonistic antibody to Fas does not induce NO in chondrocytes, and Fas-induced apoptosis is not prevented by inhibitors of NO synthesis. The expression of iNOS was markedly increased in the entire KBD articular cartilage sample compared to normal cartilage, which was consistent with the high plasma concentration of NO in patients with KBD²⁰. In addition to the expression of iNOS, abundance of Fas expression in the upper, middle, and deep zones in KBD cartilage in comparison to normal tissue was also observed in our study.

We found apoptotic chondrocytes in the middle zone of samples of KBD articular cartilage; except chondrocyte necrosis in the deep zone occurred more frequently compared to the control cartilage. The increased expression of iNOS and Fas demonstrates the potential role of NO and Fas in induction of chondrocyte apoptosis in KBD.

REFERENCES

- Wang Z. Historical review of the research progression and the control in Kashin-Beck disease, China. *Chin J Endemiol* 1999;18:161-3.
- Xiong G. Diagnostic, clinical and radiological characteristics of Kashin-Beck disease in Shaanxi Province, PR China. *Int Orthop* 2001;25:147-50.
- Allander E. Kashin-Beck disease. An analysis of research and public health activities based on a bibliography 1849-1992. *Scand J Rheumatol Suppl* 1994;99:1-36.
- Peng A, Wang WH, Wang CX, et al. The role of humic substances in drinking water in Kashin-Beck disease in China. *Environ Health Perspect* 1999;107:293-6.
- Suetens C, Moreno RR, Chasseur C, et al. Epidemiological support for a multifactorial aetiology of Kashin-Beck disease in Tibet. *Int Orthop* 2001;25:180-7.
- Wang SHJ, Guo X, Zuo H. A study on chondrocyte apoptosis in selenium- and iodine-deficient rats. *Chin J Endemiol* 2006; (in press).
- Yang TF, Jia ZQ, Shen B. Effect of T-2 toxin on apoptosis of fetus chondrocytes. *Chin J Endemiol* 2001;20:84-6.
- Kim HA, Lee YJ, Seong SC, Choe KW, Song YW. Apoptotic chondrocyte death in human osteoarthritis. *J Rheumatol* 2000;27:455-62.
- Robert K, Schen K, Peter SE, et al. Articular cartilage morphology. In: Kuettner KE, Schleyerbach R, Hascall VC, editors. *Articular cartilage biochemistry*. New York: Raven Press; 1986:3-22.
- Mo DX. Histopathology of chondronecrosis in Kashin-Beck disease and its clinical significance. *Chinese J Control Endemic Dis* 1983;1:1-4.
- Sokoloff L. The history of Kashin-Beck disease. *NY State J Med* 1989;89:343-51.
- Aigner T, McKenna L. Molecular pathology and pathobiology of osteoarthritic cartilage. *Cell Mol Life Sci* 2002;59:5-18.
- Roach HI, Aigner T, Erenpeisa J. Osteogenic differentiation of hypertrophic chondrocytes involves asymmetric cell divisions and apoptosis. *J Cell Biol* 1995;131:483-94.
- Yang TS, Hou LZ, Li FS. Biochemical characteristics of Kashin-Beck disease. In: *Proceedings of the International Workshop on Kashin-Beck Disease and Non-communicable Diseases*. Beijing: World Health Organization; 1990:116-28.
- Guo X, Aigner T, Lammi P, et al. A study on abnormal chondrocyte differentiation and abnormal expression of collagen types in AC from patients with Kashin-Beck disease. *Chin J Pathology* 1998;27:19-21.
- Yang C, Li SW, Helminen HJ, Khillan JS, Bao Y, Prockop DJ. Apoptosis of chondrocytes in transgenic mice lacking collagen II. *Exp Cell Res* 1991;235:163-8.
- Erlacher L, Maier R, Ulrich R, et al. Differential expression of the protooncogene bcl-2 in normal and osteoarthritic human articular cartilage. *J Rheumatol* 1995;22:926-31.
- Cheng EH, Kirsch DG, Clem RJ, et al. Conversion of Bcl-2 to a Bax-like death effector by caspases. *Science* 1997;278:1966-8.
- Hashimoto S, Takahashi K, Amiel D, Coutts RD, Lotz M. Chondrocyte apoptosis and nitric oxide production during experimentally induced osteoarthritis. *Arthritis Rheum* 1998;41:1266-74.
- Zhang BD, Guo X, Bai GK, et al. The changes of nitric oxide, NO synthase and sFas/Apo-1 in serum among the patients with Kashin-Beck disease. *Chin J Endemiol* 2004;31:172-5.