

Geode of the Femur: An Uncommon Manifestation Potentially Reflecting the Pathogenesis of Rheumatoid Arthritis

WONUKEE LEE, MICHAEL R. TERK, BING HU, ELAYNE K. GARBER, and MICHAEL H. WEISMAN

ABSTRACT. Geodes are noted frequently in rheumatoid arthritis (RA), but large geodes of the femur are uncommon. We describe a patient with RA and a large geode in his femur; histological findings were consistent with a rheumatoid nodule and chronically inflamed synovium. We review the literature of large femoral geodes and what this particular manifestation may reflect about the pathogenesis of RA. (First Release Oct 15 2006; J Rheumatol 2006;33:2541-4)

Key Indexing Terms:

RHEUMATOID ARTHRITIS SUBCHONDRAL CYST HIP JOINT RHEUMATOID NODULE

Geodes are regarded as common and typical manifestations of rheumatoid arthritis (RA). These subchondral radiolucent lesions have also been referred to as subchondral cysts, rheumatoid pseudocysts, and bone cysts, with some controversy over the appropriate nomenclature that best describes them¹. The terms cyst and pseudocyst are not wholly accurate due to the absence of an epithelial lining and the nonuniformity of the contents of the lesions². The word “geode” is originally a geologic term defined in the Merriam-Webster dictionary as “a nodule of stone having a cavity lined with crystals or mineral matter” or “the cavity in a geode,” and was initially favored by Resnick, *et al* because of the inaccuracy of the above terms². We also have chosen to use the term geode, as it reflects more generally the radiographic appearance and does not presume any of the pathological characteristics of these lesions. We encountered a patient with RA who was found to have a large geode in his femur. Such cases of large geodes in the femur in the setting of RA have only been reported a few times in the literature. We describe our case, review the literature on large geodes of the femur in RA, and discuss these lesions in the context of our current understanding of theories of pathogenesis of certain manifestations of RA.

CASE REPORT

A 57-year-old Hispanic man with a 25 year history of seropositive RA

From the Division of Rheumatology, Department of Radiology, and Department of Pathology, Cedars-Sinai Medical Center, Los Angeles, California, USA.

W. Lee, MD, Fellow, Division of Rheumatology; M.R. Terk, MD, Chief, Musculoskeletal Imaging; B. Hu, MD, Department of Pathology; E.K. Garber, MD; M.H. Weisman, MD, Chief, Division of Rheumatology.

Address reprint requests to Dr. M.H. Weisman, Division of Rheumatology, Cedars-Sinai Medical Center, 8700 Beverly Blvd., B-131, Los Angeles, CA 90048. E-mail: Michael.weisman@cshs.org

Accepted for publication July 7, 2006.

(rheumatoid factor and anti-cyclic citrullinated peptide antibody-positive) presented with a 2 month history of worsening left hip pain. He denied any history of trauma to his hip, overuse, increased activity, or other inciting event and had no history of hip fractures, injuries, or surgeries. His morning stiffness duration was 30 minutes, and besides his hip, he complained only of mild hand pain. He had previously undergone bilateral knee replacements and bilateral metacarpophalangeal (MCP) implants. His medications included methotrexate 17.5 mg by mouth every week, adalimumab 40 mg subcutaneously every 2 weeks, folate 1 mg a day, alendronate 70 mg a week, and diclofenac 75 mg three times a day as needed. Besides RA, his history included osteoporosis and a positive tuberculin skin test status post-isoniazid therapy. He admitted to smoking 1 to 3 cigarettes a day for the last 15 years and occasional alcohol use.

On examination, he was afebrile and his vital signs were stable. His shoulders were slightly limited in range of motion in forward flexion and lateral abduction, but there was no apparent swelling or tenderness. His elbows had 15° of flexion contracture, but no nodules, swelling, or tenderness. His wrists were fused with mild swelling and tenderness. His fingers displayed bilateral ulnar deviations, scars overlying bilateral MCP, and mild tenderness of bilateral 2nd to 5th MCP. Both of his hips had full range of motion with only minimal discomfort upon internal rotation of the left hip. His knees, ankles, mid-foot, and metatarsophalangeal joints were without swelling or tenderness. His erythrocyte sedimentation rate was 93. Besides a hemoglobin of 12 g/dl, his complete blood count was within normal limits, as were his electrolytes, creatinine, and liver function tests. A radiograph of his left hip revealed a large, lytic-appearing lesion within the left femoral head and neck that was estimated to be 4 × 8 cm, but the hip joint space was preserved (Figures 1 and 2). Magnetic resonance imaging (MRI) of the left hip showed a 6.2 × 4.2 × 2.8 cm well-circumscribed lesion in the femoral neck that terminated at the intertrochanteric line, violated the anterior cortex of the femoral neck, and was in continuity with the synovium. MRI images with fat suppression revealed the lesion to be internally complex in the femoral neck and head (Figures 3 and 4).

He was taken for surgery by the orthopedic physician for exploration of the lesion based on the suspicion that this was a malignant process. Intraoperatively, the left hip joint was described as having “massive amounts of synovium,” denuded cartilage on both sides of the joint, and a large mass within the femoral neck. Biopsies of both the synovium and the mass within the femoral neck were done, and a total hip joint replacement was performed. Histology of the synovial biopsies revealed chronic synovitis with irregular areas of zonal fibrinoid necrosis and infiltrating inflammatory cells (Figure

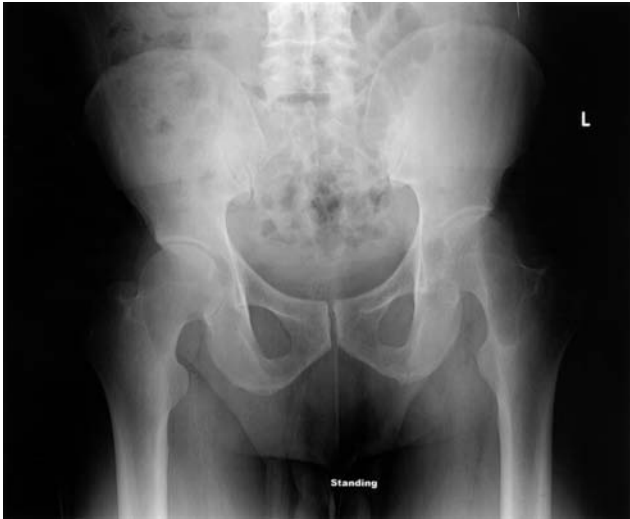

Figure 1. Radiograph of the pelvis shows the sharply marginated left femoral neck lesion without sclerotic margins.

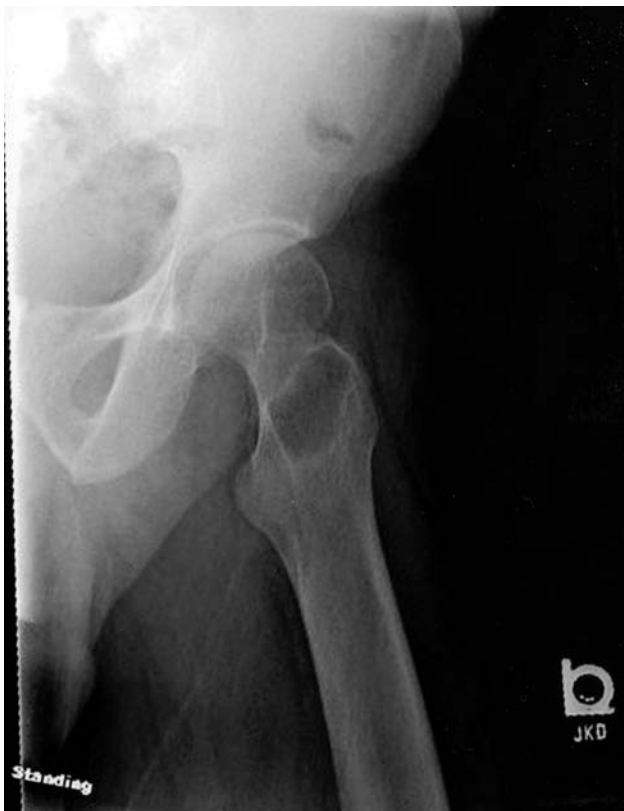

Figure 2. Radiograph of the left hip shows the large lesion within the neck of the femur to be sharply marginated with a mildly sclerotic border and a narrow zone of transition.

5). Histology of the mass within the femoral neck showed areas consistent with rheumatoid nodule formation, with fibrinoid necrosis and surrounding inflammatory cells, as well as areas of synovial tissue with chronic synovitis (Figure 6). Gross pathology revealed synovial hyperplasia, with the exterior bone surface showing no eburnation or osteophytes. The interior aspect of the femoral neck leading into the femoral head had a hollow, shelled-out, smooth-

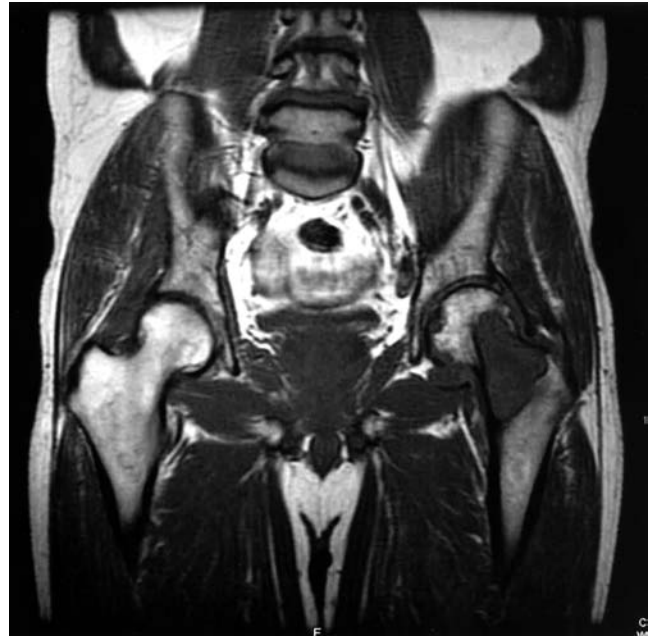

Figure 3. Coronal MRI of the pelvis shows a large lesion of the left femoral neck and head with uniform intermediate signal (coronal noncontrast T1 weighted image; TR/TE 500/9; 512 × 512; 1 NEX; 1.5 Tesla).

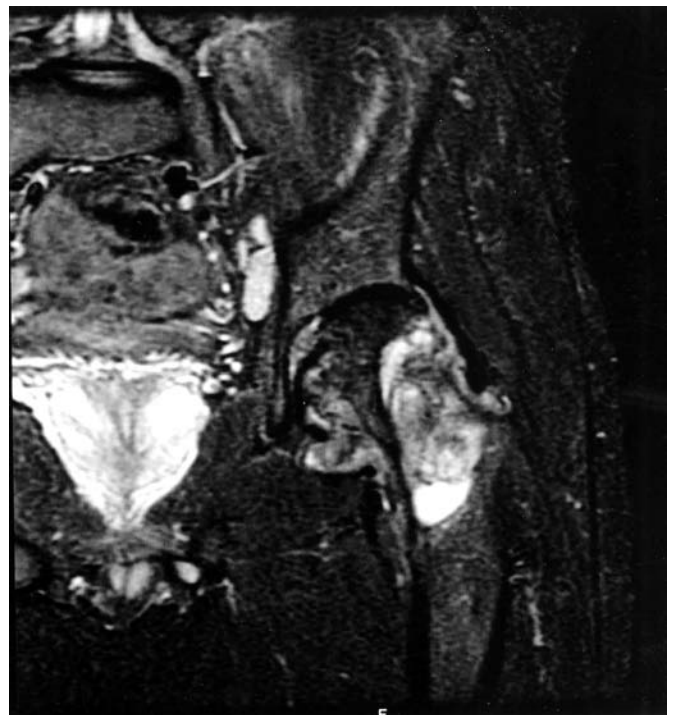

Figure 4. Coronal MRI of the left hip shows the lesion to be internally complex in the femoral neck and head with violation of the cortex (coronal non-contrast STIR image; TR/TI/TE 3717/140/42; 512 × 512; 2 NEX; 1.5 Tesla).

lined cystic area that measured 3.5 × 2.8 × 2.0 cm. He had an uneventful recovery and was discharged home.

Previously reported cases. Hunder, *et al* published the first case report of a large hip geode in 1965³. They described a 58-year-old woman who had RA

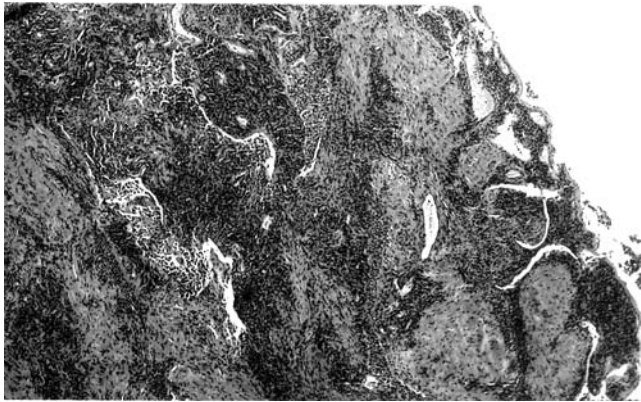


Figure 5. Chronic synovitis with irregular areas of zonal fibrinoid necrosis and infiltrating inflammatory cells.




Figure 6. Rheumatoid nodule with fibrinoid necrosis and surrounding inflammatory cells.

for 11 years and a 2.5 cm lesion in her femur. Histology of the lesion revealed partially necrotic granulation tissue. Their patient, like ours, had minimal hip pain, and the hip joint space was only moderately narrowed.

Colton and Darby reported large femoral geodes in 2 patients with RA who had associated pathological fractures⁴. The histology of those lesions was described as rheumatoid granulation tissue. They noted that in both cases there was no history of hip pain until the fractures occurred, and radiographs of the hips revealed only minimal evidence of hip joint arthritis.

Magyar, *et al* described 7 RA patients with large geodes, but only one of the cases involved the femur⁵. The other geodes were in the tibia, ulna, metatarsals, metacarpals, and humerus. On histological examination, 3 of the 7 cases were described as having findings of “granulation tissue with appearances resembling synovium affected by rheumatoid arthritis,” and 2 of the cases were described as intraosseous rheumatoid nodules. The single patient with a hip geode did have severe pain and severe narrowing of the joint space on radiographs. The investigators noted that several of the lesions were without apparent connection to the joint space, and thus proposed a possible division of these lesions into those that communicate with the joint cavity and those that do not.

Morrey described a patient with a large geode that involved the femoral neck, but there was a normal joint space, normal articular cartilage, and no surrounding synovitis⁶. This patient did have preceding hip pain that was worse with activity. He was found to have a pathologic fracture at the site of the geode, and histology of the geode was reported as nonspecific inflammatory fibrous tissue.

Resnick, *et al* examined 80 femoral heads from total hip replacements and 10 cadaveric hip joints for geodes². Of these 90 hips, 13 were from patients with RA; 10 of the 13 had geodes ≥ 2 mm diameter, and the range of sizes was from 1 mm to 35 mm. Radiographically defined geodes in RA were unique in that they did not have sclerotic margins. The investigators further noted that the geodes communicated with the joint space and histologically were consistent with “pannus.” No intraosseous rheumatoid nodules were observed in their study. Table 1 provides a summary of the reported femoral geodes in RA.

DISCUSSION

Although geodes in general are common in RA, such large geodes of the femur are unusual. Putting our case together with the previous reports, we see that patients with large geodes are often without significant hip pain and can have well preserved hip joint space on radiographs, despite the presence of a large geode. As illustrated in the case reported by Morrey⁶, these geodes can exist even with normal hip joint cartilage and no surrounding synovitis. In our case, however, the patient had an exuberance of synovitis in the hip joint and the cartilage was denuded from both sides of the joint. It is likely that the presence of this massive synovitis accounted for the normal hip joint space on our patient’s plain radiograph. Of note, the use of MRI helped in our case to define the lesion, and this is the first reported case of a large femoral geode in RA to have used MRI to help delineate the lesion. Further, these patients are at risk for pathologic fractures through these lesions, and surgical treatment is often indicated.

As described by Magyar, *et al*⁵, geodes have been observed both to communicate with the joint space and also to be isolated from the joint space. Histologically, the reports of femoral geodes state that the geodes contained rheumatoid granulation tissue or pannus. Intraosseous rheumatoid nodules have also been reported, but not from femoral geodes⁵. In our patient, there was evidence by MRI of connection between the joint space and the geode; the histology showed inflamed, necrotic synovium as well as tissue consistent with rheumatoid nodule formation. Altogether, these findings suggest 2 distinct possibilities — that these geodes can begin primarily in the bone, as a rheumatoid nodule, without connection to the joint space, and alternatively, that they may be the result of aggressive pannus invasion from the joint space across the bone cortex.

Classically, rheumatoid nodules are associated with a collection of predisposing as well as clinical findings — local trauma, rheumatoid factor positivity, a palisaded layer of macrophages, and central fibrinoid necrosis⁷. Thus, rheumatoid nodules are generally regarded to be the result of an insult, probably coming from the bloodstream, leading to small-vessel vasculitis with resultant central fibrinoid necrosis and surrounding fibroblastic proliferation⁸. The definition of

Table 1. Summary of reported large femoral geodes in patients with RA.

Study	No. of Cases	Age, yrs, Sex	Duration of Disease, yrs	Size of Lesion	Histology Description
Hunder ³	1	58 F	11	2.5 cm diameter	Partially necrotic granulation tissue
Colton ⁴	2	66 M, 63 M	33, 6	2.5 cm diameter "width of femoral neck"	Rheumatoid granulation tissue
Magyar ⁵	1	50 F	9	2 cm	Granulation tissue, resembling synovium affected by RA
Resnick ²	10	NA	NA	2 to 3.5 cm	Pannus
Morrey ⁶	1	66 M	> 3	"extensive"	Nonspecific fibrous tissue

NA: not available.

pannus, on the other hand, is frequently equated with chronic synovitis, and as well is often considered a "specialized vascular connective tissue at or near the bone-synovium interface"⁹, and is felt to be the primary source for the joint destruction in RA. In these femoral geodes we observe evidence for the presence of both rheumatoid nodules and pannus formation.

There have been reported cases of "cystic RA" in which RA patients are noted to display geodes and nodules, but no joint synovitis or significant erosions¹⁰⁻¹². Further, several MRI studies of hand and wrist geodes have revealed that geodes can often begin in an intraosseous location and subsequently form connections to the joint space¹³⁻¹⁵. Certainly, the relationship between the bone marrow and the synovium in RA is still incompletely elucidated in terms of the primary event for joint destruction, and the possibility of primary bone marrow involvement in the initiation of RA remains controversial¹⁶⁻¹⁸. The presence of this large geode, with its histologic features of rheumatoid nodule formation and chronic synovitis, located in the bone of a patient with classical RA, may be a function of this as yet undefined connection between the bone marrow and synovial membrane in the pathogenesis of RA.

REFERENCES

- Gardner DL. Geode: crystal-containing cavity, lymph space, or pseudocyst? *Ann Rheum Dis* 1985;44:569-70.
- Resnick D, Niwayama G, Coutts RD. Subchondral cysts (geodes) in arthritic disorders: pathologic and radiographic appearance of the hip joint. *AJR Am J Roentgenol* 1977;128:799-806.
- Hunder GG, Ward LE, Ivins JC. Rheumatoid granulomatous lesion simulating malignancy in the head and neck of the femur. *Mayo Clin Proc* 1965;40:766-70.
- Colton CL, Darby AJ. Giant granulomatous lesions of the femoral head and neck in rheumatoid arthritis. *Ann Rheum Dis* 1970;29:626-33.
- Magyar E, Talerman A, Feher M, Wouters HW. Giant bone cysts in rheumatoid arthritis. *J Bone Joint Surg Br* 1974;56:121-9.
- Morrey BF. Rheumatoid pseudocyst (geode) of the femoral neck without apparent joint involvement. *Mayo Clin Proc* 1987;62:407-11.
- Ziff M. The rheumatoid nodule. *Arthritis Rheum* 1990;33:761-7.
- Matteson EL. Extra-articular features of rheumatoid arthritis and systemic involvement. In: Hochberg MC, Silman AJ, Smolen JS, Weinblatt ME, Weisman MH, editors. *Rheumatology*. 3rd ed. Vol. 1. New York: Elsevier; 2003:781.
- Zvaifler NJ, Firestein GS. Pannus and pannocytes. Alternative models of joint destruction in rheumatoid arthritis. *Arthritis Rheum* 1994;37:783-9.
- Ginsberg MH, Genant HK, Yu TF, McCarty DJ. Rheumatoid nodulosis: an unusual variant of rheumatoid disease. *Arthritis Rheum* 1975;18:49-58.
- Gubler FM, Maas M, Dijkstra PF, de Jongh HR. Cystic rheumatoid arthritis: description of a nonerosive form. *Radiology* 1990;177:829-34.
- Morales-Piga A, Elena-Ibanez A, Zea-Mendoza AC, Rocamora-Ripoll A, Beltran-Gutierrez J. Rheumatoid nodulosis: report of a case with evidence of intraosseous rheumatoid granuloma. *Arthritis Rheum* 1986;29:1278-83.
- Gubler FM, Algra PR, Maas M, Dijkstra PF, Falke TH. Gadolinium-DTPA enhanced magnetic resonance imaging of bone cysts in patients with rheumatoid arthritis. *Ann Rheum Dis* 1993;52:716-9.
- Moore EA, Jacoby RK, Ellis RE, Fry ME, Pittard S, Vennart W. Demonstration of a geode by magnetic resonance imaging: a new light on the cause of juxta-articular bone cysts in rheumatoid arthritis. *Ann Rheum Dis* 1990;49:785-7.
- Tehranzadeh J, Ashikyan O, Dascalos J, Dennehey C. MRI of large intraosseous lesions in patients with inflammatory arthritis. *AJR Am J Roentgenol* 2004;183:1453-63.
- Bugatti S, Caporali R, Manzo A, Vitolo B, Pitzalis C, Montecucco C. Involvement of subchondral bone marrow in rheumatoid arthritis: lymphoid neogenesis and in situ relationship to subchondral bone marrow osteoclast recruitment. *Arthritis Rheum* 2005;52:3448-59.
- Gortz B, Hayer S, Redlich K, et al. Arthritis induces lymphocytic bone marrow inflammation and endosteal bone formation. *J Bone Miner Res* 2004;19:990-8.
- Kishimoto Y, Fukumoto S, Nishihara S, Mizumura H, Hirai K, Teshima R. Gene expression relevant to osteoclastogenesis in the synovium and bone marrow of mature rats with collagen-induced arthritis. *Rheumatology Oxford* 2004;43:1496-503.