

# Bone Involvement in Generalized Crystal-Storing Histiocytosis

VICTOIRE de LASTOURS, THOMAS PAPO, DOMINIQUE CAZALS-HATEM, AURÉLIA EDEN, ANTOINE FEYDY, NADIA BELMATOUG, MARIE-PAULE CHAUVEHEID, OLIVIER LIDOVE, and BRUNO FANTIN

**ABSTRACT.** The abnormal secretion of monoclonal immunoglobulins observed with monoclonal gammopathies and other clonal B cell dyscrasias can be responsible for a spectrum of deposition disorders. Crystal-storing histiocytosis (CSH) is a rare disease affecting patients with B cell dyscrasias and monoclonal gammopathies, characterized by the accumulation of histiocytes that have phagocytosed an abnormal crystalline immunoglobulin. We describe 2 cases of this rare disorder with multiorgan involvement and prominent bone involvement. Magnetic resonance imaging showed bone marrow infiltration and images of avascular necrosis. Bone specimen analysis gave histological proof of diffuse bone infiltration by the abnormal histiocytes. Bone involvement, which appears to be a specific feature of CSH, links this entity to other storage disorders, such as Gaucher disease. Because the accumulation of abnormal immunoglobulin-loaded histiocytes is clearly pivotal, CSH should be considered not only as an immunoglobulin deposition disease but also as a storage histiocytic disorder. (*J Rheumatol* 2006;33:2354–8)

*Key Indexing Terms:*

GENERALIZED CRYSTAL-STORING HISTIOCYTOSIS  
GAUCHER DISEASE

BONE INFILTRATION  
STORAGE DISORDER

Crystal-storing histiocytosis (CSH) is a rare deposition disorder, characterized by the property of abnormal immunoglobulin to undergo crystallization, after its phagocytosis by macrophages and the accumulation of these loaded histiocytes in various tissues. Disorders associated with CSH include multiple myeloma, monoclonal gammopathies of undetermined significance, lymphoplasmacytic lymphoma and more rarely mucosa-associated lymphoid tissue lymphoma, and amyloidosis. To our knowledge, no case of significant bone involvement in CSH has been described to date.

We describe 2 cases of generalized multiorgan CSH with clinical, radiological, and histological evidence of massive bone infiltration associated with avascular necrosis.

## CASE REPORTS

*Case 1.* A 49-year-old Black man with no notable history was admitted for fatigue and weight loss. For 3 years before admission he had experienced

---

*From the Department of Internal Medicine and Department of Pathology, Beaujon Hospital, Clichy; and Department of Internal Medicine and Department of Radiology, Bichat Hospital, Paris, France.*

*V. de Lastours, MD, Department of Internal Medicine, Beaujon Hospital, Department of Internal Medicine, Bichat Hospital; T. Papo, MD, Professor; A. Eden, MD; M-P. Chauveheid, MD; O. Lidove, MD, Department of Internal Medicine, Bichat Hospital; D. Cazals-Hatem, MD, Department of Pathology, Beaujon Hospital; A. Feydy, MD, PhD, Department of Radiology, Bichat Hospital; N. Belmatoug, MD; B. Fantin, MD, PhD, Professor, Department of Internal Medicine, Beaujon Hospital.*

*Address reprint requests to Dr. V. de Lastours, Internal Medicine Department, Beaujon Hospital, 100 Bd Général Leclerc, 92110 Clichy, France. E-mail: vdelastours@hotmail.com*

*Accepted for publication May 29, 2006.*

asthenia, weight loss (15 kg in 12 mo) and deep pain in both thighs. Progressive loss of vision and polyarthralgia developed, while the pain in his legs got worse. Three weeks before admission he noted a facial asymmetry.

On examination, the patient was cachectic. He had a complete left peripheral facial palsy and hepatomegaly and the tip of the spleen was palpable. Both corneas were thickened and white. Red and white blood cell counts were normal. C-reactive protein (CRP) concentration was 14 mg/l. Serum ferritin level was 1900 ng/l (normal < 300 ng/ml). Liver enzymes, lactate dehydrogenase, glucose, and creatinine blood levels were all in the normal range. Twenty-four hour urine collection contained 1 g protein. Urine glucose level was 20.3 mmol/l. Serum protein immunoelectrophoresis showed a monoclonal IgG kappa component of 1250 mg/dl. Other serum immunoglobulin values were normal. Cerebrospinal fluid protein level was 115 mg/dl, with no cells.

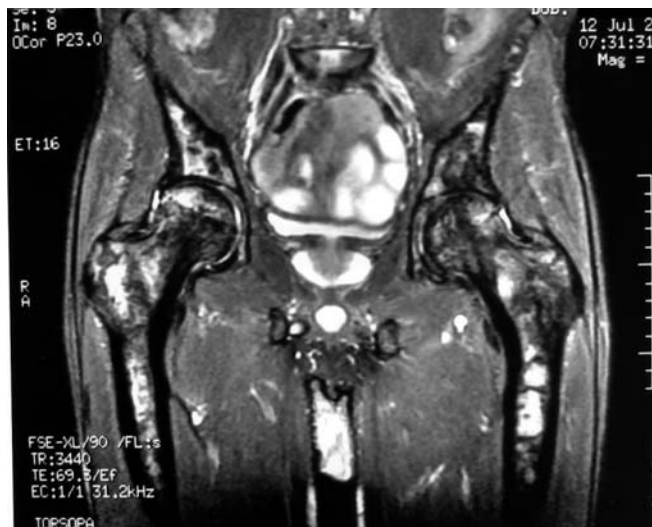Bone marrow aspirate showed an accumulation of abnormal histiocytes loaded with a crystalline needle-like material. Rare nondysmorphic plasma cells (2%) were present, some containing the same intracytoplasmic inclusions. Microscopic analysis of a liver specimen showed normal hepatic architecture, with diffuse sinusoidal infiltration of histiocytes loaded with crystalline material. On immunohistochemistry study, the large cells infiltrating the hepatic sinusoids showed a strong cytoplasmic expression of CD68, proving their histiocytic expression. Cytoplasmic crystals were positive for anti-kappa light chain on staining.

Histologic specimen analysis thus confirmed the diagnosis of multiorgan CSH associated with a monoclonal gammopathy of unknown significance (MGUS).

Hip and femur radiographs showed images of avascular necrosis of both heads and distal shafts of femurs, confirmed by magnetic resonance imaging (MRI) studies as being recent, and less recent bone infarction (Figure 1). A bone <sup>99</sup>Tc scintiscan found diffuse heterogeneous medullary increased uptake suggesting a storage disorder.

The patient died shortly after diagnosis of an unexplained shock with multiorgan failure. Microbiological tests were all negative.

*Case 2.* A 72-year-old woman from Algeria was diagnosed with ascites after



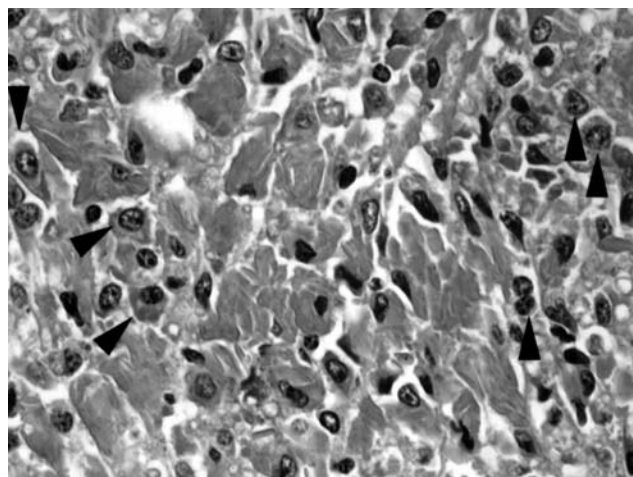
**Figure 1.** Coronal fat-saturated T2-weighted MR image of Patient 1 showing heterogeneous signal of bone marrow of femurs and iliac bones, and avascular necrosis of both heads of femurs.

a 3-year long history of asthenia, anorexia, weight loss, sweats and fever, epigastric pain, and deep bone pain in both legs. Examination revealed large volume ascites. She complained of symmetrical permanent pain in both thighs and lower legs. There was no arthritis or amyotrophy, and neurological examination was otherwise normal. Hemoglobin was 8.3 g/dl; white cell and platelet counts were normal. Creatinine clearance was 28 ml/min, CRP was 26 mg/l, and serum ferritin was 830 ng/ml. Liver biological tests and lactate dehydrogenase levels were within normal range. Plasma chitotriosidase levels were 46 times the upper value. Serum protein electrophoresis showed low gammaglobulins and a monoclonal spike measured in the betaglobulins at 1400 mg/dl, identified as IgA kappa on immunoelectrophoresis. Twenty-four hour urine collection contained 1.8 g protein, including a monoclonal spike of IgA kappa. Paracentesis was performed and peritoneal fluid analysis showed 4.4 g/dl protein content, low triglyceride levels, and 130 cells/ml (61% macrophages, 24% neutrophils, 10% lymphocytes) with no malignant cells, microorganisms, or mycobacteria. A monoclonal IgA kappa spike was also found in the peritoneal fluid.

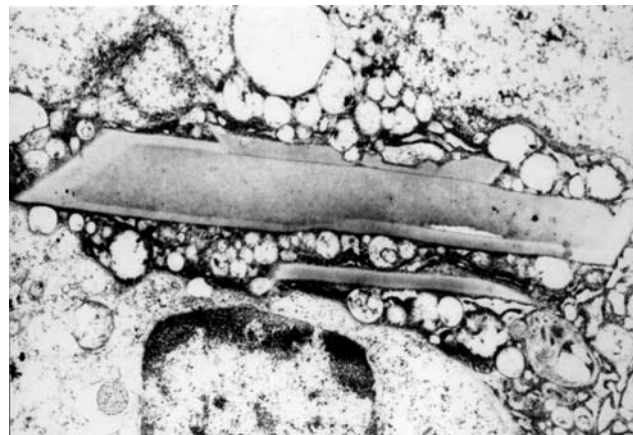Bone marrow aspirate showed malignant plasmacytosis with 22% dysmorphic plasma cells. Bone marrow biopsy showed interstitial infiltrate of crystal-storing histiocytes, which represented 30% of cells. Twenty percent of atypical plasma cells were admixed with histiocytes (Figure 2A), some of them with the same crystalloid material in their cytoplasm. Liver specimen analysis showed diffuse sinusoidal infiltration of crystal-storing histiocytes. Analysis of the peritoneal specimens also showed crystal-storing histiocytes infiltrating the conjunctive tissue. Ultrastructural electron microscopy studies revealed crystalline arrays in histiocytic cells. Crystals were geometrical, rectangular or cylindrical in configuration, and in close contact with vesicles of secondary lysosomes. As in Case 1, anti-kappa light chain staining was positive on the cytoplasmic crystals. The crystal substance exhibited fine linear striations (Figure 2B). IgA kappa-type multiple myeloma complicated with generalized crystal-storing histiocytosis was diagnosed.

<sup>99m</sup>Tc bone scintigram revealed symmetrical increased activity in the distal shafts of the femurs and tibias (Figure 3A). MRI showed images of semicircular avascular necrosis of bone marrow in the same areas (Figure 3B).

Treatment with melphalan and prednisolone for 6 months was ineffective on the general status and refractory ascites, while the monoclonal spike was stable. Thalidomide treatment was attempted but was stopped because of pancytopenia. Supportive treatment was started. A year after diagnosis, the patient experienced aseptic osteonecrosis of the right femoral head. Histological study of the femoral head after hip replacement found diffuse



**A**



**B**

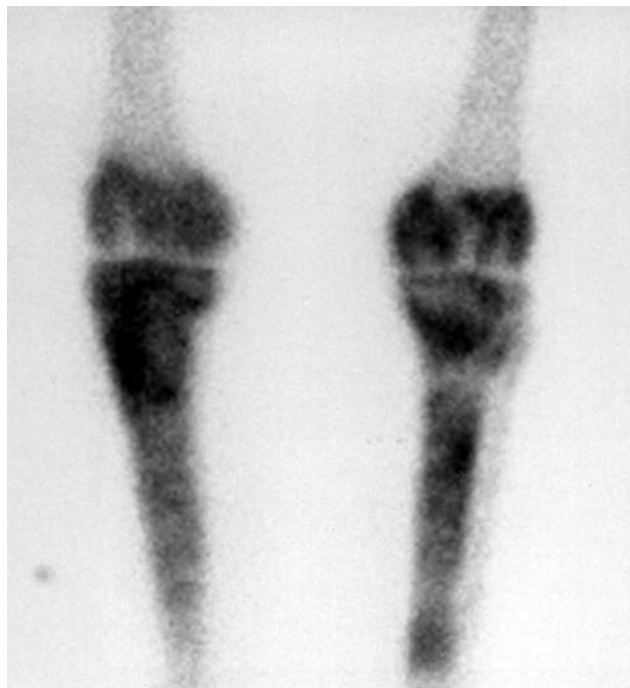**Figure 2.** A. Bone marrow section (Patient 2) shows large aggregates of crystal-storing histiocytes (arrowheads), mixed with neoplastic plasma cells (original magnification  $\times 100$ , H&E stains). B. Electron micrograph from liver tissue shows a sinusoidal histiocyte containing rectangular deposits in the cytoplasm in close contact with secondary lysosome vesicles (Patient 2).

infiltration with crystal-storing histiocytes. The patient is still alive 6 years after the diagnosis.

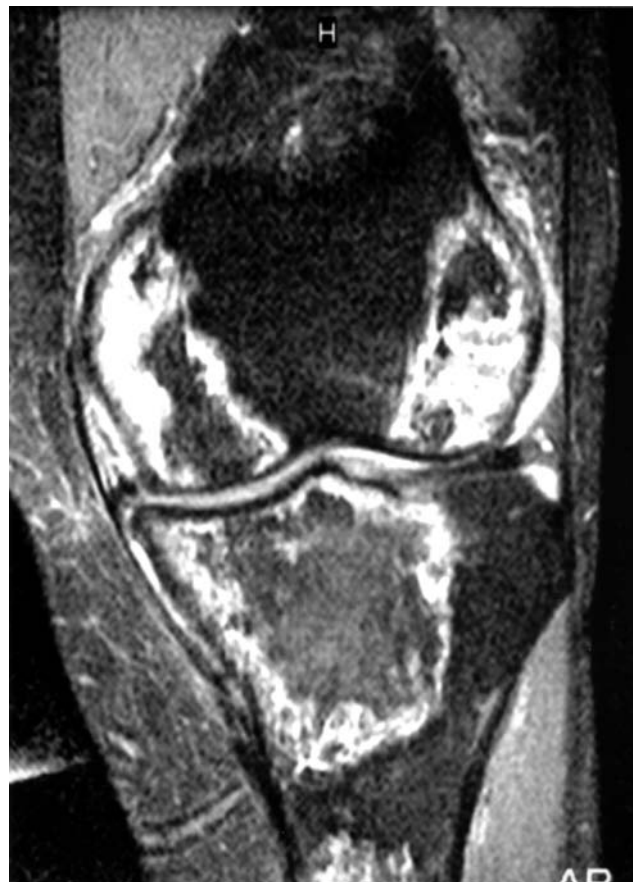## DISCUSSION

The abnormal secretion of monoclonal immunoglobulins observed with monoclonal gammopathy of unknown significance, multiple myeloma, or other clonal B cells dyscrasias can be responsible for a spectrum of various deposition disorders.

AL amyloidosis is an extracellular deposition of fibrils known as amyloid substance that consists of incomplete monoclonal lambda or kappa light chains. Many organs can be involved, but kidney and heart involvement are the most serious. Diagnosis is confirmed with light (using Congo red stain) or electronic microscopy of involved organ(s)<sup>1</sup>. Much less frequently, non-congophilic extracellular deposits of immunoglobulins are seen in monoclonal immunoglobulin deposition disorders involving entire light chains, heavy chains or both<sup>2</sup>.



A



B

Figure 3. A. Bone  $^{99}\text{Tc}$  scintiscan of the knees of Patient 2 shows heterogeneous increased uptake of both distal shafts of the femurs and proximal shafts of the tibias, suggestive of avascular bone necrosis. B. Coronal fat-saturated proton density-weighted MR image of the left knee shows extensive lesions of the distal femur and proximal tibia. The periphery of these well defined abnormal areas appears in high signal, while the center is in low signal.

Cryoglobulinemia is an extracellular but intravascular precipitation of immunoglobulins at cold temperature, which can be either monoclonal or polyclonal or both. *In vivo* crystallization of immunoglobulins has also been described, as in crystal-cryoglobulinemia, a rare complication of B cell dyscrasias often associated with type 1 monoclonal cryoglobulinemia. This disease is characterized by intravascular or tissue formations of large immunoglobulin crystals without specificity for either light or heavy isotype. The mechanisms of crystal formation are not well understood<sup>3</sup>.

Intracellular crystallization of immunoglobulins has been described predominantly in patients with B cell dyscrasias. In most cases, the crystalline inclusions were observed inside proliferating cells — plasma cells in multiple myeloma, lymphocytes in other lymphoproliferative diseases — but they were also found in many other cell and tissue types, including epithelial cells, thyroid and parotid glands, and cornea<sup>4</sup>. Cytoplasmic crystals within renal tubular cells are responsible for the Fanconi syndrome and express kappa light chain<sup>5</sup>.

In our 2 cases, systemic CSH was associated with a monoclonal gammopathy expressing kappa light chain, related to a

monoclonal gammopathy of undetermined significance and to an indolent multiple myeloma, respectively. In both cases bone involvement was prominent, with imaging and histological evidence of diffuse bone marrow infiltration.

CSH is a rare disorder, characterized by the accumulation of crystal-laden histiocytes in different tissues. To date, about 40 cases have been reported, mainly in patients with lymphoproliferative disorders: monoclonal gammopathy of undetermined significance, multiple myeloma, and lymphoplasmacytic lymphoma<sup>4,6</sup>. A few cases have also been described in patients with high serum polyclonal immunoglobulin concentrations<sup>7</sup>. The mechanism for crystallization remains unclear<sup>4,7,8</sup>. Immunoglobulin overproduction is probably not the only factor involved since the disease has been reported with very low serum levels of monoclonal paraprotein. Moreover, disease severity is not linked to the levels of secreted paraprotein, nor to the severity of the underlying hemopathy, as in our patients<sup>4</sup>.

Histological diagnosis of CSH may be difficult. Ultrastructural electron microscopy analysis as well as immunofluorescence are useful to rule out other histiocytic

disorders, and in particular Gaucher disease<sup>9</sup>. Indeed, the pathological cells in CSH have been confused with Gaucher cells, leading some investigators to describe them as “pseudo-pseudo-Gaucher cells”<sup>9,10</sup>. The crystalline inclusions differ from both glucocerebrosidase-storing Gaucher cells and the so-called pseudo-Gaucher cells that can be observed in chronic myelogenous leukemia (CML) and thalassemia<sup>9</sup>. So-called pseudo-pseudo-Gaucher cells of CSH can be differentiated from those of Gaucher disease and CML by their refractile eosinophilic crystals with hematoxylin-eosin stain. Due to the hydrophobic properties of these crystals, routine staining with eosin yields bright fluorescence under ultraviolet light, another distinguishing feature. Electron microscopy in Gaucher disease reveals tubular structures, compared to the rhomboid to needle-like membrane-bound inclusions of CSH<sup>9</sup>. Immunostaining with CD68 is essential to differentiate histiocytes from other cell types. The intracytoplasmic crystals are reactive to anti-immunoglobulin immunostaining. In most cases, a light chain is expressed, with a large preponderance of kappa-type light chain as found in Fanconi syndrome<sup>5</sup> and light chain deposition disease<sup>2</sup>, but unlike primary amyloidosis, which is usually associated with lambda light chain component<sup>1</sup>. Since macrophages do not synthesize immunoglobulins, they most probably ingest the paraproteins. In Fanconi syndrome, a proteolytic cleavage resistance of kappa chains has been described, suggesting that a similar abnormality may account for crystal accumulation in the lysosomes<sup>11</sup>. Indeed, in CSH, unusual amino acid substitutions that are important for hydrophobic interactions within the protein have been found on the monoclonal kappa light chain, suggesting that such a mutation might impair its lysosomal degradation<sup>6</sup>.

The accumulation of histiocytes filled with immunoglobulin crystals is responsible for various clinical presentations. Bone marrow involvement is nearly always present and may be responsible for pancytopenia. Many other locations have been described, including lymph nodes, kidney, thymus, lung, intestinal mucosa, and spleen<sup>4,8,12</sup>. Localized CSH does not seem to carry a bad prognosis except for kidney involvement, which may be complicated with endstage renal failure. Interestingly, patients with multiple myeloma associated with CSH survived from 5 to 15 years after initial diagnosis, which is much longer than the median survival for multiple myeloma<sup>4</sup>. Many patients presented at an early stage of the gammopathy. On the other hand, systemic CSH with accumulation of crystal-storing histiocytes in many organs may carry a severe course. In such cases, accumulation of crystal-storing histiocytes appears to cause organ failure, mimicking other histiocytic and storage disorders. A rapid fatal outcome has been reported, related in 3 cases to unexplained septic-like shock, as in Patient 1<sup>6</sup>.

No treatment has proved effective for CSH. The outcome of the disease responsible for oversynthesis of immunoglobulin does not usually parallel the outcome of CSH<sup>4</sup>. Both our patients had generalized CSH. Patient 1 had bone marrow,

liver, and spleen CSH responsible for anemia and organ enlargement. Corneal, renal, and peripheral nerve involvement was clinically obvious although not proven histologically. Serum and urinary biological abnormalities (proteinuria and glycosuria with normal glycemia) were highly suggestive of Fanconi syndrome. Patient 2 had proven bone marrow, liver, and peritoneal CSH responsible for recurrent ascites. Histological studies of the femoral head after osteonecrosis also showed massive infiltration of the bone.

To our knowledge, bone involvement has not yet been described in CSH. Diffuse and specific bone involvement was clear in both patients because (1) they had long-lasting deep bone pain; (2) bone radiographs showed avascular necrosis confirmed by MRI studies that also revealed diffuse bone marrow infiltration; (3) <sup>99</sup>Tc scintiscan showed diffuse and heterogeneous uptake of the femurs and tibias; and (4) crystal-storing histiocyte infiltration was observed on bone histological specimens.

Diffuse bone involvement relates this disease to other histiocytic disorders such as Gaucher disease and Weber-Christian and Erdheim-Chester disease<sup>10,13,14</sup>. Interestingly, Patient 2 had high plasma levels of chitotriosidase, as found in Gaucher disease and in other lysosomal storage disorders<sup>15</sup>. Such disorders all have in common abnormal macrophages and lysosomes. In CSH, rather than the abnormal immunoglobulin, it is the accumulation of abnormal histiocytes that constitutes the pivotal feature.

Clinical and radiological findings are close to those seen in Gaucher disease, where skeletal involvement includes bone marrow infiltration by Gaucher cells, failure of remodeling causing osteopenia, osteonecrosis, osteosclerosis, bone crisis, chronic bone pain, and/or pathologic fractures<sup>14</sup>. In CSH, bone marrow infiltration by abnormal histiocytes may cause vascular occlusion and increased intraosseous pressure. Indeed, our patients had radiological evidence of bone marrow infiltration as well as an ischemic component to their bone disease. Further, multiple myeloma could also cause bone ischemia and hypovascularization. Overstimulation of macrophages may trigger the synthesis of different cytokines responsible for the pseudo-septic shock that is observed in some patients, as in Patient 1<sup>6</sup>.

Bone involvement appears to be a specific feature of crystal-storing histiocytosis. Because infiltration with abnormal immunoglobulin-loaded macrophages is clearly pivotal, CSH should be considered not only as an immunoglobulin deposition disease but also as a storage histiocytic disorder.

## REFERENCES

1. Kyle RA. Amyloidosis. *Circulation* 1995;91:1269-71.
2. Randall RE, Williamson WC Jr, Mullinax F, Tung MY, Still WJ. Manifestations of systemic light chain deposition. *Am J Med* 1976;60:293-9.
3. Papo T, Musset L, Bardin T, et al. Cryocrystalglobulinemia as a cause of systemic vasculopathy and widespread erosive arthropathy. *Arthritis Rheum* 1996;39:335-40.

4. Jones D, Bhatia VK, Krausz T, Pinkus GS. Crystal-storing histiocytosis: a disorder occurring in plasmacytic tumors expressing immunoglobulin kappa light chain. *Hum Pathol* 1999;30:1441-8.
5. Truong LD, Mawad J, Cagle P, Mattioli C. Cytoplasmic crystals in multiple myeloma-associated Fanconi's syndrome. A morphological study including immunoelectron microscopy. *Arch Pathol Lab Med* 1989;113:781-5.
6. Lebeau A, Zeindl-Eberhart E, Muller EC, et al. Generalized crystal-storing histiocytosis associated with monoclonal gammopathy: molecular analysis of a disorder with rapid clinical course and review of the literature. *Blood* 2002;100:1817-27.
7. Bosman C, Camassei FD, Boldrini R, et al. Solitary crystal-storing histiocytosis of the tongue in a patient with rheumatoid arthritis and polyclonal hypergammaglobulinemia. *Arch Pathol Lab Med* 1998;122:920-4.
8. Kapadia SB, Enzinger FM, Heffner DK, Hyams VJ, Frizzera G. Crystal-storing histiocytosis associated with lymphoplasmacytic neoplasms. Report of three cases mimicking adult rhabdomyoma. *Am J Surg Pathol* 1993;17:461-7.
9. Schaefer HE. Gammopathy-related crystal-storing histiocytosis, pseudo- and pseudo-pseudo-Gaucher cells. Critical commentary and mini-review. *Pathol Res Pract* 1996;192:1152-62.
10. Harada M, Shimada M, Fukayama M, Kaneko T, Kitazume K, Weiss SW. Crystal-storing histiocytosis associated with lymphoplasmacytic lymphoma mimicking Weber-Christian disease: immunohistochemical, ultrastructural, and gene-rearrangement studies. *Hum Pathol* 1996;27:84-7.
11. Leboulleux M, Lelongt B, Mougenot B, et al. Protease resistance and binding of Ig light chains in myeloma-associated tubulopathies. *Kidney Int* 1995;48:72-9.
12. Jones D, Renshaw AA. Recurrent crystal-storing histiocytosis of the lung in a patient without a clonal lymphoproliferative disorder. *Arch Pathol Lab Med* 1996;120:978-80.
13. Veyssier-Belot C, Cacoub P, Caparros-Lefebvre D, et al. Erdheim-Chester disease. Clinical and radiologic characteristics of 59 cases. *Medicine Baltimore* 1996;75:157-69.
14. Pastores GM, Patel MJ, Firooznia H. Bone and joint complications related to Gaucher disease. *Curr Rheumatol Rep* 2000;2:175-80.
15. Guo Y, He W, Boer AM, et al. Elevated plasma chitotriosidase activity in various lysosomal storage disorders. *J Inher Metab Dis* 1995;18:717-22.