

# Nasal Septal Perforation: A Novel Clinical Manifestation of Systemic Juvenile Idiopathic Arthritis / Adult Onset Still's Disease

TADEJ AVČIN, EARL D. SILVERMAN, VITO FORTE, and RAYFEL SCHNEIDER

**ABSTRACT.** Nasal septal perforation has been well recognized in patients with various rheumatic diseases. To our knowledge, this condition has not been reported in children with systemic juvenile idiopathic arthritis (SJIA) or patients with adult onset Still's disease (AOSD). We describe 3 patients with persistent SJIA/AOSD who developed nasal septal perforation during the course of their disease. As illustrated by these cases, nasal septal perforation may develop as a rare complication of SJIA/AOSD and can be considered as part of the clinical spectrum of the disease. In one case the nasal septal perforation was associated with vasculitis. (J Rheumatol 2005;32:2429–31)

*Key Indexing Terms:*

SYSTEMIC JUVENILE IDIOPATHIC ARTHRITIS      ADULT ONSET STILL'S DISEASE  
NASAL SEPTAL PERFORATION

Perforation of the nasal septum has been well recognized in patients with various rheumatic diseases, including Wegener's granulomatosis, systemic lupus erythematosus (SLE), and sarcoidosis<sup>1,2</sup>. Nasal involvement is one of the major features of Wegener's granulomatosis and may lead to massive destruction of the septal cartilage and saddle-nose deformity<sup>3</sup>. Nasal septal perforation is also a recognized complication of mucosal involvement in SLE and occurs in up to 5% of patients<sup>4,5</sup>. Nasal septal perforations have rarely been reported in other rheumatic diseases, including rheumatoid arthritis, psoriatic arthritis, and progressive systemic sclerosis<sup>6,7</sup>. To our knowledge, nasal septal perforation has not been reported in children with systemic juvenile idiopathic arthritis (SJIA) or patients with adult onset Still's disease (AOSD).

Systemic JIA is a subtype of JIA characterized by prominent extraarticular features<sup>8</sup>. In addition to chronic arthritis, the most common manifestations are fever, evanescent rash, generalized lymphadenopathy, hepatosplenomegaly, and serositis. AOSD is virtually identical in clinical and labora-

tory manifestations to SJIA and may occur at all ages<sup>9</sup>. We describe 3 patients with persistent SJIA/AOSD who developed nasal septal perforation during the course of their disease (Table 1).

## CASE REPORTS

*Case 1.* A 4.5-year-old girl first presented in February 1998 with an 8 week history of spiking fever, evanescent rash, and polyarthritis. Laboratory investigations showed erythrocyte sedimentation rate (ESR) of 115 mm/h, hemoglobin 105 g/l, white blood cell (WBC) count  $17.4 \times 10^9/l$ , and platelet count  $420 \times 10^9/l$ . A diagnosis of SJIA was made and she was initially treated with indomethacin, followed by pulse methylprednisolone, oral prednisone (up to 2 mg/kg/day), and intraarticular corticosteroids. She had a very difficult disease course, with persistent systemic symptoms and destructive polyarthritis unresponsive to treatment with intravenous immunoglobulin, methotrexate, infliximab, and anakinra. She did not tolerate cyclosporine A and developed macrophage activation syndrome after starting treatment with etanercept<sup>10</sup>.

Six and a half years after disease onset she presented with symptoms of nasal obstruction and pain without clinical features of an infection and with no history of trauma. On examination her nasal septal mucosa had hemorrhagic crust and she had a moderate-size anterior septal perforation (Figure 1). At that time the systemic features of her disease were well controlled with oral prednisone (25 mg/day in 2 divided doses), but she had persistent polyarthritis and developed a vasculitic rash on her thighs. Laboratory investigations showed ESR 79 mm/h, hemoglobin 112 g/l, WBC count  $17.9 \times 10^9/l$ , and platelet count  $222 \times 10^9/l$ . Computer tomography (CT) of her paranasal sinuses revealed only minimal mucosal thickening in the left maxillary and the sphenoid sinuses. High resolution CT of her chest showed no evidence of pulmonary involvement.

One month after the diagnosis of nasal septal perforation she presented with a second episode of macrophage activation syndrome and had a persistent vasculitic rash on her thighs. Skin biopsy revealed small-vessel neutrophilic vasculitis with granular staining of the dermoepidermal junction basement membrane for IgA and IgM. All serum autoantibody tests including antineutrophil cytoplasmic antibodies (ANCA), antinuclear antibodies (ANA), rheumatoid factor (RF), anti-double stranded DNA antibodies

---

From the Division of Rheumatology and Department of Otolaryngology, The Hospital for Sick Children, University of Toronto, Toronto, Ontario, Canada.

T. Avčín, MD, PhD, Clinical Fellow, Division of Rheumatology; E.D. Silverman, MD, FRCPC, Professor of Pediatrics and Immunology, Division of Rheumatology; V. Forte, MD, FRCSC, Associate Professor of Otolaryngology, Department of Otolaryngology; R. Schneider, MBBCh, FRCPC, Associate Professor of Pediatrics, Head, Division of Rheumatology.

Address reprint requests to Dr. R. Schneider, Division of Rheumatology, The Hospital for Sick Children, 555 University Avenue, Toronto, Ontario M5G 1X8. E-mail: rayfel.schneider@sickkids.ca

Accepted for publication July 21, 2005.

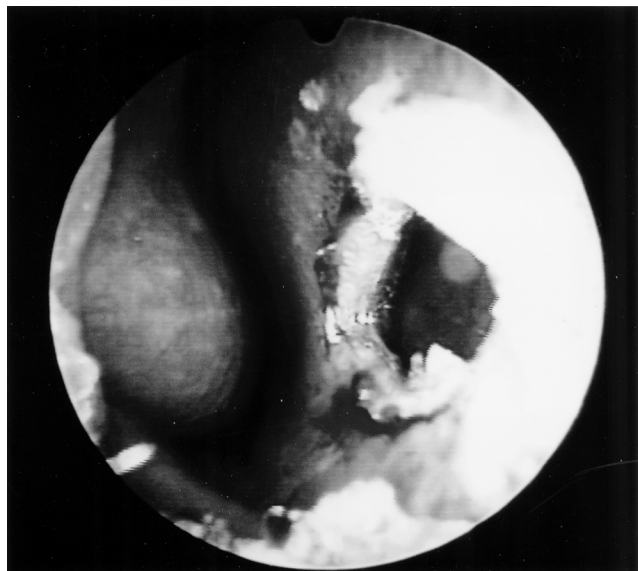


Figure 1. Nasal septal perforation in Patient 1.

(anti-dsDNA), and antibodies against extractable nuclear antigens were negative. She was treated with methylprednisolone pulse therapy, followed by high dose oral prednisone. Because of severe steroid toxicity and persistently positive laboratory markers of macrophage activation she was prescribed tacrolimus and made a good clinical recovery, with resolution of macrophage activation features and improvement of her polyarthritis. Since it was first noted, there has been no significant change in the size or character of the nasal septal perforation.

**Case 2.** A 14.5-year-old boy was hospitalized in January 2003 with a history of spiking fever, myalgia, and chest pain for 5 days. An echocardiogram showed a small pericardial effusion with good myocardial function, and an electrocardiogram was consistent with myocarditis. Laboratory data included ESR 45 mm/h, hemoglobin 89 g/l, WBC count  $34.8 \times 10^9/l$  with neutrophilia, and platelet count  $365 \times 10^9/l$ . No infectious focus was found and there were no signs of arthritis. He was treated with indomethacin and discharged with a presumptive diagnosis of viral perimyocarditis.

Two weeks later he developed chest pain, an evanescent rash, hepatosplenomegaly, and polyarthritis involving his shoulders, elbows, wrists, knees, and ankles, which persisted for 4 weeks. An ultrasound examination revealed pericardial and pleural effusions. He was diagnosed with SJIA and received treatment with methylprednisolone pulse therapy, followed by high dose prednisone (60 mg/day in 3 divided doses). He was also treated with intravenous immunoglobulin and has made a good clinical recovery. Autoantibody testing in February 2003 showed positive ANA (titer 1:320, homogenous and speckled immunofluorescence pattern) with anti-Ro and anticardiolipin antibodies; however, all subsequent autoantibody analyses repeated several times were consistently negative for ANA, RF, ANCA, anti-dsDNA, anti-Ro, and anticardiolipin antibodies.

Ten months after initial presentation, he developed whistling in his nose with no evidence of infection or trauma. There was no history of intranasal drug abuse. Examination revealed nasal septal perforation > 15 mm in diameter. At that time he had no active arthritis and the systemic features of his disease were controlled with oral prednisone (10 mg/day) and indomethacin. Laboratory investigations showed ESR 8 mm/h, hemoglobin 138 g/l, WBC count  $6.6 \times 10^9/l$ , and platelet count  $155 \times 10^9/l$ . Chest radiography showed a normal heart size and no pulmonary parenchymal abnormality.

**Case 3.** A 16.5-year-old girl first presented in September 2002 with fever, evanescent rash, arthralgias, hepatomegaly, and marked muscle pain. Laboratory investigations showed ESR 88 mm/h, hemoglobin 105 g/l,

WBC count  $11.7 \times 10^9/l$ , and platelet count  $233 \times 10^9/l$ . An extensive investigation for infection was negative and a bone marrow aspirate showed no evidence of malignancy. ANA, anti-dsDNA, and RF were negative. During the disease course she developed polyarthritis and was diagnosed with AOSD. Her disease was unresponsive to nonsteroidal antiinflammatory drugs and she was given prednisone (up to 40 mg/day) with good clinical control of her systemic symptoms. However, she had persistent arthritis and had a flare of her systemic disease during prednisone taper. She was then given methotrexate, with subsequent control of her arthritis and systemic symptoms.

Ten months after her initial symptoms she presented with symptoms of minor nasal bleeding and whistling when she was breathing. There was no history of infection, intranasal drug abuse, or trauma. Head and neck examination revealed perforation in the posterior aspect of nasal septum, about 8 mm in diameter. At the time of perforation she had signs of active arthritis without systemic features of AOSD.

## DISCUSSION

We describe 3 patients with persistent SJIA/AOSD who developed symptomatic nasal septal perforation during the course of their disease. The presenting nasal symptoms were obstruction, pain, whistling, or epistaxis. In 2 patients, perforation occurred within the first year from disease onset and in one patient after 6.5 years of disease. All patients had been treated with high dose corticosteroids. Two patients have experienced septal perforation during an active phase of the disease and one patient during an inactive phase of the disease while taking medication.

Perforation of the nasal septum is uncommon in children and most cases are secondary to trauma or infection<sup>1</sup>, which were absent in our patients. All our patients had normal or elevated levels of IgA antibodies, normal blood glucose levels, and normal thyroid function tests. Since SJIA/AOSD is a rare disease, accounting only for 10%–20% of all juvenile idiopathic arthritides<sup>8</sup>, the coincidental occurrence of nasal septal perforation in 3 patients is highly unlikely.

The etiopathogenic mechanisms leading to nasal septal perforation in SJIA/AOSD are not known, but in one case (Patient 1) we suspect that perforation was associated with vascular inflammation. In that patient, nasal septal perforation developed concurrently with vasculitic rash and preceded by 1 month an overt disease flare with macrophage activation syndrome. The vasculitic component of the disease was confirmed by skin biopsy, which revealed small-vessel neutrophilic vasculitis. Biopsy from the rim of the septal perforation was not performed, as this investigation seldom adds useful information or alters clinical management in patients with vasculitis<sup>1,11</sup> and the patient was reluctant to have this procedure.

Vascular inflammation is not a characteristic pathological process in patients with SJIA/AOSD; however, vasculitis has been reported in patients with severe forms of the disease. Elevated levels of von Willebrand factor (Factor VIII-related antigen), which is released from endothelial cells and presumably reflects the presence of vascular endothelial injury, have been reported in patients with SJIA<sup>12</sup>. Patients in our series did not exhibit clinical and/or laboratory fea-

tures of Wegener's granulomatosis and chest radiography/CT scan showed normal pulmonary parenchyma.

Several other etiopathogenic mechanisms of nasal septal perforation have been proposed in rheumatic diseases, including local vasospasm following exposure to cold inspired air and increased tendency to infection because of corticosteroid administration<sup>6,13</sup>. None of our patients had Raynaud's phenomenon or other features of local vasospasm. Regarding corticosteroid therapy, all our patients were on longterm therapy with high-dose corticosteroids, but there was no evident increase in frequency of upper airway infections. Although septum perforation is a well known complication of therapy with intranasal topical steroids in patients with allergic rhinitis<sup>14</sup>, there are no reports of nasal septal perforation resulting from systemic corticosteroid use.

In summary, nasal septal perforation may develop as a rare complication of SJIA/AOSD and can be considered as part of the clinical spectrum of the disease. All patients in our series developed symptomatic perforation and had a persistent course of SJIA/AOSD requiring treatment with high dose corticosteroids. In one case the nasal septal perforation was associated with vasculitis.

## REFERENCES

1. Diamantopoulos II, Jones NS. The investigation of nasal septal perforations and ulcers. *J Laryngol Otol* 2001;115:541-4.
2. Papadimitraki ED, Kyrmizakis DE, Kritikos I, Boumpas DT. Ear-nose-throat manifestations of autoimmune rheumatic diseases. *Clin Exp Rheumatol* 2004;22:485-94.
3. Gubbels SP, Barkhuizen A, Hwang PH. Head and neck manifestations of Wegener's granulomatosis. *Otolaryngol Clin North Am* 2003;36:685-705.
4. Rahman P, Gladman DD, Urowitz MB. Nasal-septal perforation in systemic lupus erythematosus — time for a closer look. *J Rheumatol* 1999;26:1854-5.
5. Bruno E, Russo S, Nucci R, Alessandrini M, DiGirolamo S. Nasal mucosal involvement in systemic lupus erythematosus: histopathologic and immunopathologic study. *Int J Immunopathol Pharmacol* 2000;13:39-42.
6. Willkens RF, Roth GJ, Novak A, Walike JW. Perforation of nasal septum in rheumatic diseases. *Arthritis Rheum* 1976;19:119-21.
7. Mathews JL, Ward JR, Samuelson CO, Knibbe WP. Spontaneous nasal septal perforation in patients with rheumatoid arthritis. *Clin Rheumatol* 1983;2:13-8.
8. Laxer RM, Schneider R. Systemic-onset juvenile chronic arthritis. In: Isenberg DA, Maddison PJ, Woo P, Glass D, Breedveld FC, editors. *Oxford textbook of rheumatology*. Oxford: Oxford University Press;2004:798-810.
9. Pouchot J, Sampalis JS, Beaudet F, et al. Adult Still's disease: manifestations, disease course, and outcome in 62 patients. *Medicine* 1991;70:118-36.
10. Ramanan AV, Schneider R. Macrophage activation syndrome following initiation of etanercept in a child with systemic onset juvenile rheumatoid arthritis. *J Rheumatol* 2003;30:401-3.
11. Murray A, McGarry GW. The clinical value of septal perforation biopsy. *Clin Otolaryngol* 2000;25:107-9.
12. Bowyer S, Ragsdale CG, Sullivan DB. Factor VIII related antigen and childhood rheumatic diseases. *J Rheumatol* 1989;16:1093-7.
13. Reiter D, Myers AR. Asymptomatic nasal septal perforations in systemic lupus erythematosus. *Ann Otol Rhinol Laryngol* 1980;89:78-80.
14. Cervin A, Andersson M. Intranasal steroids and septum perforation — an overlooked complication? A description of the course of events and a discussion of the causes. *Rhinology* 1998;36:128-32.