

# Role of Immunosuppressive Therapy on Clinical, Immunological, and Angiographic Outcome in Active Takayasu's Arteritis

ANAND K. VALSAKUMAR, UMESAN CHIRAMMAL VALAPPIL, VINOD JORAPUR, NAVEEN GARG, SONIYA NITYANAND, and NAKUL SINHA

**ABSTRACT.** *Objective.* To evaluate the role of an immunosuppressive regimen consisting of azathioprine and prednisolone on the clinical, immunological, and angiographic outcome in patients with active Takayasu's arteritis (TA).

*Methods.* Between January 1996 and January 2001, of 65 consecutive newly diagnosed patients with TA not previously treated by any immunosuppressive therapy, 15 fulfilled the criteria for disease activity. Detailed clinical and laboratory evaluation was carried out in these patients. They were treated with a combination of azathioprine and prednisolone for one year, and aortography was carried out in all patients before and after completion of the treatment.

*Results.* All patients had improvement in systemic symptoms and laboratory measures of disease activity within a period of 3 months of onset of treatment. Erythrocyte sedimentation rate decreased from a mean of  $55.5 \pm 14.7$  mm/h to  $21.9 \pm 9.5$  mm/h within 3 months ( $p < 0.001$ ) and further to  $20.8 \pm 15.2$  at one year ( $p = \text{NS}$ ). C-reactive protein concentrations fell from  $4.8 \pm 5.2$  mg/dl to  $0.5 \pm 0.2$  mg/dl at 3 months ( $p = 0.004$ ) and remained at  $0.5 \pm 0.3$  mg/dl at one year ( $p = \text{NS}$ ). No changes in the peripheral pulses or differences in limb blood pressures were noted. Repeat angiograms revealed no significant changes compared to baseline. No new lesion appeared in any patient. The immunosuppressive therapy was well tolerated with no notable side effects.

*Conclusion.* An immunosuppressive regimen of azathioprine and prednisolone is safe, well tolerated, and effective in ameliorating systemic symptoms and laboratory measures of disease activity in TA, and at least halts progression in angiographic lesions at one year of followup, although it does not seem to lead to a regression of the arterial lesions. (J Rheumatol 2003;30:1793–8)

## Key Indexing Terms:

TAKAYASU'S ARTERITIS

IMMUNOSUPPRESSIVE THERAPY

ANGIOGRAPHY

Takayasu's arteritis (TA) is a chronic inflammatory vasculitis of undetermined etiology that primarily involves the aorta and its major branches and to a lesser extent the pulmonary arteries and rarely coronary arteries<sup>1,2</sup>. The natural history of the disease can be divided into an early pre-pulselessness phase characterized by signs and symptoms of systemic inflammatory process and a late phase characterized by signs and symptoms of vascular occlusion<sup>3</sup>. The majority of patients present in the late phase of the disease. The clinical features usually reflect limb or organ

ischemia resulting from gradual stenosis of involved arteries.

The role of immunosuppressive therapy in TA is not well defined<sup>4</sup>. Glucocorticoids are effective in suppressing systemic symptoms and reducing the erythrocyte sedimentation rate (ESR), but reports regarding their role in angiographic regression of arterial lesions are conflicting<sup>5,6</sup>. Glucocorticoids when used alone in active TA are successful in arresting disease progression in only about 50% of patients<sup>5,7</sup>, necessitating use of additional cytotoxic therapy. The cytotoxic agents used most often in the treatment of TA are cyclophosphamide (CYC) and methotrexate, especially in glucocorticoid resistant cases<sup>5,7,8</sup>. The majority of patients with TA are women in the third and fourth decades<sup>1</sup>. CYC in these patients brings the potential risk of amenorrhea and infertility. There are only rare reports of treatment with azathioprine (AZA)<sup>7,9</sup>, and the effect on angiographic outcome is not well defined. AZA if effective would be a safer drug than CYC.

We evaluated the role of an immunosuppressive regimen consisting of prednisolone and AZA on the clinical, immunological, and angiographic outcome in patients with active TA with defined disease activity criteria.

From the Department of Cardiology, and Department of Clinical Immunology, Sanjay Gandhi Postgraduate Institute of Medical Sciences, Lucknow, India.

A.K. Valsakumar, MD, DM, Senior Resident; U. Chiramal Valappil, MD, DM, Senior Resident; V. Jorapur, MD, DM, Senior Resident; N. Garg, MD, DM, DNB, FACA, Assistant Professor, Department of Cardiology; S. Nityanand, MD, PhD, Associate Professor, Department of Clinical Immunology; N. Sinha, MD, DM, FSCAI, FACC, Professor, Head, Department of Cardiology.

Address reprint requests to Prof. N. Sinha, Department of Cardiology, Sanjay Gandhi PGIMS, Lucknow UP, India 226014. E-mail: nsinha@sgpgi.ac.in

Submitted January 21, 2000; revision accepted January 10, 2003.

## MATERIALS AND METHODS

Between January 1996 and January 2001, all consecutive newly diagnosed patients with TA seen in the departments of cardiology and clinical immunology were screened for disease activity. None had previously been treated by any immunosuppressive therapy. Patients who were diagnosed to have active disease formed the study group. The diagnosis of TA was based on the American College of Rheumatology 1990 criteria<sup>10</sup>. All patients underwent detailed clinical examination and laboratory evaluation including complete blood count, ESR, C-reactive protein (CRP), rheumatoid factor (RF), antinuclear antibody (ANA), and IgG anticardiolipin antibody (aCL). Chest radiograph, 12-lead electrocardiogram, echocardiogram, and peripheral vascular Doppler study were done in all patients. Cardiac catheterization with right and left heart pressure studies and complete biplane aortography were done in all cases, and disease was classified into types I, II, and III based on the criteria of Ueno, *et al*<sup>11</sup>.

**Criteria for disease activity.** The previously used criteria for defining disease activity (although not yet validated) were followed in this study also<sup>12</sup>. If clinically-tender arteries including carotidynia were observed, the disease was taken as active. In the absence of this physical sign, at least 2 of the following features had to be fulfilled to classify the disease as active: (1) unexplained fever > 1 week duration and/or arthralgia and myalgia; (2) elevated ESR > 30 mm/h (Westergren); and (3) raised CRP > 0.6 mg/dl. Patients were divided into 2 groups based on the disease activity criteria — Group 1, those with evidence of active disease; and Group 2, those with no evidence of active disease.

**Treatment protocol.** Patients with active disease were treated with immunosuppressive therapy according to a standard protocol using a combination of prednisolone and AZA. Prednisolone was started at a dose of 1 mg/kg body weight/day for 6 weeks and tapered to a maintenance dose of 5–10 mg/day by 12 weeks if there was a regression in clinical features of disease activity and normalization in the laboratory indicators of inflammation in this period. If the features of disease activity continued beyond 12 weeks, then the dose was tapered more gradually. Prednisolone was continued for one year at a maintenance dose of either 5 or 10 mg/day (median dose 10 mg, range 5–10 mg). AZA was given in a dose of 2 mg/kg body weight/day for one year. All patients were given supportive therapy (e.g., antihypertensive drugs for hypertension). Patients undergoing immunosuppressive therapy were followed up at 6 weeks and 3, 6, and 12 months with detailed clinical evaluation and laboratory investigations. Angiograms were repeated after one year of immunosuppressive therapy. The predetermined indications for withdrawal of AZA were leukocyte count < 4000/mm<sup>3</sup>, platelet count < 100,000/mm<sup>3</sup>, and hemoglobin < 7 g/dl.

**Angiographic analysis.** Angiograms were done in all cases before starting immunosuppressive therapy and after at least one year of completing it. All angiographic procedures were done through the retrograde femoral arterial route using standard 7 French catheters and meglumine dye (Urografin, Schering AG, Berlin, Germany). Care was taken to repeat the same views of the initial study at the second angiography. Angiograms were recorded on standard 35 mm cine-angiographic films in 13 patients and digital subtraction angiography (DSA) films in 2 patients. All angiograms were analyzed by 2 independent expert reviewers who were blinded to the clinical status of the patients. Angiograms were analyzed by the reviewers retrospectively (and not at the time of the actual angiography). Angiograms were presented to the reviewers randomly. Angiographic measurements and degree of stenosis were calculated using the hand-held caliper method. Transverse diameter of different segments of aorta and its branches was measured in the nondiseased parts, taking the outer diameter of the 7 French catheter as the reference (7 French = 2.33 mm). Similarly, transverse diameter of diseased segments of aorta and its branches was measured at their narrowest portions (minimal luminal diameter) and the percentage stenosis of each lesion was calculated individually. The same procedure was applied to both pre- and post-treatment angiograms. Each segment and each narrowing in basal and post-immunosuppressive therapy angiograms were compared.

**Statistical analysis.** Laboratory measures of disease activity (ESR and CRP) were measured at baseline and at 3-monthly intervals. The change in levels was compared using paired Student *t* test and a value of *p* < 0.05 was taken as significant. The pre- and post-treatment angiograms were analyzed segmentally and the change in diameter stenosis in each segment of aorta and its branches was analyzed by nonparametrical tests of significance (Mann-Whitney test and 2-sample Kolmogorov-Smirnov test), and a value of *p* < 0.05 was considered significant.

## RESULTS

**Baseline characteristics.** Between January 1996 and January 2001, a total of 15 patients fulfilled the disease activity criteria. All 15 patients were first-time diagnosed to have TA and none had received prior immunosuppressive therapy. All were female, with a mean age of  $28.3 \pm 7.3$  years (range 14–38). The mean duration from onset of symptoms to inclusion in the study was  $12.9 \pm 5.8$  months (range 4–24). Hypertension was present in 6, upper limb claudication in 8, lower limb claudication in 3, and presyncope in 4 patients. Carotidynia was present in 4 patients, while 6 patients had arthralgia and/or myalgia. Six patients presented with fever of more than one week duration.

The mean ESR was  $55.5 \pm 14.7$  mm/h and mean CRP was  $4.8 \pm 5.2$  mg/dl. ANA was negative in all patients. One patient had a weakly positive RF. Low titers of aCL were positive in 2 patients; one was positive for IgG and IgM and the other positive for IgG-aCL. Angiographically, 6 patients each had type I and type II, while 3 had type III arterial involvement. Thirteen patients had the purely stenotic form of the disease, while 2 had mixed stenotic-aneurysmal disease.

**Treatment and followup.** All 15 patients took the immunosuppressive therapy for one year. There were no significant side effects. No patient needed discontinuation of treatment because of cytopenias. No patient required dose reduction or temporary withdrawal of AZA, and at the end of one year all were undergoing the 2 mg/kg dosage schedule.

All patients had complete resolution of their systemic symptoms (carotidynia, myalgia, arthralgia, etc.) in the initial 12 weeks of treatment. The high ESR rapidly improved from a mean of  $55.5 \pm 14.7$  mm/h to  $21.9 \pm 9.5$  mm/h within the first 12 weeks of treatment (*p* = 0.001). The improvement persisted throughout the course of treatment. At the end of one year of treatment, the ESR was  $20.8 \pm 15.2$  mm/h. CRP also improved markedly from a mean of  $4.8 \pm 5.2$  mg/dl to  $0.5 \pm 0.2$  mg/dl at 3 months (*p* = 0.004) and the improvement persisted until the completion of treatment. At the end of one year, CRP was  $0.5 \pm 0.3$  mg/dl. Only 6 of the 15 patients had elevation of either ESR or CRP or both at 12 weeks of therapy. Of these, only 2 had either ESR or CRP or both elevated at one year of therapy. Only one patient had both high ESR and CRP at completion of one year of treatment, despite marked clinical improvement. No changes in peripheral pulses or limb blood pressure differences were noted in any patient.

Angiograms were repeated in all 15 cases after one year of immunosuppressive therapy (range 12–14 mo). Detailed pre- and post-treatment angiographic data are shown in Table 1, which shows the mean percentage of stenosis (the mean of the observations by the 2 reviewers) of each affected segment before and after therapy. The interobserver variability was less than 5% in all cases and less than the differences observed in the lesions before and after treatment. Neither of the observers consistently measured greater changes than the other. Followup angiograms revealed minor changes in the stenotic segments, with no statistically significant progression or regression in any patient (Figures 1 and 2, Table 1). Of the 54 arterial segments affected in all 15 patients, 52 were stenotic. Of these, 27 represented totally occluded arteries that retained this status at followup. Of the remaining 25 lesions, the

stenosis improved in 17, while it worsened in 8, although this did not achieve statistical significance. Two patients had aneurysmal involvement (denoted A in Table 1), one each involving the ascending aorta (diameter 46 mm) and right carotid artery (diameter 23 mm), respectively. In the followup angiograms, no change in size was observed in these aneurysmal segments. No further new lesions appeared in any patient. No clinical relapses were noted in the one year followup.

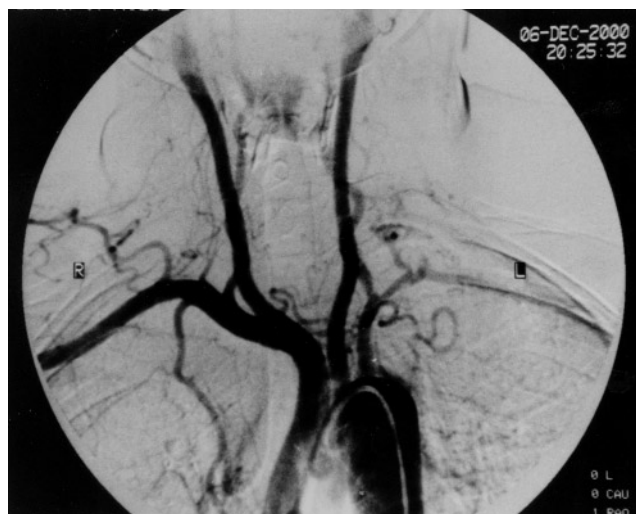## DISCUSSION

We used a protocol of immunosuppressive therapy consisting of a combination of azathioprine and prednisolone for the treatment of active Takayasu's arteritis. AZA as a cytotoxic agent was chosen because of its lower incidence of side effects. This regimen was uniformly well

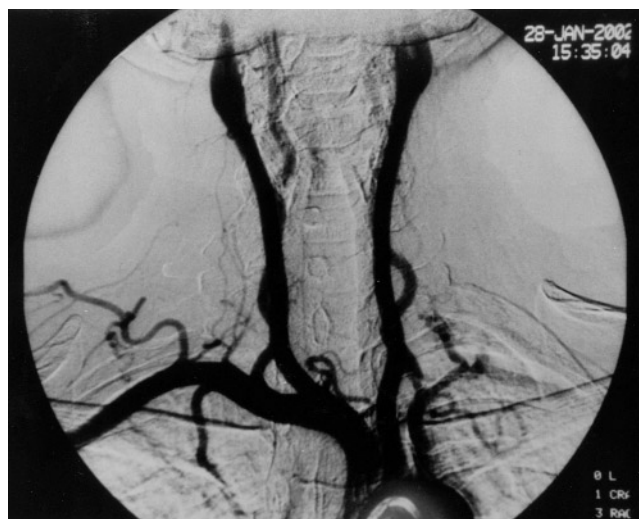
Table 1. Percentage stenosis of aorta and its branches at baseline and after one year of immunosuppressive therapy (n = 15).

Patient		Right						Left						Renal						Iliac	
		AA	Br	Sub	Ver	CC	Arch	CC	Sub	Ver	DTA	SRA	Cel	SMA	IMA	Right	Left	IRA	Right	Left	
1	Pre-Rx															100	100	21			
	Post-Rx															100	100	30			
2	Pre-Rx		100	100				100	100	26											
	Post-Rx		100	100				100	100	20											
3	Pre-Rx									54						65		50			
	Post-Rx									53						60		47			
4	Pre-Rx															100	47	50			
	Post-Rx															100	42	45			
5	Pre-Rx			100																	
	Post-Rx			100																	
6	Pre-Rx				59	69	100	100	100	41											
	Post-Rx				55	77	100	100	100	35											
7	Pre-Rx		39			100		100	79												
	Post-Rx		37			100		100	70												
8	Pre-Rx										59					34					
	Post-Rx										52					32					
9	Pre-Rx															100	37	47			
	Post-Rx															100	30	50			
10	Pre-Rx			100		A		100	100	30											
	Post-Rx			100		A		100	100	31											
11	Pre-Rx	A		100	52				100	52						30					
	Post-Rx	A		100	44				100	47						21					
12	Pre-Rx			86	70	100		100	100	33											
	Post-Rx			88	72	100		100	100	38											
13	Pre-Rx					100		100	100												
	Post-Rx					100		100	100												
14	Pre-Rx			100					100												
	Post-Rx			100					100												
15	Pre-Rx								38	48											
	Post-Rx								41	44											
Net % change		0	-2	-2	+2	0	x	0	-6	-9	-7	-7	x	x	x	-16	-12	+4	x	x	
Total segments involved		1	2	7	3	5	x	6	9	5	2	1	x	x	x	6	3	4	x	x	
Mean change/segment		0	-1	-0.29	+0.67	0	x	0	-0.67	-1.8	-3.5	-7	x	x	x	-2.67	-4	+1	x	x	
p		NS	NS	NS	NS	NS	x	NS	NS	NS	NS	NS	x	x	x	NS	NS	NS	x	x	

Rx: treatment, AA: ascending aorta, Br: brachiocephalic, Sub: subclavian, CC: common carotid, Arch: arch of aorta, Ver: vertebral, DTA: descending thoracic aorta, Cel: celiac, SMA: superior mesenteric, IMA: inferior mesenteric, SRA: suprarenal abdominal aorta, IRA: infrarenal abdominal aorta, A: aneurysm, NS: not significant, x: not involved in any case.



**A**

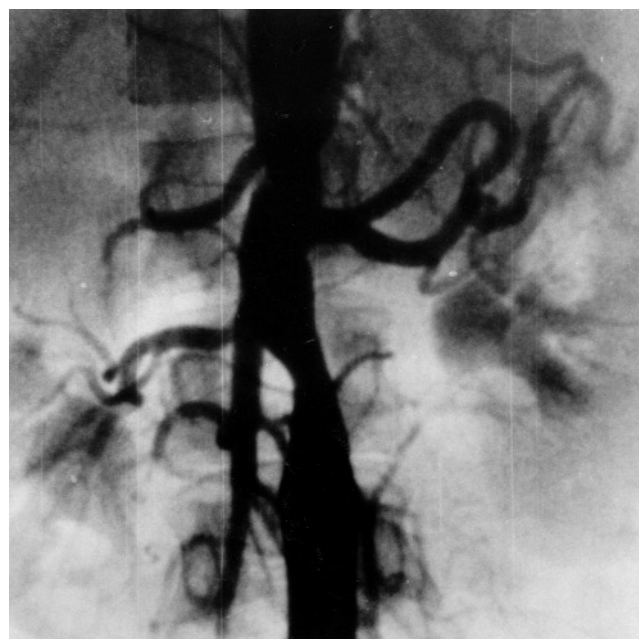


**B**

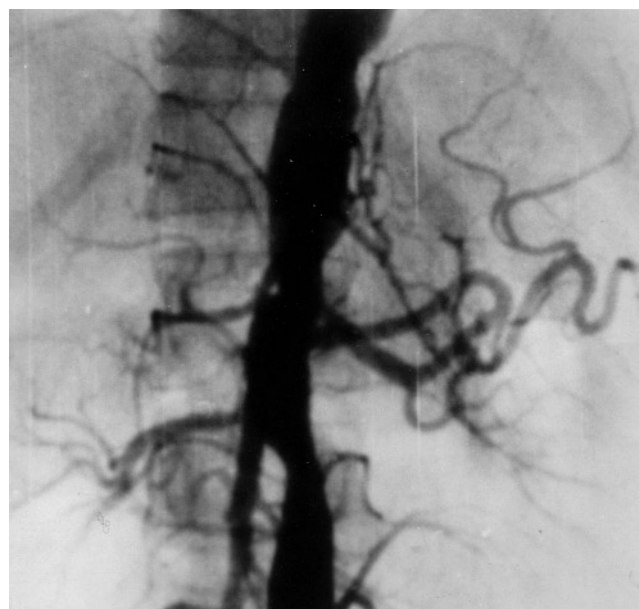*Figure 1. Aortic arch angiogram in a patient with active Takayasu's arteritis, (A) before and (B) after immunosuppressive therapy. The left subclavian artery has long-segment stenosis starting from the origin of the vertebral artery. The left vertebral artery has moderate ostial stenosis. The rest of the aortic arch and arch vessels are normal. Note there is no change in post-treatment angiogram compared to pre-treatment angiogram.*

tolerated and was effective in ameliorating the systemic symptoms and laboratory measures of disease activity within a period of 3 months in all patients.

The angiographic outcome with immunosuppressive therapy is highly variable among different studies. In our patients, there was no angiographic improvement at one year of followup, but no patient had significant progression of existing lesions or appearance of new lesions. Similar results have been described in 2 previous studies, where a halt in the angiographic progression of the disease was reported<sup>8,13</sup>. However, one study of 14 patients with active



**A**



**B**

*Figure 2. Abdominal aortogram in a patient with active Takayasu's arteritis, (A) before and (B) after immunosuppressive therapy. The abdominal aorta is diffusely diseased, with moderate stenosis above the origin of the left renal artery as well as below the origin of the right renal artery. All branches of the abdominal aorta are normal. Note there is no change in the post-treatment angiogram compared to the pre-treatment angiogram.*

TA showed angiographic improvement in 8 out of 9 patients treated with steroids, while the remaining 5 patients with no or interrupted steroid therapy showed angiographic disease progression<sup>6</sup>. Some studies, on the other hand, show



progression of existing lesions or appearance of new lesions on steroid therapy<sup>5,7</sup>.

A number of factors need to be considered while interpreting these widely discrepant findings. TA is a chronic disease and the natural history is highly variable. Subramanyan, *et al*<sup>14</sup> observed an event-free survival rate of 97% at 5 years after diagnosis in patients with no or mild complications, while Ishikawa<sup>15</sup> observed a similar rate of event-free survival at 10 years of followup in a similar group of patients. In view of the predominantly nonprogressive course and chronic disposition of the disease, large prospective randomized studies with long periods of followup are required for a firm conclusion. The time from the onset of symptoms and disease activity to inclusion in the study may account for some of the differences observed in different studies, as the disease may be expected to progress faster in the early stages. The variable response noted in different studies may be due to the differences in the ethnic population studied, as geographic variations in disease expression have been well defined<sup>16,17</sup>. Moreover, different treatment regimens and duration of therapy were employed in these studies, thus comparison of outcomes is difficult. Glucocorticoids alone have a success rate of only about 50% in arresting the disease progression of active TA. In one study, only 8 of the 16 patients responded to steroid-alone therapy in the first year of treatment<sup>5</sup>. Kerr, *et al*<sup>7</sup> treated 48 patients with active TA with glucocorticoids, and achieved remission of clinical and laboratory features in 43% of patients at one year and in 55% at 2 years. In our study, remission of clinical features of disease activity was achieved in all patients at one year and laboratory indicators of disease activity normalized in all except 2 (13.3%) patients by one year.

Assessment of disease activity is one of the major concerns in management of these patients. No uniform criteria were employed for defining "disease activity" in the previous studies. Elevated ESR is used by most physicians as an indicator of active disease, and its decline is believed to signify a response to treatment and therefore disease quiescence<sup>2</sup>. However, not all studies found that ESR was uniformly reliable<sup>18</sup>. In one study, angiographic findings in addition to clinical and laboratory measures were used for defining disease activity<sup>7</sup>. A major limitation of angiography in assessment of disease activity is that the angiography may detect diseased vessels, but does not distinguish active from chronic lesions. As angiography is a 2-dimensional visualization of the arterial lumen, the study result could also reflect the insensitivity of the angiography in defining active disease (i.e., involvement of arterial wall without modifying the lumen).

We defined disease activity on the basis of clinical features and associated elevated acute phase reactants (although these criteria have yet not been validated). In general, inactive disease is presumed to be present when

there is absence of tender arteries and systemic features, normal ESR, and stable angiographic findings. Even with the application of these guidelines, biopsy specimens from patients with presumably inactive disease have revealed histological evidence of active inflammation in as many as 42% of cases<sup>19</sup>. Alternative surrogate markers such as endothelin-1, von Willebrand factor, and factor VIII antigen have not been sufficiently evaluated in patients to be considered reliable markers of disease activity<sup>20-22</sup>. Recently, Noguchi, *et al*<sup>23</sup> suggested that increased concentrations of adhesion molecules (e.g., vascular cell adhesion molecule-1, intercellular adhesion molecule-1) may be associated with disease progression. Attempts have also been made to identify active lesions in TA using radioactive indium labeled leukocyte scintigraphy, without much success<sup>18</sup>. Positron emission tomography scanning has also been used in identifying disease activity. Hara, *et al* have described the selective accumulation of <sup>18</sup>F-fluorodeoxyglucose in the walls of affected arteries, including angiographically normal arterial segments, in a patient with active TA<sup>24</sup>. At present, lesion activity cannot be assessed conclusively short of vascular biopsy, which is not feasible for clinical diagnostic purposes.

To conclude, the immunosuppressive regimen of azathioprine and prednisolone was well tolerated and was uniformly effective in ameliorating systemic symptoms and laboratory measures of disease activity in patients with Takayasu's arteritis. No significant progression or regression of angiographic lesions was seen after one year of immunosuppressive therapy, suggesting an arrest in the disease process. As this was an open observational study, we cannot assert with certainty that it was the addition of azathioprine to prednisolone that halted the angiographic progression of the disease. It remains unconfirmed whether AZA has any certain effect on modifying disease activity or progression of vascular disease in TA. Further controlled trials with longterm followup will be necessary to establish the exact role of different regimens of AZA in TA.

## REFERENCES

1. Lupi-Herrera E, Sacher-Torres G, Marcushamer J, Mispireta J, Horowitz S, Vela JE. Takayasu's arteritis — clinical study of 107 cases. *Am Heart J* 1977;93:794-103.
2. Hall S, Barr W, Lie JT, Stanson AW, Kazmier FJ, Hunter GG. Takayasu's arteritis — A study of 32 North American patients. *Medicine* 1985;64:89-99.
3. Strachan RW, Wigzell FW, Anderson JR. Locomotor manifestations and serum studies in Takayasu's arteriopathy. *Am J Med* 1966;40:560-4.
4. Fauci AS, Haynes BF, Katz P. The spectrum of vasculitis — clinical, pathologic, immunologic and therapeutic considerations. *Ann Intern Med* 1978;89:660-76.
5. Shelhamer JH, Volkman DJ, Parrilo JE, Lawley TJ, Johnston MR, Fauci AS. Takayasu's arteritis and its therapy. *Ann Intern Med* 1985;103:121-6.
6. Ishikawa K. Effects of prednisolone therapy on arterial

- angiographic features in Takayasu's disease. *Am J Cardiol* 1991; 68:410-3.
7. Kerr GS, Hallahan CW, Giordano J, et al. Takayasu's arteritis. *Ann Intern Med* 1994;120:919-29.
  8. Hoffman GS, Leavitt RY, Kerr GS, et al. Treatment of glucocorticoid-resistant or relapsing Takayasu's arteritis with methotrexate. *Arthritis Rheum* 1994;37:578-82.
  9. Cybulska I. Takayasu's arteritis — course, diagnosis and long term results of treatment. *Pol Arch Med Wewn* 1994;91:451-60.
  10. Arend WP, Michel BA, Bloch DA, et al. The American College of Rheumatology 1990 criteria for the classification of Takayasu's arteritis. *Arthritis Rheum* 1990;33:1129-34.
  11. Ueno A, Awane Y, Wakabayashi A, Shimizu K. Successfully operated obliterative brachiocephalic arteritis (Takayasu) associated with elongated coarctation. *Jpn Heart J* 1967;8:538-44.
  12. Nityanand S, Misra K, Srivastava S, Holm G, Lefvert AK. Antibodies against cardiolipin and endothelial cell in Takayasu's arteritis — Prevalence and isotype distribution. *Br J Rheumatol* 1997;36:923-4.
  13. Weaver FA, Yellin AE. Surgical treatment of Takayasu's arteritis. *Heart Vessels* 1992;7 Suppl:154-8.
  14. Lagneau P, Michael JB, Vuong PN. Surgical treatment of Takayasu's disease. *Ann Surg* 1987;205:157-66.
  15. Yanagisawa M, Kurihara H, Kimura S. A novel potent vasoconstrictor peptide produced by vascular endothelial cells. *Nature* 1988;332:411-5.
  16. Nusinow SR, Federici AB, Zimmerman TS, Curd JG. Increased von Willebrand factor antigen in the plasma of patients with vasculitis. *Arthritis Rheum* 1984;27:1405-10.
  17. Woolf AD, Wakerley G, Wallington TB, Scott DG, Dieppe PA. Factor VIII related antigen in the assessment of vasculitis. *Ann Rheum Dis* 1987;46:441-7.
  18. Chen CC, Kerr GS, Carter CS, et al. Lack of sensitivity of indium-111 mixed leukocyte scans for active disease in Takayasu's arteritis. *J Rheumatol* 1995;22:478-81.
  19. Talwar KK, Vasan RS, Sharma S, et al. Non-specific aortoarteritis — longterm followup on immunosuppressive therapy. *Int J Cardiol* 1993;39:79-84.
  20. Subramanyan R, Joy J, Balakrishnan KG. Natural history of aortoarteritis. *Circulation* 1989;80:429-37.
  21. Judge RD, Currier RD, Gracie WA, Figley MM. Takayasu's arteritis and the aortic arch syndrome. *Am J Med* 1962;32:379-92.
  22. Sabba C, Pugliese D, Garuso G, et al. Takayasu's arteritis. A case report and discussion in differences in Eastern and Western cases. *Am J Cardiovasc Pathol* 1990;3:95-9.
  23. Noguchi S, Numano F, Gravanis MB, Wilcox JN. Increased levels of soluble forms of adhesion molecules in Takayasu arteritis. *Int J Cardiol* 1998;66 Suppl 1:S23-S33.
  24. Hara M, Goodman PC, Leder RA. FDG-PET finding in early phase Takayasu arteritis. *J Comput Assist Tomogr* 1999;23:16-8.