

Septic Discitis as a Complication of Infective Endocarditis Caused by *Streptococcus oralis*

UDAYA P. UDAYARAJ, MRCP, Specialist Registrar in Renal and General Medicine, University Hospital of Wales, Cardiff; NAGUI S.T. GENDI, FRCP, Consultant Rheumatologist, Department of Rheumatology; ELSIR M. OSMAN, MRCP, Consultant Physician, Basildon Hospital, Basildon, Basildon Hospital, Basildon, UK. Address reprint requests to Dr. N.S.T. Gendi, Basildon Hospital, Basildon SS165 NL, UK. E-mail: ngendi@yahoo.com

A 60-year-old man presented with fever, weight loss of 16 pounds over 8 weeks, and sudden worsening of his chronic back pain for one week. He had splinter hemorrhages, finger clubbing, a midsystolic click, a late systolic murmur, and microscopic hematuria. Blood cultures grew *Streptococcus oralis* and his C-reactive protein (CRP) was 172 mg/l. Transesophageal echocardiography confirmed mitral valve prolapse and a 5 mm vegetation on the posterior mitral valve leaflet. Magnetic resonance imaging (MRI) revealed discitis at L2/L3 level (Figure 1). He was treated with penicillin, gentamicin, and fusidic acid for 6 weeks, but his back pain persisted and his CRP remained elevated at 33 mg/l. Repeat lumbar spine radiograph revealed progressive destruction of L2/L3 disc space (Figure 2). Gallium scan revealed increased activity at the mid-lumbar spine suggesting continuing infection. He improved after further treatment with teicoplanin and rifampicin for 6 weeks.

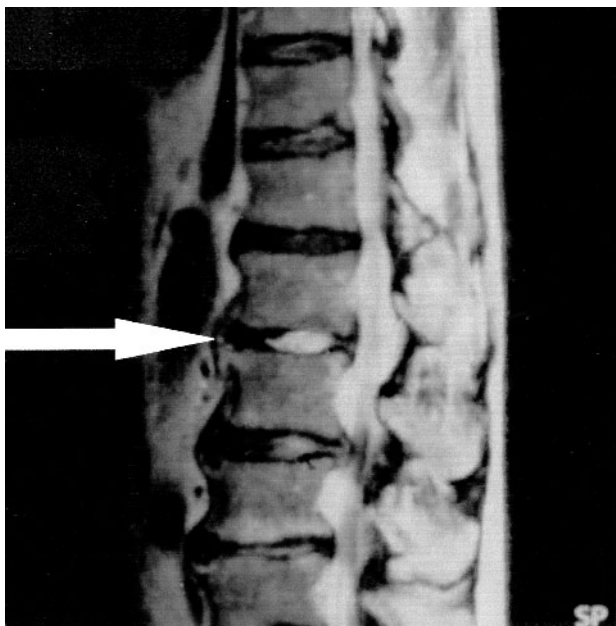


Figure 1. T2 weighted MRI shows increased signal indicating fluid in L2/L3 disc space. Degenerative disc disease is also noted.

A second patient developed *S. oralis* infection in his osteoarthritic knee as a complication of probable infective endocarditis. He had had a dental procedure 2 months before. The organism was isolated on blood cultures, and there was aortic valve stenosis although no vegetations were observed.

Septic discitis and arthritis are recognized complications of infective endocarditis¹⁻³, but this combination has not been reported before with *S. oralis*, which is an infrequent cause of endocarditis. *S. oralis* musculoskeletal infections reported to date include only one case of septic discitis following nucleolysis and another with a prosthetic hip infection after a dental procedure^{4,5}.

REFERENCES

1. Churchill MA Jr, Geraci JE, Hunder GG. Musculoskeletal manifestations of bacterial endocarditis. *Ann Intern Med* 1977;87:754-9.
2. Gonzalez-Juanatey C, Gonzalez-Gay MA, Llorca J, et al. Rheumatic manifestations of infective endocarditis in non-addicts. *Medicine* 2001;80:9-19.
3. Morelli S, Carmenini E, Caporossi AP, Aguglia G, Bernardo ML, Gurgo AM. Spondylodiscitis and infective endocarditis: case studies and review of the literature. *Spine* 2001;26:499-500.
4. Molinier S, Paris JF, Brisou P, et al. 2 cases of iatrogenic oral streptococcal infection: Meningitis and spondylodiscitis [French]. *Rev Med Interne* 1998;19:568-70.
5. Skiest DJ, Coykendall AL. Prosthetic hip infection related to a dental procedure despite antibiotic prophylaxis. *Oral Surg Oral Med Oral Pathol Oral Radiol Endod* 1995;79:661-3.

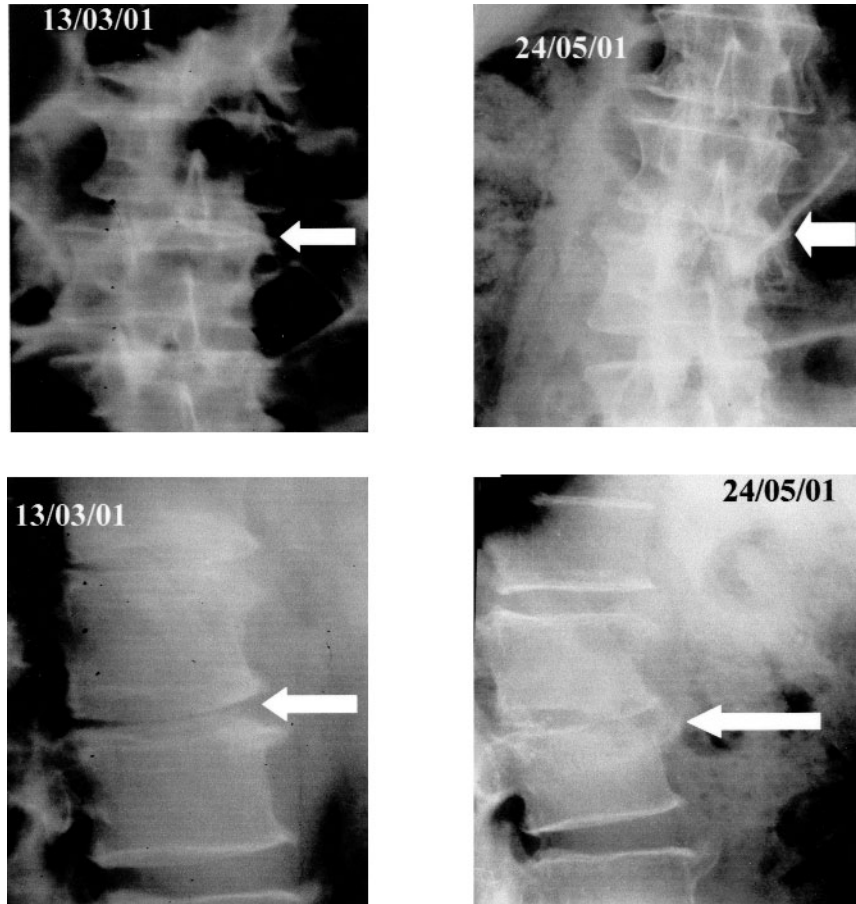


Figure 2. Plain radiographs show progressive damage of the disc space at L2/L3 level during the course of the infection. Destruction of the superior endplate of L3 vertebra and the inferior endplate of L2 vertebra and increased scoliosis developed during the course of the infection.