

Erosions Develop Rarely in Joints Without Clinically Detectable Inflammation in Patients with Early Rheumatoid Arthritis

TUULIKKI SOKKA, HANNU KAUTIAINEN, TIMO MÖTTÖNEN, and PEKKA HANNONEN

ABSTRACT. Objective. To study whether clinically observed tenderness and/or swelling of a wrist joint over the first 3 years after diagnosis predict the development of erosions in radiographs of the same joint at 5 years in patients with early rheumatoid arthritis (RA).

Methods. A total of 58 patients with recent onset RA were enrolled in a prospective RA study at Jyväskylä Central Hospital in 1983-85. Physical examination including joint counts was performed 6 times over 3 years (at 0, 6, 12, 18, 24, and 36 mo). Radiographs of hands and feet taken at the 5-year visit were scored according to the Larsen method (0-1 = non-erosive; 2-5 = erosive). At each visit, the wrist joints were assessed for tenderness (0/1) and swelling (0/1). A frequency (ranging from 0 to 6) was calculated for 4 inflammation categories — tenderness, swelling, tenderness or swelling, and tenderness and swelling — over the 3 years. Percentages of wrist joints with erosions on the 5-year radiographs were calculated for the frequency groups 0, 1, 2-3, and 4-6 of each category. Two patients died, and 5 wrists were erosive at baseline. Thus the data for 107 wrist joints of 54 patients were available for analyses.

Results. A statistically significant correlation was seen in the frequency of clinical inflammation and the development of erosions. Only one (3.3%) wrist with no tenderness in 6 examinations over the first 3 years developed erosions over 5 years, while 13 (59.1%) wrists that were tender 4-6 times in 6 examinations developed erosions. The corresponding percentages were 4.4% and 50.0% for wrists with swelling, 3.4% and 51.6% for wrists with tenderness or swelling, and 6.1% and 75.0% for wrists with tenderness and swelling.

Conclusion. Radiographic erosions develop rarely without preceding clinically detectable inflammation in the joints of patients with early RA. (J Rheumatol 2003;30:2580-4)

Key Indexing Terms:

EARLY RHEUMATOID ARTHRITIS EROSION PREDICTION RADIOGRAPHIC

The issue regarding the association between clinically detectable synovitis and bone destruction in rheumatoid joints has provoked attention for decades. In centers where subsequent clinical examinations of joints are recorded routinely, and radiographs of hands and feet are taken annually, the clinical impression of rheumatologists is that erosions develop in joints with preceding inflammation¹. More recently, it has been suggested that clinical manifestations of joint inflammation and development of bone erosions in rheumatoid arthritis (RA) are results of different pathological processes^{2,3}. Therefore, erosions would

develop unpredictably in joints that do not show tenderness or swelling in clinical examination. Indeed, inflammatory activity in RA tends to remain stable or even improve over periods of 5 to 10 years while joint damage progresses⁴. However, when individual joints are followed separately, a significant association can be found between persistent clinical synovitis and joint destruction^{1,5-8}. Further, magnetic resonance imaging (MRI) shows clearly that bone damage is associated with preceding synovitis⁹.

Clinical examination of joints can be performed at every clinic visit, and may provide important information if carefully performed and recorded. We analyzed the data obtained from one of our cohorts of patients with early RA⁵ to study whether tenderness and/or swelling in wrist joints over the first 3 years of RA predict the development of erosions of the same joints at 5 years after the diagnosis.

MATERIALS AND METHODS

A total of 58 patients with early RA were enrolled in an early RA study at Jyväskylä Central Hospital in 1983-85⁵. The mean age of the patients was 48.0 years, duration of symptoms less than 2 years (mean 8.1 mo); 73% were female, 79% were rheumatoid factor positive, and all met the American College of Rheumatology criteria for RA^{10,11}.

From the Jyväskylä Central Hospital, Jyväskylä; Rheumatism Foundation Hospital, Heinola; and Turku University Central Hospital, Turku, Finland.

Supported in part by a grant from the Academy of Finland.

T. Sokka, MD, PhD, Jyväskylä Central Hospital and Vanderbilt University, Nashville, TN, USA; H. Kautiainen, BA, Rheumatism Foundation Hospital; T. Möttönen, MD, PhD, Turku University Central Hospital; P. Hannonen, MD, PhD, Jyväskylä Central Hospital.

Address reprint requests to Dr. T. Sokka, Division of Rheumatology and Immunology, Vanderbilt University School of Medicine, 203 Oxford House, Box 5, Nashville, TN 37232-4500.
E-mail: tuulikki.sokka@vanderbilt.edu

Submitted February 14, 2003; revision accepted May 21, 2003.

Physical examination including assessment of wrists for tenderness (0/1) and swelling (0/1) was performed 6 times over 3 years by the same observer (TM): at baseline and at 6, 12, 18, 24, and 36 months.

Monitoring of patients included radiographs of hands and feet taken at baseline and every one to 2 years thereafter. Radiographs were scored according to the Larsen method¹²⁻¹⁴. The radiographs were evaluated by Kaarela and Sokka¹⁵, all radiographs of one patient at the same time, in chronological order, blinded to information concerning patient's disease course and outcomes. For the purposes of the study, Larsen scores for the wrist joints at 5 years were dichotomized: a score of 0 or 1 referring to no erosion, and scores 2-5 indicating erosion.

Statistics. Descriptive statistics were used. For each wrist, a frequency was calculated for 4 inflammation categories — tenderness, swelling, tenderness or swelling, and tenderness and swelling — over the 3 years. For example, if the wrist was tender 3 times in 6 examinations, the frequency for tenderness was 3. Percentages of wrist joints with erosions on the 5-year radiographs were calculated for each frequency group (0, 1, 2-3, 4-6) of each of the 4 inflammation categories.

Since we found that the percentage of wrists with erosions increased in parallel with the increasing frequency of tenderness and/or swelling, we used the Cochran-Armitage test to examine whether the trend was statistically significant.

Statistically it would be preferable to use only one wrist of each patient, because of the interdependency of the wrists within the patient. Therefore, we also ran the analyses for the right wrists only, as well as for the left wrists only. The results were convergent with the total data. Thus, only the results for the total data are shown.

Two patients died during the first 5 years and were excluded from the analyses. Five wrists with erosive changes at baseline were also excluded. Thus, data for 107 wrist joints of 54 patients were available for calculations. Analyses were performed with the SPSS 11.0 and STATA 7.0 software.

The study was approved by the Ethics Committee of Jyväskylä Central Hospital.

RESULTS

Erosions developed in a total of 25 (23.4%) wrist joints during the 5-year period. A statistically significant trend ($p < 0.001$) was seen in the frequency of the categories of clinical inflammation in the wrist over the 3 years of followup and the presence of erosions of the same joint at the 5-year radiographs (Table 1, Figure 1).

Only one (3.3%) wrist without tenderness and 2 (4.4%) wrists without swelling in 6 examinations over the first 3 years had developed erosions after 5 years, while 13 (59.1%) wrists that were tender 4-6 times and 7 (50.0%) wrists that were swollen 4-6 times in 6 examinations had developed erosions during the followup. The corresponding percentages were 3.4% and 51.6% for the wrists with tenderness or swelling, and 6.1% and 75.0% for wrists with

Table 1. Percentage of wrists that developed erosions after 5 years, according to the frequency of an inflammation category over the first 3 years.

Category	Larsen Score at 5 Year Visit		Total
	0–1, Non-erosive (%)	2–5, Erosive (%)	
Frequency of tenderness over 3 yrs			
0	29 (96.7)	1 (3.3)	30
1	26 (89.7)	3 (10.3)	29
2–3	18 (69.2)	8 (30.8)	26
4–6	9 (40.9)	13 (59.1)	22
Total	82 (76.6)	25 (23.4)	107
p < 0.001*			
Frequency of swelling over 3 yrs			
0	43 (95.6)	2 (4.4)	45
1	21 (80.8)	5 (19.2)	26
2–3	11 (50.0)	11 (50.0)	22
4–6	7 (50.0)	7 (50.0)	14
Total	82 (76.6)	25 (23.4)	107
p < 0.001*			
Frequency of tenderness <i>or</i> swelling over 3 yrs			
0	28 (96.6)	1 (3.4)	29
1	23 (88.5)	3 (11.5)	26
2–3	16 (76.2)	5 (23.8)	21
4–6	15 (48.4)	16 (51.6)	31
Total	82 (76.6)	25 (23.4)	107
p < 0.001*			
Frequency of tenderness <i>and</i> swelling over 3 yrs			
0	46 (93.9)	3 (6.1)	49
1	23 (76.7)	7 (23.3)	30
2–3	11 (55.0)	9 (45.0)	20
4–6	2 (25.0)	6 (75.0)	8
Total	82 (76.6)	25 (23.4)	107
p < 0.001*			

* Cochran-Armitage trend with Monte-Carlo p values.

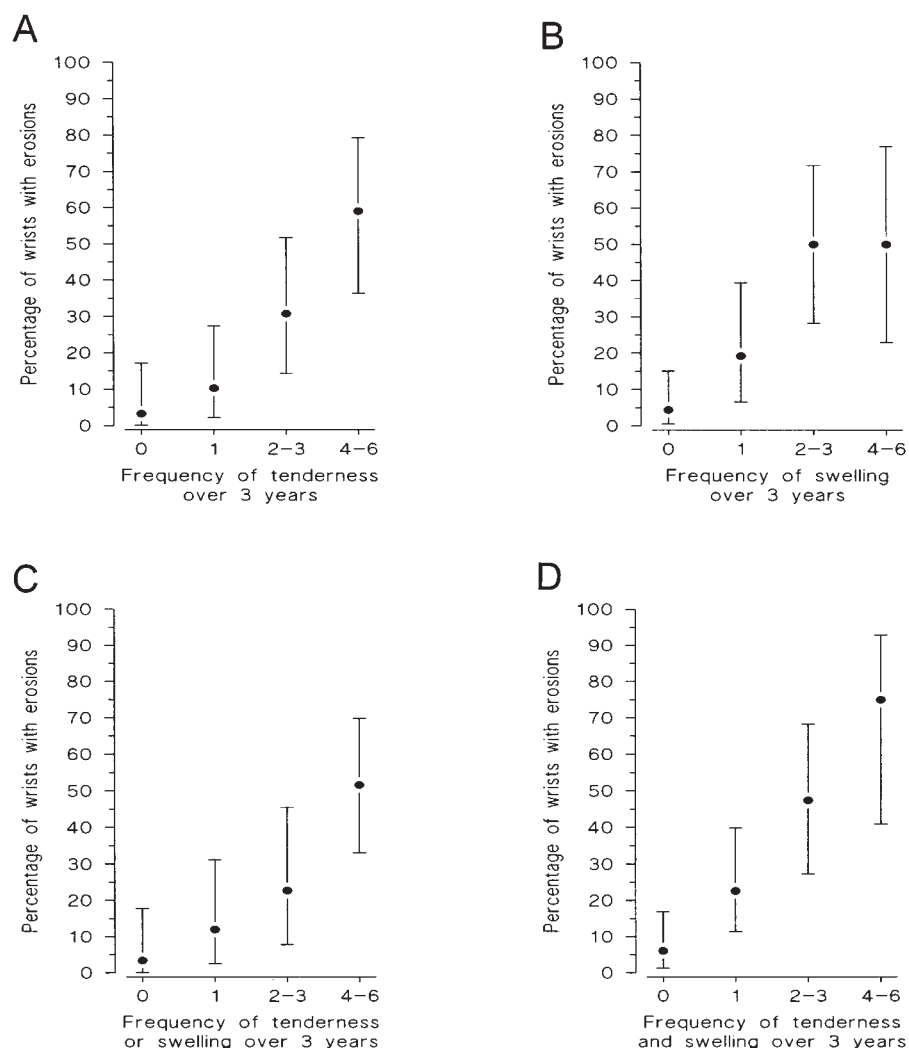


Figure 1. Percentage of wrists (95% CI) that developed erosions within 5 years, according to the frequency of an inflammation category over the first 3 years.

tenderness and swelling 0 times versus 4–6 times, respectively (Table 1, Figure 1).

DISCUSSION

The data presented here reconfirm the well established but recently less appreciated reports that rheumatoid erosions rarely appear in the joints without preceding clinically detectable inflammation. In the study by Luukkainen, *et al*¹, the Larsen erosion score increased in only 2 of 37 (5.4%) normal wrists (no tenderness and no swelling in 3 subsequent examinations) over 3 years. A previous report⁵ on the patients in our cohort showed that only 20 (4%) of 510 proximal interphalangeal (PIP) joints that did not show tenderness or swelling in 5 subsequent examinations developed new erosions over 2 years⁵. Only 11% of the wrists with clinical inflammation 0–1 time in 5 examinations over one year showed radiographic progression in the study by van

der Heide, *et al*⁶. Further, Hassell, *et al*⁷ reported that only 1.4% of PIP joints without clinically detectable inflammation in 3 examinations over 6 months showed 2 or more erosions in the 2-year radiographs, and 11% showed any erosive changes. Finally, a recent report regarding the COBRA trial, using more elaborate statistics, concluded that “local expression of disease activity is strongly related to the progression of damage in the individual joint”⁸.

Clinical examination of joints is prone to measurement errors. Indeed, lack of recorded tenderness and/or swelling of a joint that subsequently develops erosions may well be a measurement error rather than true absence of inflammation. Further, the interval with no information on the joint status between subsequent clinical examinations is several months in most cases. Therefore, more objective methods to detect synovitis have been called for. In the study by Möttönen, *et al*¹⁶, repeatedly inactive joints on the bone scan

(^{99m}technetium methylene-diphosphonate) over one year did not develop erosions over 2 years, while all but one of 47 joints that showed erosions at 2 years were active on the bone scan at all 3 subsequent examinations. More recently, sonography and magnetic resonance imaging (MRI)¹⁷⁻²⁰ have been used to predict and detect early erosions of individual joints with the suggestion that bony changes in RA are secondary to synovitis^{9,20}. However, while MRI and sonography remain useful as research tools only, repeated clinical examination of joints for tenderness and swelling is a cheap and always available measure for joint assessment.

The reports by the Kirwan group^{2,3,21}, to our knowledge, are the only ones in which no statistically significant correlation between clinically observable inflammation in individual joints and progression of radiographic erosions could be observed. However, they found progression of erosions at 2 years in 37% of the joints with synovitis (both tenderness and swelling simultaneously) recorded in at least 4 of 9 examinations. In our study the figures were comparable to Kirwan's results. A total of 23% and 52% of the joints with simultaneous tenderness and swelling 2–3 times and 4–6 times in 6 examinations, respectively, developed erosions at 5 years.

The data presented here do not explain why 23–50% of joints do not develop erosions while the frequency of tenderness and/or swelling suggests persistent inflammation (4–6 times of 6 occasions). An explanation might be the amount of inflammation of the joint as shown in an MRI study⁹ — the observation of tenderness and/or swelling was only dichotomized in our study, and severity of inflammation was not categorized. Further, all patients in our cohort were treated with disease modifying antirheumatic drugs, and systemic and local steroids were used when needed. While these drugs alleviate the signs and symptoms of inflammation in RA, they also retard development of erosions²², although the exact mechanisms of their actions remain largely unknown. On the other hand, experimental data suggest that inflammatory and destructive mechanisms in arthritides may differ at the molecular level; while tumor necrosis factor- α (TNF- α) is the primary cytokine used to determine the inflammatory activity, interleukin 1 (IL-1) appears to act as the driving agent in the erosive process²³. TNF- α also triggers the production of additional proinflammatory mediators including IL-1²⁴.

One of the limitations of our study is that it involved wrist joints only. Further, clinical data over only the first 3 years were analyzed, and there was a 2-year gap between the data of the last clinical assessment and the radiographic evaluation. However, it is known that there is a time lag between active joint inflammation and joint erosions²⁵. Nevertheless, the results of our study support the findings of several previous reports that joint erosions do not appear randomly but are preceded by clinically detectable symptoms and signs of inflammation in individual joints. Despite

the development of new imaging modalities with excellent discrimination properties to detect erosive changes early, their applicability and availability remain poor. Thus, careful repeated clinical examination of joints is not only an irreplaceable measure to guide therapy in patients with RA, but it is also a valuable method to predict erosiveness on clinical grounds.

ACKNOWLEDGMENT

We thank Dr. Theodore Pincus for inspiring discussions of the topic, and Dr. Kalevi Kaarela for instruction on analyzing radiographs.

REFERENCES

1. Luukkainen R, Kaarela K, Isomäki H, Kiviniemi P. Relationship between clinical synovitis and radiological destruction in rheumatoid arthritis. *Clin Rheumatol* 1983;2:223-6.
2. Kirwan JR. The relationship between synovitis and erosions in rheumatoid arthritis. *Br J Rheumatol* 1997;36:225-8.
3. Kirwan J, Byron M, Watt I. The relationship between soft tissue swelling, joint space narrowing and erosive damage in hand X-rays of patients with rheumatoid arthritis. *Rheumatology Oxford* 2001;40:297-301.
4. Pincus T, Sokka T. Partial control of Core Data Set measures and Disease Activity Score (DAS) measures of inflammation does not prevent long-term damage: evidence from longitudinal observations over 5–20 years. *Clin Exp Rheumatol* 2002;20 Suppl 27:S42-S48.
5. Mottonen TT. Prediction of erosiveness and rate of development of new erosions in early rheumatoid arthritis. *Ann Rheum Dis* 1988;47:648-53.
6. van der Heide A, Remme A, Hofman DM, Jacobs JWJ, Bijlsma JWJ. Prediction of progression of radiologic damage in newly diagnosed rheumatoid arthritis. *Arthritis Rheum* 1995;38:1466-74.
7. Hassell AB, Plant MJ, Clarke S, et al. Small joint synovitis in rheumatoid arthritis: Should it be assessed separately? *Br J Rheumatol* 1995;34:51-5.
8. Boers M, Kostense PJ, Verhoeven AC, van der Linden S. Inflammation and damage in an individual joint predict further damage in that joint in patients with early rheumatoid arthritis. COBRA Trial Group. *Arthritis Rheum* 2001;44:2242-6.
9. Conaghan PG, O'Connor P, McGonagle D, et al. Elucidation of the relationship between synovitis and bone damage: A randomized magnetic resonance imaging study of individual joints in patients with early rheumatoid arthritis. *Arthritis Rheum* 2003;48:64-71.
10. Ropes MW, Bennett GA, Cobb S, Jacox RF, Jessar RA. 1958 revision of diagnostic criteria for rheumatoid arthritis. *Bull Rheum Dis* 1958;9:175-6.
11. Arnett FC, Edworthy SM, Bloch DA, et al. The American Rheumatism Association 1987 revised criteria for the classification of rheumatoid arthritis. *Arthritis Rheum* 1988;31:315-24.
12. Larsen A, Dale K, Eek M. Radiographic evaluation of rheumatoid arthritis and related conditions by standard reference films. *Acta Radiol Diagn Stockh* 1977;18:481-91.
13. Larsen A. How to apply Larsen score in evaluating radiographs of rheumatoid arthritis in longterm studies? *J Rheumatol* 1995;22:1974-5.
14. Kaarela K, Kautiainen H. Continuous progression of radiological destruction in seropositive rheumatoid arthritis. *J Rheumatol* 1997;24:1285-7.
15. Sokka TM, Kaarela K, Mottonen TT, Hannonen PJ. Conventional monotherapy compared to a "sawtooth" treatment strategy in the radiographic procession of rheumatoid arthritis over the first eight years. *Clin Exp Rheumatol* 1999;17:527-32.
16. Mottonen TT, Hannonen P, Toivanen J, Rekonen A, Oka M. Value

- of joint scintigraphy in the prediction of erosiveness in early rheumatoid arthritis. *Ann Rheum Dis* 1988;47:183-9.
17. Wakefield RJ, Gibbon WW, Conaghan PG, et al. The value of sonography in the detection of bone erosions in patients with rheumatoid arthritis: a comparison with conventional radiography. *Arthritis Rheum* 2000;43:2762-70.
 18. Klarlund M, Ostergaard M, Jensen KE, Madsen JL, Skjodt H, Lorenzen I. Magnetic resonance imaging, radiography, and scintigraphy of the finger joints: one year follow up of patients with early arthritis. The TIRA Group. *Ann Rheum Dis* 2000;59:521-8.
 19. McQueen FM, Benton N, Crabbe J, et al. What is the fate of erosions in early rheumatoid arthritis? Tracking individual lesions using x-rays and magnetic resonance imaging over the first two years of the disease. *Ann Rheum Dis* 2001;60:859-68.
 20. McGonagle D, Conaghan PG, O'Connor P, et al. The relationship between synovitis and bone changes in early untreated rheumatoid arthritis: A controlled magnetic resonance imaging study. *Arthritis Rheum* 1999;42:1706-11.
 21. Hickling P, Jacoby RK, Kirwan JR, Arthritis and Rheumatism Council Low Dose Glucocorticoid Study Group. Joint destruction after glucocorticoids are withdrawn in early rheumatoid arthritis. *Br J Rheumatol* 1998;37:930-6.
 22. Pincus T, Ferraccioli G, Sokka T, et al. Evidence from clinical trials and long-term observational studies that disease-modifying anti-rheumatic drugs slow radiographic progression in rheumatoid arthritis: updating a 1983 review. *Rheumatology Oxford* 2002;41:1346-56.
 23. van den Berg WB. Uncoupling of inflammatory and destructive mechanisms in arthritis. *Semin Arthritis Rheum* 2001;30 Suppl 2:7-16.
 24. Williams RO, Feldmann M, Maini RN. Cartilage destruction and bone erosion in arthritis: the role of tumour necrosis factor alpha. *Ann Rheum Dis* 2000;59 Suppl 1:i75-i80.
 25. Matsuda Y, Yamanaka H, Higami K, Kashiwazaki S. Time lag between active joint inflammation and radiological progression in patients with early rheumatoid arthritis. *J Rheumatol* 1998;25:427-32.