Severe Cardiac Involvement in Children with Systemic Sclerosis and Myositis

PIERRE QUARTIER, DAMIEN BONNET, JEAN-CHRISTOPHE FOURNET, CHRISTINE BODEMER, PHILIPPE ACAR, MARIE OUACHÉE-CHARDIN, JÉROME LE BIDOIS, and ANNE-MARIE PRIEUR

ABSTRACT. ***Objective.*** To assess the outcome of children with systemic sclerosis (SSc) and features of polymyositis.

Methods. The charts of 4 children who met the American College of Rheumatology criteria for SSc and had features of polymyositis, as defined by the presence of proximal muscle weakness and elevated serum creatine phosphokinase or aldolase level, were retrospectively reviewed.

Results. All children had multivisceral involvement including (1) myocardial perfusion defects in all cases, with mild to severe dilated cardiomyopathy in 3; (2) lung restrictive syndrome in 3; (3) mild to severe esophageal involvement in all cases; and (4) severe intestinal dysfunction in one child. Combination therapy of corticosteroids, methotrexate (MTX), and cyclosporine resulted in improved skin thickness and muscle strength scores in all cases, as well as in lung restrictive syndrome in 2, but was not effective regarding the progression of intestinal malabsorption in one patient, esophageal dysmotility in 3 patients, and dilated cardiomyopathy in 3. Endstage cardiac failure caused 2 deaths. In one child, heart transplantation was performed for the first time in this indication.

Conclusion. Children with diffuse cutaneous SSc and features of polymyositis are prone to develop severe cardiomyopathy. Combination therapy of corticosteroids, MTX, and cyclosporine seems to be active on muscle, skin, and lung involvement but does not impair progression of esophageal or myocardial dysfunction. Heart transplantation might be considered, as an experimental treatment, in young patients with severe cardiomyopathy and no other irreversible organ damage. (J Rheumatol 2002:29:1767–73)

Key Indexing Terms:
SYSTEMIC SCLEROSIS MYOSITIS CHILD
CARDIOMYOPATHY IMMUNOSUPPRESSION HEART TRANSPLANTATION

Diffuse cutaneous systemic sclerosis (SSc) is a rare multisystem connective tissue disease characterized by extensive skin thickening and multiorgan involvement[1]. Adult patients with diffuse cutaneous SSc and skeletal muscle inflammation are particularly prone to develop severe cardiomyopathy and have therefore a particularly poor prognosis[2]. In children, scleroderma is often localized and has therefore an overall good prognosis regarding survival[3-7]. The association of scleroderma- and polymyositis-like features may be observed in several overlap syndromes, also with favorable prognosis in most cases[3,4,8]. The outcome of the few children who develop diffuse cutaneous SSc with internal organ involvement and myositis has never been specifically studied. We describe the characteristics of 4 of these children and their outcome under combination therapy by corticosteroids, cyclosporine, and methotrexate.

From the Unité d'immunologie-hématologie et rhumatologie pédiatrique, Service de cardiologie pédiatrique, Service d'anatomo-pathologie, and Service de dermatologie pédiatrique, Hôpital Necker-Enfants Malades, Paris, France.

P. Quartier, MD, Unité d'immunologie-hématologie et rhumatologie pédiatrique; D. Bonnet, MD, PhD, Service de cardiologie pédiatrique; J-C. Fournet, MD, PhD, Service d'anatomo-pathologie; C. Bodemer, MD, PhD, Service de dermatologie pédiatrique; P. Acar, MD, Service de cardiologie pédiatrique; M. Ouachée-Chardin, MD, Unité d'immunologie-hématologie et rhumatologie pédiatrique; J. Le Bidois, MD, Service de cardiologie pédiatrique; A-M. Prieur, MD, Unité d'immunologie-hématologie et rhumatologie pédiatrique.

Address reprint requests to Dr. P. Quartier, Unité d'immuno-hématologie et rhumatologie pédiatrique, Hôpital Necker-Enfants Malades, 149 rue de Sèvres, 75 743 Paris cedex 15, France.

Submitted June 4, 2001; revision accepted February 27, 2002.

MATERIALS AND METHODS

Among 72 children referred to our institution for scleroderma between April 1992 and March 1998 (including 56 cases of localized scleroderma, 4 diffuse scleroderma without visceral involvement, 6 with overlap syndromes, and 6 diffuse cutaneous SSc with visceral involvement), 4 girls met the American College of Rheumatology criteria for SSc[1] and had diffuse cutaneous involvement and features of polymyositis, as defined by the presence of proximal muscle weakness and elevated serum creatine phosphokinase (CPK) or aldolase level. Their charts were retrospectively reviewed.

These 4 patients have been treated with a combination of corticosteroids, cyclosporine, and methotrexate (MTX). From the start of combination therapy to the most recent examination, on December 7, 2001, patient survey information has included height/weight measurements, functional assessment using the Childhood Health Assessment Questionnaire (CHAQ) when available[9], and periodic assessment for skin involvement, muscle weakness and visceral manifestations.

Skin involvement and muscle weakness. Skin thickness was assessed by the same dermatologist using a classical 4 grade severity scale (from 0 to 3) on 5 different sites (forearms, lower legs, chest, upper arms, and finger) to

Personal non-commercial use only. The Journal of Rheumatology Copyright © 2002. All rights reserved.

Downloaded on April 18, 2024 from www.jrheum.org

obtain a score out of 15, which has been shown to correlate closely with the classical modified Rodnan score[10]. Skin involvement was also assessed based on presence of edema of the hands and feet, pigmentation abnormalities, telangiectasias, atrophy, or skin ulcerations. Vascular/microvascular involvement included assessment for the presence of Raynaud's phenomenon, and nailfold capillaroscopy was systematically performed at diagnosis. For muscle weakness assessment, we considered the measures taken by the same physiotherapist using a 10 point manual muscle test on several muscles, and added the values obtained for 16 distinct muscles for a total score of 160, as described by Adams, *et al*[11]. Serum CPK, aldolase, and transaminase levels were measured repeatedly. Muscle biopsies when available were processed for histological analysis.

Organ involvement. Kidney involvement was defined as presence of proteinuria or serum creatinine concentration above normal values corrected for age or elevated blood pressure that could not be related to corticosteroid therapy. Esophageal involvement was assessed by esophageal manometry showing abnormal lower sphincter pressure and/or motility disturbances. The diagnosis of small bowel involvement was retained in case of chronic diarrhea (over 3 mo) with biological evidence of malabsorption. Lung function was considered to be impaired in case of pulmonary function tests showing forced vital capacity or diffusing capacity for carbon monoxide (DLCO) under 80% of the theoretical values for sex, age, and height. Heart function was assessed by isotopic left ventricular ejection fraction (LVEF) measurement, using thallium 201, and by sequential echocardiographic left ventricular shortening fraction measurements. We also collected the results of myocardial perfusion imaging studies using thallium 201, selective coronary artery angiograms, and heart catheter when available.

Assessment for autoimmune markers included tests for antinuclear and anticentromere antibodies by indirect fluorescence on HEp-2 cells, antibodies to RNP, Sm, SSA/Ro, SSB/La, PM-1/PM-Scl, and Scl-70 by double immunodiffusion, anti-Ku antibodies by counterimmunoelectrophoresis, anti-dsDNA antibodies by the radioimmunoassay-Farr technique, anticardiolipin antibodies by ELISA, and rheumatoid factor by both latex agglutination and the Waaler-Rose test.

RESULTS

Patient characteristics. Four girls had diffuse cutaneous SSc with features of polymyositis and visceral involvement. Their main characteristics on admission are shown in Table 1. In the 4 patients, skin thickening was diffuse, involving the face, neck, and hands, as well as the extensor surfaces of the knees, elbows and wrists. Hypo- or hyper-pigmented skin was seen in the first 3 patients on the extensor surfaces of the interphalangeal articulations of the hands, on the back, and proximal to the elbows and knees. Digital skin ulcers were present at diagnosis in 3 children. Capillaroscopy showed loss of capillaries in localized areas adjacent to enlarged capillaries. Our 4 patients had muscle weakness that was predominantly proximal and associated with increased serum concentrations of muscle enzymes. In addition to elevated CPK level, which was shown to be related to elevated CPK MM isoenzyme in Patients 1, 2, and 4, the 4 children had elevated serum aldolase levels either on admission or within the following months. Muscle biopsy was performed in the 2 patients who had both the most severe muscle involvement on muscle weakness assessment and the higher levels of serum muscle enzymes. In both cases histological analysis showed acute myositis with muscular fiber necrosis, muscular atrophy, and fibrosis. In the 2 other patients, muscle biopsy was not performed because they had milder muscle disease.

Dysphagia was seen in 3 children and was limited to difficulties in swallowing solid food. Esophageal dysfunction consisted of aperistalsis in one patient and marked hypomotility in 2 patients. Dilated cardiomyopathy was present on admission in the third patient. Echocardiography showed a severely hypokinetic left ventricle, and isotopic myocardial perfusion imaging revealed a large anteroseptal defect that was not reversible after intravenous (IV) persantine infusion. In Patient 4, echocardiography showed a moderate hypocontractility of the left ventricle. Isotopic myocardial perfusion imaging was performed 2 months later and showed mild perfusion defects in the anterior region of the myocardium that were reversible after persantine infusion.

Treatment and outcome. Patient 1 was initially treated with oral prednisone (1 mg/kg per day for 3 mo, then 0.3 mg/kg per day for 38 mo) successively combined with MTX (15 to 20 mg/m^2 per week intramuscularly, months 9 to 33) and D-penicillamine (5 mg/kg per day, months 34 to 39). Therapeutic changes were motivated by disease progression. While receiving these treatments, more extensive muscle involvement (month 6), Raynaud's phenomenon (month 6), widespread skin ulcerations (month 11), severe intestinal malabsorption, and repeated episodes of intestinal pseudoobstruction (month 30), dilated cardiomyopathy, chest pain, and inferior myocardial infarction (month 37) developed. The child in question was being treated with captopril (0.7 mg/kg per day). In February 1996, 40 months after admission, combined therapy with cyclosporine (3 mg/kg per day orally), MTX (20 mg/m^2 per week intramuscularly), and prednisone (0.5 mg/kg per day orally) was initiated. As shown in Table 2, a slight improvement of skin thickness score and muscle strength score was observed, but diarrhea and malabsorption persisted, esophageal involvement progressed, and the child eventually died of endstage cardiac failure.

Patient 2 was treated in the month following her first admission by a combination of prednisone (2 mg/kg per day, then progressively tapered to 0.3 mg/kg per day over 2 yrs and discontinued after 3 yrs), cyclosporine (3 mg/kg per day orally), MTX (20 mg/m^2 orally every week for 2 yrs, every 2 weeks for 6 mo and then discontinued), and pulsed IV methylprednisolone (0.6 g/m^2 once daily for 5 days, twice weekly for 2 weeks, once weekly for 2 weeks, twice monthly for 3 mo, once monthly for 6 mo, once every 2 mo for 26 mo and then discontinued). Skin thickness score markedly improved and muscle strength progressively reached normal values (Table 2). Dysphagia persisted and motility disturbances on esophageal manometry worsened. After 48 months, echocardiography was still normal, but ventricular premature beats were evidenced on electrocardiographic/Holter monitoring. She underwent a first

Personal non-commercial use only. The Journal of Rheumatology Copyright © 2002. All rights reserved.

Downloaded on April 18, 2024 from www.jrheum.org

Table 1. Patient characteristics on admission.

	Patient 1	2	3	4
Sex, age, yrs	F, 9	F, 8	F, 13	F, 13
Disease duration, mo	4	8	7	14
Weight loss, kg	6	1	6	1.5
Skin thickness score (out of 15*)	10	10	6	9
Raynaud's phenomenon	–	+	+	+
Skin ulceration	–	+	+	+
Abnormal capillaroscopy[†]	+	+	+	+
Muscle strength score (out of 160[††])	115	119	105	147
Serum CPK level (N < 120 U/l)	413	211	7,560	140
Histological anomalies on muscle biopsy	+	NA	+	NA
FVC, % (N > 80% theoretical values)	42	82	75	74
DLCO, % (N > 80% theoretical values)	N	101	128	104
Dysphagia	+	+	+	–
Esophagus manometry anomalies	+	+	+	+
Echocardiographic LVSF, % (N > 35%)	37	37	15	27
Isotopic LVEF (N > 55%)	NA	NA	26	NA
Blood pressure, serum creatinine level	N	N	N	N
Chronic diarrhea or malabsorption	–	–	–	–
Arthritis	–	–	+	+
Antinuclear antibodies (N < 1/80)	1/320[§,#]	1/1280[¶,#]	–	1/640[¶,#]
Anti-tissue antibodies**	–	–	–	–

CPK: creatine phosphokinase; N: normal; NA: not available; FVC: Forced vital capacity; DLCO: diffusing capacity for carbon monoxide; LVSF: left ventricular shortening fraction; LVEF: left ventricular ejection fraction; * 4 grade severity scale (0 to 3) on 5 sites (forearms, lower legs, chest, upper arms, finger); [†] loss of capillaries in localized areas adjacent to enlarged capillaries; [††] by adding the values obtained for 16 distinct muscles using a 10 point manual muscle test[9]; [§] homogeneous flourescence pattern; [#] non-specific for antibodies to RNP, SM, SSA, SSB, or Scl 70-JO1; [¶] speckled fluorescence pattern; ** anti-Ku, anti-smooth muscle, anti-type 5 mitochondria.

Table 2. Patient outcome at followup after initiation of combination therapy of methotrexate, cyclosporine, and corticosteroids.

	Patient 1				2				3				4			
Time from treatment onset, mo	0*	6	12	18	0	6	12	60	0	6	12	30	0	8	12	27
Skin thickness score (out of 15[†])	10	7	8	NA	10	8	7	3	6	NA	NA	3	9	8	6	4
Muscle strength score (out of 160[‡])	102	113	NA	115	119	130	149	160	105	122	127	148	147	NA[§]	NA[§]	154
Lung: FVC (% theoretical value)	46	NA[§]	NA[§]	NA[§]	82	86	85	93	75	76	85	95	74	43	52	69
Esophagus (dysphagia)	+	+	+	+	+	+	+	+	+	+	+	+	0	0	0	0
Lower sphincter pressure, mm Hg (N = 22 ± 10)	4	NA	NA[§]	NA[§]	8	0	0	0	0	0	0	0	10.5	NA[§]	NA[§]	12
Motility disturbances[#]	++	Aperistalsis			++	+++	+++	+++	++	+++	+++	+++	++	NA[§]	NA[§]	++
Gut (diarrhea, malabsorption, pseudoobstruction)	+[¶]	+	+	+	–	–	–	–	–	–	–	–	–	–	–	–
Heart (arrhythmia requiring treatment)	0	0	0	0	0	0	0	0	0	0	+	+	0	0	0	0
Echographic LVSF, % (N > 35%)	15**	12	15	< 10	37	36	36	38	15	15	10	11	27	11	39[††]	37[‡‡]
Isotopic LVEF, % (N > 55%)	NA	NA	24	NA	NA	NA	NA	62	NA	NA	26	NA	NA	32	NA	65[‡‡]
CHAQ value at most recent checkup	NA				0.125				NA				0.750[§§]			
Death/survival	Death 19 mo[##]				Alive 69 mo				Death 32 mo[##]				Alive 33 mo[§§]			

NA: not available; N: normal; FVC: forced vital capacity; LVSF: left ventricular shortening fraction; LVEF: left ventricular ejection fraction; CHAQ: Childhood Health Assessment Questionnaire[9]; * 40 months from admission; [†] 4 grade severity scale (0 to 3) on 5 sites (forearms, lower legs, chest, upper arms, finger) to obtain a score out of 15; [‡] score out of 160[10]; [§] investigation not performed because of patient's poor clinical condition; [#] ++: distal and middle thirds, +++: whole esophagus; [¶] symptoms developed 12 months before; ** dilated cardiomyopathy was detected 3 months before; [††] 1 month, [‡‡] 19 months, and [§§] 23 months after heart transplantation; [##] end stage cardiac failure.

Personal non-commercial use only. The Journal of Rheumatology Copyright © 2002. All rights reserved.

Downloaded on April 18, 2024 from www.jrheum.org

isotopic myocardial perfusion study, which showed a normal LVEF value, but slight perfusion defects of the anterior territory that were reversible after persantine infusion. At a recent complete examination, 60 months after treatment initiation, her clinical status was stable, with a CHAQ score of 0.125 (out of 3) and school attendance normal; treatment consisted of oral cyclosporine only. Repeat isotopic myocardial perfusion study was the same as at 12 months prior (Table 3).

Patient 3, who had developed severe dilated cardiomyopathy prior to admission (Table 3), received the same combination therapy one month after her first admission at the same doses as Patient 2. She was also being treated with enalapril (0.3 mg/kg per day) and diltiazem (0.7 mg/kg per day). Skin thickness and muscle strength scores markedly improved. Lung restrictive syndrome progressively resolved (Table 2). Dysphagia persisted and sequential manometric examinations showed worsening of esophageal dysmotility. Cardiac ventricular arrhythmia was evidenced after 12 months and was treated by low doses of amiodarone (3 mg/kg per day). However, the child could attend school normally and have nearly normal physical activity for 30 months, including short bicycle riding. After 30 months, intractable congestive heart failure developed while she was still taking prednisone 0.3 mg/kg per day, MTX 20 mg/m^2 orally every 2 weeks, and cyclosporine. Myocardial perfusion imaging study showed diffuse myocardial perfusion defects, while selective coronary artery angiogram was normal. She was proposed for heart transplantation but she died under mechanical ventilation. Postmortem examination of the myocardium showed diffuse interstitial fibrosis with replacement of cardiomyocytes by collagen fibers. This process affected the whole myocardium but predominated in the subendocardial zone. No inflammatory cellular infiltrate or vasculitis was seen (Figure 1A).

Patient 4 received the same treatment as Patients 2 and 3 in the month after her first admission. However, oral prednisone was administered at a dosage of 0.5 mg/kg per day and was discontinued after 6 months for 2 months, as was IV methylprednisolone, when the child went to Algeria for holiday. Eight months from treatment initiation, she was admitted for congestive heart failure. Echocardiography showed severe dilated cardiomyopathy. Isotopic LVEF measurement showed a value of 32%. Myocardial perfusion isotopic study showed diffuse perfusion defects that were not reversible after IV persantine infusion, while selective coronary artery angiogram was normal (Table 3). Prednisone was reintroduced at the dose of 2 mg/kg per day. After several admissions for cardiac failure requiring inotropic support, she was finally proposed for heart transplantation. Heart transplantation was performed 3 months after first admission for cardiac failure. Histological analysis of the heart showed a diffuse fibrosis of interstitial tissue of myocardium. Cardiomyocytes were rarefied by the fibrosing process. No inflammatory cellular infiltrates or signs of vasculitis were seen (Figure 1B). Post-transplant treatment consisted of antithymocyte globulin, corticosteroids, azathioprine, and tacrolimus. Eight months after heart transplantation, routine electrocardiogram showed ischemic changes in the inferior leads. Selective coronary artery angiogram showed severe stenosis of the mild portion of the right coronary artery and less severe stenosis of the distal right coronary artery. The severe right coronary stenosis was successfully dilated and stented. Myocardial biopsy did not show any significant abnormality. Coronary arteries were reassessed 4 months later by angiography and intracoronary ultrasound and showed no significant stenosis. At the more recent examination, 34 months after first admission and 23 months after cardiac transplantation, the patient was doing clinically well with a CHAQ score of

Table 3. Characteristics of the patients' cardiac disease.

	Patient			
	1	2	3	4
Clinical symptoms	M39 angor + dyspnea; M42 congestive heart failure	None	M0 exertional dyspnea; M30 congestive heart failure	M8 congestive heart failure; (M11 heart transplantation)
EKG/Holter	M31 normal; M37 necrosis (Q wave) in the inferior leads	M48: some premature ventricular beats; M60 normal	M0 premature auricular beats; M12 ventricular arrhythmia	M0–11 some premature ventricular beats
Echocardiography	M37 inferior myocardial infarction, LVSF 15%*	Normal	M0 LVSF = 15%*; M12 LVSF = 10%*	M0 LVSF= 27%; M8 LVSF = 11%*
Isotopic imaging	M52 diffuse perfusion defects†, LVEF 24%	M48 & 60 slight perfusion defects‡, LVEF normal	M0 & M12 diffuse perfusion defects†, LVEF 26%	M2 slight perfusion defects‡; M8 diffuse†, LVEF 32%
RV catheterism	M52 normal	ND	M30 normal	M10 normal
Coronary arteriography	M52 normal	ND	M30 normal	M10 normal§
Heart histology	ND	ND	M31 diffuse fibrosis	M11 diffuse fibrosis

M: months from first admission; LVSF: left ventricular shortening fraction (N > 55%); LVEF: left ventricular ejection fraction (N > 55%); RV, right ventricular; ND: not done; * dilated cardiomyopathy; † no reversibility after persantine infusion; ‡ myocardial perfusion defects were limited to the anterior region of the myocardium and reversible after persantine infusion; § coronary disease developed after heart transplantation (see text).

Personal non-commercial use only. The Journal of Rheumatology Copyright © 2002. All rights reserved.

Downloaded on April 18, 2024 from www.jrheum.org

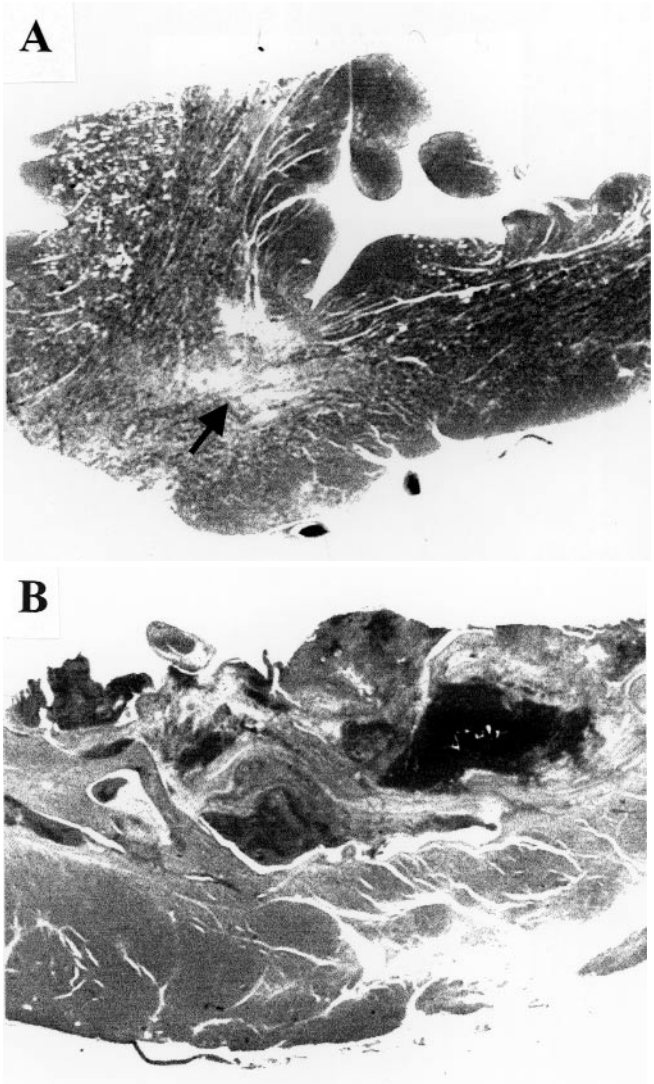

Figure 1. Histological overview (low magnification) of the myocardium wall in Patient 3 (A) and Patient 4 (B). Diffuse mutilant interstitial fibrosis (arrow), associated in Patient 3 with recent mural thrombosis.

0.625, while still taking prednisone (0.12 mg/kg per day), azathioprine (1.5 mg/kg per day), and tacrolimus (0.26 mg/kg per day). She was attending school normally and doing figure skating. Echocardiography showed a normal left ventricular contraction (shortening fraction 39%). Electrocardiogram and exercise test showed no arrhythmia and no sign of ischemia. Coronary arteriography showed no significant stenosis but a progression of diffuse coronary lesions.

To date, no renal insufficiency, interstitial syndrome on chest radiography, alteration of DLCO, or pulmonary hypertension have developed in these children. Mild lung fibrosis could not be excluded in Patient 4, whose lung capacity was always below normal values. Pulmonary artery pressure, which was regularly assessed by echocardiography in all cases and measured on one or 2 occasions by pulmonary artery catheterization in all children, except Patient 2, has always been within the normal values.

DISCUSSION

The association of diffuse cutaneous SSc with skeletal muscle and myocardial involvement may represent a particular form of the disease. Although exceptional in childhood, this association has been reported to have a bimodal distribution of ages at the time of diagnosis, with a first peak at about 20 years[2]. In a recent survey of 135 children with SSc, cardiac involvement was the main cause of death, which occurs in the small subgroup of patients with diffuse cutaneous SSc[7]. Muscle disease has been reported in 20% to 40% of children with SSc and scleroderma-like disorders, but most of these patients have an overlap syndrome that is more inflammatory and similar to polymyositis than the primary myopathy of SSc, and which has a rather benign course in most cases[4]. Some of these children have a so-called "scleromyositis" syndrome, characterized by the association of myalgia-myositis, arthralgia-arthritis, puffy atrophic sclerotic fingers, and Raynaud's phenomenon, but no extensive scleroderma or internal organ involvement. PM-Scl antibody has been reported to be a diagnostic marker of this syndrome[8,12]. In our 4 patients, myopathy was insidious; it was not associated with the muscle-specific autoantibodies of the overlap syndrome, such as anti-Ku and anti-PM-Scl antibodies. Two children met criteria of Bohan and Peter for probable polymyositis[13], with muscle biopsies early in the course of the disease that showed both acute myositis and muscular fibrosis, while the 2 other patients only met criteria for possible polymyositis.

The contrast between the beneficial effect of combination therapy (with corticosteroids and immunosuppressive drugs) on skin thickness, muscle strength, and lung function tests, and its lack of efficacy for more severe visceral involvement is in accord with previous reports[4,14,15]. Esophageal motility disturbances seem to be particularly resistant to immunosuppressive therapy[16], even if improvement has been described in some patients[17]. The improvement of lung function tests in 2 of our patients may have been at least partially related to the gain in muscle strength. In some cases, however, intensive immunosuppressive therapy, including antithymocyte globulins, high dose cyclophosphamide, and autologous hematopoietic stem cell transplantation, may provide marked improvement of lung function tests in patients with SSc and severe pulmonary involvement[15]. We have chosen not to administer cyclophosphamide since it is not always well tolerated in SSc patients with cardiomyopathy. Early combination therapy with corticosteroids, MTX, and cyclosporine was attractive since it is effective in preventing chronic graft versus host disease, a disease often mimicking SSc, after hematopoietic stem cell transplantation[18]. More experience

Personal non-commercial use only. The Journal of Rheumatology Copyright © 2002. All rights reserved.

Downloaded on April 18, 2024 from www.jrheum.org

is required to see if it is a valuable approach in diffuse cutaneous SSc.

Cardiac involvement. Cardiac involvement was a prominent feature that was associated with a severe outcome in this report as in series of adult patients with SSc and myositis[2]. The observation in our 4 patients of myocardial perfusion defects, associated in 3 cases with severe dilated cardiomyopathy, but normal selective coronary artery angiograms, fits well with descriptions in adults and with the hypothesis of impairment of myocardial microcirculation[19]. In addition, no inflammation of the heart was found on post mortem or post-transplantation histological analysis in 2 patients here, which was in accord with the findings of a large series of adult patients, where active myocardial inflammation was rarely observed at autopsy[2].

However, immunosuppressive treatments may well have contributed to the lack of inflammation in our patients. In some SSc patients, myocardial mononuclear cell inflammatory infiltrate was found at an early stage and involved activated T lymphocytes[20]. This might precede the constitution of diffuse fibrosis. In this regard, the assessment of myocardial inflammation using biological markers, such as measurements of troponin activity, would be interesting in such patients. Early detection of myocardial involvement should also probably involve the use of myocardium scintigraphy early in the course of disease. In our series, thallium 201 scintigraphy was systematically abnormal and could detect perfusion defects in Patients 2 and 4 at a stage where other examinations disclosed no or only mild anomalies. In adult SSc patients, 1231-MIBG scintigraphy was shown to be more sensitive than electrocardiography/Holter and echocardiography in detecting specific myocardium involvement[21].

Whether early immunosuppressive therapy prevents severe cardiomyopathy in some patients with diffuse cutaneous SSc and skeletal muscle involvement is still hypothetical. After diffuse cardiac sclerosis has developed, heart transplantation might be considered in some patients in the absence of other irreversible organ damage. Lung and kidney transplants have been successfully performed in patients with SSc[22,23]. In addition, heart transplantation is associated with a 2 year survival rate of 80% in children with various cardiac diseases including dilated cardiomyopathies[24]. Nevertheless, this has never been performed in patients with SSc. Here, heart transplantation was associated with an early coronary thrombosis, which was unusual since this complication usually occurs after several years[24]. We cannot exclude that the underlying disease was partially responsible for this early coronary disease. However, endomyocardial biopsies done when coronary artery stenosis was diagnosed showed no anomaly suggesting cardiac involvement of SSc.

The progression of a diffuse coronary disease at the more recent followup raises the question of considering a second heart transplantation within the coming months or years. More experience and longer followup are required to determine the risk of disease recurrence on the transplanted heart, and whether it might be prevented by immunosuppressive treatment administered after solid organ transplantation.

ACKNOWLEDGMENT

We thank Valérie Bughin, physiotherapist, for her contribution. We are indebted to Annick Delcourt and Nicole Brousse for excellent histologic analysis.

REFERENCES

1. Subcommittee for Scleroderma Criteria of the American Rheumatism Association Diagnostic and Therapeutic Criteria Committee. Preliminary criteria for the classification of systemic sclerosis (scleroderma). Arthritis Rheum 1980;23:581-90.
2. Follansbee W, Zerbe T, Medsger T. Cardiac and skeletal muscle disease in systemic sclerosis (scleroderma): A high risk association. Am J Heart 1993;125:194-203.
3. Black C. Prognosis and management of scleroderma and scleroderma-like disorders in children. Clin Exp Rheumatol 1994;12:S75-S81.
4. Uziel Y, Miller ML, Laxer RM. Scleroderma in children. Pediatr Clin North Am 1995;42:1171-203.
5. Vancheeswaran R, Black C, David J, et al. Childhood-onset scleroderma. Arthritis Rheum 1996;39:1041-9.
6. Bodemer C, Belon M, Hamel-Teillac D, et al. Scleroderma in children: a retrospective study of 70 cases [French]. Ann Dermatol Venereol 1999;126:691-4.
7. Foeldvari I, Zhavania M, Birdi N, et al. Favourable outcome in 135 children with juvenile systemic sclerosis: results of a multi-national survey. Rheumatology 2000;39:556-9.
8. Jablonska S, Blaszczyk M. Scleromyositis: a scleroderma/polymyositis overlap syndrome. Clin Rheumatol 1998;17:465-7.
9. Pouchot J, Ruperto N, Lemelle I, et al. The French version of the Childhood Health Assessment Questionnaire (CHAQ) and the Child Health Questionnaire (CHQ). Clin Exp Rheumatol 2001;19 Suppl 23:S60-5.
10. Silman A, Harrison M, Brennan P. Is it possible to reduce observer variability in skin score assessment of scleroderma? The ad hoc International Group on the Assessment of Disease Outcome in Scleroderma. J Rheumatol 1995;22:1277-80.
11. Adams E, Pucino F, Yarboro C, et al. A pilot study: Use of fludarabine for refractory dermatomyositis and polymyositis, and examination of endpoint measures. J Rheumatol 1999;26:352-6.
12. Blaszczyk M, Jablonska S, Szymanska-Jagiello W, Jarzabek-Chorzelska M, Chorzelski T, Mohamed A. Childhood scleromyositis: an overlap syndrome associated with PM-Scl antibody. Pediatr Dermatol 1991;8:1-8.
13. Bohan A, Peter JB. Polymyositis and dermatomyositis. N Engl J Med 1975;292:403-7.
14. Denton CP, Black CM. Scleroderma and related disorders: therapeutic aspects. Baillieres Best Pract Res Clin Rheumatol 2000;14:17-35.
15. Martini A, Maccario R, Ravelli A, et al. Marked and sustained improvement two years after autologous stem cell transplantation in a girl with systemic sclerosis. Arthritis Rheum 1999;42:807-11.
16. Hendel L, Stentoft P, Aggestrup S. The progress of oesophageal involvement in progressive systemic sclerosis during D-penicillamine treatment. Scand J Rheumatol 1989;18:149-55.
17. Dantas R, Meneghelli U, Oliveira R, Villanova M. Esophageal dysfunction does not always worsen in systemic sclerosis. J Clin Gastroenterol 1993;17:281-5.

Personal non-commercial use only. The Journal of Rheumatology Copyright © 2002. All rights reserved.

Downloaded on April 18, 2024 from www.jrheum.org

18. Chao N, Schmidt G, Niland J, et al. Cyclosporine, methotrexate, and prednisone compared with cyclosporine and prednisone for prophylaxis of acute graft-versus-host disease. N Engl J Med 1993;329:1225-30.
19. Follansbee W, Curtiss E, Medsger T, et al. Physiologic abnormalities of cardiac function in progressive systemic sclerosis with diffuse scleroderma. N Engl J Med 1984;310:142-8.
20. Liangos O, Neure L, Kuhl U, et al. The possible role of myocardial biopsy in systemic sclerosis. Rheumatology 2000;39:674-9.
21. Gurtner C, Werner RJ, Winten G, et al. Early diagnosis of cardiac involvement in systemic sclerosis by 1231-MIBG. Nucl Med Commun 1998;19:849-57.
22. Pigula F, Griffith B, Zenati M, Dauber J, Yousem S, Keenan R. Lung transplantation for respiratory failure resulting from systemic disease. Ann Thorac Surg 1997;64:1630-4.
23. Chang Y, Spiera H. Renal transplantation in scleroderma. Medicine (Baltimore) 1999;78:382-5.
24. Shaddy RE, Naftel DC, Kirklin JK, et al. Outcome of cardiac transplantation in children. Survival in a contemporary multi-institutional experience. Pediatric Heart Transplant Study. Circulation 1996;94:69-73.

Personal non-commercial use only. The Journal of Rheumatology Copyright © 2002. All rights reserved.

Downloaded on April 18, 2024 from www.jrheum.org