

# Gelatinase Expression and Activity in the Synovium and Skin of Patients with Erosive Psoriatic Arthritis

CAROL A. HITCHON, CAROL L. DANNING, GABOR G. ILLEI, HANI S. EL-GABALAWY,  
and DIMITRIOS T. BOUMPAS

**ABSTRACT. Objective.** Matrix metalloproteinases (MMP), especially the gelatinases (MMP2, MMP9), have been implicated in several features of inflammatory arthritis including angiogenesis and bone erosions. We examined the expression and activity of the gelatinases and their regulators in psoriatic skin and synovium using tissue immunohistochemistry and a sensitive tissue based zymographic technique.

**Methods.** Lesional and perilesional skin biopsies and synovial samples obtained by closed needle biopsy from 15 patients with erosive psoriatic arthritis (PsA) were analyzed by immunohistochemistry for the expression of the gelatinases and their regulators, tissue inhibitor of metalloproteinase 1 and 2 (TIMP-1, TIMP-2) and membrane type metalloproteinases (MT1-MMP, MT2-MMP), using immunohistochemistry. Synovial tissue from 8 patients with erosive rheumatoid arthritis (RA) was used as a comparison. MMP tissue expression was quantified by 2 blinded independent observers. Immunohistochemical data are reported as the mean percentage positive cells per total nucleated cells in 10 high power fields  $\pm$  SD. Functional activity of the gelatinases was measured using a sensitive tissue based zymography technique and corrected for protein content. Zymography data are presented as ng/mg  $\pm$  SE.

**Results.** MMP expression was greater in the synovial lining layer (LL) than in the synovial sublining layer (SL) in both PsA and RA tissue for most MMP except collagenase 1 (MMP1), which was equally distributed between the LL and SL. Expression of MMP or their regulators did not differ between PsA synovial membrane (SM) and RA SM in LL. Moreover, although latent gelatinase A (MMP2) staining in PsA SM was equivalent to RA SM, increased gelatinase A activity was found in PsA SM over RA SM using zymography [82.4 (SD 62.8) vs 10.1 (SD 1.7);  $p = 0.02$ ]. Compared to PsA SM, lesional skin had lower levels of MT1-MMP (MMP14) ( $1.4 \pm 1.7$  vs  $15.7 \pm 8.4$ ;  $p = 0.009$ ) and MT2-MMP (MMP15) ( $12.1 \pm 8.7$  vs  $21.6 \pm 9.9$ ;  $p = 0.001$ ).

**Conclusion.** We characterized the expression and activity of gelatinases in PsA and demonstrate that gelatinase activity in SM of PsA patients with erosive disease is comparable to if not greater than that in RA synovium. (J Rheumatol 2002;29:107–17)

## Key Indexing Terms:

ARTHRITIS	PSORIATIC	METALLOENDOPEPTIDASES
GELATINASES	TISSUE INHIBITOR OF METALLOPROTEINASE	SKIN

Psoriatic arthritis (PsA) is an inflammatory arthropathy occurring in 5–8% of patients with psoriasis that combines features of the spondyloarthropathies and rheumatoid arthritis (RA)<sup>1</sup>. Involvement of both skin and synovium provide the unique opportunity to study the inflammatory response at 2 distinct sites that are easily accessible for clinical and pathological evaluation. Population studies estimate the prevalence of PsA to be 0.02–0.1%<sup>2</sup> and although less

prevalent than RA, PsA is gradually becoming recognized for its potential to cause significant joint destruction with resultant functional disability. Understanding the pathogenesis of this disease is thus important for the development of future therapeutic targets.

There is increasing evidence that joint destruction in erosive inflammatory arthropathies such as RA and PsA involves the invasion and erosion of cartilage and bone by synovial cells<sup>3</sup> and is mediated, in part, by matrix metalloproteinases (MMP)<sup>4,6</sup>. MMP are known to play diverse roles in several features of synovitis including angiogenesis<sup>7</sup> and cytokine modulation<sup>8,9</sup>, and through their collective ability to degrade several types of collagen can damage both cartilage and bone<sup>3</sup>. The gelatinases, gelatinase A (MMP2) and gelatinase B (MMP9), are produced by cells found in synovial tissue<sup>10,11</sup> as well as by keratinocytes in the skin<sup>12,13</sup> and can degrade type IV collagen or gelatin. Both gelatinases are present in the synovium of patients with erosive RA<sup>14,15</sup> and gelatinase A (MMP2) has been shown to be

---

*From the Arthritis and Rheumatism Branch, National Institute of Arthritis, Musculoskeletal and Skin Diseases (NIAMS), National Institutes of Health, Bethesda, Maryland, USA.*

*C.A. Hitchon, MD, FRCPC, University of Manitoba, Winnipeg Manitoba, Canada; C.L. Danning, MD, FACP, Gunderson Lutheran, Gunderson Clinic, Lacrosse, Wisconsin, USA; G.G. Illei, MD, FACP, NIAMS; H.S. El-Gabalawy, MD, FRCPC, NIAMS, and University of Manitoba; D.T. Boumpas, MD, FACP, NIAMS, and University of Crete, Medical School, Heraklion, Greece.*

*Address reprint requests to Dr. C.A. Hitchon, University of Manitoba, RR 149, 800 Sherbrook St., Winnipeg, Manitoba R3A 1M4, Canada.*

*Submitted February 6, 2001; revision accepted July 23, 2001.*

present at the cartilage-pannus junction<sup>16</sup>. The ability of synthetic MMP inhibitors to block cytokine stimulated bone and cartilage resorption *in vitro*<sup>17,18</sup> and synthetic MMP inhibitors of gelatinase and collagenase to inhibit clinical joint swelling and bone erosion *in vivo*<sup>19</sup> implicate the MMP in bone erosion. Together, these studies indicate a role for MMP, in particular the gelatinases, in erosive synovial disease.

In addition to cellular infiltration and proliferation, the synovial membrane of patients with inflammatory synovitis is characterized by the proliferation of new blood vessels. This angiogenesis plays an important role in both acute and chronic responses within the synovial membrane, with recent data suggesting that the perpetuation of synovitis is, at least in part, dependent on angiogenesis<sup>20</sup>. MMP are emerging as key mediators of angiogenesis<sup>7</sup> and their importance is indicated by the ability of endogenous and synthetic MMP inhibitors to inhibit angiogenesis in both *in vitro* and *in vivo* models<sup>21-23</sup>. Gelatinase A (MMP2), possibly through its ability to bind the vitronectin receptor  $\alpha v\beta_3$  expressed on the surface of endothelial cells undergoing angiogenesis<sup>24-26</sup>, appears to be of particular importance to angiogenesis and synovitis.

MMP activity is normally tightly controlled to allow proteinase activity without complete disruption of the extracellular matrix, and this regulation occurs at several levels. MMP production is stimulated by inflammatory cytokines mediated, in part, through AP-1 or NF- $\kappa$ B nuclear transcription factors<sup>27,28</sup>. Further regulation occurs post-transcriptionally and is best understood for gelatinase A. In the current model for gelatinase A function, gelatinase A is secreted as a 72 kDa inactive soluble proenzyme. The proenzyme is localized to the surface of cells and is activated through the formation of a trimolecular complex containing tissue inhibitor of metalloproteinase 2 (TIMP-2), gelatinase A, and membrane type 1 MMP (MT1-MMP) (MMP14)<sup>7,29-33</sup>. This results in production of the enzymatically active 62 kDa form of gelatinase A. Gelatinase B (MMP9) is also secreted as a proenzyme, which can be activated by other MMP such as stromelysin (MMP3)<sup>34</sup> or by the plasmin system and is inhibited when bound to TIMP-1. Membrane type 2 MMP (MT2-MMP) may also be involved in gelatinase regulation<sup>35</sup>. Although the expression and potential role of gelatinases has been explored in RA<sup>14</sup>, their role in psoriatic tissue is still unclear. We investigated the expression of the gelatinases and their regulators in the synovium and skin of patients with erosive PsA and compared this to RA synovium.

## MATERIALS AND METHODS

**Patient population.** Patients participating in studies of pathogenesis and treatment of PsA and RA were seen sequentially in the Rheumatology Day Hospital at the National Institutes of Health. PsA patients had a history of inflammatory peripheral arthritis (with or without spinal involvement) and characteristic psoriatic disease of at least 6 months' duration. All PsA

patients were rheumatoid factor (RF) negative. Patients with RA met 1987 American College of Rheumatology criteria for RA<sup>36</sup> and were RF positive. At the time of biopsy, disease modifying antirheumatic drugs (DMARD), other than low dose prednisone, were held for at least one month; prednisone (< 10 mg/day) was held for 24 h prior to biopsy. Patients had active disease defined as at least 3 swollen or tender peripheral joints and > 45 min of morning stiffness with or without an elevated erythrocyte sedimentation rate (ESR) (> 28 mm/h), or C-reactive protein (CRP) (> 0.8 mg/dl). A detailed clinical history, physical examination, and basic laboratory studies including RF, ESR, CRP, and radiographic evaluation were obtained in all patients. Medication history for DMARD and prednisone use was obtained. Health Assessment Questionnaire (HAQ) and Psoriasis Activity and Severity Index (PASI)<sup>37</sup> scores were recorded. All participants provided complete informed consent.

**Tissue samples.** A blinded closed needle biopsy of the most inflamed accessible joint was performed under local anesthesia. Representative samples were obtained by angling the biopsy needle in different directions within the joint and taking multiple samples. At least 3 synovial fragments per patient were snap frozen in OCT freezing medium (Sakura Finetec, Torrance, CA, USA). Alternatively, samples were obtained at the time of surgical synovectomy. Three millimeter punch biopsies of lesional and uninvolved perilesional skin were obtained from all psoriatic patients and processed as above. Perilesional skin was considered normal-appearing skin within 1–2 cm of a psoriatic plaque.

**Immunohistochemistry.** Eight micrometer frozen sections were fixed on gelatin coated slides in acetone (4°C), air dried, then rehydrated in 1× Tris buffered saline (TBS). Sections were pretreated with 0.03% peroxidase blocking reagent (Dako, Carpinteria, CA, USA). All sections were blocked with 25% pooled human serum and 25% normal goat serum for 30 min at room temperature, then 100  $\mu$ l of diluted primary antibodies were applied and the slides incubated overnight in a humidified slide chamber at 4°C. Monoclonal antibodies to the following were used: CD3, CD68, von Willebrand factor (vWf) (all Dako), MMP1, MMP2, MMP3, MMP9, MMP14, MMP15 (all R&D Systems, Minneapolis, MN, USA), TIMP-1, and TIMP-2 (CalBiochem, La Jolla, CA, USA). Antibody binding was detected using biotinylated secondary immunoglobulin and streptavidin-horseradish peroxidase or streptavidin-alkaline phosphatase (Dako). Tissues were counterstained with Harris hematoxylin and mounted with glycergel. Control procedures included isotype matched murine monoclonal antibodies of irrelevant specificity or exclusion of the primary antibody.

**Immunohistochemistry quantification.** Quantification of immunohistochemical staining was performed under light microscopy using an Olympus BX60 optic system. All specimens analyzed for MMP expression using immunohistochemistry had visible synovial lining layer. Synovial staining was assessed separately in lining and sublining layers; in the skin, both epidermal and dermal layers were analyzed. A minimum of 10 high power fields (hpf; 400× magnification) of each sample (representing up to 3 biopsies) were analyzed. Tissue protein expression for each Mab used was scored as percentage of positive cells/total nuclei and averaged to obtain an estimate of overall tissue staining. Vascularity was determined by calculating the number of vWf positive blood vessels per hpf (400× magnification). The analysis was performed by 2 blinded independent observers (CH, CD). Significant interobserver discrepancies were addressed by reevaluation and achievement of consensus. MMP expression was recorded as the percentage positive cells per total nuclei per hpf  $\pm$  SD.

**Zymography.** Zymography was performed by a described method<sup>38</sup>. Frozen 8  $\mu$ m tissue sections were solubilized with Tris-glycine sodium dodecyl sulfate (SDS) buffer (Biofluids Inc., Rockville, MD, USA). Samples (30  $\mu$ l) were electrophoresed on polyacrylamide gels containing 10% gelatin (Novex, San Diego, CA, USA). HT-1080 media was used as a positive control for gelatinase activity. Gels were incubated in 0.25% Triton-X buffer (Sigma) for 3 h to renature extracted proteins, then incubated for 18 h at 37°C in low salt collagenase buffer to allow enzymatic degradation of

gelatin. Gels were stained for protein with Coomassie blue, destained for 60 min, and mounted. Completed gels were scanned into Adobe Photoshop® (Adobe Systems Inc., San Jose, CA, USA) and enzymatic degradation analyzed with Scion Image (Scion Corp., Frederick, MD, USA). Enzymatic activity was corrected for protein content using the commercial Bio-Rad protein assay kit (Bio-Rad Laboratories, San Diego, CA, USA). Zymography results are recorded as ng/mg ± standard error.

**Statistics.** Results are reported as group means ± standard error or group means ± standard deviation. Statistics were applied using Statview® (SAS Institute Inc., Cary, NC, USA). Statistical significance was determined using unpaired Student's *t* tests, variables with nonparametric distributions were analyzed by Mann-Whitney U or Wilcoxon signed ranks nonparametric tests, and correlations were analyzed by linear regression. *P* values were not corrected for multiple comparisons because this was a hypothesis generating, descriptive study and the target MMP were identified a priori. Statistical significance was considered at the *p* < 0.05 level.

## RESULTS

**Patient characteristics.** Synovial, lesional, and perilesional skin tissue samples were obtained from 15 psoriatic patients and synovial tissue from 8 RA patients. Patient characteristics are summarized in Table 1. Fourteen PsA patients had polyarticular disease and one patient had oligoarticular disease. Seven PsA patients had axial involvement. Three PsA patients had enthesitis and 7 had dactylitis. Disease duration, tender and swollen joint counts, and joint scores were equivalent between PsA and RA groups. Compared to RA patients, PsA patients had lower values for both ESR (38 vs 65.6) and CRP (1.1 vs 5.2) and had less functional disability as measured by their HAQ scores (0.92 vs 1.4). Fourteen PsA and all RA patients had erosive disease deter-

Table 1. Patient characteristics at study enrollment. Except where indicated, values are the mean ± SD.

	PsA, n = 15	RA, n = 8
Age, years	41 (12.2)	51 (11.2)
M:F	2:1	7:1
Disease duration, yrs	12.8 (13.8)	11.8 (6.0)
Tender joint		
Count	26.5 (12.8)	24 (8.5)
Score	48 (23.7)	39.6 (18.2)
Swollen joint		
Count	18.4 (9.8)	22.8 (5.7)
Score	27.1 (17.6)	30.0 (6.9)
Erosions present, %	93	100
New bone formation, %	46	NA
Enthesitis/dactylitis, %	64	NA
Spinal involvement, %	73	NA
PASI score	7.78 (6.01)	NA
HAQ score	0.92 (0.40)	1.4 (0.5)
ESR, mm/h	38 (24.7)	65.6 (19.0)*
CRP, mg/dl	1.1 (1.1)	5.2 (3.2)**
Corticosteroid use,% (< 10 mg prednisone/day)	20%	75%

PsA: psoriatic arthritis; RA: rheumatoid arthritis; NA: not applicable; PASI: Psoriasis Area and Severity Index<sup>35</sup>; HAQ: Health Assessment Questionnaire; ESR: erythrocyte sedimentation rate; CRP: C-reactive protein.

\* *p* < 0.04 vs PsA group; \*\* *p* < 0.001 vs PsA group.

mined by standard radiographs of hands and feet. One PsA patient had arthritis mutilans and 7 PsA patients had evidence of new bone formation. Only 3 PsA patients and 6 RA patients were taking prednisone (< 10 mg/day). Fifty-six percent of PsA patients had been previously treated with methothrexate or sulfasalazine compared with 20% of RA patients. No psoriatic or RA patient received DMARD therapy (other than prednisone) or intraarticular corticosteroids within at least one month of biopsy.

**Tissue histology.** Synovial tissue samples were scored for synovial lining layer (LL) hyperplasia, sublining layer (SL) cellular infiltration, cell markers for lymphocytes (CD3), macrophages (CD68), and vascularity (Table 2). The inflammatory scores and vascularity of the PsA and RA synovial samples were comparable. Psoriatic patients had significantly less (*p* < 0.014) lymphocytic infiltrate in the sublining layers than patients with RA and tended to have less LL hyperplasia and macrophage infiltration, although this was not significant. Lesional skin had greater epidermal hyperplasia, dermal vascularity, and inflammatory scores, but comparable macrophage infiltration to that seen in perilesional skin (data not shown).

**MMP expression in synovial tissue.** MMP expression in PsA and RA synovial tissue was studied by immunohistochemistry using Mab to the gelatinases (MMP2, MMP9), their activators (MT1-MMP/MMP14, MT2-MMP/MMP15), and their inhibitors (TIMP-1, TIMP-2). In addition, collagenase-1 (MMP1) and stromelysin (MMP3) expression were studied. The expression in PsA synovium was compared to the expression seen in RA synovium. Figure 1 shows representative staining patterns of gelatinase A, gelatinase B, MT1-MMP, and TIMP-1 in PsA synovium.

Immunohistochemical staining using a Mab to latent gelatinase A (MMP2) revealed a high percentage of gelatinase A (MMP2) positive cells; these cells were commonly present in perivascular aggregates. Gelatinase A positive cells were more prevalent in the LL compared to the SL in both psoriatic (45.7 ± 15.7 vs 25.2 ± 13.5; *p* = 0.001) and RA synovium (51.5 ± 15.3 vs 31.7 ± 16.1; *p* = 0.02). No significant differences were seen in the gelatinase A expression between PsA and RA (Table 3).

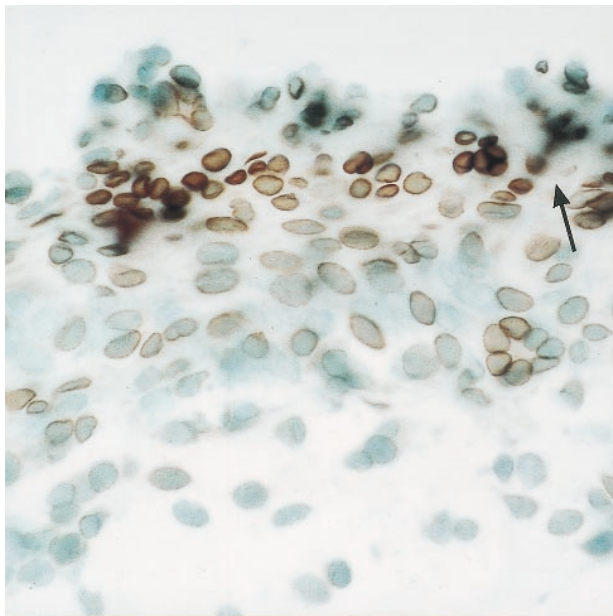
Gelatinase B (MMP9) has been described in RA synovial tissue<sup>14,15</sup> and is also present in PsA synovial tissue (Figure 1B). Intensely stained gelatinase B (MMP9) positive cells were scattered throughout the synovial sublining. There was significantly less gelatinase B than A in both lining and sublining. Similarly to gelatinase A, the expression of gelatinase B was greater in the LL than the SL in both PsA (17.9 ± 14 vs 10.7 ± 10.4; *p* = 0.04) and RA (17.1 ± 12.9 vs 7.6 ± 5.1; *p* = 0.04). No significant differences in the percentage of gelatinase B positive cells were present between PsA and RA (Table 3).

Membrane bound MMP (MT1-MMP and probably MT2-MMP) in conjunction with the tissue inhibitor (TIMP-2) are

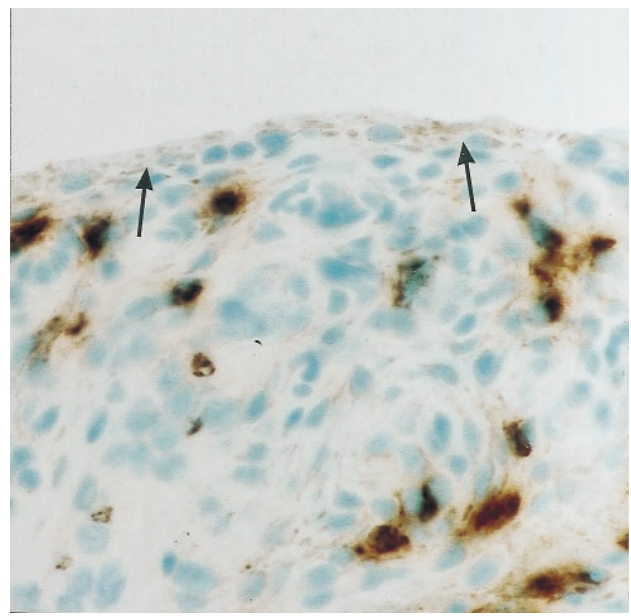
Table 2. Tissue morphology and cell phenotype in psoriatic arthritis (PsA) versus rheumatoid arthritis (RA) synovium and in psoriatic arthritis lesional versus perilesional skin.

	PsA	RA	Psoriatic Plaque	Perilesional Normal Appearing Skin
Synovium				
Lining layer thickness, No. of cells thick, median (SD)	2.3 (0.5)	3.0 (1.1)		
Cellularity score, total nuclei/ hpf, median (SD)	2.5 (0.8)	2.7 (0.5)		
Vascularity score, No. of vWf positive blood vessels/ hpf, median (SD)	6.4 (2.8)	6.2 (6.9)		
T lymphocytes, % positive CD3+ cells/hpf, mean (SD)				
Lining layer	3.6 (3.9)	6.2 (4.5)		
Sublining layer	14.2 (8.9)	22.2 (8.2)**		
Macrophages				
Lining layer <sup>†</sup>	49.5 (19.1)	76.8 (13.7)		
Sublining layer <sup>††</sup>	2.73 (5.1)	3.0 (0.6)		
TNF $\alpha$				
Lining layer	9.2 (12.6)	21.6 (15)*		
IL-1B				
Lining layer	10.6 (7.7)	27.9 (16.4)*		
PsA skin				
Epidermal thickness, $\mu\text{m}^2/\text{hpf}$ , median (SD)			6739 (2454)	3090 (907)
Cellularity score (as above)			2.7 (0.3)	1.6 (0.4)***
Vascularity score (as above)			5.1 (1.0)	4.3 (1.2)

<sup>†</sup> Percentage of CD68+ cells/hpf (mean  $\pm$  SD); <sup>††</sup> score on a 0–4 scale (mean  $\pm$  SD): 1 =  $\leq$  10% cells positive, 2 = 11–25% cells positive, 3 = 26–50% cells positive, 4 =  $>$  50% cells positive. \*\*  $p < 0.014$  vs PsA, \*\*\*  $p < 0.0001$  vs lesional skin, \*  $p < 0.05$  vs PsA. vWf: von Willebrand factor.

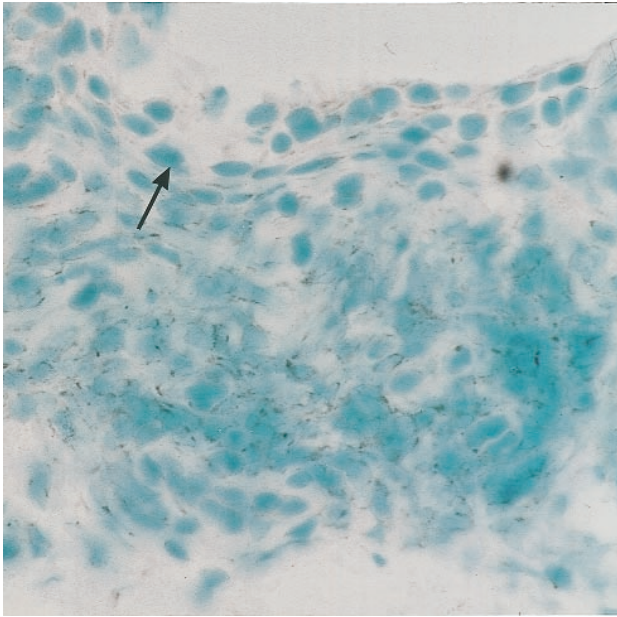


A

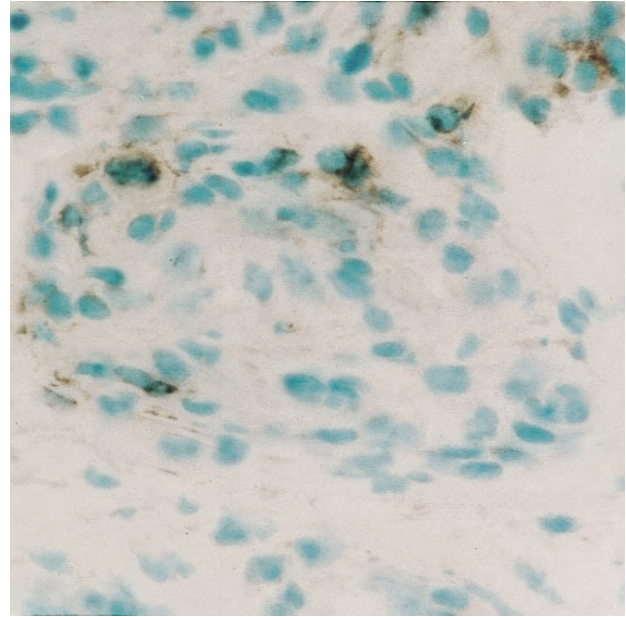


B

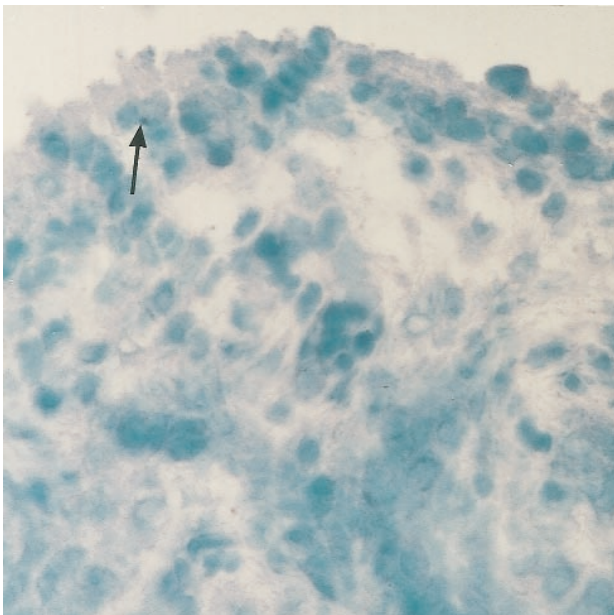
Figure 1. MMP expression in PsA synovial membrane (SM). PsA synovial membrane sections were stained with Mab directed against (A) gelatinase A (MMP2), (B) gelatinase B (MMP9), (C) MT1-MMP (MMP14), (D) TIMP-1, and (E) a nonspecific IgG negative control. Positive cells were detected using diaminobenzidine substrate (brown). Arrow shows synovial lining layer (original magnification  $\times 600$ ).



C



D



E

thought to activate latent gelatinase A at the cell surface and to regulate gelatinase activity. The regulatory mechanisms for gelatinase B are not fully defined, but may be similar to gelatinase A and are thought to involve TIMP-1. To further characterize the expression and activity of the gelatinases, we used immunohistochemistry to examine the expression of activators, MT1-MMP (MMP14) and MT2-MMP (MMP15) and inhibitors, TIMP-2 and TIMP-1, of gelatinase function. MT1-MMP, MT2-MMP, TIMP-1, and TIMP-2 positive cells were seen throughout the sublining, but tended

to concentrate in perivascular aggregates in a pattern similar to that seen for gelatinase A. Thus, the regulatory elements of gelatinase activity were generally located in the same synovial region as the gelatinase enzyme.

LL expression was higher than SL expression for MT1-MMP ( $26.0 \pm 14.8$  vs  $15.7 \pm 8.4$ ;  $p = 0.06$ ) and MT2-MMP ( $36.8 \pm 13.2$  vs  $21.6 \pm 9.9$ ;  $p = 0.06$ ) in PsA synovium. There was significantly more MT1-MMP expression in the SL of PsA compared to RA tissue ( $15.7 \pm 8.4$  vs  $6.8 \pm 8.7$ ;  $p = 0.05$ ) (Table 3).

TIMP-2 is involved in the regulation of gelatinase A and was more commonly expressed than TIMP-1, a regulator of gelatinase B, paralleling the gelatinase protein expression patterns. Similar to other MMP studied, the expression of TIMP was greatest in the LL compared to the SL for both TIMP-1 ( $34.4 \pm 9.8$  vs  $13.4 \pm 7.9$ ;  $p = 0.03$ ) and TIMP-2 ( $45.0 \pm 15.8$  vs  $30.0 \pm 10.7$ ;  $p = 0.01$ ) in PsA. TIMP-2 expression in the LL had a negative correlation with LL thickness ( $R^2 = 0.73$ ,  $p = 0.002$ ) and a positive correlation with disease duration ( $R^2 = 0.43$ ,  $p = 0.04$ ). An imbalance in the ratio of MMP to TIMP has been hypothesized as a potential source for the disrupted regulation of MMP activity seen in RA, and the ratio of serum TIMP-1 and stromelysin in RA has been shown to be greater than in osteoarthritis<sup>39</sup>. We were unable to find differences in the TIMP-1/MMP3, TIMP-1/MMP9, or TIMP-2/MMP2 ratios at the tissue level between PsA and RA samples, nor did ratios correlate with histologic inflammatory scores or with vascularity.

A positive correlation was seen between gelatinase B expression in LL and ESR ( $R^2 = 0.848$ ,  $p = 0.0002$ ) and CRP ( $R^2 = 0.776$ ,  $p = 0.002$ ) as well as between gelatinase B in the SL and ESR ( $R^2 = 0.769$ ,  $p = 0.0004$ ) and CRP ( $R^2 =$

Table 3. Matrix metalloproteinase expression in the lining layer (LL) and sublining layer (SL) of PsA and RA synovial tissue using immunohistochemistry<sup>†</sup> and tissue based zymography<sup>††</sup>.

	PsA		RA	
	LL	SL	LL	SL
Gelatinase A	45.7 (15.7)	25.2 (13.5) <sup>#</sup>	51.5 (15.3)	31.7 (16.1) <sup>##</sup>
Gelatinase B	17.9 (14)	10.7 (10) <sup>##</sup>	17.1 (13)	7.6 (5) <sup>##</sup>
TIMP-2	45.0 (15.8)	30.0 (10.7) <sup>##</sup>	36.8 (11)	25.6 (3.1) <sup>##</sup>
MT1-MMP	26.0 (14.8)	15.7 (8.4) <sup>&amp;</sup>	19.0 (8.9)	6.8 (8.7) <sup>##@</sup>
TIMP-1	34.4 (9.8)	13.4 (7.9) <sup>##</sup>	35.1 (16.9)	9.6 (8.9) <sup>##</sup>
MT2-MMP	36.8 (13.2)	21.6 (9.9) <sup>&amp;</sup>	31.7 (12)	17.2 (11.8) <sup>##</sup>
Collagenase-1	47.0 (14.1)	40.8 (19)	58.5 (23.2)	32.6 (14.9) <sup>#</sup>
Stromelysin	22.0 (6.6)	6.3 (5.7) <sup>##</sup>	32.0 (13.5)	9.9 (8.4) <sup>##</sup>
Active gelatinase A <sup>††</sup>	82.4 (62.6)		10.1 (4.7) <sup>*</sup>	
Active gelatinase B <sup>††</sup>	160.6 (91.6)		10.5 (2.4)	

<sup>†</sup> Immunohistochemistry recorded as percentage positive cells hpf ± SD.

<sup>††</sup> zymography recorded as ng/mg ± SE.

<sup>#</sup> lining layer vs sublining layer, p = 0.01; <sup>##</sup> lining layer vs sublining, p < 0.05; <sup>&</sup> lining layer vs sublining, p < 0.07; <sup>@</sup> p = 0.05, RA SL vs PsA SL; <sup>\*</sup> RA vs PsA, p < 0.02.

0.787, p = 0.001) in PsA. Gelatinase B in the sublining also positively correlated with disease duration (R<sup>2</sup> = 0.45, p = 0.02). MT1-MMP in the LL correlated negatively with ESR (R<sup>2</sup> = 0.937, p = 0.03) in PsA. No correlations were seen between MMP expression and joint counts or scores, new bone formation, HAQ, or PASI scores.

*Synovial gelatinase activity.* MMP are secreted as proenzymes that are activated extracellularly, thus expression does not necessarily equate with enzyme activity. To examine the activity of the gelatinases in PsA and RA synovial tissue we used a sensitive tissue based zymographic technique. Active gelatinase A (62 kDa) and latent gelatinase A (72 kDa) were separated by molecular weight on polyacrylamide gels containing gelatin using electrophoresis, and gelatinase activity was quantified by determining the extent of gelatin degradation. The gelatinase activity in a single 8 μm frozen tissue section was determined, whereas the control consisted of supernatant from cultured HT-1080 fibrosarcoma cells, which had a higher concentration of gelatinase enzyme and thus a more prominent band on the zymography gel. All reported gelatinase activities are corrected for protein content. Synovial tissue from 7 PsA tissues (2 exposed to prednisone) and 7 RA tissues (6 exposed to prednisone) were studied by zymography. Active gelatinase A was present in both PsA and RA synovial tissue (Figure 2). In this study, the activity of gelatinase A in PsA synovial tissue was greater than that seen in RA synovial tissue — 82.4 (62.8) vs 10.5 (4.7) ng/mg (p = 0.02) (Table 3). Gelatinase A activity correlated with the numbers of T lymphocytes in the sublining of PsA synovium (R<sup>2</sup> = 0.876, p = 0.002).

Zymography was also used to determine the activity of gelatinase B (92 kDa) in PsA synovial tissue. PsA synovium had amounts of gelatinase B in the active and inactive forms that were comparable to RA synovium — 161 (92) vs 10

(2.4) ng/mg (p = 0.06) (Table 3). Gelatinase B activity correlated with histologic gelatinase B expression in PsA sublining (R<sup>2</sup> = 0.974, p = 0.01). Gelatinase activity did not correlate with clinical markers of disease activity.

The composition of the higher molecular weight bands identified by zymography is not clear; however, they may represent dimerized enzyme.

*MMP expression and gelatinase activity in psoriatic skin.* The pattern of MMP expression in psoriatic lesional skin is shown in Figure 3. All MMP studied including gelatinase A (Figure 3A) and TIMP-2 (Figure 3B) were present in psoriatic skin. TIMP-2 appeared to stain the epidermal-dermal junction. The MMP expression in skin was similar to that seen in the synovial tissue, with collagenase-1 (MMP1) and gelatinase A (MMP2) being the most abundant MMP and TIMP-2 the commonest inhibitor (Table 4). However,

Table 4. Matrix metalloproteinase expression in lesional and perilesional skin of patients with psoriatic arthritis using immunohistochemistry<sup>†</sup> and tissue based zymography<sup>††</sup>.

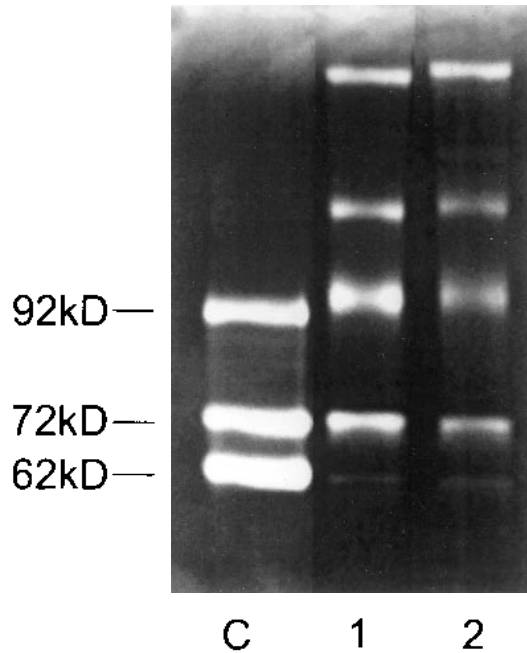
	Psoriatic Plaque	Perilesional Normal Appearing Skin
Gelatinase A	38.6 (10.3)	34.4 (16.3)
Gelatinase B	6.9 (5.1) <sup>*</sup>	3.3 (3.1)
MT1- MMP	1.4 (1.7)	2.5 (1.8)
MT2-MMP	12.1 (8.7) <sup>**</sup>	6.6 (6.9)
TIMP2	26.3 (10)	25.5 (10.5)
TIMP1	10.8 (7.6)	9.9 (7.2)
Collagenase-1	32.1 (15.6)	40.8 (11.9)
Stromelysin	2.2 (2.6)	2.8 (2.8)
Active gelatinase A <sup>††</sup>	17.8 (7.1)	11.2 (1.7)
Active gelatinase B <sup>††</sup>	75.0 (33.8)	45.8 (31.7)

<sup>†</sup> Immunohistochemistry as percentage positive cells/hpf ± SD.

<sup>††</sup> Zymography recorded as ng/mg ± SE.

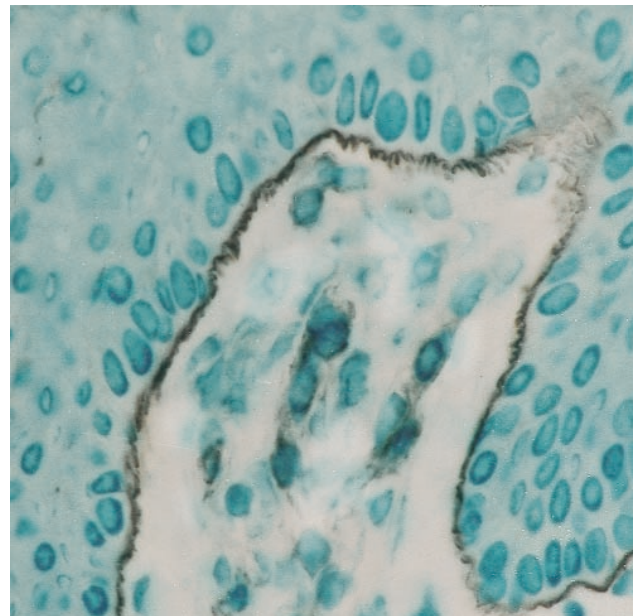
<sup>\*</sup> p = 0.02, psoriatic plaque vs perilesional skin;

<sup>\*\*</sup> p = 0.06, psoriatic plaque vs perilesional skin.

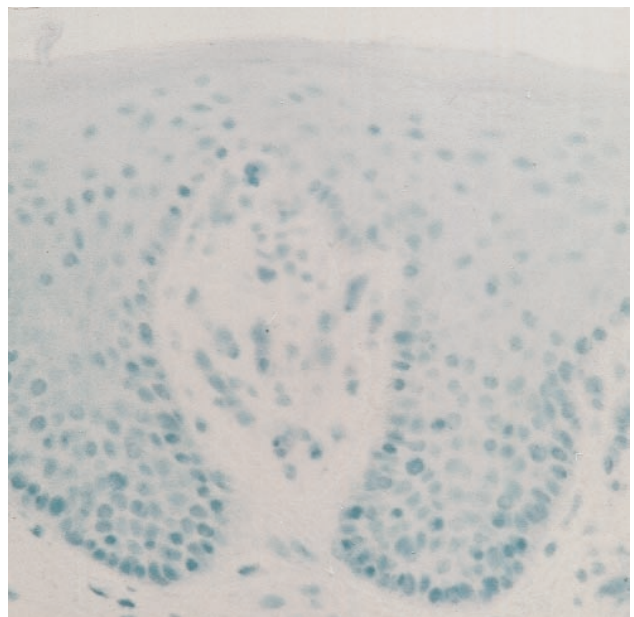


**Figure 2.** MMP activity in RA (lane 1) versus PsA (lane 2). Active gelatinases (MMP2 and MMP9) were detected in PsA and RA synovium by solubilizing synovial biopsy tissue sections and separating on SDS-PAGE containing 0.1% gelatin. HT-1080 fibrosarcoma cell line media was used as a control (lane C). The 92 kDa band represents total MMP9, the 72 kDa band latent MMP2, and the 62 kDa band active MMP2. Gelatinase A (MMP2) activity was quantified by analyzing band density using Image software and corrected for protein content.

lesional skin tissue had significantly less stromelysin (MMP3) ( $2.1 \pm 2.6$  vs  $6.3 \pm 5.7$ ;  $p = 0.004$ ), MT1-MMP (MMP14) ( $1.4 \pm 1.7$  vs  $15.7 \pm 8.4$ ;  $p = 0.009$ ), MT2-MMP (MMP15) ( $12.1 \pm 8.7$  vs  $21.6 \pm 9.9$ ;  $p = 0.001$ ), and gelatinase A ( $38.6 \pm 10.3$  vs  $45.7 \pm 15.7$ ;  $p = 0.02$ ) expression compared to synovial lining layer. Lesional skin had more

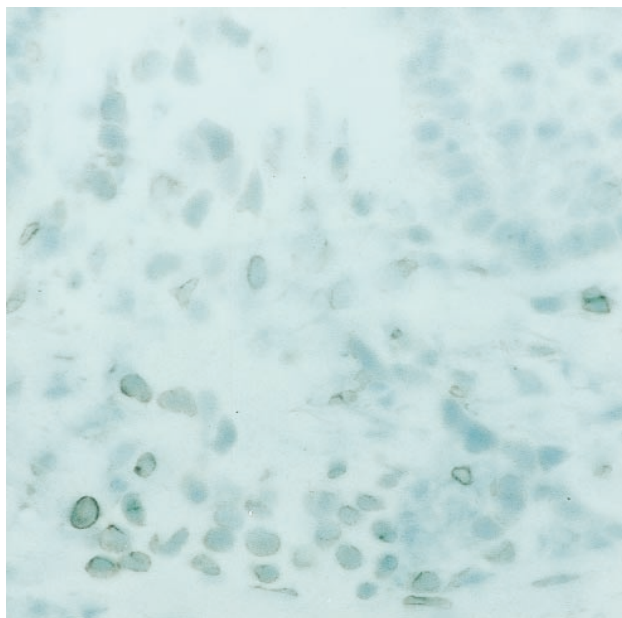


**B**



**C**

**Figure 3.** MMP expression in PsA lesional skin. PsA lesional skin sections were stained with Mab directed against (A) gelatinase A (MMP2), (B) TIMP-2, (C) nonspecific IgG control. Positive cells were detected using diaminobenzidine substrate (brown). (A, B, original magnification  $\times 400$ ; C, original magnification  $\times 200$ ).



**A**

gelatinase B (MMP9) ( $6.9 \pm 5.1$  vs  $3.3 \pm 3.1$ ;  $p = 0.02$ ) and MT2-MMP (MMP15) ( $12.1 \pm 8.7$  vs  $6.6 \pm 6.8$ ;  $p = 0.06$ ) expression than perilesional skin. The expression of MT2-MMP (MMP15) in lesional skin correlated positively with vascularity ( $R^2 = 0.632$ ,  $p = 0.01$ ). No correlations were seen between gelatinase A or MT1-MMP and vascularity. Gelatinase activity was studied in 14 psoriatic lesional and perilesional skin samples using zymography. Although active MMP2 was detected in both lesional and perilesional skin, there was no difference in the amount of activity.

## DISCUSSION

This study is the first to characterize the expression and activity of the gelatinases in psoriatic arthritis. We have shown that the gelatinases (MMP2, MMP9) and their regulators (MT-MMP and TIMP) as well as collagenase-1 (MMP1) and stromelysin (MMP3) are present in both psoriatic synovium and skin. In this study, the synovial expression of MMP in PsA was compared to that of a clinically matched cohort of patients with established RA. The expression of the gelatinases was comparable in both types of inflammatory arthritis. Gelatinase activity determined by a sensitive tissue based technique revealed the presence of active gelatinase A and B in synovium. Gelatinase A activity was greater in PsA than RA synovium; however, more RA patients were taking prednisone and prednisone decreases the expression of MMP<sup>40,41</sup>. Additional examination of the skin from patients with PsA revealed that the gelatinases were present and active in both lesional and perilesional skin. MMP expression in both lesional and perilesional skin was comparable to that seen in synovium, with the exception of stromelysin (MMP3), gelatinase A, and the membrane type MMP, MT1-MMP and MT2-MMP, which had greater synovial expression.

The functional disability associated with inflammatory arthropathies such as PsA and RA is largely the result of bone damage, either erosions or ankylosis. The role of metalloproteinases in early bone erosion is shown by the ability of MMP inhibitors to prevent the development of erosions in adjuvant arthritis<sup>19</sup>, and the ability of selective inhibition of gelatinase A and B to reduce interleukin 1 (IL-1) stimulated bone resorption<sup>17</sup>. In addition, inhibitors of collagenase (MMP13) prevent the formation of early erosive pits *in vitro*<sup>42</sup>, and bone resorption is reduced in mice with mutations of collagen at the site of collagenase cleavage<sup>43</sup>. Studies of RA have recently described the presence of active gelatinase A in tissues from patients with early erosions, indicating a potential role for the gelatinases in the initiation or early development of erosive synovitis<sup>14</sup>. Our results indicate that the gelatinases are also present and active in erosive PsA and that the immunolocalization of other MMP is similar in psoriatic and rheumatoid synovium. This suggests a common pathway to erosion formation may be present.

MMP may contribute to the formation of bone erosions through their ability to regulate the differentiation or activity of mediators of bone turnover, regulation of cytokines, or through facilitating angiogenesis. The key mediators of bone resorption and formation are the macrophage derived osteoclast and the mesenchymal derived osteoblast<sup>44</sup>. Clinical evidence has shown that early inflammatory lesions of bone are characterized by large amounts of active osteoclasts<sup>45</sup>. Macrophages are stimulated to differentiate into osteoclasts through the interaction of the nuclear factor  $\kappa$ B (NF- $\kappa$ B) receptor (RANK) produced by osteoblasts and its ligand (RANKL) on the surface of undifferentiated macrophages. This interaction can be inhibited by osteoprotegerin (OPG), a soluble "decoy receptor" that competes with RANK for RANKL. RANK and RANKL are members of the TNF and TNF receptor superfamilies and RANKL expression is increased by TNF. Both TNF and NF- $\kappa$ B are present in PsA synovial tissue<sup>46</sup>.

Osteoclast activity is dependent upon localization and attachment of the osteoclast to the bone surface. Integrins, in particular  $\alpha$ v $\beta$ 3, appear to be important for this process through their ability to polarize the cytoskeleton and potentially through interactions with other extracellular components<sup>47</sup>. Gelatinase A may act by facilitating osteoclast attachment and detachment at the sites of bone resorption through its ability to bind  $\alpha$ v $\beta$ 3 integrin. After osteoclast attachment and formation of the ruffled membrane, bone is demineralized and the collagen matrix degraded by enzymes such as cathepsin and MMP. Gelatinase A is constitutively expressed by osteoclasts and gelatinase B, stromelysin and collagenase are expressed following IL-1 stimulation. Thus MMP may also play a direct role in bone resorption.

Acute and chronic inflammatory synovitis is closely influenced by inflammatory cytokines, in particular IL-1 $\beta$  and TNF- $\alpha$ , and the activity of these cytokines can be influenced by MMP. Gelatinase A and B as well as stromelysin can process recombinant IL-1 $\beta$  precursors into active IL-1 $\beta$ <sup>8</sup> and degrade active IL-1 $\beta$  into inactive fragments<sup>9</sup>. Thus gelatinases are able to up or downregulate IL-1 $\beta$  activity. In turn, TNF- $\alpha$  and IL-1 $\beta$  induce gelatinase A (MMP2), gelatinase B (MMP9)<sup>48</sup>, and collagenase expression<sup>49</sup>. Although TNF- $\alpha$  and IL-1 $\beta$  particularly dominate the inflammatory response seen in PsA tissue<sup>46,50</sup>, recent studies comparing the cytokine profiles of PsA and RA have shown lower levels of macrophage derived cytokines including IL-1 $\beta$  and TNF- $\alpha$  in PsA synovium compared to RA synovium<sup>46</sup>. In addition, IL-10, which increases TIMP-1 and decreases MMP9 mRNA production and activity<sup>51</sup>, is relatively deficient in PsA synovium. Consistent with these observations, the expression of collagenase-1 (MMP1) and TIMP-1 were positively correlated with tissue TNF- $\alpha$  and IL-10 levels, respectively. As reported<sup>52</sup>, MMP expression was greater in the lining layer than the sublining layer, paralleling the distribution of inflammatory cytokines<sup>46</sup>.



Angiogenesis is an early feature of inflammatory synovitis such as in RA, and pathological studies of PsA synovial tissue indicate angiogenesis is also important in PsA<sup>53-55</sup>. Metalloproteinases clearly play a role in angiogenesis, as indicated by the ability of MMP inhibitors to decrease angiogenesis *in vitro* and *in vivo* and the observation that MMP deficient mice have reduced angiogenic responses<sup>56</sup>. The gelatinases, in particular gelatinase A (MMP2), appear to be particularly important in angiogenesis<sup>7</sup>, and in this study, interstitial gelatinase positive cells were most commonly seen in perivascular aggregates. Although the mechanisms by which metalloproteinases influence angiogenesis are unknown, the ability of gelatinase A to bind the vitronectin receptor  $\alpha v\beta 3$  and the colocalization of gelatinase A and  $\alpha v\beta 3$  to angiogenic vessels suggest a potential link to cell adhesion and cytoskeletal reorganization. Of particular note is the observation that MT1-MMP, which was seen more in PsA than RA synovial sublining, has fibrinolytic activity and that overexpression of MT1-MMP in cell lines results in the cells being able to invade fibrin<sup>57</sup>. Interestingly, MT2-MMP expression was found to correlate with vascularity in PsA skin, suggesting it too may play a role in angiogenesis. MMP degrade collagen and thus conceptually may play a role in removing matrix barriers needed for endothelial cell migration or tubule formation. In addition, they may contribute to signaling pathways promoting angiogenesis or to the production of angiogenesis-regulating factors such as angiostatin.

Studies of MMP in PsA synovium have described the expression of collagenase and stromelysin<sup>58-60</sup>. Collagenase was the most abundantly expressed MMP in both PsA and RA synovium. Stromelysin appears to be upregulated at the cartilage-pannus junction, suggesting it may also play a role in erosive disease. Stromelysin is a potent activator of other MMP including gelatinase B, and serum stromelysin levels correlate with some measures of clinical activity. However, it is not specific for erosive disease<sup>60</sup>.

The unique feature of PsA is the involvement of skin as part of the disease process. Psoriatic skin is characterized by hyperkeratosis, epidermal hyperplasia, an inflammatory infiltrate, and increased blood vessel formation<sup>46,54</sup>. Gelatinases, in particular gelatinase A, are needed for keratinocyte migration<sup>61</sup> and are important for early and chronic wound healing<sup>13</sup>. Further circumstantial evidence to support the role of gelatinases in the pathogenesis of psoriatic skin lesions includes the ability of UV light and retinoic acid, treatments known to be effective on psoriatic lesions, to influence MMP expression in skin<sup>62,63</sup>. Studies of gelatinase expression in psoriatic skin have also shown perivascular gelatinase A (MMP2) and scattered gelatinase B (MMP9) expression<sup>64</sup>, with the expression in lesional skin being greater than perilesional or normal skin<sup>65</sup>. We show that all MMP we studied, including both MMP inhibitors, are expressed in both lesional and perilesional skin and that

the main difference is an increased gelatinase B expression in lesional skin. Interestingly, TIMP-2 antibody stained the dermal-epidermal junction intensely. This area is known to contain type IV collagen and staining patterns for collagen type IV are similar to those seen for TIMP-2<sup>64</sup>.

The critical role of MMP in inflammatory arthritis is emphasized by studies showing MMP inhibitors ameliorate arthritis and bone destruction in animal models. The ability of MMP to influence the expression and activity of inflammatory cytokines, to upregulate and downregulate angiogenesis, and to potentially influence osteoclast activity suggest multiple mechanisms by which they may be acting in inflammatory erosive synovitis. The data presented here suggest that the expression of MMP, in particular the expression and activity of the gelatinases, is comparable in both erosive PsA and RA. Differences between the MMP profiles of the skin and joint indicate subtle but potentially important differences between these 2 tissues. Our data provide further rationale for investigating therapies directed at MMP inhibition in psoriatic arthritis and suggest that MMP inhibitors, especially those directed toward gelatinase A (MMP2), may be of clinical benefit in PsA skin and joint disease.

## REFERENCES

1. Boumpas DT, Tassioulas IO. Psoriatic arthritis. In: Klippel JH, Weyand CM, Wortman RL, editors. *Primer on the rheumatic diseases*. 11th ed. Atlanta: Arthritis Foundation; 1997:175-9.
2. Helliwell PS, Wright V. Psoriatic arthritis: clinical features. In: Klippel JH, Dieppe PA, editors. *Rheumatology*. 2nd ed. London: Mosby; 1998:6.21.1-8.
3. Zaifler NJ, Firestein GS. Pannus and pannocytes. Alternative models of joint destruction in rheumatoid arthritis. *Arthritis Rheum* 1994;37:783-9.
4. Keyser G, Redlich A, Haupl T, et al. Differential expression of cathepsins B and L compared with matrix metalloproteinases and their respective inhibitors in rheumatoid arthritis and osteoarthritis. *Arthritis Rheum* 1998;41:1378-87.
5. Gravalles EM, Darling JA, Ladd AL, Katz JN, Glimcher LH. In situ hybridization studies of stromelysin and collagenase messenger RNA expression in rheumatoid synovium. *Arthritis Rheum* 1991;34:1078-84.
6. McCachren SS. Expression of metalloproteinases and metalloproteinase inhibitor in human arthritis synovium. *Arthritis Rheum* 1991;34:1085-93.
7. Stetler-Stevenson D. Matrix metalloproteinases in angiogenesis: a moving target for therapeutic intervention. *J Clin Invest* 1999;103.
8. Schonbeck U, Mach F, Libby P. Generation of biologically active IL-1 beta by matrix metalloproteinases: a novel caspase-1-independent pathway of IL-1 beta processing. *J Immunol* 1998;161:3340-6.
9. Ito A, Mukaiyama A, Itoh Y, et al. Degradation of interleukin 1 beta by matrix metalloproteinases. *J Biol Chem* 1996;271:14657-60.
10. Ahrens D, Koch AE, Pope RM, Stein-Picerella M, Niedbala MJ. Expression of matrix metalloproteinase 9 (96 kd gelatinase B) in human rheumatoid arthritis. *Arthritis Rheum* 1996;39:1576-87.
11. Unemori EN, Hibbs MS, Amerento EP. Constitutive expression of a 92-kD gelatinase (type V collagenase) by rheumatoid synovial fibroblasts and its induction in normal human fibroblasts by inflammatory cytokines. *J Clin Invest* 1991;88:1656-62.
12. Salo T, Lyon JG, Rahemtulla F, Birkedal-Hansen H, Larjava H.

- Transforming growth factor beta 1 up-regulates type IV collagenase expression in cultured human keratinocytes. *J Biol Chem* 1991;266:11436-41.
13. Turlion JF, Vickeroy CJ, Leaper DJ, Bailey AJ. Post-surgical wound progression monitored by temporal changes in the expression of matrix metalloproteinase-9. *Br J Dermatol* 1997;137:508-16.
  14. Goldbach-Mansky R, Lee JM, Hoxworth JM, et al. Active synovial matrix metalloproteinase-2 is associated with radiographic erosions in patients with early synovitis. *Arthritis Res* 2000;2:145-53.
  15. Grillet B, Dequeker J, Paemen L, Van Damme B, Opendakker G. Gelatinase B in chronic synovitis: Immunolocalization with a monoclonal antibody. *Br J Rheumatol* 1997;36:744-7.
  16. Konttinen YT, Caponis A, Takagi M, et al. New collagenolytic enzymes/cascade identified at the pannus-hard tissue junction in rheumatoid arthritis: destruction from above. *Matrix Biol* 1998;17:585-601.
  17. Ganu V, Goldberg R, Peppard J, et al. Inhibition of interleukin 1 $\alpha$ -induced cartilage oligomeric matrix protein degradation in bovine articular cartilage by matrix metalloproteinase inhibitors. *Arthritis Rheum* 1998;41:2143-51.
  18. Hill PA, Murphy G, Docherty AJP, et al. The effects of selected inhibitors of matrix metalloproteinases (MMPs) on bone resorption and the identification of MMPs and TIMP-1 in isolated osteoclasts. *J Cell Sci* 1994;107:3055-64.
  19. Conway JG, Wakefield JA, Brown RH, et al. Inhibition of cartilage and bone destruction in adjuvant arthritis in the rat by a matrix metalloproteinase inhibitor. *J Exp Med* 1995;182:449-57.
  20. Jackson JR, Seed MP, Kircher CH, Willoughby DA, Winkler JD. The codependence of angiogenesis and chronic inflammation. *FASEB J* 1997;11:457-65.
  21. Arnan-Apte B, Pepper MS, Voest E, et al. Inhibition of angiogenesis by tissue inhibitor of metalloproteinase-3. *Invest Ophthalmol Vis Sci* 1997;38:817-23.
  22. Isaji M, Miyata H, Ajisawa YM, Takehana Y, Yoshimura N. Tranilast inhibits the proliferation, chemotaxis and tube formation of human microvascular endothelial cells in vitro and angiogenesis in vivo. *Br J Pharmacol* 1997;122:1061-6.
  23. Zhou Z, Apte SS, Soininen R, et al. Impaired endothelial ossification and angiogenesis in mice deficient in MT-MMP1. *Proc Natl Acad Sci USA* 2000;97:4052-7.
  24. Brooks PC, Silletti S, von Schalscha TL, Friedlander M, Cheresch DA. Disruption of angiogenesis by PEX, a noncatalytic metalloproteinase fragment with integrin binding activity. *Cell* 1998;92:391-400.
  25. Brooks PC, Stromblad S, Sanders LC, et al. Localization of matrix metalloproteinase MMP2 to the surface of invasive cells by interaction with integrin  $\alpha$ v $\beta$ 3. *Cell* 1996;85:683-93.
  26. Stogard CM, Stupack DG, Jonczyk A, Goodman SL, Fox RI, Cheresch DA. Decreased angiogenesis and arthritic disease in rabbits treated with an  $\alpha$ v $\beta$ 3 antagonist. *J Clin Invest* 1999;103:147-54.
  27. Benkow U, Brinckerhoff CE. The AP-1 site and MMP gene regulation: What is all the fuss about. *Matrix Biology* 1997;15:519-26.
  28. Han Z, Boyle DL, Manning AM, Firestein GS. AP-1 and NF- $\kappa$ B regulation in rheumatoid arthritis and murine collagen-induced arthritis. *Autoimmunity* 1998;28:197-208.
  29. Shofuda K, Moriyama K, Nishihashi A, et al. Role of tissue inhibitor of metalloproteinase-2 (TIMP2) in regulation of progelatinase A activation catalyzed by membrane-type matrix metalloproteinase-1 (MT1-MMP) in human cancer cells. *J Biochem* 1998;124:462-70.
  30. Strongin AY, Collier I, Bannikov G, Marmer BL, Grant GA, Goldberg GI. Mechanism of cell surface activation of 72-kDa type IV collagenase isolation of the activated form of the membrane metalloproteinase. *J Biol Chem* 1995;270:5331-8.
  31. Cao J, Rehemtulla A, Bahou W, Zucker S. Membrane type matrix metalloproteinase 1 activates progelatinase A without furin cleavage of the N-terminal domain. *J Biol Chem* 1996;271:30174-80.
  32. Murphy G, Knauper V. Relating matrix metalloproteinase structure to function: why the "hemopexin" domain. *Matrix Biology* 1997;15:511-8.
  33. Howard EW, Bullen EC, Banda MJ. Preferential inhibition of 72- and 92-kDa gelatinases by tissue inhibitor of metalloproteinase-2. *J Biol Chem* 1991;266:13070-5.
  34. Ogata Y, Enhild JJ, Nagase H. Matrix metalloproteinase 3 (stromelysin) activates the precursor for the human matrix metalloproteinase 9. *J Biol Chem* 1992;267:3581-4.
  35. Butler GS, Will H, Atkinson SJ, Murphy G. Membrane type 2 matrix metalloproteinase can initiate the processing of progelatinase A and is regulated by the tissue inhibitors of matrix metalloproteinases. *Eur J Biochem* 1997;244:653-7.
  36. Arnett FC, Edworthy SM, Bloch DA, et al. The American Rheumatology Association 1987 revised criteria for the classification of rheumatoid arthritis. *Arthritis Rheum* 1988;31:315-24.
  37. Fredriksson T, Pettersson U. Severe psoriasis, oral therapy with a new retinoid. *J Rheumatol* 1982;9:719-22.
  38. Kleiner DE, Stetler-Stevenson WG. Quantitative zymography: detection of picogram quantities of gelatinases. *Anal Biochem* 1994;218:325-9.
  39. Keyszer G, Lambiri I, Nagel R, et al. Circulating levels of matrix metalloproteinases MMP-3, MMP-1, tissue inhibitor of metalloproteinase-1 (TIMP-1), and MMP-1/TIMP-1 complex in rheumatic disease. Correlation with clinical activity of rheumatoid arthritis versus other surrogate markers. *J Rheumatol* 1999;26:251-8.
  40. Sharif M, Slisbury C, Taylor DJ, Kirwin JR. Changes in biochemical markers of joint tissue metabolism in a randomized controlled trial of glucocorticoids in early rheumatoid arthritis. *Arthritis Rheum* 1998;41:1203-9.
  41. Firestein GS, Paine MM, Littman BH. Gene expression (collagenase, tissue inhibitor of metalloproteinases, complement, and HLA-DR) in rheumatoid arthritis and osteoarthritis synovium: quantitative analysis and effect of intrarticular steroids. *Arthritis Rheum* 1991;34:1094-105.
  42. Holliday LS, Welgus HG, Fliszar CJ, Veith GM, Jeffrey JJ, Gluck SL. Initiation of osteoclast bone resorption by interstitial collagenase. *J Biol Chem* 1997;272:22053-8.
  43. Zhao W, Byrne MH, Boyce BF, Krane SM. Bone resorption induced by parathyroid hormone is strikingly diminished in collagenase resistant mutant mice. *J Clin Invest* 1999;103:517-24.
  44. Teitelbaum SL. Bone resorption by osteoclasts. *Science* 2000;289:1504-8.
  45. Gravalles EM, Manning C, Tsay A, et al. Synovial tissue in rheumatoid arthritis is a source of osteoclast differentiation factor. *Arthritis Rheum* 2000;43:250-8.
  46. Danning CL, Illei GG, Hitchon C, Greer MR, Boumpas DT, McInnes IB. Macrophage-derived cytokine and nuclear factor  $\kappa$ B p65 expression in synovial membrane and skin of patients with psoriatic arthritis. *Arthritis Rheum* 2000;43:1244-56.
  47. McHugh KP, Hoidalva-Dilke K, Zheng MH, et al. Mice lacking beta3 integrins are osteosclerotic because of dysfunctional osteoclast. *J Clin Invest* 2000;105:433-40.
  48. Saren P, Welgus HG, Kovanen PT. TNF-alpha and IL-1 beta selectively induce expression of 92-kDa gelatinase by human macrophages. *J Immunol* 1996;157:4159-65.
  49. Meyer FA, Yaron I, Yaron M. Synergistic, additive, and antagonistic effects of interleukin-1 beta, tumor necrosis factor alpha, and gamma-interferon on prostaglandin E, hyaluronic acid, and collagenase production by cultured synovial fibroblasts. *Arthritis Rheum* 1990;33:1518-25.

50. Ritchlin C, Haas-Smith SA, Hicks D, Cappuccio J, Osterland CK, Looney RJ. Patterns of cytokine production in psoriatic synovium. *J Rheumatol* 1998;25:1544-52.
51. Lacraz S, Nicod LP, Chicheportiche R, Welgus HG, Dayer J-M. IL-10 inhibits metalloproteinase and stimulates TIMP-1 production in human mononuclear phagocytes. *J Clin Invest* 1995;96:2304-10.
52. Cunnane G, FitzGerald O, Hummel KM, Gay RE, Gay S, Bresnihan B. Collagenase, cathepsin B and cathepsin L gene expression in the synovial membrane of patients with early inflammatory arthritis. *Rheumatology* 1999;38:34-42.
53. Danning CL, Illei GG, Lee EG, Boumpas DT, McInnes IB.  $\alpha$ v $\beta$ 3 integrin expression in psoriatic arthritis [abstract]. *Arthritis Rheum* 1998; Suppl 41:S346.
54. Veale D, Yanni G, Rodgers S, Barnes L, Bresnihan B, Fitzgerald O. Reduced synovial membrane macrophage numbers, ELAM-1 expression and lining layer hyperplasia in psoriatic arthritis as compared with rheumatoid arthritis. *Arthritis Rheum* 1993; 36:893-900.
55. Ceponis A, Kontinen YT, Imal S, et al. Synovial lining, endothelial and inflammatory mononuclear cell proliferation in synovial membranes in psoriatic and reactive arthritis: a comparative quantitative morphometric study. *Br J Rheumatol* 1998;37:170-8.
56. Itoh T, Tanioka M, Yoshida H, Yoshioka T, Nishimoto H, Itohara S. Reduced angiogenesis and tumor progression in gelatinase A deficient mice. *Cancer Res* 1998;58:1048-51.
57. Hiraoka N, Allen E, Apel IJ, Gyetko MR, Weiss SJ. Matrix metalloproteinases regulate neovascularization by acting as pericellular fibrinolysins. *Cell* 1998;95:365-77.
58. Ritchlin C, Greenwald RA, Moak SA, Haas-Smith S. Pattern of metalloproteinase production in psoriatic synovial explant tissues [abstract]. *Arthritis Rheum* 1998; Suppl 41:S335.
59. Kane D, Bresnihan B, Whitehead S, Fitzgerald O. Upregulation of collagenase stromelysin and TIMP-1 mRNA expression in psoriatic arthritis synovium [abstract]. *Arthritis Rheum* 1999; Suppl 42:S374.
60. Koolwijk P, Miltenburg AMM, Van Erck MGM, et al. Activated gelatinase-B (MMP9) and urokinase-type plasminogen activator in synovial fluids of patients with arthritis. Correlation with clinical and experimental variables of inflammation. *J Rheumatol* 1995;22:385-93.
61. Makela M, Larjara H, Pirila E, et al. Matrix metalloproteinase 2 (gelatinase A) is related to migration of keratinocytes. *Exp Cell Res* 1999;251:67-78.
62. Herrmann G, Brenneisen P, Wlaschek M, et al. Psoralen photoactivation promotes morphological and functional changes in fibroblasts in vitro reminiscent of cellular senescence. *J Cell Sci* 1998;111:759-67.
63. Varani J, Burmeister B, Sitrin RG, et al. Expression of serine proteinases and metalloproteinase in organ-cultured human skin. Altered levels in the presence of retinoic acid and possible relationship to retinoic acid and possible relationship to retinoid-induced loss of epidermal cohesion. *Am J Pathol* 1994;145:561-73.
64. Feliciani C, Vitullo P, D'Orazi G, et al. The 72-kDa and the 92-kDa gelatinases, but not their inhibitors TIMP-1 and TIMP-2, are expressed in early psoriatic lesions. *Exp Dermatol* 1997;6:321-7.
65. Varani J, Kang S, Stoll S, Elder JT. Human psoriatic skin in organ culture: comparison with normal skin exposed to exogenous growth factors and effects of an antibody to the EGF receptor. *Pathobiology* 1998;6:253-9.