

Pigmented Villonodular Synovitis. Review of 20 Cases

HANS ROLAND DÜRR, ANDREAS STÄBLER, MARKUS MAIER, and HANS JÜRGEN REFIOUR

ABSTRACT. Objective. Pigmented villonodular synovitis (PVS) is a rare aggressive lesion. Inclusion of this disease in the differential diagnosis of rheumatoid arthritis can lead to early diagnosis and treatment. In this retrospective study we evaluated diagnostic procedures, therapies, and outcomes of PVS.

Methods. Twenty surgically treated cases of PVS were evaluated: joint, 16; tenosynovial, 3; and bursa, one. The 20 patients had undergone the following surgeries: 4 total synovectomies, 2 subtotal synovectomies, eight arthroscopically assisted resections, 4 resections of extraarticular lesions, and 2 arthroplasties. The mean followup was 17.5 mo (1–54).

Results. At diagnosis, pain was present in 19 of 20 cases. Joint swelling or a tumor was found in 11 cases, and 12 patients complained of repeated joint effusions. The mean duration of symptoms was 23.8 mo (range 1–144). Half the cases had a nodular pattern and the other half a diffuse pattern. The most common location of PVS was the knee (14 patients). Surgical treatment before admission did not always lead to an accurate diagnosis. For example, in 2 patients, arthroscopy did not reveal PVS. In 2 patients a soft tissue sarcoma was suggested. In 3 patients, the diagnosis was made incidentally with arthroscopy or arthroplasty. On radiographs, bone lesions were seen in 8 cases; in 13 of 17 cases the diagnosis was by magnetic resonance imaging (MRI). After surgery 17 patients stayed free of recurrence, 14 without symptoms. One patient who had an incidental diagnosis of PVS has a synovectomy planned as a second procedure. One patient awaits a second dorsal procedure after a ventral knee synovectomy. One patient shows recurrent disease 33 mo after resection of a nodular knee lesion.

Conclusion. PVS should be included in the differential diagnosis of any arthritis. MRI is the most effective diagnostic tool in identifying PVS. The treatment of PVS consists of surgical excision in sound tissue. A total synovectomy should be the treatment of choice in diffuse disease. From the literature, nonsurgical therapies, such as steroid injections, ⁹⁰Y synoviorthesis, or external beam radiation, seem to be of benefit in selected patients. (J Rheumatol 2001;28:1620–30)

Key Indexing Terms:

PIGMENTED VILLONODULAR SYNOVITIS

MAGNETIC RESONANCE IMAGING
SYNOVECTOMY

First described by Chassaignac, pigmented villonodular synovitis (PVS) is a benign but aggressive lesion of the synovial membrane¹. The knee is the most commonly involved site². PVS is rare, with an annual incidence estimated to be 1.8 patients per million population. Young adults are most often affected³. Due to the distribution of synovial tissue, PVS commonly occurs monoarticularly, but it can also occur along tendon sheaths (pigmented villonodular tenosynovitis, PVTS) or in bursae (pigmented villonodular bursitis, PVB)⁴. PVTS is often described as the “giant cell tumor of the tendon sheath.” Due to the possibility of localized or diffuse involvement, the descriptive prefix L or D is used (LPVS or DPVS) in order to avoid the term nodular, especially in diffuse PVS^{5,6}.

PVS is characterized by brownish, villous, and nodular growths containing groups of histiocytes. Histologically, fibrous stroma, hemosiderin deposits, giant cells, and foam cells are found, sometimes invading the adjacent bone in an aggressive manner⁷. The etiology is unknown. Inflammation due to an unknown agent^{4,8} and repetitive traumatic events are suggested as possible causes⁹. There is also some evidence supporting a neoplastic process, especially in diffuse forms of the disease^{10–13}.

The diagnosis of PVS is delayed in many cases due to the nonspecific clinical symptoms. Recurrent joint effusions, locking of the joint by nodular lesions, and diffuse aggressive disease with bone erosions are manifestations associated with a number of different lesions, from loose bodies and meniscal tears to rheumatoid arthritis (RA). Therefore, including this disease in the differential diagnosis of RA and early use of magnetic resonance imaging (MRI) may lead to earlier diagnosis and prevent joint damage resulting from delayed treatment¹⁴.

Treatment of PVS is controversial. Surgical excision of affected tissue, total or subtotal synovectomy, radiosynovectomy, and even external beam radiation have all been advocated^{6,15–18}. We evaluated the diagnostic procedures, surgical therapies, and clinical outcomes of 20 patients with PVS.

From the Department of Orthopedics and Orthopedic Surgery and the Institute of Radiology, Ludwig Maximilians University, Munich, Germany. Supported by the Curt-Bohneward-Fund.

H.R. Dürr, MD; M. Maier, MD; H.J. Refior, MD, PhD, Director, Department of Orthopedics and Orthopedic Surgery; A. Stäbler, MD, PhD, Institute of Radiology.

Address reprint requests to Dr. H.R. Dürr, Orthopaedische Klinik und Poliklinik, Universitaet Rostock, Ulmenstrasse 44/45, D-18055 Rostock, Germany. E-mail: hans_roland.duerr@med.uni-rostock.de

Submitted June 20, 2000; revision accepted January 19, 2001.

MATERIALS AND METHODS

Seven men and 13 women with PVS treated surgically at our institution between 1995 and 1999 were studied retrospectively. The mean age at surgery was 46.0 years (range 16–82) (Figure 1). The medical records and radiological images of each patient were reviewed. Followup data were obtained on all patients with a clinical and radiological evaluation at our institution, through a local physician in the patient's community, or through telephone contact with the patient. Followup occurred at a mean of 17.5 months (1–54) after surgery. In all cases, the diagnosis of PVS was proven with a histologic examination. Local recurrence was confirmed either by a second surgical procedure or by MRI. The subjects included 16 cases with joint involvement (PVS), 3 cases of tenosynovial involvement (PVTS) (Figure 2), and one case with a bursa lesion (PVB) (Figure 3; Table 1). In 10 cases, a nodular pattern was seen (Figure 4) and in the other 10 cases, a diffuse pattern (Figure 5). The most commonly involved joint was the knee (14 patients). Three patients showed a local recurrent lesion at admission after having surgery elsewhere. The surgical procedures included 4 open synovectomies, 2 open subtotal synovectomies (anterior compartment), 8 arthroscopically assisted mini-arthrotomies with resection of nodular disease (Figure 6), 4 resections of soft tissue lesions, and 2 total knee joint replacements.

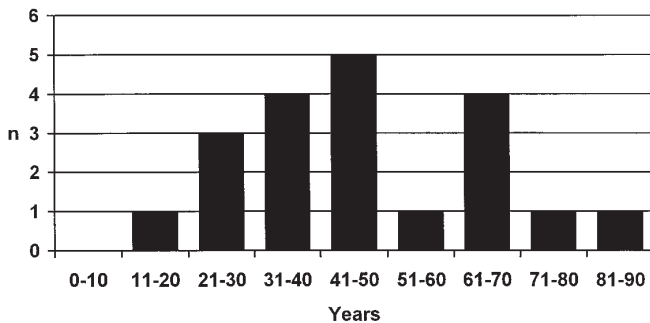


Figure 1. Distribution of age in 20 patients with pigmented villonodular synovitis.

Table 1. Location and growth pattern in 20 patients with pigmented villonodular synovitis.

Patient	Type of Lesion	Growth Pattern	Region
1	PVS	D	Knee joint
2	PVS	N	Knee joint
3	PVS	N	Knee joint
4	PVS	D	Knee joint
5	PVS	N	Knee joint
6	PVS	D	Knee joint
7	PVS	D	Knee joint
8	PVS	N	Knee joint
9	PVS	N	Knee joint
10	PVS	N	Knee joint
11	PVS	N	Knee joint
12	PVS	D	Knee joint
13	PVS	D	Knee joint
14	PVS	N	Knee joint
15	PVS	D	Ankle joint
16	PVS	D	Hip joint
17	PVB	N	Gluteal bursa
18	PVTS	N	Toe
19	PVTS	D	Toe
20	PVTS	D	Finger

D: diffuse; N: nodular; PVTS: pigmented villonodular tenosynovitis; PVB: pigmented villonodular bursitis.

RESULTS

Clinical symptoms. The most common symptom was pain, which was reported in 19 of 20 cases. A swelling of the joint or a slow growing tumor in the involved soft tissue region was reported in 11 cases. Twelve patients complained of repeated monoarticular effusions and some underwent repeated aspirations. A limited range of motion was seen in 6 involved joints. The mean duration of symptoms was 23.8 months (range 1–144), highlighting the difficulties associated with the diagnosis of this disease. Three patients attributed their symptoms to a traumatic event.

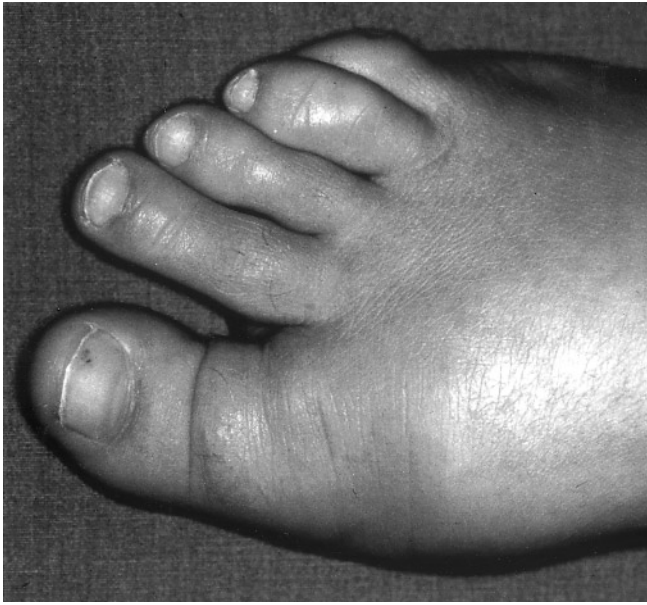Previous treatment. Four patients underwent surgery before admission that did not lead to the correct diagnosis. In 2 patients, arthroscopic procedures were performed; in 2 others, a soft tissue sarcoma was suggested after a partial resection of a lesion. As a result, one patient received several cycles of chemotherapy. In one patient, several open synovectomies of the knee joint had been done before admission because of recurrences.

Diagnostic procedures. Radiographs were obtained for all patients and showed lesions of the bone in 8 cases. MRI was obtained in 17 of the 20 cases. Three patients did not receive an MRI because the diagnosis of PVS had been made incidentally during knee joint arthroplasty (n = 2) and a knee arthroscopy performed for a suspected meniscal lesion (n = 1). PVS was suspected in 13 of 17 MRI examinations. In the remaining 4 cases, 2 were suspected of having a tumor, and in one case each a hemangioma or a ganglion was suspected.

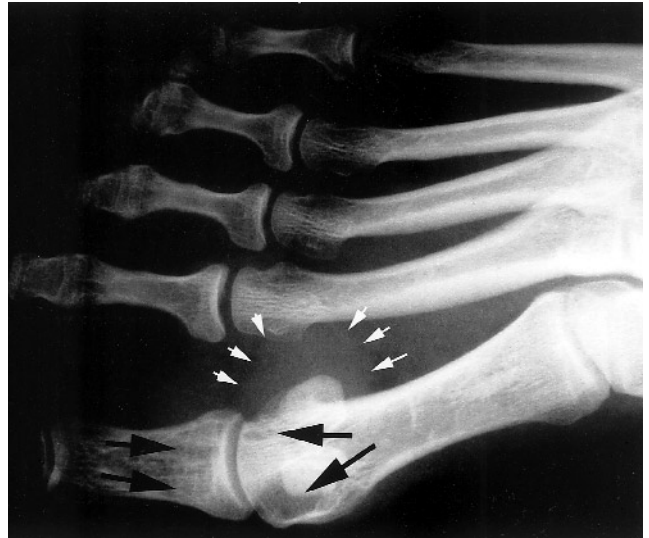Followup. Surgical complications did not occur and no patient received any form of adjuvant therapy. In total, 14 patients stayed free of recurrence without clinical symptoms. Two patients without recurrence and unaltered knee joints as seen on radiographs complained of recurrent pain. One patient with severe knee joint destruction due to years of PVS with multiple recurrences was free of disease, but suffered repeated pain, swelling, and reduced range of motion (Figure 7). A knee arthroplasty is planned in this patient. Open synovectomy is planned for a patient whose PVS was found incidentally during knee joint arthroplasty. The one patient who has already undergone a subtotal synovectomy of the anterior knee compartment is awaiting a second synovectomy of the dorsal compartment. Only one patient has recurrent disease, 33 months after arthroscopically assisted mini-arthrotomy and resection of a nodular lesion in the anterior knee compartment.

DISCUSSION

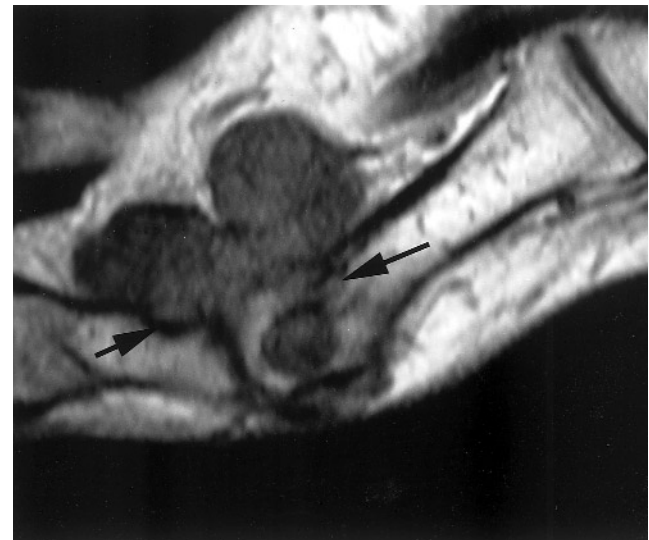
Etiology. Many theories have been discussed regarding the etiology of PVS. A primary concern is an explanation for the inflammatory component of PVS lesions. Some theories suggest that repetitive traumatic events or hemarthrosis could cause PVS, because PVS-like lesions have been



A

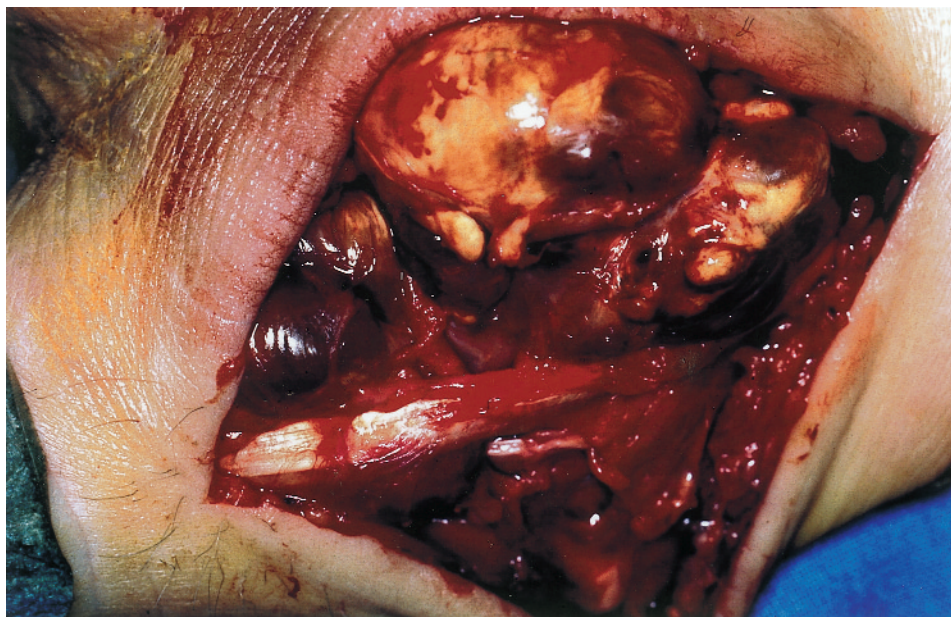


B

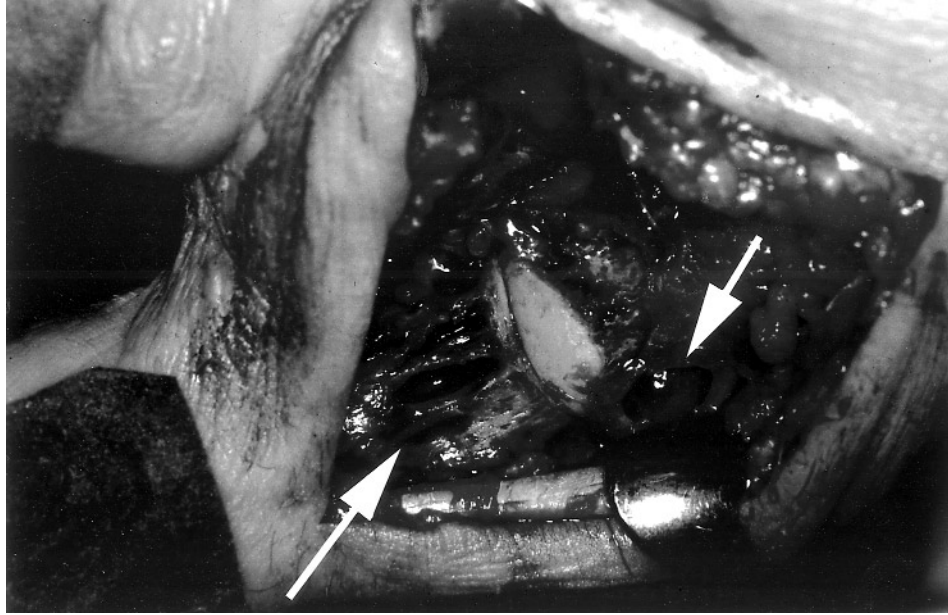


C

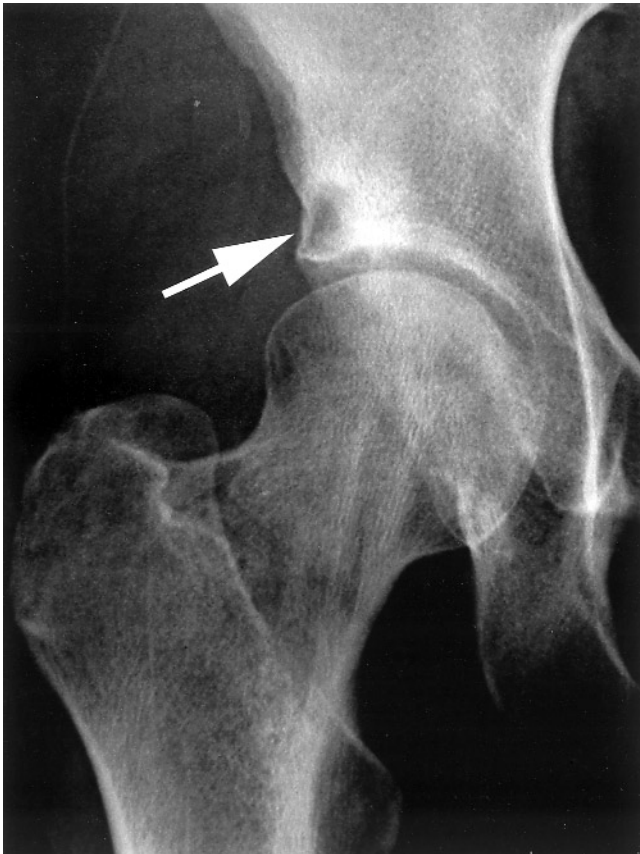
Figure 2. A. A 35-year-old woman had pain and swelling in the base of the right first toe for 12 months. B. Radiograph shows multiple osteolytic lesions in the distal metacarpal and the proximal phalangeal bone (large arrows) and a large soft tissue swelling (small arrows). C. Sagittal T1 weighted MRI scan of the first metacarpal and phalanx showing a soft tissue tumor with low signal intensity compared to the high signal intensity of unaffected bone marrow invading the bone in several areas (arrows). D. Intraoperative view shows the large synovitic brownish tumor extending along the extensor tendon and invading the bone. E. Several osteolytic defects in the metacarpal and phalangeal bone after removal of the lesion (arrows).



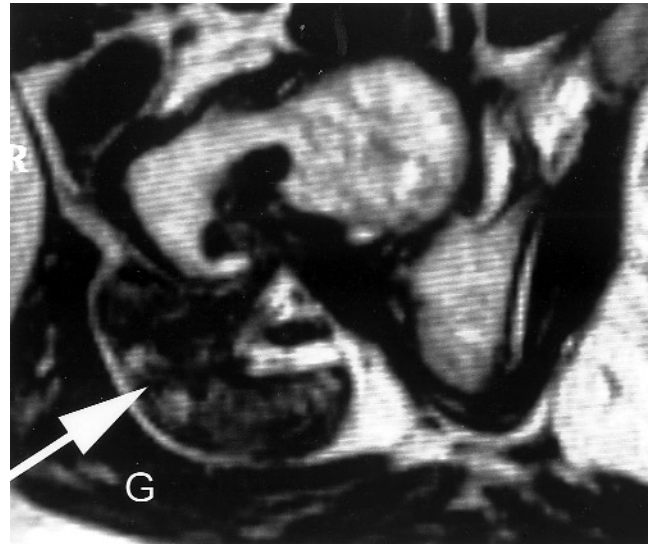
D



E

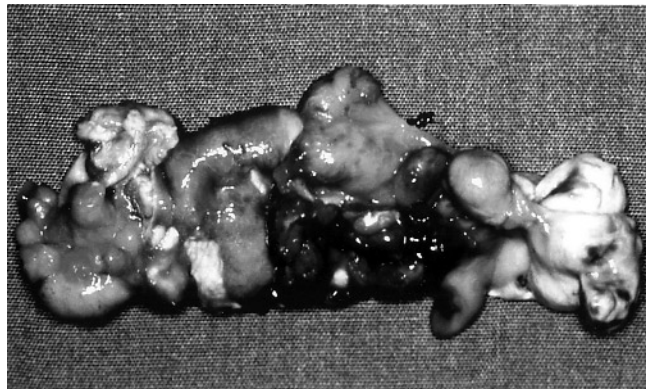
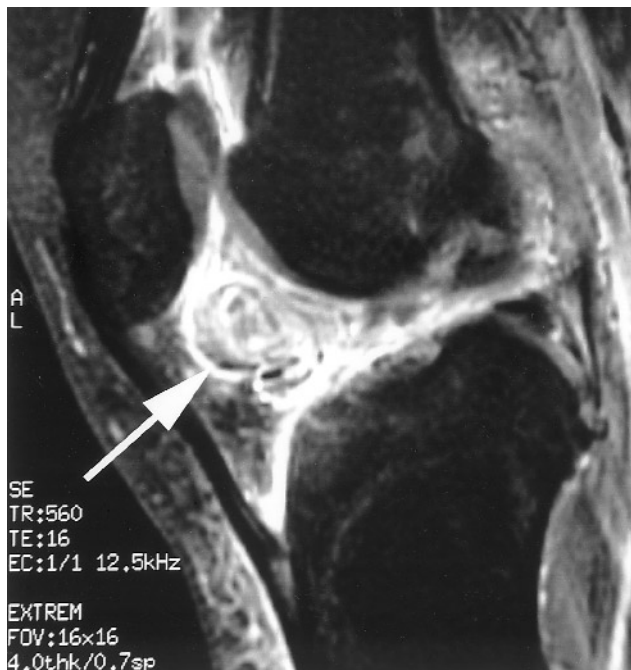


A



B

Figure 3. A. Radiograph of a 49-year-old woman with pain in the right hip and reported tenderness of the gluteal region for 12 months. Because of the cystic lesion in the acetabulum (arrow), the initial diagnosis was coxarthrosis. The femoral neck and the soft tissue appear normal. B. Axial T2 weighted MRI scan shows the large pigmented villonodular bursitis (arrow) between the gluteal muscles (G) and the hip joint with invasion of bone in the distal neck of the femur. In contrast to reactive synovitis, larger low signal areas are visible.



A

B

Figure 4. A. Sagittal T1 weighted SE fat saturated MRI scan of the knee after administration of Gd-DTPA in a 27-year-old woman who had pain and repeated joint effusions for 4 years. A large nodular lesion can be seen in the anterior compartment of the joint in Hoffa's fat pad showing contrast enhancement (arrow). B. PVS lesion was excised by arthroscopically assisted mini-arthrotomy.

produced by injecting blood or colloidal iron into the synovia¹⁹⁻²¹. This might explain some histological similarities between PVS and the synovitis found in hemophiliac patients, but does not explain the lesions in patients without traumatic events and those with extended soft tissue lesions²².

Specific bacteria or viruses have not been identified in PVS⁵. One of the major drawbacks in reactive inflammatory theories is the explanation of nodular disease and recurrence after incomplete excision¹⁰. For this reason, neoplastic theories have been examined recently.

Cytogenetic analysis has revealed clonal abnormalities, such as trisomy 7, indicating a neoplastic proliferation^{11,13,23,24}. However, other investigators found conflicting results with cytogenetic heterogeneities⁸. There are reports of patients with histologically proven PVS developing distant pulmonary or lymph node metastases²⁵. Whether these lesions represent a true neoplastic entity that is a malignant counterpart of PVS is still debatable.

Genetic factors may also be associated with this disease, as 3 generations of children with multiple lentiginos syndrome have been reported²⁶.

Epidemiology. Consistent with our data, PVS is most often found in patients between 20 and 50 years of age²⁷. Females tend to be more frequently affected than males (13 female, 7 male in this series)^{10,28}. The knee is the most common location, followed by the hip, ankle, and shoulder^{3,29,30}. However, any other region with synovial tissue can be affected. Even though multiple simultaneous lesions are possible, monoarticular disease is most often found³¹. In the knee, the diffuse form seems to be more common than the localized form⁶.

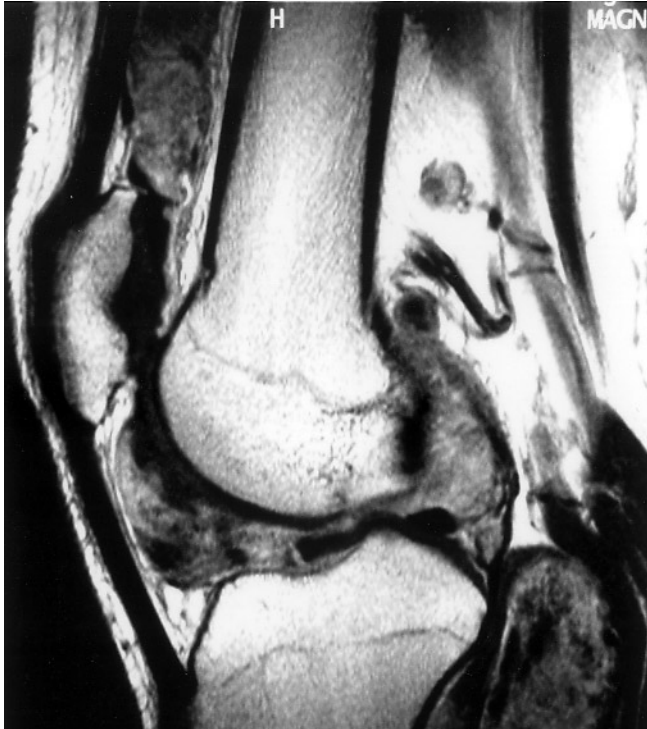Clinical symptoms. The clinical symptoms of PVS are nonspecific. A few patients may recall a traumatic event preceding the symptoms, but most cases have a gradual progression of symptoms. In this study only 5 patients experienced symptoms for less than one year, whereas 12 of 20 patients reported experiencing symptoms for one to 2 years before being diagnosed. Other studies report symptoms for a longer period before an accurate diagnosis is made, between 2 and 5 years¹⁶. Localized nodular forms may mimic other common knee lesions.

Aspirated joint effusions are sometimes bloodstained or brownish, providing a clue to diagnosis^{3,29}. However, a differential diagnosis based on analysis of the synovial fluid is almost impossible⁶.

Imaging. The effectiveness of several radiological imaging methods in diagnosing PVS has been investigated. Synovial swelling with an absence of calcifications within the swelling, normal bony mineralization of the affected joint, and preservation of the joint space are typical imaging findings³². In PVTS, bony erosions are found in about 25% of the cases³, whereas in diffuse disease of the joints, between 33 and 54% may show well corticated cysts or erosions of the adjacent bone, especially in tight joints such as the hip (Figure 8)³³.

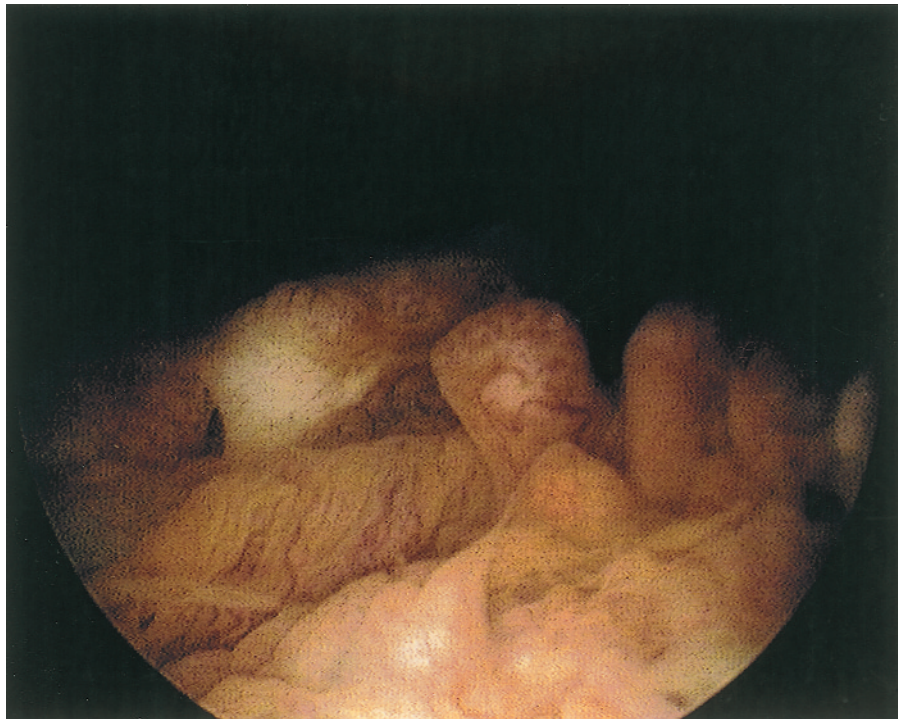A variety of imaging methods have been used to diagnose PVS, each having varying degrees of diagnostic value. These methods include arthrography, nuclear bone scans, ultrasound (US), computed tomography (CT), and MRI.

Both arthrography and nuclear bone scans have proven to be limited in their diagnostic value. Arthrography, used more commonly in the pre-MRI period, may show filling defects due to intraarticular nodules, but is not widely



A

Figure 5. A. Sagittal T1 weighted contrast enhanced MRI scan of the knee joint in a 32-year-old man who had pain, swelling, and effusion of the joint for 13 months. A diffuse synovitic lesion with enhancing solid soft tissue masses can be seen throughout the joint and in a large Baker's cyst. B. Diffuse PVS was identified arthroscopically. Patient was treated with 2 stage anterior and posterior total synovectomy.



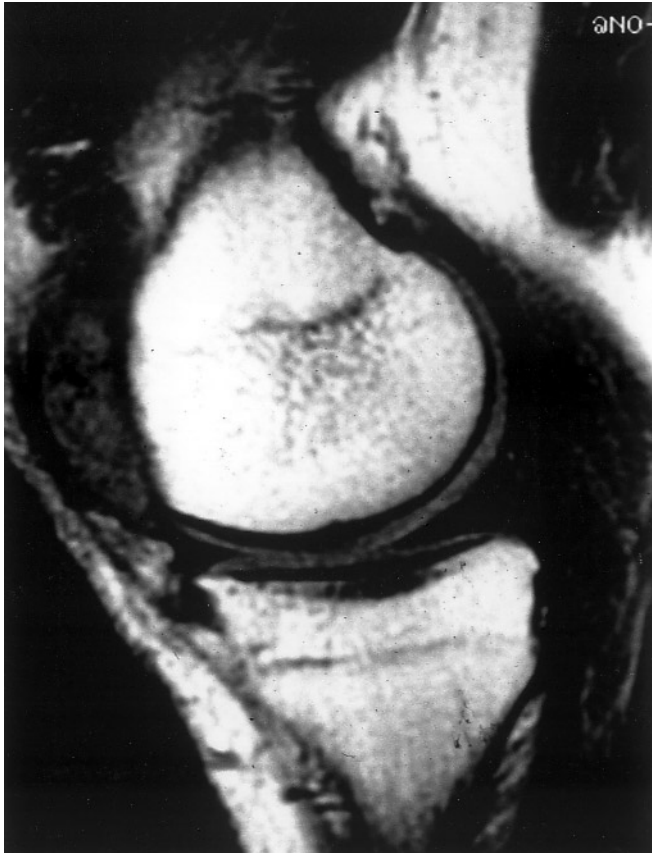B

used^{34,35}. Nuclear bone scans, even with thallium, are of minimal diagnostic value because of their nonspecific results^{36,37}.

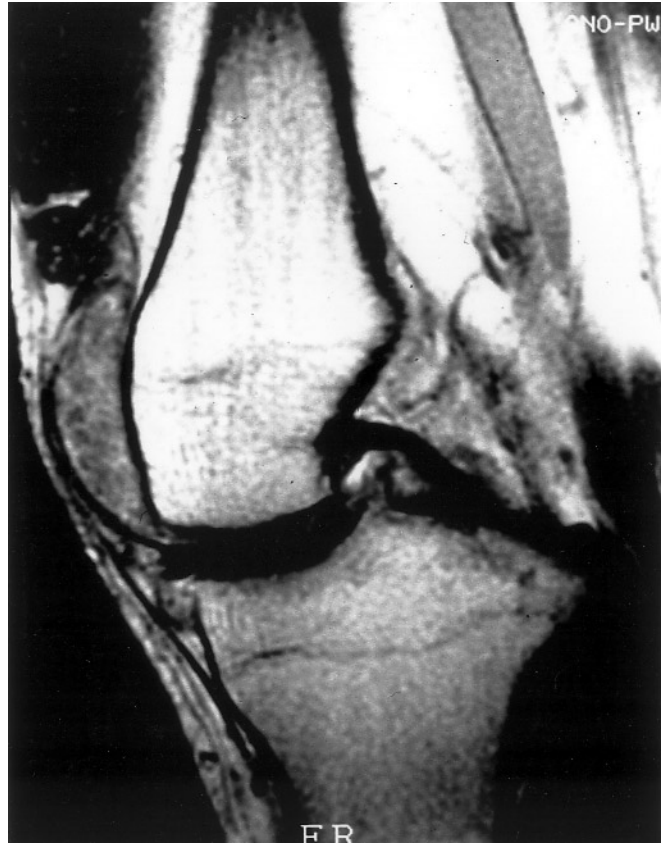Ultrasound, conversely, does provide diagnostic information that may be helpful, especially in localized disease, in revealing lesions and differentiating them from other

common joint conditions, such as meniscal lesions³⁸. In addition, US is easily obtained. But since the accuracy of US depends to a high degree on the personal experience of the examiner, a general recommendation cannot be given. In this series, US was not performed.

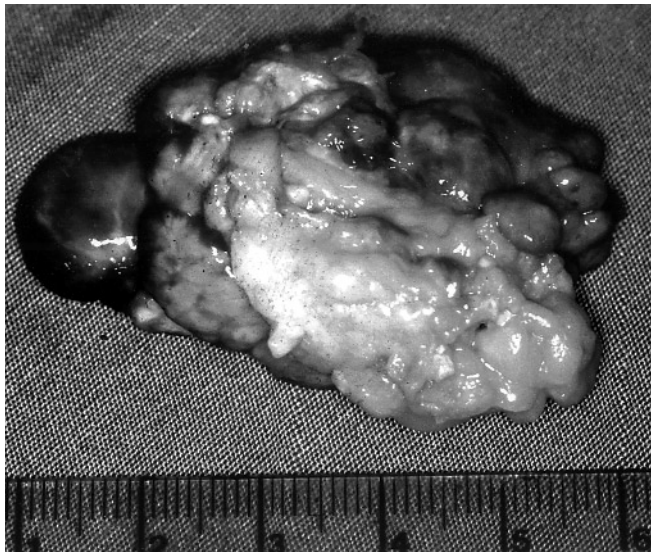
Because PVS contains iron deposits, CT is especially



A



B



C

Figure 6. A. Sagittal T1 weighted SE MRI scan of the knee in a 29-year-old man who had pain, swelling, and effusion of the joint for 144 months. MRI shows the typical low signal of hemosiderin pigmentation in a nodular PVS. B. Sagittal T1 weighted contrast enhanced MRI scan shows the lesion through uptake of the contrast medium. Enhancement is diminished and inhomogenous compared to that normally seen with RA. C. Lesion was resected with arthroscopically assisted mini-arthrotomy. Patient is free of symptoms after 27 months.

useful in delineating bony erosions, as well as in revealing high attenuation tissue³⁹. However, CT is limited in its delineation of soft tissue lesions and its sensitivity to inflammatory tissue.

MRI has proven its superiority in detecting PVS over other imaging methods. With MRI, it is possible to simultaneously visualize hemosiderin deposits, lipids, and inflam-

mation tissue in PVS. Hemosiderin causes a decreased signal intensity on T1 and T2 weighted images. If the tissue contains enough hemosiderin, it will have a low signal on all pulse sequences (Figures 2–6)^{40,41}. Caution must be taken, however, because diseases such as RA, hemophilia, amyloid arthropathy, and even osteoarthritis may also show the same findings³². Although it is nonspecific, with the use of

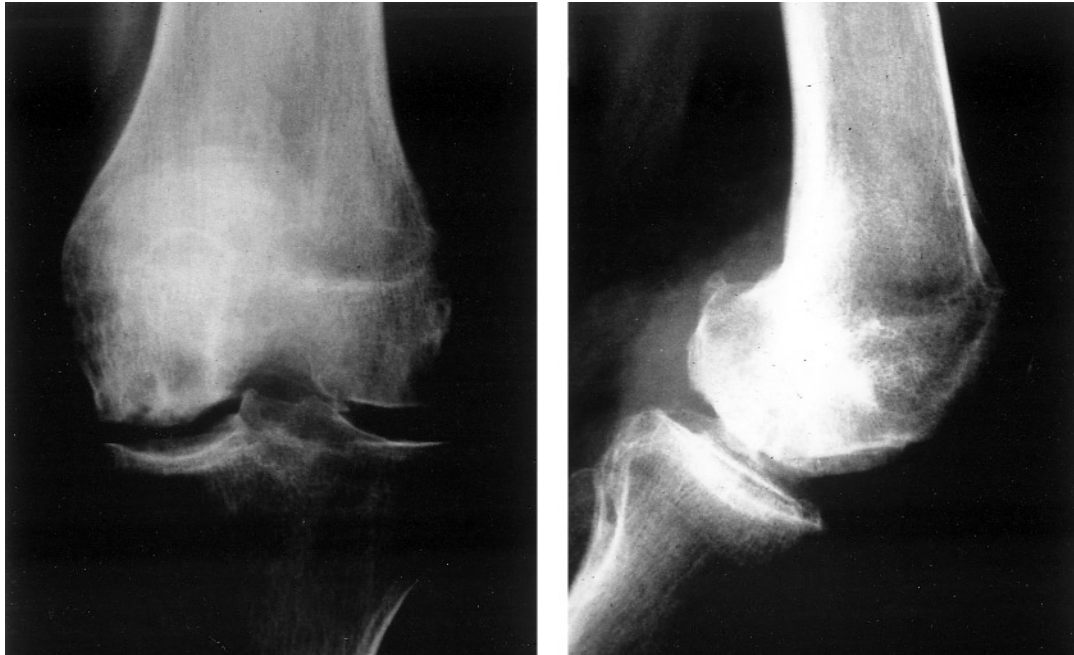

Figure 7. Radiographs of knee joint from a 35-year-old woman show a small osteolytic lesion after multiple arthroscopic and open synovectomies. She is free of PVS but the joint shows the typical postarthritic destruction pattern.

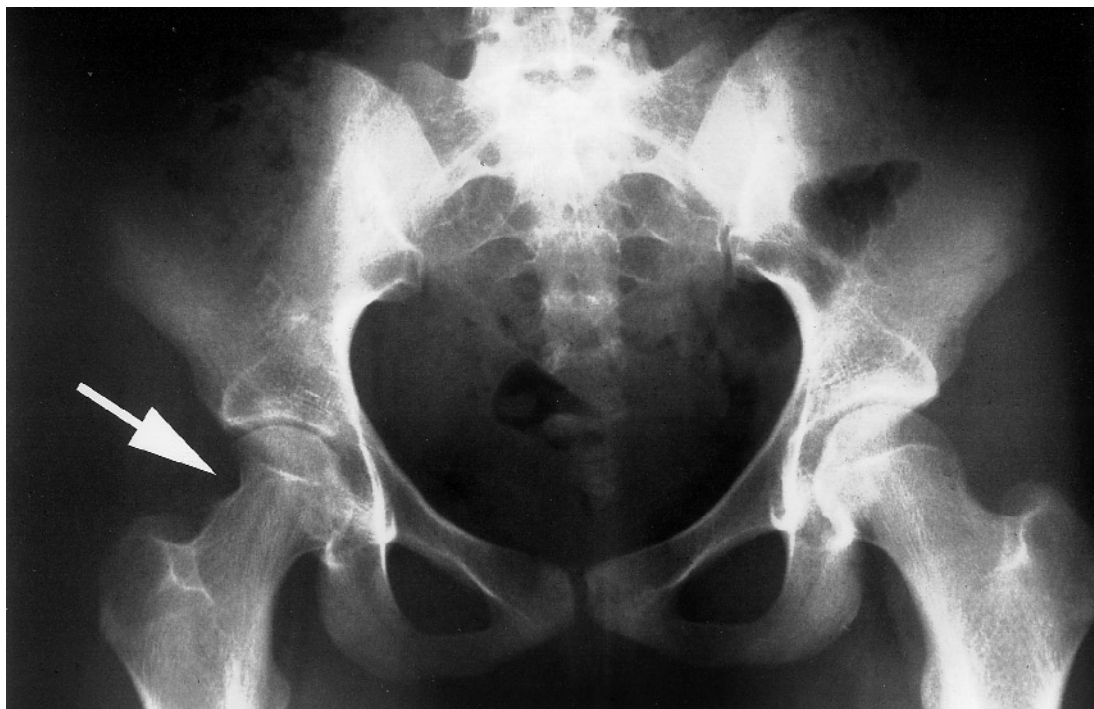

Figure 8A.

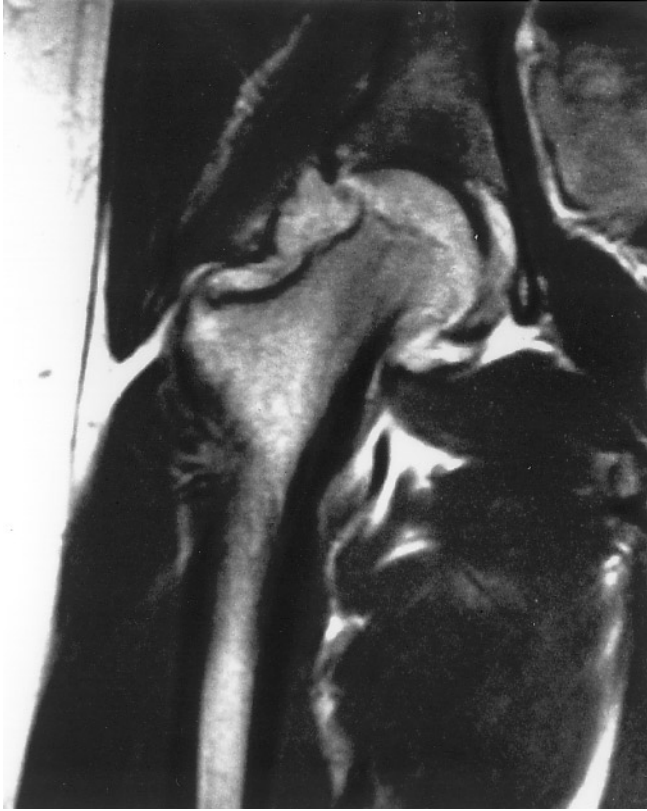

Figure 8. A. Radiograph of the pelvis of a 16-year-old girl shows pressure related erosions of the lateral femoral neck on the right side (arrow) and the beginning of joint space narrowing. She had pain and limited motion for 15 months. B. Coronal T1 weighted Gd enhanced SE MR image shows the synovitic lesion with additional joint effusion and bone erosion. She is free of symptoms 14 months after open synovectomy.

contrast enhancement, more nodules of the lesion may be visible, allowing a more precise location of the disease⁴². In our experience, a preoperative diagnosis was possible in 13 of 17 lesions examined with MRI. MRI has proven to be the most precise imaging tool, especially at the knee joint⁴³.

Therapy. PVS is predominantly treated with surgery. Several studies report that the localized form of PVS can be treated with a simple, even arthroscopically performed excision of the lesion, with very low recurrence rates^{28,44}. In our study, only one patient in 8 had recurrence on MRI of the knee joint after arthroscopically assisted mini-arthrotomy and resection. In diffuse forms of joint disease, total synovectomy is the commonly recommended method of treatment⁴⁵. There is no agreement whether this procedure should be done by arthrotomy or arthroscopically, especially in the knee joint. Due to the difficulties associated with total arthroscopic synovectomies, recurrence rates are lower in open procedures than in arthroscopic synovectomies, at least in centers with less arthroscopic experience (8% in 24 patients vs 17% in 12 patients)^{45,46}. On the other hand, post-operative morbidity is lower in arthroscopically treated

patients than in open synovectomies in most of the studies^{2,46,47}. In cases of destructive joint disease, total knee arthroplasty is a viable option, but due to the often young age of these patients, it may result in early failure. Aseptic loosening resulted in revision arthroplasty for 3 patients, above-knee amputation in one of 18 cases after knee arthroplasty for PVS⁴⁸. In a review of 99 patients with surgically treated PVS in a period of 67 years, 25 recurrences occurred. Significantly higher recurrence rates were observed in lesions of the knee joint after previous operative procedures and incomplete synovectomies. A continuous recurrence-free survival rate of only 65% was found after 25 years¹⁶. Local recurrences after several surgical procedures, especially in patients with diffuse PVS, may lead to significant problems. Hence, nonsurgical forms of treatment have been evaluated in recent years.

Local injection of steroids is a method that is easy to perform and was successful in a number of cases^{29,49}.

A few early reports focused on the use of radiosynoviothrosis, as used with RA⁵⁰⁻⁵². In one study, a good response to ⁹⁰Y was observed in 4 of 8 patients, 6 of whom had been previously treated with surgery⁵³. In this study, after a surgical synovectomy to decrease synovial thickening 5 of 6 joints treated within the first 6 months after surgery and 4 of 6 patients treated later showed marked longterm improvement⁵⁴.

There are also a few case studies of external beam radiation, and one larger study of 14 patients (6 primary, 8 recurrent lesions, all diffuse type)¹⁸. In the latter study, 13 patients showed a complete response and one had to be treated surgically 9 years after radiation with excision of the lesion. Eleven patients showed at least good function, while 3 had fair functional results. The authors concluded that in large PVS lesions after surgical resection, a moderate dose of radiotherapy (35 Gy in 15 fractions) is beneficial for residual disease, if additional surgery would lead to major functional deficiencies.

In conclusion, the etiology of PVS is still unclear. Distinctive nomenclature should be used for comparing different diagnostic and therapeutic techniques. MRI has proved to be the most helpful tool in the investigation of PVS. In uncertain cases, an arthroscopic biopsy is easily obtainable. Treatment mainly consists of surgical excision of affected tissue. In experienced centers, this may be done arthroscopically. Total synovectomy should be the treatment of choice in diffuse disease. From the literature, nonsurgical therapies such as steroid injections, ⁹⁰Y synoviorthesis, or external beam radiation seem to be of considerable benefit in selected patients.

REFERENCES

1. Chassaignac M. Cancer de la gaine des tendons [Cancer of the tendon sheath]. *Gaz Hop Civ Milit* 1852;47:185-6.
2. Ogilvie-Harris DJ, McLean J, Zarnett ME. Pigmented villonodular synovitis of the knee. The results of total arthroscopic

- synovectomy, partial arthroscopic synovectomy, and arthroscopic local excision. *J Bone Joint Surg (Am)* 1992;74:119-23.
3. Myers BW, Masi AT. Pigmented villonodular synovitis and tenosynovitis: a clinical epidemiologic study of 166 cases and literature review. *Medicine (Baltimore)* 1980;59:223-38.
 4. Jaffe HL, Lichtenstein L, Sutro CJ. Pigmented villonodular synovitis, bursitis and tenosynovitis. A discussion of the synovial and bursal equivalents of the tenosynovial lesions commonly denoted as xanthoma, xanthogranuloma, giant cell tumor or myeloplaxoma of the tendon sheath, with some consideration of this tendon sheath lesion itself. *Arch Pathol* 1941;31:731-65.
 5. Granowitz SP, D'Antonio J, Mankin HL. The pathogenesis and long-term end results of pigmented villonodular synovitis. *Clin Orthop* 1976;114:335-51.
 6. Flandry F, Hughston JC. Pigmented villonodular synovitis. *J Bone Joint Surg (Am)* 1987;69:942-9.
 7. Mirra JM. Pigmented villonodular synovitis invading bone. Bone tumors. Clinical, radiologic, and pathologic correlations. Vol 1. Philadelphia: Lea & Febiger; 1989:1766-75.
 8. Sakkers RJ, de Jong D, van der Heul RO. X-chromosome inactivation in patients who have pigmented villonodular synovitis. *J Bone Joint Surg (Am)* 1991;73:1532-6.
 9. Hirohata K. Light microscopic and electron microscopic studies of individual cells in pigmented villonodular synovitis and bursitis (Jaffe). *Kobe J Med Sci* 1968;14:251-79.
 10. Rao AS, Vigorita VJ. Pigmented villonodular synovitis (giant-cell tumor of the tendon sheath and synovial membrane). A review of eighty-one cases. *J Bone Joint Surg (Am)* 1984;66:76-94.
 11. Choong PF, Willen H, Nilbert M, et al. Pigmented villonodular synovitis. Monoclonality and metastasis — a case for neoplastic origin? *Acta Orthop Scand* 1995;66:64-8.
 12. Abdul-Karim FW, el-Naggar AK, Joyce MJ, Makley JT, Carter JR. Diffuse and localized tenosynovial giant cell tumor and pigmented villonodular synovitis: a clinicopathologic and flow cytometric DNA analysis. *Hum Pathol* 1992;23:729-35.
 13. Ray RA, Morton CC, Lipinski KK, Corson JM, Fletcher JA. Cytogenetic evidence of clonality in a case of pigmented villonodular synovitis. *Cancer* 1991;67:121-5.
 14. Flipo RM, Desvigne-Noulet MC, Cotten A, et al. Pigmented villonodular synovitis of the hip. Results of a national survey apropos of 58 cases. *Rev Rhum [Ed Fr]* 1994;61:85-95.
 15. Srinivasa R, Vigorita VJ. Pigmented villonodular synovitis (Giant-cell tumor of the tendon sheath and synovial membrane). *J Bone Joint Surg (Am)* 1984;66:76-94.
 16. Schwartz HS, Unni KK, Pritchard DJ. Pigmented villonodular synovitis. A retrospective review of affected large joints. *Clin Orthop* 1989;247:243-55.
 17. Ushijima M, Hashimoto H, Tsuneyoshi M, Enjoji M. Giant cell tumor of the tendon sheath (nodular tenosynovitis). A study of 207 cases to compare the large joint group with the common digit group. *Cancer* 1986;57:875-84.
 18. O'Sullivan B, Cummings B, Catton C, et al. Outcome following radiation treatment for high-risk pigmented villonodular synovitis. *Int J Radiat Oncol Biol Phys* 1995;32:777-86.
 19. Key JA. Experimental arthritis. The reaction of joints to mild irritation. *J Bone Joint Surg (Am)* 1929;11:705-38.
 20. Singh R, Grewal DS, Chakravarti RN. Experimental production of pigmented villonodular synovitis in the knee and ankle joints of rhesus monkeys. *J Pathol* 1969;98:137-42.
 21. Young JM, Hudacek AG. Experimental production of pigmented villonodular synovitis in dogs. *Am J Pathol* 1954;30:799-811.
 22. Stein H, Duthie RB. The pathogenesis of chronic hemophilic arthropathy. *J Bone Joint Surg (Br)* 1981;63:601-9.
 23. Fletcher JA, Henkle C, Atkins L, Rosenberg AE, Morton CC. Trisomy 5 and trisomy 7 are nonrandom aberrations in pigmented villonodular synovitis: confirmation of trisomy 7 in uncultured cells. *Genes Chromosomes Cancer* 1992;4:264-6.
 24. Sciort R, Rosai J, Dal Cin P, et al. Analysis of 35 cases of localized and diffuse tenosynovial giant cell tumor: a report from the Chromosomes and Morphology (CHAMP) study group. *Mod Pathol* 1999;12:576-9.
 25. Bertoni F, Unni KK, Beabout JW, Sim FH. Malignant giant cell tumor of the tendon sheaths and joints (malignant pigmented villonodular synovitis). *Am J Surg Pathol* 1997;21:153-63.
 26. Wendt RG, Wolfe F, McQueen D, Murphy P, Solomon H, Housholder M. Polyarticular pigmented villonodular synovitis in children: evidence for a genetic contribution. *J Rheumatol* 1986;13:921-6.
 27. de Visser E, Veth RP, Pruszczynski M, Wobbes T, van de Putte LB. Diffuse and localized pigmented villonodular synovitis: evaluation of treatment of 38 patients. *Arch Orthop Trauma Surg* 1999;119:401-4.
 28. Johansson JE, Ajjoub S, Coughlin LP, Wener JA, Cruess RL. Pigmented villonodular synovitis of joints. *Clin Orthop* 1982;163:159-66.
 29. Rydholm U. Pigmented villonodular synovitis. *Acta Orthop Scand* 1998;69:203-10.
 30. Dorwart RH, Genant HK, Johnston WH, Morris JM. Pigmented villonodular synovitis of synovial joints: clinical, pathologic, and radiologic features. *AJR Am J Roentgenol* 1984;143:877-85.
 31. Goldman AB, DiCarlo EF. Pigmented villonodular synovitis. Diagnosis and differential diagnosis. *Radiol Clin North Am* 1988;26:1327-47.
 32. Bravo SM, Winalski CS, Weissman BN. Pigmented villonodular synovitis. *Radiol Clin North Am* 1996;34:311-26.
 33. Smith JH, Pugh DG. Roentgenographic aspects of articular pigmented villonodular synovitis. *AJR Am J Roentgenol* 1962;87:1146-56.
 34. Halpern AA, Donovan TL, Horowitz B, Nagel D. Arthrographic demonstration of pigmented villonodular synovitis of the knee. *Clin Orthop* 1978;132:193-5.
 35. Lowenstein MB, Smith JR, Cole S. Infrapatellar pigmented villonodular synovitis: arthrographic detection. *AJR Am J Roentgenol* 1980;135:279-82.
 36. Makhija M, Stein I, Grossman R. Bone imaging in pigmented villonodular synovitis of the knee. *Clin Nucl Med* 1992;17:340-3.
 37. Caluser C, Healey J, Macapinlac H, et al. Tl-201 uptake in recurrent pigmented villonodular synovitis. Correlation with three-phase bone imaging. *Clin Nucl Med* 1992;17:751-3.
 38. Shanley DJ, Auber AE, Watabe JT, Buckner AB. Pigmented villonodular synovitis of the knee demonstrated on bone scan. Correlation with US, CT, and MRI. *Clin Nucl Med* 1992;17:901-2.
 39. Butt WP, Hardy G, Ostlere SJ. Pigmented villonodular synovitis of the knee: computed tomographic appearances. *Skeletal Radiol* 1990;19:191-6.
 40. Jelinek JS, Kransdorf MJ, Utz JA, et al. Imaging of pigmented villonodular synovitis with emphasis on MR imaging. *AJR Am J Roentgenol* 1989;152:337-42.
 41. Hughes TH, Sartoris DJ, Schweitzer ME, Resnick DL. Pigmented villonodular synovitis: MRI characteristics. *Skeletal Radiol* 1995;24:7-12.
 42. Bessette PR, Cooley PA, Johnson RP, Czarnecki DJ. Gadolinium-enhanced MRI of pigmented villonodular synovitis of the knee. *J Comput Assist Tomogr* 1992;16:992-4.
 43. Araki Y, Tanaka H, Yamamoto H, et al. MR imaging of pigmented villonodular synovitis of the knee. *Radiat Med* 1994;12:11-5.
 44. Granowitz SP, Mankin HJ. Localized pigmented villonodular synovitis of the knee. Report of five cases. *J Bone Joint Surg (Am)* 1967;49:122-8.
 45. Flandry FC, Hughston JC, Jacobson KE, Barrack RL, McCann SB,

- Kurtz DM. Surgical treatment of diffuse pigmented villonodular synovitis of the knee. *Clin Orthop* 1994;300:183-92.
46. Zvijac JE, Lau AC, Hechtman KS, Uribe JW, Tjin ATE. Arthroscopic treatment of pigmented villonodular synovitis of the knee. *Arthroscopy* 1999;15:613-7.
47. Sim FH. Synovial proliferative disorders: role of synovectomy. *Arthroscopy* 1985;1:198-204.
48. Hamlin BR, Duffy GP, Trousdale RT, Morrey BF. Total knee arthroplasty in patients who have pigmented villonodular synovitis. *J Bone Joint Surg Am* 1998;80:76-82.
49. Van Emelen K, Moens P, Wouters K, Fabry G. Villonodular synovitis of the knee in a 5-year-old child. *Rev Chir Orthop Reparatrice Appar Mot* 1999;85:621-6.
50. O'Sullivan MM, Yates DB, Pritchard MH. Yttrium 90 synovectomy — a new treatment for pigmented villonodular synovitis [letter]. *Br J Rheumatol* 1987;26:71-2.
51. Wiss DA. Recurrent villonodular synovitis of the knee. Successful treatment with yttrium-90. *Clin Orthop* 1982;169:139-44.
52. Zullig R, Gross D, Frank T, Ruttimann A. Results of intraarticular treatment with yttrium-90 of persistent knee effusions. *Schweiz Rundsch Med Prax* 1979;68:1118-22.
53. Franssen MJ, Boerbooms AM, Karthaus RP, Buijs WC, van de Putte LB. Treatment of pigmented villonodular synovitis of the knee with yttrium-90 silicate: prospective evaluations by arthroscopy, histology, and ^{99m}Tc pertechnetate uptake measurements. *Ann Rheum Dis* 1989;48:1007-13.
54. Gumpel JM, Shawe DJ. Diffuse pigmented villonodular synovitis: non-surgical management. *Ann Rheum Dis* 1991;50:531-3.