

# Thoracic Syndesmophytes Commonly Occur in the Absence of Lumbar Syndesmophytes in Ankylosing Spondylitis: A Computed Tomography Study

Sovira Tan, Lawrence Yao, and Michael M. Ward

**ABSTRACT. Objective.** To determine the extent of thoracic involvement with syndesmophytes in ankylosing spondylitis (AS) relative to lumbar involvement.

**Methods.** We performed thoracolumbar spine computed tomography (CT) and lumbar radiography on 18 patients. We quantitated syndesmophytes in 11 intervertebral disc spaces and related these to the presence of syndesmophytes on lumbar radiographs.

**Results.** Syndesmophytes were slightly more common in the thoracic than in the lumbar spine and bridging was significantly more common. Thoracic syndesmophytes were universally present in patients without visible lumbar syndesmophytes on either radiographs or CT.

**Conclusion.** Syndesmophytes predominate in the thoracic spine. Lumbar radiographs underestimate the degree of thoracic involvement. (J Rheumatol First Release October 1 2017; doi:10.3899/jrheum.170340)

*Key Indexing Terms:*

ANKYLOSING SPONDYLITIS      SYNDESMOPHYTE      COMPUTED TOMOGRAPHY

Syndesmophytes, bony structures forming at the annulus fibrosis in many patients with ankylosing spondylitis (AS), constitute irreversible spinal damage<sup>1</sup>. Syndesmophytes are usually studied using plain radiographs. The current standard for radiographic assessment, the modified Stoke Ankylosing Spondylitis Spine Score (mSASSS), only scores the cervical and lumbar spine<sup>2</sup>. The thoracic spine has been excluded because of poor visualization as a result of overlying ribs and lungs, small disc spaces, and the higher dose of radiation needed for imaging. Consequently, the involvement of the thoracic spine with syndesmophytes has not been widely studied. If syndesmophytes differentially develop in the thoracic spine, exclusion of this large region may affect the validity of spinal fusion biomarker studies.

We initiated the investigation of syndesmophytes using computed tomography (CT)<sup>3</sup>. CT provides excellent visualization of both the thoracic and lumbar vertebrae, thereby providing a unique opportunity to investigate the presence of syndesmophytes in both regions. Its 3-D imaging allows

detection of syndesmophytes along the entire vertebral rim. We investigated the presence of syndesmophytes in the thoracic spine using CT, and examined the concordance between thoracic and lumbar syndesmophytes, with the aim of determining whether lumbar involvement, as seen on CT or radiographs, was representative of spinal damage in the thoracic spine.

## MATERIALS AND METHODS

**Patients.** We included patients age  $\geq 18$  years who met the modified New York criteria for AS<sup>4</sup>. For this cross-sectional study, we enrolled a convenience sample of patients who did not have complete lumbar fusion on radiographs. Our study protocol was approved by the US National Institute of Diabetes and Digestive and Kidney Diseases/National Institute of Arthritis and Musculoskeletal and Skin Diseases Institutional Review Board (04-AR-0205). All patients provided written informed consent.

**CT scanning and image analysis.** Patients were scanned using either a Siemens Somatom Flash or Force scanner (slice thickness 1.0 mm). Voltage was set at 120 kVp and reference mAs at 190. The estimated equivalent absorbed radiation dose was 8.01 mSv. The scans provided 11 intervertebral disc spaces (IDS) for analysis (T5–T6 to L3–L4).

We computed syndesmophyte height in each IDS using a validated algorithm<sup>5,6</sup>. The algorithm detects syndesmophytes as any voxels of bone density extending from the vertebral rim and lying between the planes of the 2 vertebral endplates. Maximal syndesmophyte height was measured in 72 angular sectors of 5° each along the circumference of the vertebral rim. We divided these height measurements by the local height of the IDS so that bridging had a value of 1.0; values between 0 and 1.0 represented the proportion of the IDS spanned by a syndesmophyte, and 0 represented no syndesmophyte. We summed the 72 measurements over 360° to provide 1 circumferential measure of syndesmophyte height per IDS. We also computed the circumferential extent of bridging in an IDS as the sum of angular sectors with a score of 1.0, with a value of 360 representing complete fusion.

**Radiography.** Two readers (LY and MMW) independently scored the

---

From the Intramural Research Program, US National Institute of Arthritis and Musculoskeletal and Skin Diseases (NIAMS), National Institutes of Health (NIH); Radiology and Imaging Sciences, Clinical Center, NIH, Bethesda, Maryland, USA.

Supported by the Intramural Research Program, NIAMS, NIH (grant number ZIA-AR-041153); and by the NIH Clinical Center.

S. Tan, PhD, Intramural Research Program, NIAMS, NIH; L. Yao, MD, Radiology and Imaging Sciences, Clinical Center, NIH; M.M. Ward, MD, MPH, Intramural Research Program, NIAMS, NIH.

Address correspondence to Sovira Tan, NIAMS, Building 10, CRC, Room 4-1350, Bethesda, Maryland 20892, USA. E-mail: [tanso@mail.nih.gov](mailto:tanso@mail.nih.gov)

Accepted for publication June 15, 2017.

---

Personal non-commercial use only. The Journal of Rheumatology Copyright © 2017. All rights reserved.

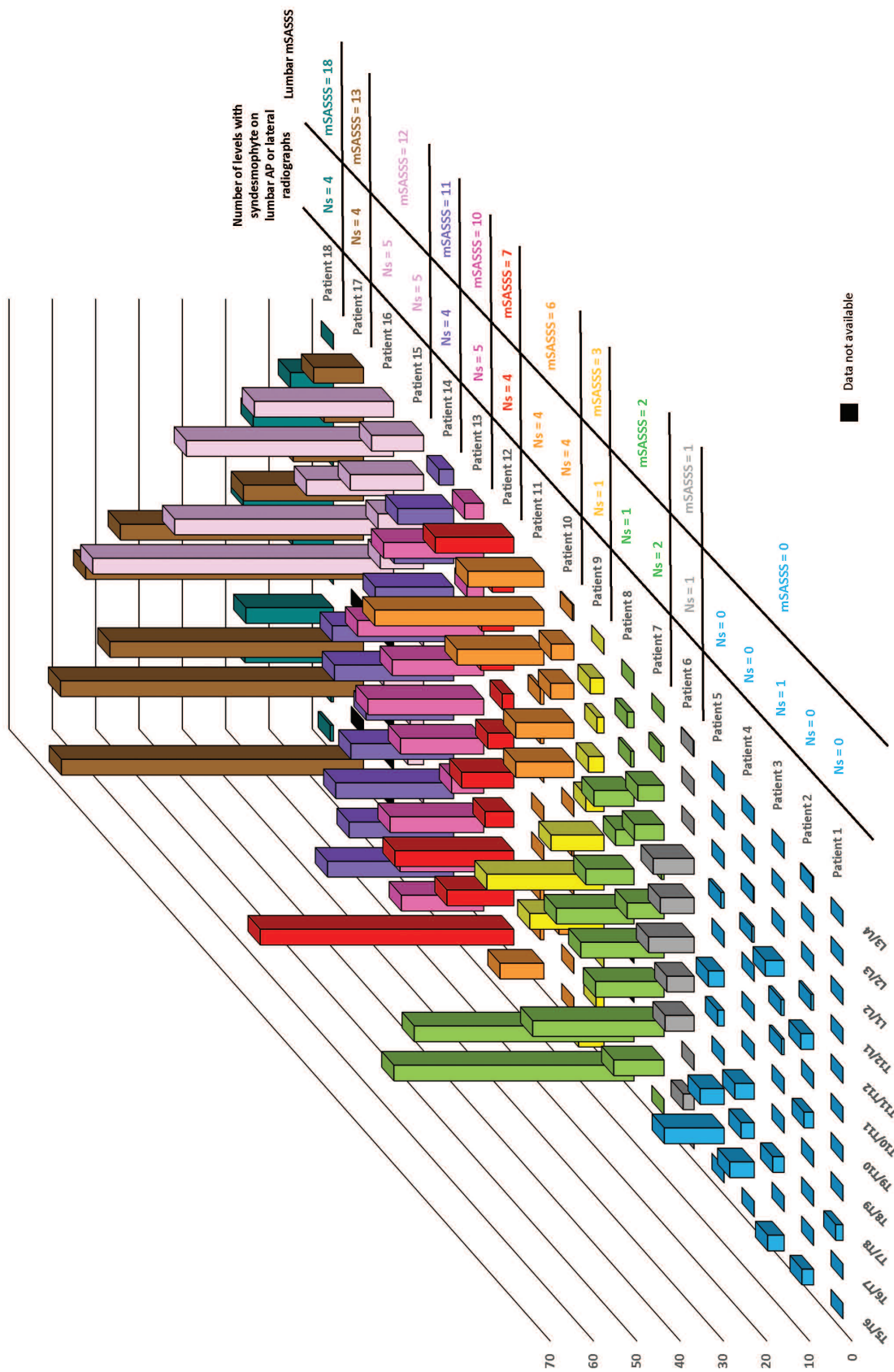


Figure 1. Relationship between lumbar syndesmophytes and thoracic syndesmophytes by individual patient. Patients are ordered by ascending mSASSS scores. Vertical axis represents circumferential syndesmophyte height. Maximal syndesmophyte height was measured in 72 angular sectors of 5° each along the circumference of the vertebral rim and normalized by the local disc height so that bridging had a value of 1.0. The 72 measurements were then summed to provide the circumferential height (possible range 0-7; 72 indicating complete fusion). T12-L1 was considered a lumbar level. mSASSS: modified Stoke Ankylosing Spondylitis Spine Score; AP: anterior-posterior.

anterior-posterior and lateral radiographs of the lumbar spine for the presence or absence of syndesmophytes and bridging for each IDS from T12–L1 to L5–S1. They also scored the lumbar mSASSS. Readings were compared and any differences in scores were resolved by joint readings. Readings were done without knowledge of the CT results.

**Statistical analysis.** For each IDS, we recorded the percentage of patients with any syndesmophyte, mean circumferential syndesmophyte height, percentage of patients with bridging, and mean radial extent of bridging. We tested for within-patient linear trends in the percentage of IDS with syndesmophytes or bridging by descending vertebral level (from T5–T6 to L3–L4) using logistic regression analyses. Similarly, we used linear regression to examine within-patient linear trends in the continuous measures (mean circumferential syndesmophyte height and mean radial extent of bridging) by descending vertebral level. We implemented these analyses with generalized estimating equations to account for clustering by patient.

We next investigated the relationship between lumbar and thoracic syndesmophytes by plotting the syndesmophyte circumferential height at all levels for all patients, ordered by mSASSS. To study the relationship between thoracic CT involvement and lumbar radiographic involvement, we grouped patients by the number of lumbar levels with syndesmophytes/bridging on either lateral or anterior-posterior radiographs and computed the percentage of thoracic levels with syndesmophytes/bridging on CT scans in each group.

## RESULTS

We enrolled 18 patients (16 men). Their mean (SD) age was 44.0 (11.6) years, and mean duration of AS was 19.4 (8.8) years. Eleven were treated with tumor necrosis factor inhibitors. The median lumbar mSASSS (possible range 0–36) was 4.5 (25th, 75th percentile 0, 11). Ten IDS (out of 198) could not be processed by the CT algorithm due to extensive discitis.

Syndesmophytes were very common in the thoracic spine. Supplementary Figure 1 (available from the authors on request) shows multiple thoracic syndesmophytes on the CT scan of a patient with lumbar mSASSS of 2. The percentage of IDS with any syndesmophyte ranged from 56% to 89%, peaked at the thoracolumbar junction, and was slightly higher

in the thoracic than the lumbar spine (Table 1). The mean circumferential syndesmophyte height was somewhat larger in the more superior levels than the inferior levels ( $p_{\text{trend}} = 0.08$ ). The presence and extent of bridging were both significantly greater in the more superior thoracic levels than in the lumbar levels.

Within individual patients, syndesmophytes by CT were either more common in or equally present in thoracic IDS compared to lumbar IDS (Figure 1). Patients with extensive syndesmophytes at multiple lumbar IDS typically had extensive thoracic syndesmophytes (patients 12–18 in Figure 1). Only 1 patient (Patient 11) had lumbar-predominant involvement. However, patients with no or very few lumbar IDS with syndesmophytes by CT (patients 1–9) also commonly had thoracic syndesmophytes, which in some cases were quite extensive (patients 7–9). Patients without syndesmophytes in L1–L2 to L3–L4 (patients 1–6) each had thoracic syndesmophytes, often in more than 1 IDS. Compared to readings of lumbar radiographs, all patients with extensive lumbar syndesmophytes also had extensive thoracic involvement on CT, but all patients with a lumbar mSASSS of 0 also had thoracic syndesmophytes. There was a modest positive correlation between thoracic circumferential heights and lumbar mSASSS, attributable in part to the scores of 2 patients (Supplementary Figure 2, available from the authors on request).

When grouped by the number of lumbar levels with syndesmophytes on radiographs, patients with syndesmophytes in at least 1 lumbar IDS had syndesmophytes in the majority of thoracic IDS (Table 2). Patients with no lumbar syndesmophytes had syndesmophytes in 39% of thoracic IDS, on average, and bridging in some thoracic IDS. Findings were similar when we considered bridging only. Thoracic bridging was present in 36% of IDS among patients without lumbar bridging.

Table 1. Degree of syndesmophyte involvement in 11 thoracic and lumbar vertebral levels.

	Percentage of Patients with Any Syndesmophytes*	Mean (SD) Circumferential Height	Percentage of Patients with Any Bridging*	Mean (SD) Extent of Bridging
T5–T6	65 (11/17)	15.1 (23.5)	53 (9/17)	72.3 (166.0)
T6–T7	69 (11/16)	9.1 (13.6)	50 (8/16)	39.7 (68.7)
T7–T8	81 (13/16)	13.6 (18.8)	50 (8/16)	60.6 (96.2)
T8–T9	62 (10/16)	10.2 (15.1)	50 (8/16)	44.1 (73.0)
T9–T10	69 (11/16)	8.4 (9.4)	50 (8/16)	33.1 (41.1)
T10–T11	65 (11/17)	10.6 (16.3)	47 (8/17)	39.1 (78.0)
T11–T12	83 (15/18)	13.4 (19.9)	33 (6/18)	49.7 (98.3)
T12–L1	89 (16/18)	10.7 (13.3)	39 (7/18)	31.4 (60.8)
L1–L2	72 (13/18)	6.9 (7.6)	11 (2/18)	4.7 (14.0)
L2–L3	67 (12/18)	9.7 (14.0)	33 (6/18)	29.4 (56.7)
L3–L4	56 (10/18)	5.5 (9.1)	17 (3/18)	5.5 (14.3)
$P_{\text{trend}}$	0.69	0.08	0.0001	0.02

\*Some vertebral levels had fewer than 18 values because a few IDS could not be processed by the CT algorithm due to extensive discitis (Andersson lesions). CT: computed tomography; IDS: intervertebral disc spaces.

Table 2. Relationship between syndesmophytes/bridging on lumbar radiographs and syndesmophytes/bridging on thoracic computed tomography.

No. Lumbar Levels with Syndesmophytes on Radiographs	No. Patients	Mean Percentage of Thoracic Levels with Syndesmophytes on CT	Mean Percentage of Thoracic Levels with Bridging on CT
0	4	39	11
1	4	79	59
2	1	86	71
3	0	N/A	N/A
4	4	81	59
5	3	90	71

No. Lumbar Levels with Bridging on Radiographs	No. Patients	Mean Percentage of Thoracic Levels with Syndesmophytes on CT	Mean Percentage of Thoracic Levels with Bridging on CT
0	9	62	36
1	5	74	53
2	2	100	86
3	1	86	57
4	1	100	100
5	0	N/A	N/A

CT: computed tomography; N/A: not applicable.

## DISCUSSION

In our study of thoracic syndesmophytes using CT, we found that syndesmophytes were commonly present in the thoracic spine, and bridging was significantly more common in mid-thoracic than lumbar levels. Thoracic syndesmophytes were often present irrespective of lumbar syndesmophytes. Importantly, if syndesmophytes were observed on a lumbar radiograph, one could expect there to be syndesmophytes in the thoracic spine, but not the converse. Several patients with normal lumbar radiographs had substantial thoracic syndesmophytes. Previous studies using either radiographs or magnetic resonance imaging reported syndesmophytes to be more or equally common in the thoracic compared to the lumbar spine<sup>7,8,9,10,11</sup>. Our study extends these findings by examining thoracic involvement in relation to the degree of lumbar involvement, rather than considering each region independently.

Because of its 2-dimensional character, the sensitivity of syndesmophyte detection on radiographs is low relative to CT<sup>3</sup>. This could explain why in our study, the presence of any syndesmophyte on lumbar radiographs was associated with syndesmophytes in the thoracic CT scans. By the time syndesmophytes are detectable on lumbar radiographs, structural damage may already have occurred in large portions of the thoracolumbar spine.

Patients with the least syndesmophyte involvement had more thoracic than lumbar syndesmophytes, suggesting that syndesmophytes were more likely to develop in the thoracic spine first. However, T11–L2 was the most affected level. Bridging was more common in the mid-thoracic levels, which might be due to longer chronicity, less movement

there, or because disc heights are smaller there. Longitudinal studies of patients in an earlier stage of AS are needed to definitively determine which spine region is typically involved first. The clinical consequences of isolated thoracic syndesmophytes are unclear.

Improvements in CT technology permitted more extensive spine coverage at an equal effective dose, and without definite compromises in scan quality<sup>12</sup>. We did not scan the cervical spine. Our method is a research tool and not intended for use in clinical practice. Our study suggests that the thoracic spine is commonly affected by syndesmophytes. We also found that most patients with minimal radiographic involvement in the lumbar spine had extensive thoracic involvement. This finding indicates that lumbar radiographs cannot be used to infer the degree of syndesmophyte involvement in other spinal regions. Most often, lumbar radiographic readings underestimate the degree of syndesmophyte involvement in the thoracic spine. This discordance may confound studies of biomarkers of spinal fusion that use plain radiographs to evaluate spinal damage.

## REFERENCES

1. Braun J, Sieper J. Ankylosing spondylitis. *Lancet* 2007;369:1379-90.
2. Wanders AJ, Landewé RB, Spoorenberg A, Dougados M, van der Linden S, Mielants H, et al. What is the most appropriate radiologic scoring method for ankylosing spondylitis? A comparison of the available methods based on the outcome measures in rheumatology clinical trials filter. *Arthritis Rheum* 2004;50:2622-32.
3. Tan S, Yao J, Flynn JA, Yao L, Ward MM. Quantitative measurement of syndesmophyte volume and height in ankylosing spondylitis using CT. *Ann Rheum Dis* 2014;73:544-50.
4. van der Linden S, Valkenburg HA, Cats A. Evaluation of diagnostic criteria for ankylosing spondylitis. A proposal for

- modification of the New York criteria. *Arthritis Rheum* 1984;27:361-8.
5. Tan S, Yao J, Yao L, Ward MM. Improved precision of syndesmophyte measurement for the evaluation of ankylosing spondylitis using CT: a phantom and patient study. *Phys Med Biol* 2012;57:4683-704.
  6. Tan S, Yao J, Flynn JA, Yao L, Ward MM. Quantitation of circumferential syndesmophyte height along the vertebral rim in ankylosing spondylitis using computed tomography. *J Rheumatol* 2015;42:472-8.
  7. Spencer DG, Park WM, Dick HM, Papazoglou SN, Buchanan WW. Radiological manifestations in 200 patients with ankylosing spondylitis: correlation with clinical features and HLA B27. *J Rheumatol* 1979;6:305-15.
  8. Helliwell PS, Hickling P, Wright V. Do the radiological changes of classic ankylosing spondylitis differ from the changes found in the spondylitis associated with inflammatory bowel disease, psoriasis, and reactive arthritis? *Ann Rheum Dis* 1998;135-40.
  9. Braun J, Baraliakos X, Golder W, Hermann KG, Listing J, Brandt J, et al. Analysing chronic spinal changes in ankylosing spondylitis: a systematic comparison of conventional x-rays with magnetic resonance imaging using established and new scoring systems. *Ann Rheum Dis* 2004;63:1046-55.
  10. Baraliakos X, Listing J, Rudwaleit M, Sieper J, Braun J. Development of a radiographic scoring tool for ankylosing spondylitis only based on bone formation: addition of the thoracic spine improves sensitivity to change. *Arthritis Rheum* 2009; 61:764-71.
  11. Geusens P, De Winter L, Quaden D, Vanhoof J, Vosse D, van den Berghet J, et al. The prevalence of vertebral fractures in spondyloarthritis: relation to disease characteristics, bone mineral density, syndesmophytes and history of back pain and trauma. *Arthritis Res Ther* 2015;17:294.
  12. Kalra MK, Woisetschlager M, Dahlstrom N, Singh S, Lindblom M, Choy G, et al. Radiation dose reduction with sinogram affirmed iterative reconstruction technique for abdominal computed tomography. *J Comput Assist Tomogr* 2012;36:339-46.