

# Chronic Nonbacterial Osteomyelitis: Pathophysiological Concepts and Current Treatment Strategies

Sigrun R. Hofmann, Anja Schnabel, Angela Rösen-Wolff, Henner Morbach, Hermann J. Girschick, and Christian M. Hedrich

**ABSTRACT.** Chronic nonbacterial osteomyelitis (CNO) is an autoinflammatory bone disorder, covering a clinical spectrum with asymptomatic inflammation of single bones at the one end, and chronic recurrent multifocal osteomyelitis (CRMO) at the other end. The exact molecular pathophysiology of CNO remains largely unknown. Provided familial clusters and the association with inflammatory disorders of the skin and intestine suggest a genetic predisposition. Recently, profound dysregulation of cytokine responses was demonstrated in CRMO. Failure to produce antiinflammatory cytokines interleukin (IL)-10 and IL-19 contributes to activation of inflammasomes and subsequent IL-1 $\beta$  release. In IL-10-deficient and in CNO-prone chronic multifocal osteomyelitis mice, IL-1 $\beta$  was linked to bone inflammation. Further, alterations to the gut microbiome were suggested in contributing to IL-1 $\beta$  release from innate immune cells in mice, offering an interesting target in the search for molecular mechanisms in CNO. Here, we summarize clinical presentation and treatment options in CNO/CRMO, current pathophysiological concepts, available mouse models, and promising future scientific directions. (J Rheumatol First Release September 1 2016; doi:10.3899/jrheum.160256)

*Key Indexing Terms:*

CHRONIC NONBACTERIAL OSTEOMYELITIS                      TREATMENT                      CYTOKINE  
CHRONIC RECURRENT MULTIFOCAL OSTEOMYELITIS                      INFLAMMATION

Autoinflammatory disorders are characterized by seemingly unprovoked episodes of systemic inflammation in the absence of self-reactive T cells or high-titer autoantibodies<sup>1,2</sup>. Sterile bone inflammation occurs in a number of monogenic autoinflammatory syndromes, including pyogenic arthritis, pyoderma gangrenosum, and acne syndrome (PAPA); deficiency of interleukin (IL)-1 receptor antagonist (DIRA);

familial chronic multifocal osteomyelitis (Majeed syndrome); and in polygenic or multifactorial disorders, such as sporadic chronic nonbacterial (or noninfectious) osteomyelitis (CNO) and synovitis, acne, pustulosis, hyperostosis, and osteitis syndrome (SAPHO)<sup>3,4</sup>. Particularly in the adult age group, CNO is frequently associated with skin manifestations and/or occurs in the context of SAPHO<sup>5,6,7,8,9</sup>. Whether isolated CNO/chronic recurrent multifocal osteomyelitis (CRMO) and SAPHO are the same disease in different age groups remains to be determined. The aforementioned disorders have been included in the group of autoinflammatory bone disorders<sup>3,4,7</sup>.

*From the Pediatric Rheumatology and Immunology, Department of Pediatrics, Medizinische Fakultät Carl Gustav Carus, Technische Universität Dresden, Dresden; Department of Pediatrics, University of Würzburg; Children's Hospital, Vivantes Klinikum-Friedrichshain, Berlin, Germany.*

*S.R. Hofmann, MD, PhD, Pediatric Rheumatology and Immunology, Department of Pediatrics, Medizinische Fakultät Carl Gustav Carus, Technische Universität Dresden; A. Schnabel, MD, Pediatric Rheumatology and Immunology, Department of Pediatrics, Medizinische Fakultät Carl Gustav Carus, Technische Universität Dresden; A. Rösen-Wolff, MD, PhD, Pediatric Rheumatology and Immunology, Department of Pediatrics, Medizinische Fakultät Carl Gustav Carus, Technische Universität Dresden; H. Morbach, MD, PhD, Department of Pediatrics, University of Würzburg; H.J. Girschick, MD, PhD, Children's Hospital, Vivantes Klinikum-Friedrichshain; C.M. Hedrich, MD, PhD, Pediatric Rheumatology and Immunology, Department of Pediatrics, Medizinische Fakultät Carl Gustav Carus, Technische Universität Dresden.*

*Address correspondence to Dr. C.M. Hedrich, Pediatric Rheumatology and Immunology, Children's Hospital Dresden, Medizinische Fakultät Carl Gustav Carus, Technische Universität Dresden, Fetscherstr. 74, D-01307 Dresden, Germany. E-mail: Christian.hedrich@uniklinikum-dresden.de*  
*Accepted for publication July 20, 2016.*

CNO sometimes presents with mild clinical symptoms, which, in combination with lacking awareness by care providers, may lead to delayed diagnosis. Despite the lack of reliable epidemiologic data, CNO is likely to be the single most common autoinflammatory bone disorder. This is supported by a single-center study in our institution, suggesting that CNO is almost as common as infectious osteomyelitis<sup>10,11</sup> (Schnabel, *et al*, submitted).

CNO primarily affects children and adolescents, but can occur in all age groups. Disease onset before 2–3 years of age, however, is extremely uncommon and should prompt consideration of other monogenic autoinflammatory syndromes as differential diagnoses. Peak onset of CNO is between 7 years and 12 years of age with a slight female predominance<sup>3,5,6,7,12</sup>. The clinical presentation of CNO is

variable, with relatively benign, self-limiting episodes of monofocal bone lesions at the one end, and its most severe form, CRMO, at the other. The molecular pathophysiology of autoinflammatory bone disorders is complex and incompletely understood. To our current understanding, bone inflammation is the net result of impaired innate immune responses, resulting in disbalanced cytokine expression, osteoclast differentiation and activation, osteolysis, and bone remodeling<sup>3,4,5,6,7,12,13,14,15</sup>. Here, we discuss the clinical course, pathophysiology, and treatment options in CNO, and available animal models.

## MONOGENIC AUTOINFLAMMATORY BONE DISORDERS

*Familial CNO: Majeed syndrome.* Majeed syndrome is characterized by early-onset bone inflammation, Sweet syndrome-like skin rash, and dyserythropoietic anemia. Autosomal recessively inherited loss-of-function mutations in the *LPIN2* gene, encoding for the phosphatase lpin2, result in overactivation of Toll-like receptor (TLR)-4 pathways and systemic inflammation. Treatment is empiric and includes nonsteroidal antiinflammatory drugs (NSAID), corticosteroids, and IL-1–blocking strategies<sup>3,13,14,16,17,18,19,20,21</sup>.

*Inflammasome-associated monogenic disorders.* Inflammasomes are multiprotein complexes that mediate the cleavage and subsequent release of proinflammatory cytokines IL-1 $\beta$  and IL-18<sup>4,5,6,7</sup>.

DIRA is characterized by early-onset pustular rash, oral ulcers, rib widening with periosteal inflammation, multifocal osteolytic lesions, and heterotopic ossification. DIRA is caused by autosomal recessively inherited mutations in the *IL1RN* gene, encoding for the IL-1 receptor antagonist, a post-translational regulator of IL-1 signaling, resulting in uncontrolled proinflammatory cytokine and chemokine expression. Substitution with recombinant IL-1 receptor antagonist anakinra induces remission<sup>22,23,24</sup>.

PAPA syndrome is characterized by sterile erosive arthritis, cystic acne, and pyoderma gangrenosum-like ulcerative lesions<sup>25,26</sup>. Autosomal dominant mutations in the *PSTPIP1* gene, encoding for the pyrin-interacting protein CD2-binding protein 1, cause uncontrolled inflammasome activation and IL-1 $\beta$  release<sup>26,27</sup>. Treatment options include corticosteroids, thalidomide, cyclosporine, tacrolimus, and intravenous immunoglobulin. Data on biologic treatment are rare and inconsistent<sup>1,3,25,26,27</sup>.

More details about the pathophysiology of monogenic autoinflammatory bone disorders and treatment options are provided in Supplementary Data 1 (available online at [jrheum.org](http://jrheum.org)).

## SPORADIC CHRONIC NONBACTERIAL OSTEOMYELITIS (CNO)

In sporadic CNO, bone inflammation manifests later in life and is usually less severe when compared with monogenic

autoinflammatory syndromes. Most experience first symptoms in childhood or adolescence, with peak onset between 7 and 12 years of age. Medical histories of the patients and their families sometimes include inflammatory conditions, arthritis (in our cohort, up to 40% in patients with CNO), skin (in our CNO cohort, 10% acne and 5% palmoplantar pustulosis) or intestinal inflammatory disorders (in our cohort, 6% Crohn disease and 4% ulcerative colitis; Schnabel, *et al*, submitted)<sup>3,4,5,6,7,10,11,28,29</sup>.

*Clinical presentation and diagnosis.* In the absence of reliable and widely accepted diagnostic criteria or disease biomarkers, CNO remains a diagnosis of exclusion. The clinical presentation is variable with mild, sometimes self-limiting courses at one end of the spectrum and chronic remitting multifocal bone lesions at the other. Bone lesions cluster around the metaphysis of long bones. Bone lesions most commonly occur in the clavicle, humerus, vertebral column, pelvic region, femur, tibia, ankle, and the calcaneus. Of note, lesions can be asymptomatic, which appears to be the case particularly when vertebral bones are involved. Vertebral compression fractures can be the first symptom of CRMO and may result in growth impairment, gibbus formation, or neurological symptoms. Thus, wherever available, whole-body magnetic resonance imaging (WB-MRI) should be performed in all patients with suspected CNO/CRMO to exclude “silent” bone inflammation, especially in the vertebral column<sup>3,4,5,6,7,28</sup>. Alternatively, a series of MRI scans covering all or most of the body, and bone scintigraphy (if MRI is not available) may be performed. Conventional radiographs may provide information on osseous damage and sclerosis, but are not suitable for the assessment of inflammatory activity or the search for clinically silent inflammatory lesions.

Because the molecular pathophysiology of CNO remains largely unknown and positive predictive tests are lacking, CNO/CRMO remains a diagnosis of exclusion<sup>11</sup>. Jansson, *et al* developed a clinical score to distinguish patients with CNO from individuals with bacterial osteomyelitis, benign or malignant bone tumors based on clinical and laboratory findings, and the distribution of radiographic bone lesions<sup>11</sup>. However, the clinical score was not designed and has not yet been evaluated for mycobacterial bone infections, Langerhans cell histiocytosis, lymphoma, leukemia (particularly acute lymphoblastic leukemia), metabolic disorders (hypophosphatasia), and other autoinflammatory bone disorders. Thus, in unclear cases, and prior to treatment with systemic steroids (see below), bone biopsies should be considered to rule out alternative underlying disorders<sup>3,4,5,6,7,28</sup>.

Biomarkers for the diagnosis or monitoring of clinical activity of CNO/CRMO are lacking. “Classical” inflammation markers, such as C-reactive protein and erythrocyte sedimentation rate (ESR), are not disease-specific. Further, in most patients with CNO/CRMO, they are only mildly elevated, but can remain within normal limits. Thus,

biomarker studies in large cohorts of patients with CNO and control populations are urgently needed. Recently, we identified a set of 9 serum inflammation markers that allow discrimination among patients with CRMO, patients with Crohn disease, and healthy individuals (Eotaxin, IL-12, IL-1RA, sIL-2R, IL-6, MCP-1, MIG, MIP-1b, and RANTES). This serum protein array may prove useful for future diagnostic approaches, but remains to be tested in larger multiethnic cohorts and patients with additional inflammatory disorders<sup>30</sup>.

**Pathophysiology.** The pathophysiology of CNO is incompletely understood. Familial clusters of CNO, the relatively high prevalence of additional inflammatory manifestations, including psoriatic skin lesions and inflammatory bowel disease in conjunction with the accumulation of inflammatory disorders in first-degree relatives, suggest a genetic component to sporadic CNO<sup>3,4,5,6,7,28</sup>. For a majority of patients with CNO/CRMO (those with sporadic CNO/CRMO), genetic causes, exact immunological contributors, and/or environmental triggers are unknown. A potential genetic association was reported for a region on chromosome 18q21.3-22<sup>31</sup>, but has not been confirmed by other groups. Mutations in genes associated with inflammatory bone loss in other conditions, including *PSTPIP1* (PAPA syndrome), *CARD15/NOD2* (Crohn disease, Blau syndrome), and *IL1RN* (DIRA), have been excluded in small cohorts of patients with CNO/CRMO. Taken together, no reported single gene variant can explain disease expression in CNO/CRMO<sup>5,6,23,32,33</sup>.

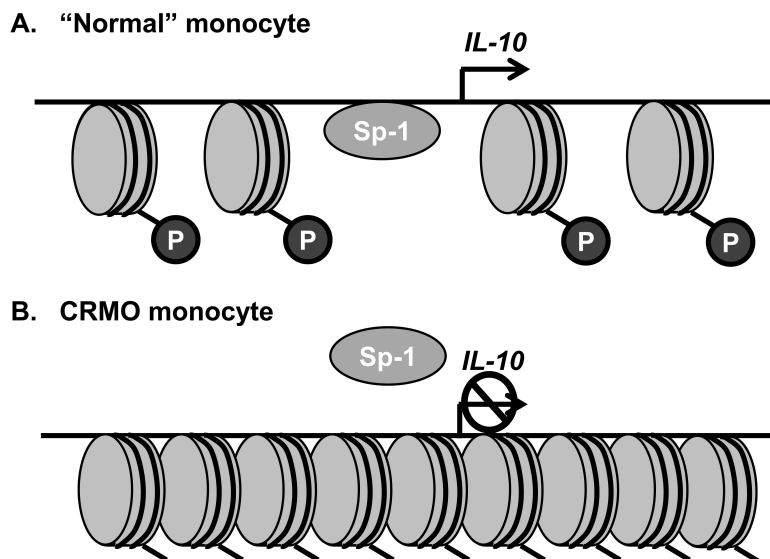
Because CNO-associated inflammatory disorders [including Crohn disease, psoriasis (PsO), acne, etc.] are characterized by an imbalance between pro- and antiinflammatory cytokine expression, we asked whether the immune-regulatory cytokine IL-10 may be involved in the pathophysiology of CNO/CRMO. We determined an enrichment of *IL-10* promoter polymorphisms in patients with CNO/CRMO that, to our initial surprise, encode for “high” levels of the immune-regulatory cytokine IL-10 expression<sup>15,34,35,36</sup>. This was in contrast to our finding of reduced IL-10 mRNA and protein expression by resting and TLR-4 agonist lipopolysaccharide (LPS)-stimulated monocytes from patients with CRMO when compared with controls or patients with juvenile idiopathic arthritis. Because the failure to express IL-10 was not explained by *IL-10* promoter haplotypes, we investigated TLR-4 signaling pathways and the epigenetic regulation of *IL-10* in monocytes from patients with CRMO<sup>15,35,36</sup>. We demonstrated that mitogen-activated protein kinases (MAPK), extracellular signal-regulated kinase (ERK) 1 and ERK2, fail to be activated in CRMO monocytes. This resulted in (1) reduced nuclear shuttling of the transcription factor signaling protein (Sp)-1 and (2) impaired epigenetic remodeling of the *IL-10* promoter (histone H3 phosphorylation at serine residue 10, H3S10p; Figure 1; Supplementary Figure 1, available online at [jrheum.org](http://jrheum.org))<sup>14,15</sup>. This impairment results in reduced IL-10

expression in monocytes from patients with CNO/CRMO.

*IL-10*, together with its homologues *IL-19* and *IL-20*, is organized in the so-called *IL-10* cytokine cluster on chromosome 1q32. IL-19 mostly exerts immune-regulatory functions, while IL-20 acts as a proinflammatory cytokine. In monocytes from healthy individuals, IL-10 family members IL-10, IL-19, and IL-20 are coregulated<sup>35,36</sup>. We demonstrated that, as for IL-10, failure to activate Sp-1 together with lack of epigenetic remodeling (H3S10p) in monocytes from patients with CRMO also contributes to reduced IL-19 expression. Of note, expression of the IL-10 homologue IL-20 was not impaired. Conversely, IL-20 expression was enhanced in monocytes from patients with CRMO in response to stimulation with LPS. Enhanced IL-20 expression is most likely secondary to insufficient inhibition by IL-10. Additionally, the *IL-20* gene was methylated to a lower degree in monocytes from patients with CRMO when compared with controls. Because DNA methylation is a potent mechanism silencing gene expression, IL-20 expression in CRMO monocytes may be favored by reduced DNA methylation<sup>37</sup>.

Interestingly, the MAPK-dependent expression of proinflammatory cytokines tumor necrosis factor- $\alpha$  (TNF- $\alpha$ ) and IL-6 was not impaired in monocytes from patients with CRMO. This may be explained by the observation that Jun kinases (JNK) and p38 MAPK pathways are not impaired in CNO/CRMO, resulting in an imbalance between pro- and antiinflammatory cytokines<sup>14,15</sup>. Previous reports indicate diametric effects of TNF- $\alpha$ , IL-6, and IL-20 on the one hand and IL-10 on the other on the interaction between the receptor activator of nuclear factor- $\kappa$ B (RANK) and its ligand (RANKL). This may be of central interest for the molecular pathophysiology of CRMO, because activated RANK:RANKL pathways contribute to osteoclast differentiation and activation, which may subsequently result in inflammatory bone loss in CNO/CRMO<sup>3,38,39,40,41</sup>.

Scianaro, *et al* showed evidence suggesting increased activation of the NLRP3 inflammasome contributing to the proinflammatory phenotype in CNO/CRMO<sup>42</sup>. The study demonstrated increased mRNA expression of inflammasome components ASC, NLRP3, and caspase-1, as well as increased transcription and protein release of IL-1 $\beta$  from cultured peripheral blood mononuclear cells from patients with active CRMO as compared with patients with inactive disease or controls. Further, applying immunohistochemistry, tissue protein expression of ASC, NLRP3, caspase-1, IL-1 $\beta$ , and IL-6 in bone biopsies from patients with CRMO was established. In a recent study (Schnabel, *et al*, submitted), we confirmed findings<sup>37,42</sup> on inflammasome-associated gene expression in immune cells from patients with CRMO and linked impaired IL-10 and IL-19 expression with increased IL-1 $\beta$  mRNA expression, and proteolytic cleavage and secretion of IL-1 $\beta$  protein. Enhanced inflammasome activity in monocytes from



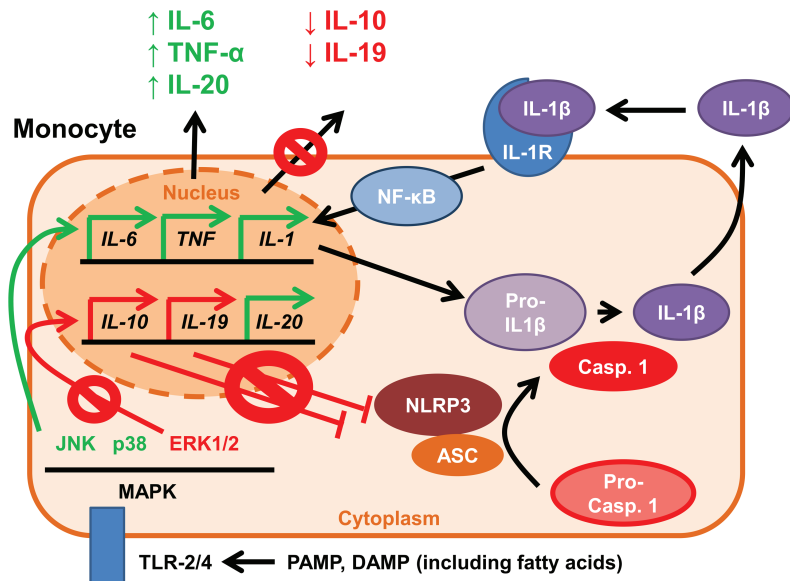
**Figure 1.** Disturbed epigenetic remodeling and transcription factor binding to the *IL-10* gene in monocytes from patients with CRMO. A. *IL-10* expression is regulated by epigenetic mechanisms, including DNA methylation and histone modifications. Phosphorylation of histone H3 at serine residue 10 (P) mediates epigenetic opening of the *IL-10* gene, allowing for transcription factor binding, including the recruitment of Sp-1. B. In monocytes from patients with CRMO, histone H3 fails to be phosphorylated, resulting in impaired “opening” of the locus, altered Sp-1 recruitment, and subsequently reduced *IL-10* expression. *IL-10*: interleukin 10; CRMO: chronic recurrent multifocal osteomyelitis; Sp-1: signaling protein-1.

patients with CRMO was reversed by the addition of recombinant *IL-10* or *IL-19*, indicating that reduced MAPK activation and the resulting failure to express *IL-10* and *IL-19* may contribute to increased inflammasome activation and inflammatory bone loss in CRMO<sup>37</sup> (Figure 2).

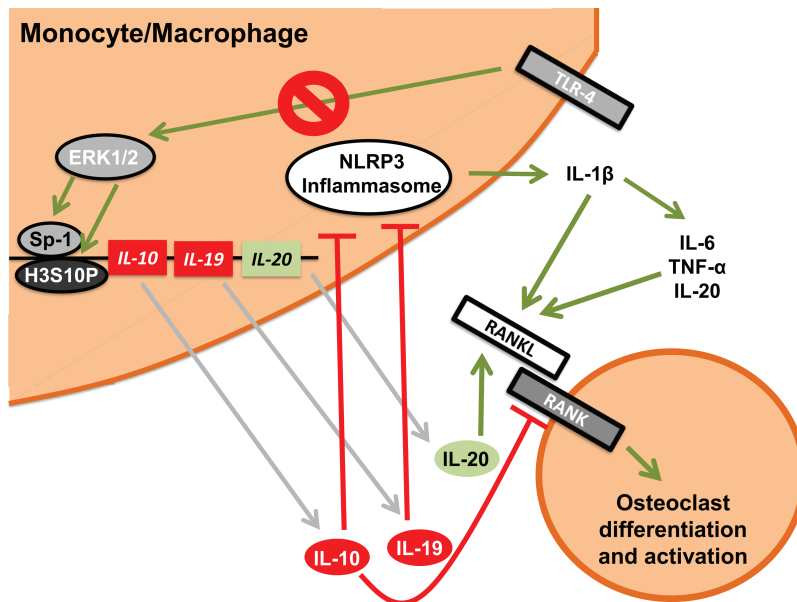
The observation that cellular infiltrates in bone biopsies from patients with CNO/CRMO change from innate immune cells (monocytes, macrophages, and neutrophils) to leukocytes and plasma cells suggests interplay between innate and adaptive immune mechanisms during the disease course. Variable cellular infiltrates during the disease course are a hallmark of several inflammatory diseases, including the CNO-associated disorder PsO. In PsO, innate and adaptive immune cell infiltrates alternate, coexist, and influence one another, driving disease expression and activity<sup>43,44,45,46,47</sup>. It appears likely that also in CNO/CRMO, cellular infiltrates reflect the immunological reaction, providing another model disease for the interplay between innate and adaptive immune responses<sup>46,47</sup>. Unfortunately, very little is known about the kinetics of innate and adaptive inflammatory responses in CNO/CRMO. The available reports are very preliminary, but promise the potential for future targeted treatment depending on the involvement of innate versus adaptive immune cells, and local expression of specific cytokines and chemokines<sup>6,46,47</sup>.

**Treatment and monitoring.** Despite a growing body of literature, debates continue over therapeutic strategies (beyond NSAID treatment), measurement of disease activity,

treatment goal definition, and outcome measures. In the absence of scientific evidence (such as prospective studies) or widely accepted consensus treatment plans, treatment of CNO/CRMO remains empirical. The assessment of disease activity, which provides the basis for conscious treatment decisions, remains somewhat unclear. Beck, *et al* provided the Pediatric CNO (PedCNO) score, which includes 5 measures: ESR, number of radiological lesions, severity of disease estimated by the physician, severity of disease estimated by the patient or parent, and the Childhood Health Assessment Questionnaire<sup>48</sup>. In a study, a set of disease biomarkers was shown to correlate with the PedCNO score, but remain to be confirmed in larger unrelated populations<sup>30</sup>. Frequently, radiographic signs of activity (such as bone edema and/or contrast enhancement on MRI) and structural damage with or without signs of inflammatory activity are used to make treatment decisions. The term “structural damage” in the context of CNO/CRMO, however, is not well defined and includes bone sclerosis and (mostly vertebral) fractures. Further, the time to followup radiographic imaging remains undetermined. From personal conversations and reports in the literature, most experienced institutions perform followup MRI scans (usually regional MRI in cases with initially monofocal disease and no new symptoms, and WB-MRI in CRMO) after 6 to 9 months in most cases, then once per year as long as patients require treatment<sup>3,5,6,48</sup>.



**Figure 2.** Unbalanced MAPK activation in monocytes from patients with CRMO results in altered cytokine expression and secretion. In monocytes from patients with CRMO, MAPK ERK1 and ERK2 fail to be activated in response to TLR activation. As a result, antiinflammatory cytokines IL-10 and IL-19 fail to be expressed. JNK and p38 MAPK undergo unaltered activation, which results in proinflammatory cytokine expression (IL-1 $\beta$ , IL-6, TNF- $\alpha$ , and IL-20). Reduced expression of immune modulatory cytokines IL-10 and IL-19 results in increased inflammasome activation and increased IL-1 $\beta$  expression and release. MAPK: mitogen-activated protein kinases; CRMO: chronic recurrent multifocal osteomyelitis; ERK1: extracellular signal-regulated kinase-1; TLR: Toll-like receptor; IL-10: interleukin 10; JNK: Jun kinases; TNF- $\alpha$ : tumor necrosis factor- $\alpha$ ; NF- $\kappa$ B: nuclear factor- $\kappa$ B; Casp. 1: caspase-1; PAMP: pathogen-associated molecular patterns; DAMP: danger-associated molecular patterns.



**Figure 3.** Current understanding of altered intra- and extracellular signaling networks in CRMO. Through the aforementioned molecular mechanisms, IL-10-related cytokines IL-10, IL-19 (both immune modulating), and IL-20 (proinflammatory) are dysregulated in monocytes from patients with CRMO. Proinflammatory cytokines IL-1 $\beta$ , IL-6, IL-20, and TNF- $\alpha$  increase interactions between RANK and RANKL on osteoclast precursor cells, mediating osteoclast differentiation and activation, thus potentially contributing to bone inflammation in CRMO. CRMO: chronic recurrent multifocal osteomyelitis; IL-10: interleukin 10; TNF- $\alpha$ : tumor necrosis factor- $\alpha$ ; RANK: receptor activator of nuclear factor- $\kappa$ B; RANKL: RANK ligand; ERK1: extracellular signal-regulated kinase-1; Sp-1: signaling protein-1; TLR-4: Toll-like receptor-4.

First-line treatment of CNO/CRMO is typically NSAID. Studies indicate that NSAID are effective in about two-thirds of patients with CNO/CRMO. However, NSAID appear to be more efficient in patients with limited disease (CNO) when compared with individuals with CRMO<sup>48</sup>. Further, a retrospective analysis in our cohort of patients with CRMO suggests that NSAID may induce longterm improvement of inflammatory activity and symptoms, but may not be sufficient for longterm remission in the majority of patients (6 mos: 54%, 12 mos: 60%, 24 mos: 50%; Schnabel, *et al*, submitted). Thus, NSAID should be considered the gold standard and first choice treatment option in all patients with CNO/CRMO and no structural damage, with the option to escalate treatment in patients who relapse or do not reach complete remission. Patients with “mild” vertebral involvement, defined as bone edema without structural damage, can start treatment with NSAID, but require close clinical monitoring and radiographic followup (usually MRI after 4–6 weeks).

In individuals who fail to reach clinical and radiographic remission in response to NSAID treatment, oral corticosteroids may be administered. Usually, we treat patients with 1–2 mg/kg/day prednisolone (PSL; maximum 60 mg/day) over 5–10 days to induce clinical improvement and support NSAID treatment. In patients with CNO who first respond and then relapse shortly after the discontinuation of PSL or in individuals receiving oral corticosteroids as a bridging agent during the initiation of disease-modifying antirheumatic drug (DMARD) therapy, longer low-dose corticosteroid treatment is considered (usually 0.1–0.2 mg/kg/day for 4–6 weeks).

Given the aforementioned observations in monocytes from patients with CRMO, therapeutic effects of NSAID and corticosteroids in a large proportion of patients can be explained (Figure 3). NSAID inhibit the activity of cyclooxygenases (COX), enzymes responsible for the conversion of arachidonic acid into prostaglandins. Prostaglandins are essential for the activation of osteoclast cells, which may be central to inflammatory bone loss in CRMO<sup>3</sup>. Within the same pathway, corticosteroids inhibit phospholipase A2 (upstream of NSAID), as well as COX, resulting in reduced prostaglandin levels<sup>3</sup>. Further, corticosteroids inhibit nuclear factor- $\kappa$ B (NF- $\kappa$ B)-dependent gene activation, resulting in reduced expression of proinflammatory cytokine genes, including the genes for *IL-6*, and *TNF- $\alpha$* <sup>49,50</sup>.

Patients initially presenting with structural damage (e.g., vertebral fractures or edema with sclerosis) and patients who fail to respond to NSAID and repeated oral corticosteroid courses should be treated more aggressively. Possible options are sulfasalazine (SSZ), methotrexate (MTX), anti-TNF agents, anti-IL-1 treatment, and bisphosphonates. The classic DMARD SSZ and MTX are more commonly used in North America<sup>12</sup>. Both agents mediate reduced inflammatory cytokine expression, thus potentially correcting the imbalance between pro- and antiinflammatory signals in CNO/CRMO<sup>51</sup>. In many European centers, including our

institution, cases resistant to standard treatment with NSAID and corticosteroids are successfully treated with TNF inhibitors. TNF inhibitors specifically block TNF- $\alpha$ , restoring the balance between this highly potent proinflammatory cytokine and immune modulatory cytokines IL-10 and IL-19<sup>14,15,37</sup>. During the differentiation and activation of osteoclasts, TNF- $\alpha$  versus IL-10 and IL-19 are counteracting mediators<sup>40</sup>. Pamidronate is used in cases resistant to TNF inhibitors or in patients with radiologically active spinal involvement with structural damage (particularly vertebral fractures)<sup>5,6,7</sup>. Pamidronate can be administered following 1 of 2 common protocols: (1) an initial dose of 0.5 mg/kg/day followed by 1 mg/kg/day (maximum 60 mg) on days 2 and 3 every 3 months for a total of 3–4 courses, or (2) 1 dose of 1 mg/kg (very first dose 0.5 mg/kg, maximum 60 mg) every month for 1–6 months<sup>52,53</sup>. Pamidronate is highly effective in most cases refractory to other therapeutic agents, which may be explained by blockade of the most downstream cell-type involved. However, this hypothesis remains to be scientifically proven<sup>5</sup>.

### NONBACTERIAL OSTEOMYELITIS IN MICE

Two well-characterized murine models exist, both resembling severe CRMO. Chronic multifocal osteomyelitis (cmo) mice carry a spontaneous homozygous mutation (p.L98P), and lupo mice carry a chemically induced homozygous mutation (p.I282N) in the proline-serine-threonine phosphatase-interacting protein 2 (*Pstpip2*) gene<sup>54,55</sup>. Both strains develop severe cytokine and chemokine dysregulation, systemic inflammation, extramedullary hematopoiesis, skin inflammation, and sterile osteomyelitis. Though the exact contribution of *Pstpip2* mutations remains unknown, a central contribution of enhanced IL-1 $\beta$  expression and secretion has been demonstrated. Of note, IL-1 $\beta$  release was independent of NLRP3 inflammasome activation, because cmo mice that were also deficient of the inflammasome components NLRP3, ASC, or caspase-1 were not protected from the development of osteomyelitis. Thus, additional proteases other than caspase-1 appear to be responsible for proinflammatory IL-1 $\beta$  activation in cmo mice<sup>56,57,58</sup>. More details about murine CRMO are provided in Supplementary Data 2 (available online at [jrheum.org](http://jrheum.org))<sup>54,55,56,57,58,59</sup>.

### POTENTIAL INFLUENCE OF THE MICROBIOME

Over the past few years, disturbances to the microbiome, particularly of the gut, have been proven to contribute to altered immune cell distribution and inflammatory phenotypes in several disorders. In rheumatoid arthritis, for example, the replacement of *Lactobacillus spp.* with *Prevotella spp.* has been linked to disease activity and outcomes. Lukens, *et al* published the first evidence that disturbances in the gut microbiome may contribute to sterile bone inflammation<sup>57</sup>. The authors demonstrated that cmo mice on a high-fat diet exhibited alteration in their gut microbiome, and were protected from the development of aseptic

osteomyelitis. Animals on a low-fat diet exhibited elevated numbers of inflammation-associated microbes, including *Prevotella spp.*, while animals on a high-fat diet exhibited a shift toward *Lactobacillus spp.*, which was reflected by enhanced IL-1 $\beta$  expression in animals on a low-fat diet. Fecal transplant from high-fat diet mice to young cmo mice resulted in decreased *Prevotella spp.* colonization of the gut and protection from CNO<sup>57</sup>.

In humans, data on possible effects of diet or other environmental factors on CRMO are currently lacking. The reported association between severe cystic acne and CNO, however, may hint at involvement of changes in the microbiome contributing to inflammation in CNO. Particularly in adults, CNO frequently occurs in conjunction with synovitis, acne, pustulosis, and hyperostosis, and is then referred to as SAPHO syndrome<sup>3,7,9</sup>. Because both individual disorders, severe cystic acne and CNO, share the feature of imbalanced expression and secretion of proinflammatory (IL-6, TNF- $\alpha$ ) and antiinflammatory cytokines (IL-10), and because *Propionibacterium acnes* mediates TLR-induced activation of MAPK pathways, it is tempting to propose a potential pathophysiological connection of an altered skin microbiome and aseptic bone inflammation in CNO — at least in patients with severe acne and concomitant CNO or full-blown SAPHO syndrome<sup>60</sup>. This, however, currently remains highly speculative and warrants scientific investigation.

Despite intense investigation and recent scientific advances, the exact molecular pathomechanisms of CNO/CRMO remain incompletely understood. Based on our current knowledge, the imbalance between pro- and antiinflammatory cytokines in potentially proinflammatory monocytes centrally contributes to the disease phenotype of CNO/CRMO. Mostly monocyte/macrophage-derived serum biomarkers for the diagnosis and monitoring of CRMO support the hypothesis. In agreement with these observations, correcting the imbalance between pro- and antiinflammatory cytokines through untargeted (NSAID, corticosteroids, bisphosphonates) or targeted approaches (etanercept, anakinra, etc.) has proven successful for the treatment of CNO/CRMO. Further studies are warranted to confirm current pathophysiological concepts in larger multiethnic cohorts, investigate the influence of the microbiome (particularly of the skin and gut), and target the exact molecular events resulting in altered MAPK activation in monocytes from patients with CRMO. A better understanding of the exact molecular pathomechanisms will aid in finding novel targeted treatment options with limited side effects.

#### ACKNOWLEDGMENT

The authors thank Christine Hedrich for her English-language consultation on this manuscript.

#### ONLINE SUPPLEMENT

Supplementary data for this article are available online at [jrheum.org](http://jrheum.org).

#### REFERENCES

1. Almeida de Jesus A, Goldbach-Mansky R. Monogenic autoinflammatory diseases: concept and clinical manifestations. *Clin Immunol* 2013;147:155-74.
2. McDermott MF, Aksentjevich I, Galon J, McDermott EM, Ogunkolade BW, Centola M, et al. Germline mutations in the extracellular domains of the 55 kDa TNF receptor, TNFR1, define a family of dominantly inherited autoinflammatory syndromes. *Cell* 1999;97:133-44.
3. Morbach H, Hedrich CM, Beer M, Girschick HJ. Autoinflammatory bone disorders. *Clin Immunol* 2013;147:185-96.
4. Sharma M, Ferguson PJ. Autoinflammatory bone disorders: update on immunologic abnormalities and clues about possible triggers. *Curr Opin Rheumatol* 2013;25:658-64.
5. Hedrich CM, Hahn G, Girschick HJ, Morbach H. A clinical and pathomechanistic profile of chronic nonbacterial osteomyelitis/chronic recurrent multifocal osteomyelitis and challenges facing the field. *Expert Rev Clin Immunol* 2013;9:845-54.
6. Hedrich CM, Hofmann SR, Pablik J, Morbach H, Girschick HJ. Autoinflammatory bone disorders with special focus on chronic recurrent multifocal osteomyelitis (CRMO). *Pediatr Rheumatol Online J* 2013;11:47.
7. Stern SM, Ferguson PJ. Autoinflammatory bone diseases. *Rheum Dis Clin North Am* 2013;39:735-49.
8. Assmann G. New directions in management of SAPHO syndrome. *Curr Rheumatol Rev* 2013;9:1.
9. Carneiro S, Sampaio-Barros PD. SAPHO syndrome. *Rheum Dis Clin North Am* 2013;39:401-18.
10. Jansson AF, Grote V; ESPED Study Group. Nonbacterial osteitis in children: data of a German Incidence Surveillance Study. *Acta Paediatr* 2011;100:1150-7.
11. Jansson AF, Muller TH, Gliera L, Ankerst DP, Wintergerst U, Belohradsky BH, et al. Clinical score for nonbacterial osteitis in children and adults. *Arthritis Rheum* 2009;60:1152-9.
12. Borzutzky A, Stern S, Reiff A, Zurakowski D, Steinberg EA, Dedeoglu F, et al. Pediatric chronic nonbacterial osteomyelitis. *Pediatrics* 2012;130:e1190-7.
13. El-Shanti HI, Ferguson PJ. Chronic recurrent multifocal osteomyelitis: a concise review and genetic update. *Clin Orthop Relat Res* 2007;462:11-9.
14. Hofmann SR, Morbach H, Schwarz T, Rosen-Wolff A, Girschick HJ, Hedrich CM. Attenuated TLR4/MAPK signaling in monocytes from patients with CRMO results in impaired IL-10 expression. *Clin Immunol* 2012;145:69-76.
15. Hofmann SR, Schwarz T, Möller JC, Morbach H, Schnabel A, Rosen-Wolff A, et al. Chronic non-bacterial osteomyelitis is associated with impaired Sp1 signaling, reduced IL10 promoter phosphorylation, and reduced myeloid IL-10 expression. *Clin Immunol* 2011;141:317-27.
16. Asumalahti K, Laitinen T, Lahermo P, Suomela S, Itonen-Vatjus R, Jansen C, et al. Psoriasis susceptibility locus on 18p revealed by genome scan in Finnish families not associated with PSORS1. *J Invest Dermatol* 2003;121:735-40.
17. Ferguson PJ, Bing X, Vasef MA, Ochoa LA, Mahgoub A, Waldschmidt TJ, et al. A missense mutation in *pstpip2* is associated with the murine autoinflammatory disorder chronic multifocal osteomyelitis. *Bone* 2006;38:41-7.
18. Ferguson PJ, Chen S, Tayeh MK, Ochoa L, Leal SM, Pelet A, et al. Homozygous mutations in *LPIN2* are responsible for the syndrome of chronic recurrent multifocal osteomyelitis and congenital dyserythropoietic anaemia (Majeed syndrome). *J Med Genet* 2005;42:551-7.
19. Herlin T, Fiirgaard B, Bjerre M, Kerndrup G, Hasle H, Bing X, et al. Efficacy of anti-IL-1 treatment in Majeed syndrome. *Ann Rheum Dis* 2013;72:410-3.

20. Valdearcos M, Esquinas E, Meana C, Peña L, Gil-de-Gómez L, Balsinde J, et al. Lipin-2 reduces proinflammatory signaling induced by saturated fatty acids in macrophages. *J Biol Chem* 2012;287:10894-904.
21. Vega MI, Huerta-Yepaz S, Garban H, Jazirehi A, Emmanouilides C, Bonavida B. Rituximab inhibits p38 MAPK activity in 2F7 B NHL and decreases IL-10 transcription: pivotal role of p38 MAPK in drug resistance. *Oncogene* 2004;23:3530-40.
22. Aksentijevich I, Masters SL, Ferguson PJ, Dancey P, Frenkel J, van Royen-Kerkhoff A, et al. An autoinflammatory disease with deficiency of the interleukin-1-receptor antagonist. *N Engl J Med* 2009;360:2426-37.
23. Morbach H, Dick A, Beck C, Stenzel M, Muller-Hermelink HK, Raab P, et al. Association of chronic non-bacterial osteomyelitis with Crohn's disease but not with CARD15 gene variants. *Rheumatol Int* 2010;30:617-21.
24. Reddy S, Jia S, Geoffrey R, Lorier R, Suchi M, Broeckel U, et al. An autoinflammatory disease due to homozygous deletion of the IL1RN locus. *N Engl J Med* 2009;360:2438-44.
25. Lindor NM, Arsenaault TM, Solomon H, Seidman CE, McEvoy MT. A new autosomal dominant disorder of pyogenic sterile arthritis, pyoderma gangrenosum, and acne: PAPA syndrome. *Mayo Clin Proc* 1997;72:611-5.
26. Smith EJ, Allantaz F, Bennett L, Zhang D, Gao X, Wood G, et al. Clinical, molecular, and genetic characteristics of PAPA syndrome: a review. *Curr Genomics* 2010;11:519-27.
27. Wise CA, Gillum JD, Seidman CE, Lindor NM, Veile R, Bashiardes S, et al. Mutations in CD2BP1 disrupt binding to PTP PEST and are responsible for PAPA syndrome, an autoinflammatory disorder. *Hum Mol Genet* 2002;11:961-9.
28. Girschick HJ, Zimmer C, Klaus G, Darge K, Dick A, Morbach H. Chronic recurrent multifocal osteomyelitis: what is it and how should it be treated? *Nat Clin Pract Rheumatol* 2007;3:733-8.
29. Jansson A, Renner ED, Ramser J, Mayer A, Haban M, Meindl A, et al. Classification of non-bacterial osteitis: retrospective study of clinical, immunological and genetic aspects in 89 patients. *Rheumatology* 2007;46:154-60.
30. Hofmann SR, Kubasch AS, Range U, Laass MW, Morbach H, Girschick HJ, et al. Serum biomarkers for the diagnosis and monitoring of chronic recurrent multifocal osteomyelitis (CRMO). *Rheumatol Int* 2016;36:769-79.
31. Golla A, Jansson A, Ramser J, Hellebrand H, Zahn R, Meitinger T, et al. Chronic recurrent multifocal osteomyelitis (CRMO): evidence for a susceptibility gene located on chromosome 18q21.3-18q22. *Eur J Hum Genet* 2002;10:217-21.
32. Beck C, Girschick HJ, Morbach H, Schwarz T, Yimam T, Frenkel J, et al. Mutation screening of the IL-1 receptor antagonist gene in chronic non-bacterial osteomyelitis of childhood and adolescence. *Clin Exp Rheumatol* 2011;29:1040-3.
33. Hurtado-Nedelec M, Chollet-Martin S, Chapeton D, Hugot JP, Hayem G, Gérard B. Genetic susceptibility factors in a cohort of 38 patients with SAPHO syndrome: a study of PSTPIP2, NOD2, and LPIN2 genes. *J Rheumatol* 2010;37:401-9.
34. Hamel J, Paul D, Gahr M, Hedrich CM. Pilot study: possible association of IL10 promoter polymorphisms with CRMO. *Rheumatol Int* 2012;32:555-6.
35. Hedrich CM, Bream JH. Cell type-specific regulation of IL-10 expression in inflammation and disease. *Immunol Res* 2010;47:185-206.
36. Hofmann SR, Rosen-Wolff A, Tsokos GC, Hedrich CM. Biological properties and regulation of IL-10 related cytokines and their contribution to autoimmune disease and tissue injury. *Clin Immunol* 2012;143:116-27.
37. Hofmann SR, Kubasch AS, Ioannidis C, Rösen-Wolff A, Girschick HJ, Morbach H, et al. Altered expression of IL-10 family cytokines in monocytes from CRMO patients result in enhanced IL-1 $\beta$  expression and release. *Clin Immunol* 2015;161:300-7.
38. César-Neto JB, Duarte PM, de Oliveira MC, Casati MZ, Tambeli CH, Parada CA, et al. Smoking modulates interferon-gamma expression in the gingival tissue of patients with chronic periodontitis. *Eur J Oral Sci* 2006;114:403-8.
39. Grange PA, Raingeaud J, Calvez V, Dupin N. Nicotinamide inhibits *Propionibacterium acnes*-induced IL-8 production in keratinocytes through the NF-kappaB and MAPK pathways. *J Dermatol Sci* 2009;56:106-12.
40. Nakashima T, Takayanagi H. Osteoimmunology: crosstalk between the immune and bone systems. *J Clin Immunol* 2009;29:555-67.
41. Nakashima T, Takayanagi H. Osteoclasts and the immune system. *J Bone Miner Metab* 2009;27:519-29.
42. Scianaro R, Insalaco A, Bracci Laudiero L, De Vito R, Pezzullo M, Teti A, et al. Deregulation of the IL-1 $\beta$  axis in chronic recurrent multifocal osteomyelitis. *Pediatr Rheumatol Online J* 2014;12:30.
43. Boehncke WH, Schön MP. Psoriasis. *Lancet* 2015;386:983-94.
44. Christophers E, Metzler G, Röcken M. Bimodal immune activation in psoriasis. *Br J Dermatol* 2014;170:59-65.
45. Harden JL, Krueger JG, Bowcock AM. The immunogenetics of psoriasis: a comprehensive review. *J Autoimmun* 2015;64:66-73.
46. Hedrich CM. Shaping the spectrum - from autoinflammation to autoimmunity. *Clin Immunol* 2016;165:21-8.
47. Girschick HJ, Huppertz HI, Harmsen D, Krauspe R, Müller-Hermelink HK, Papadopoulos T. Chronic recurrent multifocal osteomyelitis in children: diagnostic value of histopathology and microbial testing. *Hum Pathol* 1999;30:59-65.
48. Beck C, Morbach H, Beer M, Stenzel M, Tappe D, Gattenlöhner S, et al. Chronic nonbacterial osteomyelitis in childhood: prospective follow-up during the first year of anti-inflammatory treatment. *Arthritis Res Ther* 2010;12:R74.
49. Foteinou PT, Calvano SE, Lowry SF, Androulakis IP. In silico simulation of corticosteroids effect on an NFkB- dependent physicochemical model of systemic inflammation. *PLoS One* 2009;4:e4706.
50. Kim K, Brar P, Jakubowski J, Kaltman S, Lopez E. The use of corticosteroids and nonsteroidal antiinflammatory medication for the management of pain and inflammation after third molar surgery: a review of the literature. *Oral Surg Oral Med Oral Pathol Oral Radiol Endod* 2009;107:630-40.
51. Holzinger D, Frosch M, Föll D. [Methotrexate in the therapy of juvenile idiopathic arthritis]. [Article in German] *Z Rheumatol* 2010;69:496-504.
52. Hospach T, Langendoerfer M, von Kalle T, Maier J, Dannecker GE. Spinal involvement in chronic recurrent multifocal osteomyelitis (CRMO) in childhood and effect of pamidronate. *Eur J Pediatr* 2010;169:1105-11.
53. Miettunen PM, Wei X, Kaura D, Reslan WA, Aguirre AN, Kellner JD. Dramatic pain relief and resolution of bone inflammation following pamidronate in 9 pediatric patients with persistent chronic recurrent multifocal osteomyelitis (CRMO). *Pediatr Rheumatol Online J* 2009;7:2.
54. Chitu V, Nacu V, Charles JF, Henne WM, McMahon HT, Nandi S, et al. PSTPIP2 deficiency in mice causes osteopenia and increased differentiation of multipotent myeloid precursors into osteoclasts. *Blood* 2012;120:3126-35.
55. Grosse J, Chitu V, Marquardt A, Hanke P, Schmittwolf C, Zeitlmann L, et al. Mutation of mouse *Mayp/Pstpip2* causes a macrophage autoinflammatory disease. *Blood* 2006;107:3350-8.
56. Cassel SL, Janczy JR, Bing X, Wilson SP, Olivier AK, Otero JE, et al. Inflammasome-independent IL-1 $\beta$  mediates autoinflammatory disease in *Pstpip2*-deficient mice. *Proc Natl Acad Sci U S A* 2014;111:1072-7.
57. Lukens JR, Gross JM, Calabrese C, Iwakura Y, Lamkanfi M, Vogel



- P, et al. Critical role for inflammasome-independent IL-1 $\beta$  production in osteomyelitis. *Proc Natl Acad Sci U S A* 2014;111:1066-71.
58. Ferguson PJ, Laxer RM. New discoveries in CRMO: IL-1 $\beta$ , the neutrophil, and the microbiome implicated in disease pathogenesis in *Pstpip2*-deficient mice. *Semin Immunopathol* 2015;37:407-12.
59. Greenhill CJ, Jones GW, Nowell MA, Newton Z, Harvey AK, Moideen AN, et al. Interleukin-10 regulates the inflammasome-driven augmentation of inflammatory arthritis and joint destruction. *Arthritis Res Ther* 2014;16:419.
60. Jugeau S, Tenaud I, Knol AC, Jarrousse V, Quereux G, Khammari A, et al. Induction of toll-like receptors by *Propionibacterium acnes*. *Br J Dermatol* 2005;153:1105-13.