

Number of Ruptured Tendons and Surgical Delay as Prognostic Factors for the Surgical Repair of Extensor Tendon Ruptures in the Rheumatoid Wrist

Yu Sakuma, Kensuke Ochi, Takuji Iwamoto, Asami Saito, Koichiro Yano, Yurino Naito, Shinji Yoshida, Katsunori Ikari, and Shigeaki Momohara

ABSTRACT. Objective. Extensor tendon ruptures in the rheumatoid wrist are usually restored by extensor tendon reconstruction surgery. However, the factors significantly correlated with the outcomes of extensor tendon reconstruction have not been defined. We examined factors showing a statistically significant correlation with postoperative active motion after tendon reconstruction.

Methods. Spontaneous extensor tendon ruptures of 66 wrists in patients (mean age, 52.6 yrs) with rheumatoid arthritis (RA) were evaluated. All patients underwent tendon reconstruction surgery with wrist arthroplasty or arthrodesis. Active ranges of motion of the affected fingers were evaluated at 12 weeks postsurgery. Statistical significance was determined using multiple and single regression analyses.

Results. Forty-six (69.6%) wrists had “good” results, while 13 (19.7%) and 7 (10.6%) wrists had “fair” and “poor” results, respectively. In multiple regression analysis, an increased number of ruptured tendons and the age at operation were independent variables significantly correlated with the postoperative active motion of reconstructed tendons ($p = 0.009$). Single regression analysis also showed a significant association between the number of ruptured tendons and surgical delay ($p = 0.02$).

Conclusion. The number of ruptured extensor tendons was significantly correlated with the results of tendon reconstruction, and the number of ruptured tendons was significantly correlated with preoperative surgical delay. Our results indicate that, in patients presenting with possible finger extensor tendon rupture, rheumatologists should consult with hand surgeons promptly to preserve hand function. (J Rheumatol First Release Jan 15 2014; doi:10.3899/jrheum.130861)

Key Indexing Terms:

RHEUMATOID ARTHRITIS EXTENSOR TENDON RUPTURE RECONSTRUCTION
SURGICAL DELAY NUMBER OF RUPTURED TENDONS SURGICAL REPAIR

Extensor tendon rupture at the wrist is often seen in patients with rheumatoid arthritis (RA). Various conditions may lead to extensor tendon rupture, including attrition of the tendon with eroded, roughened, or dislocated bone; direct invasion of inflamed tenosynovium into the extensor

tendons; and ischemic necrosis of the tendon resulting from diminished blood supply caused by high pressure associated with proliferative synovium under the extensor retinaculum^{1,2}. Because extensor tendon rupture results in significant functional loss in the affected hand, many patients with extensor tendon rupture undergo surgical tendon reconstruction combined with treatments for the distal radioulnar joint^{3,4,5,6}.

Several reports have investigated the risk factors for finger extensor tendon rupture in the rheumatoid wrist. The risk factors for this condition include dorsal subluxation of the ulnar head, supination of the carpal bones, scallop sign of the distal radius, tenosynovitis persisting for more than 6 months, and dislocation of the extensor carpi ulnaris tendon^{7,8,9,10,11}. Several surgical procedures for tendon reconstruction have been reported and used, including end-to-side suture to adjust the extensor tendons, tendon transfer procedures [using extensor indicis proprius (EIP) tendons¹², wrist extensors¹³, and flexor digitorum sublimis (FDS) tendons¹⁴], and palmaris longus (PL) tendon¹⁵ grafting for multiple tendon ruptures. The clinical outcomes

From the Department of Orthopedic Surgery, Institute of Rheumatology, Tokyo Women's Medical University, Shinjuku, Tokyo, Japan.

Supported in part by grants-in-aid for scientific research from the Ministry of Education, Culture, Sports, Science and Technology-Japan to K.I.; the Japan Society for the Promotion of Science; The Nakatomi Foundation; and the Japan Orthopedics and Traumatology Foundation to K.O.

Y.S. Sakuma, MD, assistant professor; K.O. Ochi, MD, PhD, associate lecturer; T.I. Iwamoto, MD, PhD, associate lecturer; A.S. Saito, MD, assistant professor; K.Y. Yano, MD, assistant professor; Y.N. Naito, MD, assistant professor; S.Y. Yoshida, MD, assistant professor; K.I. Ikari, MD, PhD, associate professor; S.M. Momohara, MD, PhD, professor, Department of Orthopedic Surgery, Institute of Rheumatology, Tokyo Women's Medical University.

Address correspondence to Dr. K. Ochi, Department of Orthopedic Surgery, Institute of Rheumatology, Tokyo Women's Medical University, 10-22 Kawada-cho, Shinjuku-ku, Tokyo, 162-0054, Japan.

E-mail: ochi@1998.jukuin.keio.ac.jp

Accepted for publication October 30, 2013.

Personal non-commercial use only. The Journal of Rheumatology Copyright © 2014. All rights reserved.

for the surgical repair of single- or 2-tendon ruptures are generally good; however, the results for ruptures involving 3 or more tendons are less satisfactory^{2,16}. It is widely accepted that surgical treatment for extensor tendon ruptures in the rheumatoid wrist should be performed before the rupture progresses to 3 or more tendons to yield a favorable postoperative result; however, to the best of our knowledge, no statistical analyses have been performed to confirm this theory. Moreover, the factors significantly correlated with the results of extensor tendon reconstruction in the rheumatoid hand remain unclear.

In our study, we evaluated the correlation between these suspected factors, and used the postoperative active range of motion of the metacarpophalangeal (MCP) joint of the affected fingers as a guide to determine which clinical factors are more likely to lead to better outcomes of the surgical treatment of the extensor tendon ruptures in the rheumatoid wrist.

MATERIALS AND METHODS

Patients. We retrospectively reviewed the clinical characteristics of 66 hands (62 patients with RA: 56 women and 6 men) that underwent surgical procedures for extensor tendon reconstruction combined with treatment of the distal radioulnar joint for extensor tendon rupture. The mean age of the patients at the time of surgery was 52.6 years (range: 25–83), with a mean disease duration of 12.0 years (range: 2.7–38.5). The mean Larsen grading of the affected wrist was 3.8 (range: 2–5) and that of the affected MCP joint was 1.5 (range: 0.5–3.5). The mean number of ruptured extensor tendons was 2.9 (range: 1–6). The right side was affected in 74.2% of the patients, and their mean surgical delay (duration between the onset of tendon ruptures and the surgical treatments) was 23.7 weeks (range: 3–180). Written consent was obtained from all patients according to the Declaration of Helsinki, and the study was approved by the internal review board of our institute.

Surgical procedures and postoperative treatment. Overall, end-to-side suture was performed in 34 cases, tendon transfer in 26 cases, tendon grafting in 2 cases, and a combination of these techniques in 4 cases. Twenty-eight cases involved either 1 or 2 extensor tendon ruptures. Among these, 21 were treated with end-to-side suture surgical techniques (the distal stump of the ruptured tendon was sutured to the adjacent intact extensor tendon by interlacing suture)³. In 7 cases, EIP tendons were transferred to the ruptured tendons using an interlacing suture technique¹². Thirty-eight patients had 3 or more tendon ruptures. Among these, 14 cases were treated with end-to-side suture techniques, 18 cases with EIP transfer¹², 1 case with extensor carpi radialis longus tendon transfer¹³, 3 cases with tendon transfer using the FDS tendon of the ring finger¹⁴, and 2 cases with free tendon grafting using autogenous PL¹⁵. The affected wrist joints were treated using the Sauvé-Kapandji procedure in 59 cases⁵, Darrach procedure in 2 cases⁶, and arthrodesis in 6 cases⁴. All the wrist joints were immobilized in slightly dorsiflexed position using volar splinting for 3 weeks. The affected fingers underwent early motion treatment as follows: in patients undergoing end-to-side suture reconstruction of the extensor tendon, we performed 6 weeks of tension-reduced early mobilization as described by Ishiguro, *et al*^{3,17}. In patients showing extensor tendon rupture of the little finger (suture of the distal stump of the extensor of the little finger to the extensor of the ring finger transfer), the affected little finger was buddy-taped dorsally to the unaffected ring finger to reduce the tension at the site of tendon suture and allow active finger motion with significantly reduced risk of rerupture. In cases with extensor tendon rupture of the ring and little fingers (extensor of ring/little finger to extensor of middle finger transfer), the little finger was first buddy-taped dorsally to

the ring finger. Next, the buddy-taped ring/little fingers were again buddy-taped dorsally to the unaffected middle finger for the purpose described above. Patients were encouraged to move their fingers actively soon after the operation under the buddy taping conditions. In cases in which the tendon was reconstructed by either tendon transfer or tendon grafting, dynamic splinting was applied on the day after the operation. Outpatient-based postoperative rehabilitation was performed by hand therapists specializing in RA hands, starting from a mean of 20.9 days (range: 10–49) after the surgery, and the mean frequency of visits to hand therapists was 0.9 (range: 0.3–1.6) per week.

Evaluation of tendon reconstruction surgery. The results of tendon reconstruction surgery were evaluated at 12 weeks postsurgery. Postoperative active range of motion of the affected MCP joints was evaluated using our system, which assesses the motion of the MCP joint in a simplification of the Geldmacher criteria for outcome assessment¹⁸. The results of tendon reconstruction were evaluated by a combination of mean active flexion arc and mean active extension lag of the MCP joint of the affected fingers (Figure 1). “Good” cases had an active flexion arc $\geq 45^\circ$ and an extension lag $< 20^\circ$. “Fair” cases had an active flexion arc $\geq 45^\circ$ and an extension lag of 20° to 40° , or an active flexion arc $< 45^\circ$ and an extension lag $< 20^\circ$. “Poor” cases had an active flexion arc $< 45^\circ$ and an extension lag of 20° to 40° , or an extension lag $\geq 40^\circ$. Differences in the preoperative and postoperative active range of motion of the affected MCP joint were evaluated independently in available cases.

Statistical analysis. Multiple regression analysis was performed to clarify factors correlated with the results of tendon reconstruction surgery. The results of surgery using our system were assigned scores of 1 to 3 (good = 1, fair = 2, poor = 3) considered as ordinal variables, and preoperative and postoperative range of motion of the affected MCP joints were considered as continuous variables. The dependent variables considered to be potential correlates of surgical outcomes in regression models included age at operation, number of ruptured extensor tendons, Larsen grading of the wrist joint and the MCP joint of the affected fingers, surgical delay, surgical procedures used to reconstruct extensor tendons (the adjacent suture technique described above, and the others), the surgical procedure applied to the radiocarpal joint, the interval between surgery and the beginning of postoperative rehabilitation, and the frequency of ambulatory visits for rehabilitation. The correlation between surgical delay and the number of ruptured extensor tendons was also analyzed using simple linear regression analysis. All statistical analyses were performed using R 2.14.1 (CRAN: the Comprehensive R Archive Network at <http://cran.r-project.org/>), with a confidence level of 95% ($p < 0.05$).

RESULTS

Forty-six cases (69.7%) had good results, 13 (19.7%) had fair results, and 7 (10.6%) had poor results in our system.

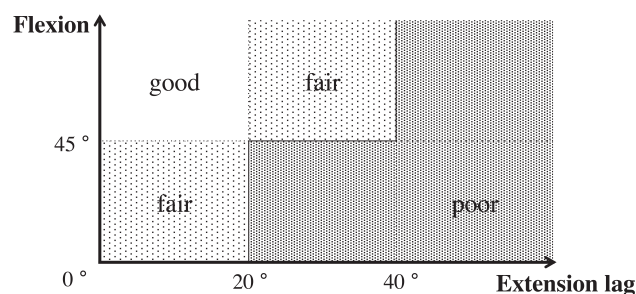


Figure 1. Evaluation system for the results of extensor tendon reconstruction. The results of tendon reconstruction were evaluated using a combination of mean flexion arc and mean extension lag of metacarpophalangeal joints of the affected fingers.

Although not statistically significant, a greater surgical delay tended to result in poorer postoperative results ($p = 0.19$, regression coefficient: 0.004; Table 1). Partial or total arthrodesis of the radiocarpal joint was performed in 6.5% of the good cases, 0% of the fair cases, and 28.6% of the poor cases.

Multiple regression analysis showed that age at the time of surgery and number of ruptured tendons were significantly correlated with the outcomes of tendon recon-

struction surgery (age, $p = 0.016$; number of ruptured tendons, $p = 0.009$; Table 1). Figure 2 shows the correlation between the number of ruptured tendons and the results of tendon reconstruction, and the mean surgical delay. A simple linear regression analysis showed a significant correlation between the number of ruptured tendons and the mean surgical delay ($p = 0.02$, regression coefficient: 0.01).

None of the potential correlates of surgical outcomes had any significant correlation with the preoperative and post-

Table 1. Clinical variables and results of tendon reconstruction.

Variables	Result of Tendon Reconstruction			p (regression coefficient)
	Good, n = 46	Fair, n = 13	Poor, n = 7	
Age at surgery, yrs (range)	51.9 (25–80)	53.3 (28–83)	59.3 (37–75)	0.015 (0.016)
Disease duration, yrs (range)	12.1 (2.7–30.2)	14.5 (4.2–38.5)	8.2 (4.3–12)	0.41 (0.011)
Larsen grading of the affected wrist joint	3.8 (2–5)	4.0 (3–5)	3.6 (3–4)	0.56 (0.082)
Larsen grading of the affected MCP joint	1.3 (0.5–3.5)	1.4 (1–3)	1.4 (0.5–3)	0.70 (–0.059)
Surgical delay, weeks (range)	18.6 (2.7–129.7)	40.6 (6.6–180.1)	29.5 (4–119)	0.19 (–0.036)
Number of ruptured tendon (range)	2.6 (1–4)	3.3 (2–6)	4.0 (2–6)	0.0088 (–0.23)
Surgical procedure for the wrist, n				0.38 (0.24)
Sauvé-Kapandji procedure	42	12	5	
Darrach procedure	1	1	0	
Partial fusion	2	0	2	
Total fusion	1	0	0	
Methods for tendon reconstruction, n				0.72 (0.063)
End-to-side suture	23	9	2	
Tendon transfer	18	3	5	
Tendon graft	1	1	0	
Combined	4	0	0	
Duration between surgery and rehabilitation, days (range)	20.7 (10–49)	22.4 (10–37)	18.6 (10–37)	0.95 (0.0071)
Frequency of postoperative rehabilitation, per week (range)	0.9 (0.3–1.6)	0.8 (0.3–1.6)	1.0 (0.6–1.5)	0.86 (0.046)

MCP: metacarpophalangeal.

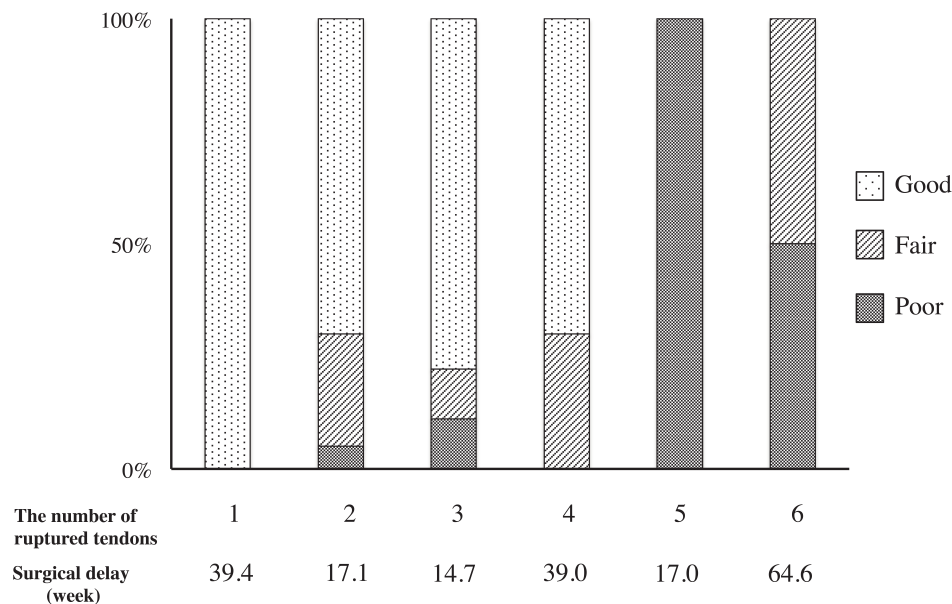


Figure 2. Correlation between the number of ruptured tendons and the result of tendon reconstruction, and the surgical delay.

operative range of motion of the affected MCP joints or the extension lag of the MCP joint of the affected fingers.

DISCUSSION

In our study, we showed that an increased number of ruptured extensor tendons was significantly correlated with poor results of extensor tendon reconstruction. To the best of our knowledge, few reports have comprehensively analyzed perioperative and postoperative factors affecting the results of extensor tendon reconstruction. Moore, *et al* showed that the surgical results in multiple tendon ruptures were generally poor, whereas single- or 2-tendon ruptures were successfully restored with surgical treatment². Although they did not perform a statistical analysis, their findings supported our results. Shannon and Barton reported that the factors that may decrease postoperative satisfaction of patients with RA who undergo extensor tendon reconstruction include perioperative systemic steroid therapy, postoperative wound complications, MCP joint dislocation, intrinsic muscle contracture, and rupture of FDS tendons¹⁶. However, they did not show a detailed correlation between postoperative patient satisfaction and postoperative motion of the affected fingers.

In our study, the number of ruptured extensor tendons was significantly correlated with a greater surgical delay. Although it is widely accepted that extensor tendon ruptures in the rheumatoid wrist begin with single- or 2-tendon rupture and progress to 3 or more tendon ruptures in a time-dependent manner in the absence of timely treatment^{2,16}, our findings may provide the first statistical support for this theory.

The reason for the correlation between an increased number of tendon ruptures and poor patient outcomes is unclear. However, in our study, an increased number of ruptured tendons was significantly correlated with a greater surgical delay. It is reasonable to assume that a longer surgical delay should result in a more severe contracture of the affected extensor muscles and a more severe flexion contracture of the affected MCP joints, which could result in a poorer surgical outcome. Another reason could be that cases of multiple tendon rupture require more complex surgical procedures and postoperative rehabilitation than cases showing few tendon ruptures, which could result in poorer surgical outcomes.

In our study, younger age at surgery was also significantly correlated with better surgical outcomes. This is reasonable because younger patients normally have greater muscle power, and may have a higher motivation for postoperative rehabilitation compared with elderly patients.

Our results statistically confirmed the importance of early surgical treatment of tendon ruptures of the rheumatoid wrist, particularly before the rupture of 3 or more extensor tendons, to increase the likelihood of good surgical outcomes¹⁹.

Our results should be of value for rheumatologists who often encounter extensor tendon ruptures and can refer the patients to hand surgeons for further consultation. Alderman, *et al* reported that rheumatologists tend to underestimate the need and the effect of surgical treatments for rheumatoid hands²⁰. However, our findings suggest that to ensure favorable postoperative results, rheumatologists should understand the effectiveness and importance of early surgical intervention in the treatment of rheumatoid wrists. In patients with RA who show difficulty in extending their fingers, it may be important for rheumatologists to consider the possibility of extensor tendon rupture and to consult with hand surgeons without delay¹².

Our study had several limitations. First, we were unable to evaluate the level of disease activity or the function and conditions of other joints, grip strength, and outcome measurement with the questionnaire distributed to our patients. Second, our evaluation was performed 12 weeks after surgical treatment for extensor tendon rupture, and may not necessarily be indicative of longterm results. Further prospective studies with a greater number of participants and a longer post-operative followup period are needed to evaluate the factors influencing the longterm outcomes of extensor tendon reconstruction in patients with RA.

The number of ruptured extensor tendons was significantly correlated with the results of tendon reconstruction, and the number of ruptured tendons showed a significant correlation with preoperative surgical delay. Our results indicate that if a rheumatologist encounters a patient with a possible finger extensor tendon rupture, it may be important to consult with hand surgeons promptly to preserve hand function.

ACKNOWLEDGMENT

The authors thank all the members at the Institute of Rheumatology, Tokyo Women's Medical University.

REFERENCES

1. Vaughan-Jackson OJ. Rupture of extensor tendons by attrition at the inferior radio-ulnar joint; report of two cases. *J Bone Joint Surg Br* 1948;30B:528-30.
2. Moore JR, Weiland AJ, Valdata L. Tendon ruptures in the rheumatoid hand: analysis of treatment and functional results in 60 patients. *J Hand Surg Am* 1987;12:9-14.
3. Ishiguro T, Ikegami H, Horiuchi Y, Takayama S. Tension-reduced early mobilization for reconstruction of ruptured extensor tendons in the rheumatoid hands. *J Jpn Soc Surg Hand* 1989;6:509-12.
4. Murray PM. Radioscapholunate arthrodesis. *Hand Clin* 2005;21:561-6.
5. Taleisnik J. The Sauve-Kapandji procedure. *Clin Orthop Relat Res* 1992;275:110-23.
6. Nolan WB 3rd, Eaton RG. A Darrach procedure for distal ulnar pathology derangements. *Clin Orthop Relat Res* 1992;275:85-9.
7. Ryu J, Saito S, Honda T, Yamamoto K. Risk factors and prophylactic tenosynovectomy for extensor tendon ruptures in the rheumatoid hand. *J Hand Surg Br* 1998;23:658-61.

8. McQueen F, Beckley V, Crabbe J, Robinson E, Yeoman S, Stewart N. Magnetic resonance imaging evidence of tendinopathy in early rheumatoid arthritis predicts tendon rupture at six years. *Arthritis Rheum* 2005;52:744-51.
9. Ishikawa H, Abe A, Murasawa A, Nakazono K, Horizono H, Ishii K, et al. Rheumatoid wrist deformity and risk of extensor tendon rupture evaluated by 3DCT imaging. *Skeletal Radiol* 2010; 39:467-72.
10. Freiberg RA, Weinstein A. The scallop sign and spontaneous rupture of finger extensor tendons in rheumatoid arthritis. *Clin Orthop Relat Res* 1972;83:128-30.
11. Seki E, Ishikawa H, Murasawa A, Nakazono K, Abe A, Horizono H, et al. Dislocation of the extensor carpi ulnaris tendon in rheumatoid wrists using three-dimensional computed tomographic imaging. *Clin Rheumatol* 2013;32:1627-32.
12. Williamson SC, Feldon P. Extensor tendon ruptures in rheumatoid arthritis. *Hand Clin* 1995;11:449-59.
13. Boyce T, Youm Y, Sprague BL, Flatt AE. Clinical and experimental studies on the effect of extensor carpi radialis longus transfer in the rheumatoid hand. *J Hand Surg Am* 1978;3:390-4.
14. Nalebuff EA, Patel MR. Flexor digitorum sublimis transfer for multiple extensor tendon ruptures in rheumatoid arthritis. *Plast Reconstr Surg* 1973;52:530-3.
15. Mountney J, Blundell CM, McArthur P, Stanley D. Free tendon interposition grafting for the repair of ruptured extensor tendons in the rheumatoid hand. A clinical and biomechanical assessment. *J Hand Surg Br* 1998;23:662-5.
16. Shannon FT, Barton NJ. Surgery for rupture of extensor tendons in rheumatoid arthritis. *Hand* 1976;8:279-86.
17. Ochi K, Horiuchi Y, Matsumura T, Nakamura M, Takei T, Yabe H. Distal radius fracture after Sauve-Kapandji procedure in a rheumatoid arthritis patient. *Mod Rheumatol* 2012;22:290-4.
18. Geldmacher J, Plank M, Treuheit KD. Bedeutung der präoperativen Status bei der Auswertung der Ergebnisse der Rekonstruktion der Strecksehnen (in German). Significance of the preoperative status in the evaluation of results of the reconstruction of extensor tendons. *Handchir Mikrochir Plast Chir* 1986;18:23-9.
19. Gong HS, Lee JO, Baek GH, Kim BS, Kim JY, Lee JS, et al. Extensor tendon rupture in rheumatoid arthritis: a survey of patients between 2005 and 2010 at five Korean hospitals. *Hand Surg* 2012;17:43-7.
20. Alderman AK, Chung KC, Kim HM, Fox DA, Ubel PA. Effectiveness of rheumatoid hand surgery: contrasting perceptions of hand surgeons and rheumatologists. *J Hand Surg Am* 2003; 28:3-11; discussion 2-3.