

# Hepatitis B Virus-associated Antigen Deposition in Renal Tissue from Patients with Systemic Lupus Erythematosus

ZHUOLONG WANG, MENGTAO LI, XIAOFENG ZENG, and XINJIAN LIU

**ABSTRACT. Objective.** To determine the significance of hepatitis B virus (HBV)-associated antigen deposition in renal tissue from patients with systemic lupus erythematosus (SLE).

**Methods.** The medical records of 166 inpatients with lupus nephritis and 384 controls without SLE were analyzed retrospectively. Patients with SLE were classified as positive or negative depending on whether HBV-associated antigen deposition was detected in renal biopsies.

**Results.** HBV-associated antigen deposition was mainly detected in renal tissue from patients with SLE (50.6%), primary renal glomerular disease (20.8%), and allergic purpura (21.7%). It was not detected in renal tissue from patients with diabetic nephropathy, hypertensive nephrosclerosis, thin basement membrane nephropathy, or Alport syndrome. Hepatitis B surface antigen and core antigen were deposited in the mesangial region and vascular loops. The positive group had a significantly higher frequency of IgG, IgA, and IgM deposition than the negative group (53.6% vs 30.5%;  $p < 0.01$ ). There was no significant difference in the types of lupus nephritis observed between the 2 groups.

**Conclusion.** There was a high prevalence of HBV-associated antigen deposition in renal tissue of patients with SLE by indirect immunofluorescence, which may result mainly from the cross-reactivity with deposited immunoglobulins. (J Rheumatol First Release March 15 2012; doi:10.3899/jrheum.111107)

*Key Indexing Terms:*

SYSTEMIC LUPUS ERYTHEMATOSUS  
HEPATITIS B VIRUS

LUPUS NEPHRITIS  
PREVALENCE

Systemic lupus erythematosus (SLE) is a multisystem autoimmune disease characterized by the production of autoantibodies to components of the cell nucleus. Renal damage occurs in most patients with SLE. Despite intensive research, the cause of SLE remains unknown<sup>1</sup>.

Hepatitis B virus (HBV), a member of the *Hepadnaviridae* family, is a small DNA virus with unusual features similar to those of retroviruses. There are currently more than 300 million people worldwide infected with HBV<sup>2</sup>. In China, there is a 10%–15% rate of chronic HBV infection in the general population<sup>3,4</sup>. The prevalence of HBV infection in patients with SLE varies according to local endemicity<sup>4,5,6</sup>.

The relationship between HBV and SLE remains unclear. It is reasonable to suspect a higher frequency of HBV infection in patients with SLE than in the general population because of the increased susceptibility to infection that

results from immunological dysfunction and treatment with corticosteroids and other immunosuppressive agents. Unexpectedly, patients with SLE have lower prevalence of serum hepatitis B surface antigen (HBsAg) and higher prevalence of anti-HBV antibody compared with the general population<sup>4,7,8,9,10</sup>. In China, the prevalence of serum HBsAg is 2.33% in patients with SLE compared with 9.56% in the general population<sup>4</sup>. HBV-associated antigen deposition in renal tissue may cause HBV-related renal disease<sup>11</sup>, and one study has shown HBsAg renal deposition in 30 of 47 patients with SLE<sup>12</sup>. It seems contradictory for patients with SLE to have low prevalence of HBsAg in serum and high prevalence of HBsAg deposition in the kidneys. Whether renal deposition of HBV antigens is caused by HBV infection (genuine HBV antigen) or some nonspecific reaction (artifactual staining of HBV antigen) remains uncertain.

We discovered HBV-associated antigens may deposit in renal tissue from SLE patients even the serologic screening tests for HBV infection are negative in our clinical practice (unpublished data).

We have conducted a retrospective study by analyzing the medical data of 166 inpatients with SLE and 384 without SLE (as controls) to determine the significance of HBV-associated antigen deposition in renal tissue.

*From the Department of Rheumatology, Peking Union Medical College Hospital, Chinese Academy of Medical Science, and Peking Union Medical College, Beijing, China.*

*Z. Wang, PhD; M. Li, MD; X. Zeng, BM; X. Liu, PhD, Department of Rheumatology, Peking Union Medical College Hospital, Chinese Academy of Medical Science, and Peking Union Medical College.*

*Address correspondence to Prof. X. Zeng, Department of Rheumatology, Peking Union Medical College Hospital, Xicheng District, Beijing 100032, China. E-mail: Zengxiaofeng@medmail.com.cn*

*Accepted for publication December 12, 2011.*

Personal non-commercial use only. The Journal of Rheumatology Copyright © 2012. All rights reserved.

## MATERIALS AND METHODS

**Patients.** All patients were admitted to Peking Union Medical College Hospital from October 2004 to March 2010.

**Selection criteria.** Inclusion criteria for the SLE group were (1) patients fulfilled the revised American College of Rheumatology classification criteria for SLE<sup>13</sup>; (2) patients had lupus nephritis and underwent renal biopsy to clarify the pathological changes; (3) serological screening tests for HBV infection were negative including HBsAg, hepatitis B surface antibody (HBsAb), hepatitis B e antigen (HBeAg), hepatitis B e antibody (HBeAb) and hepatitis B core antibody (HBcAb). Exclusion criteria: any positive serological screening tests for HBsAg, HBsAb, HBeAg, HBeAb, or HBcAb.

Patients with SLE were classified into 2 groups: (1) negative group: HBsAg and hepatitis B core antigen (HBcAg) were both negative in renal biopsy specimens; (2) positive group: HBsAg and/or HBcAg were positive in renal biopsy specimens.

**Control group.** Inclusion criteria for the control group (non-SLE) were (1) patients with renal disease who underwent renal biopsy to clarify pathological changes; (2) serological screening tests for HBV infection were negative, including HBsAg, HBsAb, HBeAg, HBeAb, and HBcAb. Exclusion criteria: any positive serological screening tests for HBsAg, HBsAb, HBeAg, HBeAb, or HBcAb.

**Clinical and laboratory data.** Data were collected from the medical records of the Peking Union Medical College Hospital. Serological screening for HBV infection included HBsAg, HBsAb, HBeAg, HBeAb, and HBcAb. Testing was performed by chemiluminescence (Abbott Architect I2000SR; Abbott Park, IL, USA) during hospitalization and before renal biopsy.

**Renal biopsy.** Biopsy tissue was divided into 3 samples. One sample was fixed and cut into sections 3  $\mu$ m thick, then stained with hematoxylin and eosin and periodic acid silver methenamine. The second sample was embedded in ornithine carbamoyltransferase compound and cut into sections 5  $\mu$ m thick for detecting IgG, IgA, and IgM with direct immunofluorescence, and HBV antigen with indirect immunofluorescence. The third sample was processed using conventional methods for observation by electron microscopy.

**Detection of HBV antigen in renal tissue.** Frozen sections (5  $\mu$ m) of fresh renal tissue were stained for HBsAg and HBcAg by indirect immunofluorescence. The primary antibodies for HBV antigens were mouse monoclonal HBsAb (isotype IgG2b, kappa; Invitrogen, Carlsbad, CA, USA) and rabbit anti-HBcAg (Invitrogen). Secondary antibodies were rabbit polyclonal anti-mouse immunoglobulins/FITC (DakoCytomation, Glostrup, Denmark), and swine polyclonal anti-rabbit immunoglobulins/FITC (DakoCytomation). Staining specificity for HBV antigens was checked by blocking and absorption procedures. No cross-reactivity of anti-HBV antigens or with immunoglobulins, complement, fibrinogen, and glomerular tissues from HBsAg-negative controls was observed.

The deposition site was classified as the mesangial region, capillary loops, or interstitial zone, and the deposition type as diffuse, local, proportional, or segmental. The deposition site, main site, and deposition type were routinely recorded on the examination reports. A renal pathologist reviewed the pathological diagnosis and immunofluorescence results. Histological classification of lupus nephritis was according to the International Society of Nephrology/ Renal Pathology (2003).

**Statistical analysis.** Clinical data were compared using t, chi-square, and Fisher's exact tests. The statistical significance of the various tests was examined by 2-sided hypothesis testing. P values < 0.05 were considered significant. Statistical analysis was performed using SPSS version 17.0.

## RESULTS

**Demographic characteristics.** A total of 166 patients met the entry criteria for the SLE group. There were 384 patients in the control group, including 226 with primary renal glomeru-

lar disease, 92 with allergic purpura, 14 with diabetic nephropathy, 12 with hypertensive nephrosclerosis, 33 with thin basement membrane nephropathy, and 7 with Alport syndrome. Demographic features are shown in Table 1.

**Comparison of HBV-associated antigen deposition in renal tissue.** HBV-associated antigen deposition in the kidney is shown in Table 2. Patients may have deposition of HBsAg or HBcAg alone or in combination. It was detected in renal tissue mainly from patients with SLE (Figures 1 and 2), primary renal glomerular disease, or allergic purpura. HBV-associated antigen deposition was not detected in renal tissue from patients with diabetic nephropathy, hypertensive nephrosclerosis, thin basement membrane nephropathy, or Alport syndrome.

HBV-associated antigen deposition was found in 50.6% of patients with SLE and 20.8% of those with primary renal glomerular disease. Patients with SLE had obviously significantly higher prevalence of HBV-associated antigen deposition than those with primary renal glomerular disease (chi-square = 38.21,  $p < 0.01$ ).

We compared the 2 groups of patients for prevalence of HBsAg alone, HBcAg alone, and combined HBsAg/HBcAg. HBsAg deposition was found in 49.4% of patients with SLE, compared with 20.4% of those with primary renal glomerular disease. Patients with SLE had obviously significantly higher prevalence of HBsAg deposition than those with primary renal glomerular disease (chi-square = 36.71,  $p < 0.01$ ). Among patients with SLE, 25.3% had HBcAg deposition, compared with 4.9% of those with primary renal glomerular disease. Patients with SLE had obviously significantly higher prevalence of HBcAg deposition than those without SLE (chi-square = 34.17,  $p < 0.01$ ). Among patients with SLE, 24.1% had combined HBsAg/HBcAg deposition, compared with 4.4% of those with primary renal glomerular disease. Patients with SLE had obviously significantly higher prevalence of HBsAg/HBcAg deposition than those with primary renal glomerular disease (chi-square = 33.28,  $p < 0.01$ ).

HBV-associated antigen deposition was found in 21.7% of those with allergic purpura. Patients with SLE had obviously significantly higher prevalence of HBV-associated antigen deposition than those with allergic purpura (chi-square = 20.49,  $p < 0.01$ ).

We compared the 2 groups of patients for prevalence of HBsAg or HBcAg alone, or combined HBsAg/HBcAg. Patients with SLE had obviously significantly higher prevalence of HBsAg deposition than those with allergic purpura (49.4% vs 20.7%, respectively; chi-square = 20.53,  $p < 0.01$ ). Patients with SLE had obviously significantly higher prevalence of HBcAg deposition than those with allergic purpura (25.3% vs 2.2%; chi-square = 22.38,  $p < 0.01$ ). Patients with SLE had obviously significantly higher prevalence of HBsAg/HBcAg deposition than those with allergic purpura (24.1% vs 1.1%; chi-square = 23.44,  $p < 0.01$ ).

Table 1. Demographic features.

Groups	N	Sex, M/F	Age, mean $\pm$ SD, yrs	Disease Duration, mean $\pm$ SD, mo
SLE	166	14/152	30.8 $\pm$ 10.9	35.9 $\pm$ 56.4
Primary renal glomerular disease	226	42/184	32.1 $\pm$ 12.1	23.2 $\pm$ 39.9
Allergic purpura	92	51/41	26.1 $\pm$ 11.1	23.4 $\pm$ 42.8
Diabetes nephropathy	14	8/6	47.6 $\pm$ 13.6	65.4 $\pm$ 66.8
Hypertensive nephrosclerosis	12	7/5	40.7 $\pm$ 11.4	35.8 $\pm$ 46.3
Thin basement membrane nephropathy	33	14/19	33.9 $\pm$ 11.9	36.4 $\pm$ 56.0
Alport syndrome	7	5/2	17.2 $\pm$ 4.8	70.7 $\pm$ 58.7

SLE: systemic lupus erythematosus.

Table 2. Comparison of HBV-associated antigen deposition in renal tissue.

Groups	N	A (%)	B (%)	C (%)	D (%)
SLE	166	84 (50.6)	82 (49.4)	42 (25.3)	40 (24.1)
Primary renal glomerular disease	226	47 (20.8)	46 (20.4)	11 (4.9)	10 (4.4)
Allergic purpura	92	20 (21.7)	19 (20.7)	2 (2.2)	1 (1.1)
Diabetes nephropathy	14	0	0	0	0
Hypertensive nephrosclerosis	12	0	0	0	0
Thin basement membrane nephropathy	33	0	0	0	0
Alport syndrome	7	0	0	0	0

A: HBsAg(+) and/or HBcAg(+). B: HBsAg(+). C: HBcAg(+). D: HBsAg (+), HBcAg(+). HBV: hepatitis B virus; SLE: systemic lupus erythematosus; HBsAg: HB surface antigen; HBcAg: hepatitis B core antigen.

*HBV-associated antigen deposition and immunoglobulin deposition in renal tissue.* All 84 patients with SLE in the positive group had immunoglobulin deposition (IgG, IgA, or IgM) in renal tissue (Table 3). The positive group had a significantly higher prevalence of IgG/IgA/IgM deposition than the negative group. We compared deposition of IgG, IgA, and IgM with that of HBsAg and HBcAg, and found that they had a similar site and distribution of deposition.

*HBV-associated antigen deposition and type of lupus nephritis.* The proportion of patients with Class I-VI lupus nephritis is shown in Table 4. Class IV and V lupus nephritis were more common than the other types in the positive and negative groups. There was no Class I lupus nephritis in the positive group. There was no significant difference in the types of lupus nephritis in the 2 groups.

## DISCUSSION

HBsAg is often regarded as the marker of HBV infection, and anyone who has a serological positive test for HBsAg should be presumed to have some level of ongoing viremia<sup>14</sup>. Atypical HBV infection, including seronegative or latent HBV infection, is HBsAg-negative (either seronegative for all HBV markers or positive for HBcAb and/or HBsAb). HBcAg can be found only in cell nuclei and/or cytoplasm, but not in blood. The clinical manifestations are determined by the immunological response of the host<sup>14,15</sup>.

The mechanisms involved in HBV-related autoimmune diseases may include molecular mimicry between HBV

antigens and self-proteins, generation of immune complexes between HBV antigens and antibodies, and exposure of intracellular antigens to the immune system following apoptosis/tissue damage, reproducing the spectrum of nonhepatic manifestations of natural hepatitis B<sup>16,17</sup>.

HBV-associated antigen can be deposited in the glomeruli and cause HBV-associated glomerulonephritis by the following mechanisms: immune complex formation *in situ*; circulating immune complexes becoming trapped in the glomeruli; or HBV directly infecting cells in the glomeruli<sup>18,19,20</sup>.

In our study, 50.6% of SLE patients with negative serological screening for HBV infection had renal deposition of HBV-associated antigens. HBV-Ag was mainly detected in renal tissue from patients with SLE, primary renal glomerular disease, or allergic purpura, which belongs to the immune-complex type of glomerulonephropathy; it was not detected in renal tissue from patients with diabetic nephropathy, hypertensive nephrosclerosis, or thin basement membrane nephropathy. Although the secondary antibodies used in our study were solid-phase-absorbed with human and fetal calf serum and cross-reactivity with human immunoglobulins was low, it remains possible that we had false-positive results. If all the patients with HBV-Ag renal deposition (50.6%) were thought to have HBV infection, this seems contradictory to clinical results. Secondary antibodies may bind nonspecifically to deposited immunoglobulins. The kidneys of patients with SLE could have more

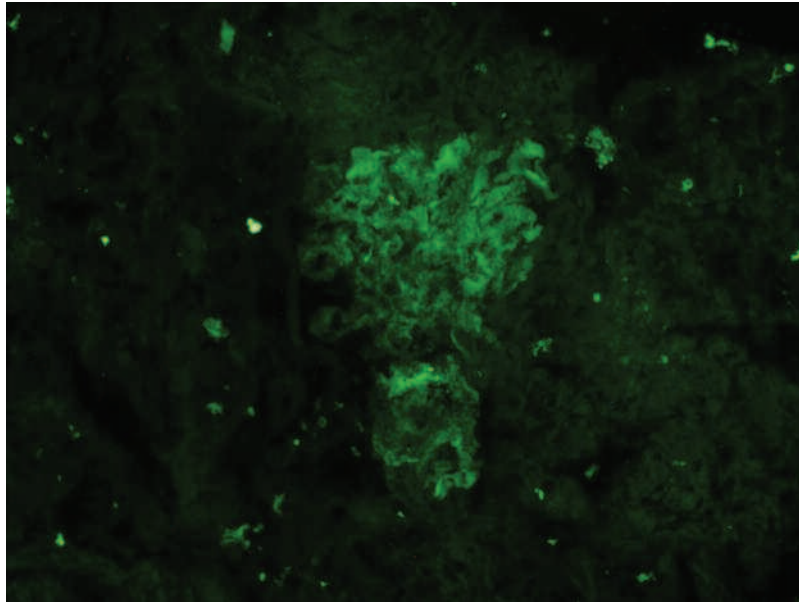


Figure 1. Indirect immunofluorescence staining with mouse anti-hepatitis B surface antigen and FITC-conjugated rabbit anti-mouse immunoglobulins shows diffuse positive staining.

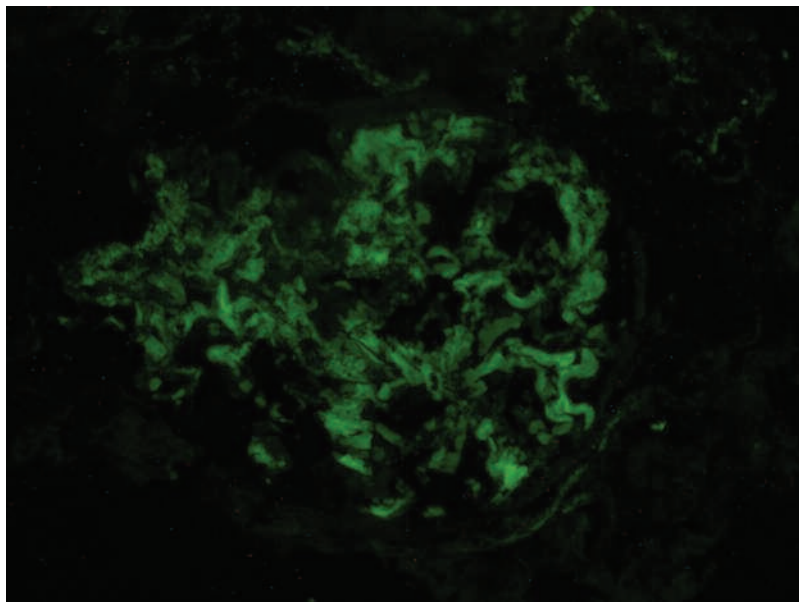


Figure 2. Indirect immunofluorescence staining with rabbit anti-hepatitis B core antibody and FITC-conjugated swine anti-rabbit immunoglobulins shows segmental positive staining.

deposited immunoglobulins, which means that patients with SLE may have a significantly higher prevalence of HBV-associated antigen deposition than non-SLE patients.

In our study, the positive group had a significantly higher frequency of IgG/IgA/IgM deposition compared with the negative group (53.6% vs 30.5%;  $p < 0.01$ ). This implied that there was a difference between the 2 groups for deposited immunoglobulins, and the cross-reactivity with deposited immunoglobulins resulted in artifactual staining of HBV

antigen. This explanation is supported by the fact that no significant difference in the types of lupus nephritis was observed between the 2 groups.

HBV DNA has been detected in some patients with renal HBV-associated antigens by *in situ* hybridization or Southern blot analysis<sup>20,21</sup>. In a transgenic mouse model, the expression of HBsAg and HBcAg on tubular epithelial cells was associated with upregulation of complement-mediated inflammatory gene pathways in the absence of HBV repli-

Table 3. HBV-associated antigen and immunoglobulin deposition.

Group (n)	IgG (%)	IgA (%)	IgM (%)	IgG/A (%)	IgG/M (%)	IgA/M (%)	IgG/A/M (%)*	Ig-negative (%)
Positive group (84)	23 (27.4)	0	1 (1.2)	9 (10.7)	6 (7.1)	0	45 (53.6)	0
Negative group (82)	22 (26.8)	1 (1.2)	1 (1.2)	12 (14.6)	10 (12.2)	1 (1.2)	25 (30.5)	10 (12.2)

\* Chi-square = 9.06,  $p < 0.01$ . HBV: hepatitis B virus.

Table 4. HBV-associated antigen deposition and lupus nephritis, by classification stage.

Group (n)	I (%)	II (%)	III (%)	IV (%)	V (%)	V + III (%)	V + IV (%)	VI
Positive group (84)	0	6 (7.1)	7 (8.3)	28 (33.3)	26 (31.0)	5 (6.0)	12 (14.3)	0
Negative group (82)	2 (2.4)	14 (17.1)	7 (8.5)	32 (39.0)	18 (22.0)	3 (3.7)	6 (7.3)	0

HBV: hepatitis B virus.

cation<sup>22</sup>. In our study, 25.3% of SLE patients had HBcAg positivity in the mesangial region. Whether HBV directly infected cells in the glomeruli or it was atypical HBV infection needs to be clarified. The HBV seronegative finding may be due to sedimentation of immune complexes in the kidneys.

HBV-related glomerulopathy may coexist with SLE<sup>11</sup>. HBV-related nephropathy and lupus nephritis have morphological similarities<sup>23</sup>, which leads to difficulty in diagnosis. Our results suggest that HBV-associated antigen deposition detected by indirect immunofluorescence may not be a good marker, because of the possible cross-reactivity.

Our findings suggest that indirect immunofluorescence shows a high prevalence of HBV-associated antigen deposition in renal tissue of patients with SLE, which may result mainly from cross-reactivity with deposited immunoglobulins.

## ACKNOWLEDGMENT

The authors acknowledge Medical Records, Department of Rheumatology, Department of Pathology, Department of Nephrology, Peking Union Medical College Hospital.

## REFERENCES

- Rahman A, Isenberg DA. Systemic lupus erythematosus. *N Engl J Med* 2008;358:929-39.
- Liang TJ. Hepatitis B: The virus and disease. *Hepatology* 2009;49 Suppl:S13-21.
- Liang XF, Chen YS, Wang XJ, He X, Chen LJ, Wang J, et al. A study on the sero-epidemiology of hepatitis B in Chinese population aged over 3-years old [Chinese]. *Zhonghua Liu Xing Bin Xue Za Zhi* 2005;26:655-8.
- Zhao J, Qiu M, Li M, Lu C, Gu J. Low prevalence of hepatitis B virus infection in patients with systemic lupus erythematosus in southern China. *Rheumatol Int* 2010;30:1565-70.
- Chng HH, Fock KM, Chew CN, Guan R, Feng PH, Boey ML, et al. Hepatitis B virus infection in patients with systemic lupus erythematosus. *Singapore Med J* 1993;34:325-6.
- Abu-Shakra M, El-Sana S, Margalith M, Sikuler E, Neumann L, Buskila D. Hepatitis B and C viruses serology in patients with SLE. *Lupus* 1997;6:543-4.
- Shorey J, Cheatum DE, Combes B, Ziff M. Hepatitis B antigen and antibody in patients with systemic lupus erythematosus. *Arthritis Rheum* 1974;17:583-9.
- Maya R, Gershwin ME, Shoenfeld Y. Hepatitis B virus (HBV) and autoimmune disease. *Clin Rev Allerg Immunol* 2008;34:85-102.
- Permin H, Aldershvile J, Nielsen JO. Hepatitis B virus infection in patients with rheumatic diseases. *Ann Rheum Dis* 1982;41:479-82.
- Ram M, Anaya JM, Barzilai O, Izhaky D, Porat Katz BS, Blank M, et al. The putative protective role of hepatitis B virus (HBV) infection from autoimmune disorders. *Autoimmun Rev* 2008;7:621-5.
- Mac-Moune Lai F, Lai KN, Lee JC, Hom BL. Hepatitis B virus-related glomerulopathy in patients with systemic lupus erythematosus. *Am J Clin Pathol* 1987;88:412-20.
- Looi LM, Prathap K. Hepatitis B virus surface antigen in glomerular immune complex deposits of patients with systemic lupus erythematosus. *Histopathol* 1982;6:141-7.
- Hochberg MC. Updating the American College of Rheumatology revised criteria for the classification of systemic lupus erythematosus. *Arthritis Rheum* 1997;40:1725.
- Ganem D, Prince AM. Hepatitis B virus infection — natural history and clinical consequences. *N Engl J Med* 2004;350:1118-29.
- Joller-Jemelka HI, Wicki AN, Grob PJ. Detection of HBV antigen in "anti-HBc alone" positive sera. *J Hepatol* 1994;21:269-72.
- Zignego AL, Piluso A, Giannini C. HBV and HCV chronic infection: Autoimmune manifestations and lymphoproliferation. *Autoimmun Rev* 2008;8:107-11.
- Girard M. Autoimmune hazards of hepatitis B vaccine. *Autoimmun Rev* 2005;4:96-100.
- Nangaku M, Couser MG. Mechanisms of immune-deposit formation and the mediation of immune renal injury. *Clin Exp Nephrol* 2005;9:183-91.
- Bhimma R, Coovadia HM. Hepatitis B virus-associated nephropathy. *Am J Nephrol* 2004;24:198-211.
- Lin CY. Hepatitis B virus deoxyribonucleic acid in kidney cell probably leading to viral pathogenesis among hepatitis B virus associated membranous nephropathy patients. *Nephron* 1993; 63:58-64.
- Lai KN, Ho RT, Tam JS, Lai FM. Detection of hepatitis B virus DNA and RNA in kidney of HBV related glomerulonephritis. *Kidney Int* 1996;50:1965-77.
- Ren J, Wang L, Chen Z, Ma ZM, Zhu HG, Yang DL, et al. Gene expression profile of transgenic mouse kidney reveals pathogenesis of hepatitis B virus associated nephropathy. *J Med Virol* 2006;78:551-60.
- Lai FM, To KF, Wang AY, Choi PC, Szeto CC, Li PK, et al. Hepatitis B virus-related nephropathy and lupus nephritis: Morphologic similarities of two clinical entities. *Mod Pathol* 2000;13:166-72.