

# Power Doppler Ultrasonography Assessment of Entheses in Spondyloarthropathies: Response to Therapy of Enteseal Abnormalities

ESPERANZA NAREDO, ENRIQUE BATLLE-GUALDA, M. LUZ GARCÍA-VIVAR, ANGEL M. GARCÍA-APARICIO, JOSE LUIS FERNÁNDEZ-SUEIRO, MANUEL FERNÁNDEZ-PRADA, EMILIO GINER, MANUEL RODRIGUEZ-GOMEZ, MARIA FRANCISCA PINA, JULIO A. MEDINA-LUEZAS, FRANCISCO JAVIER TOYOS, CRISTINA CAMPOS, RICARDO GUTIÉRREZ-POLO, MIGUEL ANGEL FERRER, OLGA MARTÍNEZ, CESAR DÍAZ-TORNE, TERESA GONZALEZ, SERAFÍN CAMPOS, RUBÉN QUEIRO, MANUEL CASTAÑO-SÁNCHEZ, JUAN JOSÉ AZNAR, SAGRARIO BUSTABAD, MANUEL PAEZ-CAMINO, ROSER TUNEU, TERESA RUIZ, LOURDES MATEO, MANUEL PUJOL, ANDRÉS PONCE, INMACULADA ROS, ANGEL GALLEGOS, JUAN MORENO, DOMINGO GUMBAU, MANUELA SIANES, M. JOSE POVEDA-ELICES, MONTSERRAT ROMERO-GÓMEZ, and ENRIQUE RAYA; the Ultrasound Group of the Spanish Society of Rheumatology

**ABSTRACT. Objective.** To investigate the response to therapy of enteseal abnormalities assessed with power Doppler (PD) ultrasound (US) in spondyloarthropathies (SpA).

**Methods.** A total of 327 patients with active SpA who were starting anti-tumor necrosis factor (TNF) therapy were prospectively recruited at 35 Spanish centers. A PDUS examination of 14 peripheral entheses was performed by the same investigator in each center at baseline and at 6 months. The following elementary lesions were assessed at each entheses (presence/absence): morphologic abnormalities (hypoechoogenicity and/or thickening), enteseal calcific deposits, cortical abnormalities (bone erosion and/or proliferation), adjacent bursitis and intraentheses and perientheses (tendon body and/or bursa) PD signal. Response to therapy of each elementary lesion was assessed by calculating change in the cumulative presence from baseline to 6 months. Intraobserver reliability of PDUS was evaluated by blindly assessing the stored baseline images 3 months after the real-time examination.

**Results.** Complete data were obtained on 197 patients who received anti-TNF therapy for 6 months. In 91.4% of the patients there were gray-scale or PD elementary lesions at baseline and at 6 months. Cumulative enteseal morphologic abnormalities, intraentheses PD, perientheses PD, and bursitis showed a significant decrease from baseline to 6 months ( $p < 0.05$ ). There was high intraobserver reliability for all elementary lesions (interclass correlation coefficient  $> 0.90$ ,  $p < 0.0005$ ).

**Conclusion.** Enteseal morphologic abnormalities, PD signal, and bursitis were US abnormalities that were responsive to anti-TNF therapy in SpA. PDUS can be a reproducible method for multi-center monitoring of therapeutic response in enthesitis of SpA. (J Rheumatol First Release September 1 2010; doi:10.3899/jrheum.100136)

## Key Indexing Terms:

ULTRASONOGRAPHY  
THERAPY MONITORING

ENTHESITIS

SPONDYLOARTHROPATHIES  
ANTI-TUMOR NECROSIS FACTOR

From the Department of Rheumatology, Hospital Universitario Severo Ochoa, Madrid; Hospital Universitario de Alicante, Alicante; Hospital de Basurto, Bilbao; Hospital Virgen de la Salud, Toledo; Hospital Juan Canalejo, La Coruña; Hospital Universitario de Guadalajara, Guadalajara; Hospital Clínico Universitario Lozano Blesa, Zaragoza; Complejo Hospitalario Ourense, Ourense; Hospital Rafael Méndez, Lorca, Murcia; Complejo Hospitalario de Palencia, Palencia; Hospital Virgen Macarena, Sevilla; Hospital General Universitario de Valencia, Valencia; Clínica San Miguel, Pamplona; Hospital Universitario Virgen de las Nieves, Granada; Hospital Virgen de la Concha, Zamora; Hospital de la Santa Creu i Sant Pau, Barcelona; Instituto Provincial de Rehabilitación, Madrid; Hospital Virgen del Rocío, Sevilla; Hospital Universitario Central de Asturias, Oviedo; Hospital Virgen de la Arrixaca, Murcia; Hospital de Mérida, Mérida; Hospital Universitario de Tenerife, Tenerife; Hospital de Jerez, Jerez; Hospital Althaia Xarxa Assistencial de Manresa, Barcelona; Hospital Sierrallana, Santander; Hospital Germans Trias i Pujol, Badalona; Hospital Mutua de Terrassa, Barcelona; Hospital General de Granollers, Barcelona; Hospital Son

Llatzer, Palma de Mallorca; Hospital Universitario de Getafe, Madrid; Hospital Santa María del Rosell, Cartagena; Hospital de la Plana, Villarreal; Hospital General de Albacete, Albacete; Hospital Universitario de Tarragona Joan XXIII, Tarragona; Hospital Universitario Reina Sofía, Córdoba; Hospital Clínico San Cecilio, Granada, Spain.

Supported by a grant from Abbott Laboratories. Dr. Naredo has received an honorarium from Abbott Laboratories for coordinating this study.

E. Naredo, MD, Hospital Universitario Severo Ochoa; E. Batlle-Gualda, MD, PhD, Hospital Universitario de Alicante; M.L. García-Vivar, MD, Hospital de Basurto; A.M. García-Aparicio, MD, Hospital Virgen de la Salud; J.L. Fernández-Sueiro, MD, PhD, Hospital Juan Canalejo; M. Fernández-Prada, MD, Hospital Universitario de Guadalajara; E. Giner, MD, Hospital Clínico Universitario Lozano Blesa; M. Rodríguez-Gomez, MD, Complejo Hospitalario Ourense; M.F. Pina, MD, Hospital Rafael Méndez; J.A. Medina-Luezas, MD, Complejo Hospitalario de Palencia; F.J. Toyos, MD, Hospital Virgen Macarena; C. Campos, MD, Hospital

General Universitario de Valencia; R. Gutiérrez-Polo, MD, Clínica San Miguel; M.A. Ferrer, MD, PhD, Hospital Universitario Virgen de las Nieves; O. Martínez, MD, Hospital Virgen de la Concha; C. Díaz-Torne, MD, Hospital de la Santa Creu i Sant Pau; T. Gonzalez, MD, Instituto Provincial de Rehabilitación; S. Campos, MD, PhD, Hospital Virgen del Rocío; R. Queiro, MD, PhD, Hospital Universitario Central de Asturias; M. Castaño-Sánchez, MD, Hospital Virgen de la Arrixaca; J.J. Aznar, MD, Hospital de Mérida; S. Bustabad, MD, Hospital Universitario de Tenerife; M. Paez-Camino, MD, Hospital de Jerez; R. Tuneu, MD, Hospital Althaia Xarxa Assistencial de Manresa; T. Ruiz, MD, Hospital Sierrallana; L. Mateo, MD, PhD, Hospital Germans Trias i Pujol; M. Pujol, MD, PhD, Hospital Mutua de Terrassa; A. Ponce, MD, Hospital General de Granollers; I. Ros, MD, Hospital Son Llatzer; A. Gallegos, MD, Hospital Universitario de Getafe; J. Moreno, MD, Hospital Santa María del Rosell; D. Gumbau, MD, Hospital de la Plana; M. Sianes, MD, Hospital General de Albacete; M.J. Poveda-Elices, MD, Hospital Universitario de Tarragona Joan XXIII; M. Romero-Gómez, MD, Hospital Universitario Reina Sofía; E. Raya, MD, PhD, Hospital Clínico San Cecilio.

Address correspondence to Dr. E. Naredo, Hospital Universitario Severo Ochoa, Calle Arturo Soria 259, 4º A, 28033 Madrid, Spain.  
E-mail: esnaredo@ser.es

Accepted for publication June 3, 2010.

Entheses are the sites where tendons, ligaments, muscle, fascia, or joint capsules are attached to the bone<sup>1</sup>. Inflammation of entheses or enthesitis is a pathological feature of spondyloarthropathies (SpA)<sup>2,3</sup>. Histological studies on enthesitis have described local inflammation, fibrosis, erosion, and ossification. Inflammation of adjacent bursae may also occur in enthesitis<sup>1</sup>.

Enthesitis has been classically diagnosed by physical examination for the presence of subjective tenderness at enthesal areas. Conventional radiography shows chronic bone changes in enthesitis such as proliferation or erosions. Both magnetic resonance imaging (MRI) and ultrasound (US) allow us to objectively detect a spectrum of early and late changes in enthesitis<sup>4,5</sup>. MRI is limited for clinical use because of its limited availability and high cost. US with Doppler technique is a sensitive and reliable imaging modality for assessing morphological changes and abnormal blood flow at the peripheral entheses<sup>6,7,8,9,10,11,12,13</sup>. US has been shown to detect subclinical enthesitis, mainly in lower limbs of patients with SpA<sup>8,9,10,14,15</sup>. In addition, this technique is noninvasive, more widely available, relatively inexpensive, and patient-friendly in clinical practice.

Studies have described a number of gray-scale US abnormalities in peripheral entheses in SpA<sup>6,7,8,9,10,11,12,13,14,15</sup>. These have consisted of a loss of normal fibrillar echotexture, a decrease in enthesal echogenicity, an increase in enthesal thickness, calcific deposits at the insertion of the tendon, adjacent bursitis, periosteal formation, and bone erosions. In some studies, enthesal thickening, hypoechogenicity, echotexture abnormality, and bursitis have been considered signs of inflammation, whereas calcific deposits and bone abnormalities have been considered signs of consequent structural damage<sup>10,12,13</sup>. However, this classification of enthesal lesions has not been validated in any study.

The power Doppler (PD) technique has demonstrated its

capacity to detect abnormal vascularization at the enthesal and adjacent to the enthesal in SpA<sup>9,11,12,13,16</sup>. The presence of PD signal at the cortical bone insertion has not been found in healthy controls<sup>17</sup> and has been shown to be specific for peripheral SpA enthesitis<sup>9</sup>.

In 2005, the Outcome Measures in Rheumatology (OMERACT) group for musculoskeletal US defined enthesopathy as abnormally hypoechoic (loss of normal fibrillar architecture) and/or thickened tendon or ligament at its bony attachment (may occasionally contain hyperechoic foci consistent with calcification), seen in 2 perpendicular planes that may exhibit Doppler signal and/or bony changes including enthesophytes, erosions, or irregularity<sup>18</sup>. Various cross-sectional studies have proposed reliable US scoring systems of enthesitis, which have consisted of a variable sum of presence or grading of elementary lesions found in SpA entheses<sup>8,9,10,11,12,13,16</sup>. These scoring systems have been developed mainly for diagnostic purposes<sup>9,10,11</sup>. However, there are few longitudinal studies on the response to therapy of gray-scale or PD enthesal abnormalities in SpA<sup>19,20</sup>. Our multicenter study was undertaken to investigate the response to therapy and reproducibility of PDUS abnormalities in entheses of patients with active SpA who began anti-tumor necrosis factor (TNF) therapy.

## MATERIALS AND METHODS

This study was conducted by the Ultrasound Group of the Spanish Society of Rheumatology. Three hundred twenty-seven patients (230 men, 97 women) with SpA according to the European Spondylarthropathy Study Group criteria<sup>21</sup> or the criteria of Amor, *et al*<sup>22</sup> were prospectively recruited at 35 Spanish centers, from March 2007 to October 2008.

Patients were additionally classified as having ankylosing spondylitis (AS), according to the modified New York criteria<sup>23</sup>; reactive arthritis (ReA), according to the criteria of Willkens, *et al*<sup>24</sup>; psoriatic arthritis (PsA) or arthritis-associated inflammatory bowel disease (IBD) if psoriasis or IBD, respectively, was present; and undifferentiated SpA if the SpA criteria were fulfilled, but no diagnosis of AS, PsA, ReA, or arthritis-associated IBD could be established.

All patients were beginning therapy with a TNF-blocking agent, according to Spanish and international consensus on the use of biologic agents for the treatment of SpA<sup>25,26</sup>. The study was conducted in accord with the Declaration of Helsinki and was approved by the local ethics committees. Informed consent was obtained from all patients before study enrollment.

The patients underwent a clinical, laboratory, and PDUS evaluation at baseline and at 6 months. Therapeutic decisions were made throughout the follow-up period depending on the SpA clinical course without knowledge of the PDUS findings.

*Clinical and laboratory assessment.* Clinical data were obtained by a rheumatologist at each center who was blinded to the PDUS findings. The following data were recorded for each patient at study entry: age; sex; symptom duration; use of nonsteroidal antiinflammatory drugs (NSAID), corticosteroids, disease-modifying antirheumatic drugs (DMARD), and anti-TNF agents received for SpA; and HLA-B27 status. At each visit, the Spanish versions of the Bath Ankylosing Spondylitis Disease Activity Index (BASDAI) and the Bath Ankylosing Spondylitis Functional Index (BASFI) were recorded using visual analog scales. In addition, tenderness at 13 entheses [Maastricht Ankylosing Spondylitis Enthesitis Score (MASES)<sup>27</sup>] was investigated. Data on serum markers of inflammation, C-reactive protein (CRP) level (normal 0–10 mg/l), and erythrocyte sedi-

mentation rate (ESR; normal 10–20 mm/h) were obtained from laboratory tests performed within 48 hours of each clinical visit.

**PDUS assessment.** Patients underwent a PDUS assessment within 4 hours of each clinical evaluation by the same rheumatologist experienced in this technique at each center. These rheumatologists were unaware of the clinical and laboratory findings and were not involved in the treatment decisions. To reduce the possibility of bias, the patients were asked not to discuss their clinical symptoms with the US examiner, and the PDUS examination was carried out in a darkened room.

Systematic longitudinal and transverse multiplanar PDUS examination of 14 peripheral entheses was carried out with the same real-time scanner in all centers (Logiq 5 PRO; General Electric Healthcare, Kyunggi-do, Korea) using multifrequency linear array transducers (7–12 MHz). PDUS assessment included the following bilateral entheses: lateral epicondyle; medial epicondyle; quadriceps tendon; proximal patellar tendon; distal patellar tendon; Achilles tendon; and plantar fascia. US scanning technique, gray-scale and PD machine settings, and definitions of abnormality were standardized among investigators prior to the study. The PDUS scanning method is described in Table 1. The same gray-scale and PD settings were used at baseline and at followup for each enthesal site. The entheses at anatomic areas that had undergone surgical procedures were not evaluated.

PD assessment was performed by selecting a region of interest that included the bony margins, enthesal site, and a variable view of surrounding tissues. Pulse repetition frequency was adjusted to the lowest permissible value to maximize sensitivity. This setting resulted in pulse repetition frequency of 500 Hz. Low-wall filters were used. The dynamic range was 40 dB. Color gain was set just below the level at which color noise appeared underlying bone (no flow should be visualized at bony surfaces). This setting resulted in gains of 30 dB. Flow was additionally demonstrated in 2 planes and confirmed by pulse wave Doppler spectrum to exclude artefacts.

At each enthesis, the following elementary lesions were assessed (presence/absence): (1) enthesal morphologic abnormalities (i.e., hypoechogenicity and/or thickening); (2) enthesal calcific deposits; (3) enthesal cortical abnormalities (i.e., bone erosion and/or enthesophytes); (4) adjacent bursitis; (5) intraenthesal PD signal at the cortical bone insertion; and (6) perienthesal PD signal at tendon body and/or bursa. A cumulative score for each elementary lesion was calculated by summing separately the entheses that showed each of them.

Table 1. Power doppler ultrasound (PDUS) scanning method of the entheses.

Enthesis (bilateral)	Patient Position	Probe Placement
Common extensor tendon (lateral elbow epicondyle)	Sitting facing the examiner, with arms partially flexed on a table and palmar surfaces of hands together	Over the lateral epicondyle, in longitudinal and transverse position. In longitudinal position, with slight inclination of the distal portion of the probe oriented parallel to long axis of extensor muscles
Common flexor tendon (medial elbow epicondyle)	Sitting facing the examiner, with arms lying extended on a table, palms facing up	Over the medial epicondyle, in longitudinal and transverse position. In longitudinal position, with slight inclination of the distal end of the probe oriented parallel to long axis of flexor muscles
Quadriceps tendon (superior pole of patella)	Supine decubitus with the knee flexed 30° for GS and in neutral position for PD	Over the proximal pole of the patella, in longitudinal and transverse position
Proximal patellar tendon (inferior pole of patella)	Supine decubitus with the knee flexed 45° for GS and in neutral position for PD	Over the distal pole of the patella, in longitudinal and transverse position
Distal patellar tendon (anterior tibial tuberosity)	Supine decubitus with the knee flexed 45° for GS and in neutral position for PD	Over the anterior tibial tuberosity, in longitudinal and transverse position
Achilles tendon (superior pole of calcaneus)	Prone decubitus with the feet hanging outside the examination table in slight dorsal flexion for GS and in neutral position for PD	Over the posterior and superior aspect of the calcaneus, in longitudinal and transverse position
Plantar fascia (inferior aspect of calcaneus)	Prone decubitus with the feet hanging outside the examination table in slight dorsal flexion for GS and in neutral position for PD	Over the plantar aspect of the calcaneus, in longitudinal and transverse position

GS: gray-scale.

Enthesis thickening and hypoechogenicity were evaluated relative to the body of the tendon. Calcific deposit at the enthesis was defined as hyperechoic spots or lines at the preinsertional area of the tendons, with or without acoustic shadowing, seen in 2 perpendicular planes. Bone erosion was defined as a discontinuity of the enthesal bone surface, seen in 2 perpendicular planes. Entesophyte was defined as a hyperechoic prominence at the end of the enthesal bone contour, seen in 2 perpendicular planes. Bursitis was defined as a well circumscribed hypoechoic or anechoic collection at the site of an anatomic bursa.

**Intraobserver reliability of PDUS.** Intraobserver reliability of the PDUS assessment was evaluated by recording representative images from the full baseline examination of the patients included in the study. The stored images from each patient were evaluated under blinded conditions by the same investigator who performed the corresponding real-time PDUS examination a minimum of 3 months later.

**Statistical analysis.** Statistical analysis was performed using SPSS, version 13.0 (SPSS, Chicago, IL, USA). Quantitative variables were presented as the mean  $\pm$  SD and range. Paired-samples t test was used for comparing baseline and 6 month followup mean values for quantitative variables. McNemar's test was used for comparing baseline and 6 month percentages of enthesal abnormalities. Correlations between clinical, laboratory, and PDUS parameters were analyzed by Pearson's correlation coefficient.

Intraobserver reliability for each elementary lesion score was evaluated by calculating the intraclass correlation coefficient (ICC; 2-way mixed effects). An ICC value  $<$  0.40 was considered poor, 0.40–0.50 moderate, 0.50–0.70 good, and 0.70–1.0 excellent.

## RESULTS

**Patient characteristics.** Three hundred twenty-seven patients with SpA (230 men, 97 women; mean  $\pm$  SD age 44.5  $\pm$  11.3 yrs) who were starting therapy with adalimumab [264 (80.7%) patients], infliximab [33 (10.1%) patients], or etanercept [30 (9.2%) patients] were prospectively included in the study. Twenty-three patients (7%) had received 1 previous anti-TNF agent and 2 (0.6%) had received 2 previous biologic agents. These patients had been



switched to another TNF-blocking agent because of inefficacy (21 patients) or adverse effects (4 patients).

To homogenize the cohort, we analyzed data from only those patients who had received uninterrupted anti-TNF therapy for the 6 month followup period. Seventy (21.4%) patients were switched to another TNF-blocking agent during the study because of inefficacy [56 (17.1%) patients] or adverse effects [14 (4.3%) patients]. Sixty (18.3%) patients missed the followup visit. Complete clinical, laboratory, and PDUS data were obtained on 197 SpA patients (139 men, 58 women). The mean age of these patients was  $44.5 \pm 11.1$  years (range 18–74), and the mean disease duration was  $10 \pm 8.9$  years (range 0.2–50.3). One hundred thirty-five (68.5%) patients had been classified as having AS; 34 (17.3%) PsA; 16 (8.1%) undifferentiated SpA; 11 (5.6%) arthritis-associated IBD; and 1 (0.5%) ReA. One hundred thirty-three (67.5%) patients were HLA-B27-positive.

At inclusion to study, 39 patients (19.8%) were taking methotrexate, 25 (12.7%) were taking sulfasalazine, and 14 (7.2%) were taking other DMARD. One hundred eighty (91.4%) patients were taking NSAID, and 35 (17.8%) were taking prednisone. Three patients had undergone previous knee surgery.

**Disease activity and functional course.** A significant decrease in the mean BASDAI, BASFI, and MASES was found at the followup assessment ( $p < 0.0005$ ). At study entry, the mean BASDAI was  $5.83 \pm 1.48$  (range 2.1–9.2) and the mean BASFI was  $5.43 \pm 2.17$  (range 0–9.6). At 6 months, the mean BASDAI was  $3.22 \pm 2.16$  (range 0–9.4) and the mean BASFI was  $3.61 \pm 2.60$  (range 0–9.9). MASES decreased from  $3.96 \pm 3.22$  (range 0–12) at baseline to  $2.52 \pm 2.80$  (range 0–13) at 6 months (Table 2).

**PDUS abnormalities.** In 91.4% of the patients there were gray-scale or PD abnormalities at baseline and 6 months. These abnormalities were detected in a mean of  $5.7 \pm 3.8$  (range 0–14) entheses at baseline and in a mean of  $5.5 \pm 3.8$  (range 0–14) entheses at 6 months. The percentages of patients who showed each elementary lesion at any entheses

at baseline and 6 months are shown in Table 3. The overall frequency of each elementary lesion at each bilateral entheses at baseline and 6 months is shown in Table 4. A representative PDUS image of enthesal abnormalities in SpA is shown in Figure 1.

**Course of PDUS elementary lesions.** Mean changes in the cumulative elementary lesions from baseline to 6 months are shown in Table 2. The morphologic abnormality score, intraentheses PD score, and perientheses PD score showed a highly significant decrease from baseline to 6 months ( $p < 0.0005$ ). The adjacent bursitis score also decreased significantly ( $p = 0.036$ ), whereas the calcific deposit score and cortical abnormality score increased throughout the followup period. The total number of entheses that presented morphologic abnormalities, intraentheses PD, and perientheses PD decreased significantly from baseline to 6 months at most sites ( $p < 0.05$ ; Table 4). The overall numbers of bursitis adjacent to the Achilles tendon were also significantly reduced after 6 months of therapy ( $p = 0.036$ ; Table 4).

The elementary lesion scores and the clinical (BASDAI, BASFI, MASES) and laboratory (CRP, ESR) measures did not correlate at baseline and 6 months. There was no correlation between changes in the elementary lesion scores and changes in the clinical and laboratory variables throughout followup (data not shown).

**Intraobserver reliability of the PDUS assessment.** Table 5 shows the intraobserver ICC for each elementary lesion score. All ICC were significantly  $> 0.90$ , reflecting a high degree of intraobserver reliability.

## DISCUSSION

Peripheral enthesitis can be present in all SpA subtypes. It may be either a relevant clinical manifestation or it may be asymptomatic. Gray-scale US provides information on morphologic and structural involvement of entheses, and PDUS detects abnormal vascularization in the inflamed entheses<sup>6,7,8,9,10,11,12,13,14,15,16</sup>. In addition, asymptomatic enthesitis can be detected with US in SpA patients<sup>8,9,10,14,15</sup>.

Table 2. Changes in clinical measures and ultrasonography elementary lesion scores from baseline to 6 months.

Measure	Baseline, mean $\pm$ SD (range)	6 Months, mean $\pm$ SD (range)	p
BASDAI	$5.83 \pm 1.48$ (2.1–9.2)	$3.22 \pm 2.16$ (0–9.4)	$< 0.0005$
BASFI	$5.43 \pm 2.17$ (0–9.6)	$3.61 \pm 2.60$ (0–9.9)	$< 0.0005$
MASES	$3.96 \pm 3.22$ (0–12)	$2.52 \pm 2.80$ (0–13)	$< 0.0005$
Morphologic abnormality score	$2.19 \pm 2.66$ (0–11)	$1.34 \pm 2.02$ (0–12)	$< 0.0005$
Calcific deposit score	$1.11 \pm 1.63$ (0–9)	$1.23 \pm 1.79$ (0–9)	0.142
Cortical abnormality score	$3.92 \pm 3.73$ (0–14)	$4.17 \pm 3.86$ (0–14)	0.036
Adjacent bursitis score	$0.94 \pm 1.21$ (0–5)	$0.76 \pm 1.19$ (0–6)	0.036
Intraentheses Power Doppler score	$1.36 \pm 2.11$ (0–12)	$0.68 \pm 1.64$ (0–11)	$< 0.0005$
Perientheses Power Doppler score	$1.75 \pm 2.92$ (0–14)	$0.98 \pm 2.23$ (0–13)	$< 0.0005$

BASDAI: Bath Ankylosing Spondylitis Disease Activity Index; BASFI: Bath Ankylosing Spondylitis Functional Index; MASES: Maastricht Ankylosing Spondylitis Enthesitis Score.

Table 3. Percentage of patients who showed each elementary lesion at any entheses.

Elementary Lesion	Baseline (% of patients)	6 Months (% of patients)
Morphologic abnormalities	61.4	46.7
Calcific deposits	47.7	48.7
Cortical abnormalities	79.7	78.7
Adjacent bursitis	46.7	37.1
Intraentheses PD signal	47.2	26.9
Perientheses PD signal	57.9	29.9

PD: power Doppler.

Consequently, US imaging of entheses could be incorporated as a complementary procedure into the overall assessment of involvement and disease activity of SpA, as well as monitoring of response to therapy.

Investigators have proposed gray-scale and/or PD scoring systems for enthesitis based on cross-sectional studies in SpA<sup>8,9,10,11,12,13,16</sup>. These scoring systems have consisted of cumulative qualitative<sup>8,9,10,11,12,13</sup> and/or semiquantitative grading<sup>11,12,13,16</sup> of elementary lesions at selected entheses, most of them in the lower limbs in patients with SpA. They have been used to demonstrate diagnostic value for SpA<sup>9,10,11</sup>, reliability<sup>8,9,10,11,12,13,16</sup>, or correlation with clinical assessment of enthesitis<sup>16</sup>.

PDUS changes after anti-TNF therapy in heel entheses have been reported in a reduced number of patients with SpA<sup>20</sup>. However, to our knowledge, our study is the first that has separately evaluated response to therapy of differ-

ent PDUS abnormalities in a large multicenter cohort of patients with active SpA who were beginning anti-TNF therapy. This treatment has been widely demonstrated to be effective in SpA<sup>28,29,30,31</sup>.

For this study, we selected 14 peripheral entheses easily accessible to US and frequently chosen in previous studies<sup>6,7,8,9,10,11,12,13,14,15</sup>. Our results were in accord with previous studies that reported a high prevalence of abnormal US entheses findings in patients with SpA<sup>9</sup>.

We evaluated entheses hypoechoogenicity and thickening together, because both have been considered morphologic signs of acute inflammation<sup>13</sup>, and because both are essential elementary lesions in the OMERACT definition of enthesopathy<sup>18</sup>. We included bone erosions and enthesophytes in the same elementary lesions because both are chronic structural changes produced by inflammation, and because enthesophytes and erosions are easily misinterpreted when both are present at the entheses.

Morphologic abnormalities and PD signal demonstrated a highly significant improvement from baseline to 6 months of anti-TNF therapy. Bursitis adjacent to Achilles tendon also showed a significant improvement throughout followup. Calcific deposits and cortical abnormalities worsened throughout the followup period, in spite of the therapy. Our findings confirmed that morphologic abnormalities, PD signal, and bursitis can be considered active inflammatory lesions responsive to anti-TNF agents, whereas calcific deposits and cortical abnormalities should be considered structural damage not responsive to inflammation-targeted treatment.

Table 4. Changes in bilateral entheses involvement by each elementary lesion (EL) at baseline and at 6 months.

Visit, EL	LEPY, n (%)	MEPY, n (%)	QT, n (%)	PPT, n (%)	DPT, n (%)	ACHT, n (%)	PLF, n (%)
Baseline MA	59 (15)	25 (6.3)	62 (15.9)	58 (14.8)	72 (18.4)	113 (28.7)	43 (10.9)
6 mo MA	33 (8.4)	16 (4.1)	29 (7.4)	24 (6.1)	46 (11.8)	85 (21.6)	30 (7.6)
p	< 0.0005	0.064	< 0.0005	< 0.0005	< 0.0005	< 0.0005	0.041
Baseline CD	34 (8.6)	8 (2.0)	65 (16.6)	10 (2.6)	24 (6.1)	67 (17.0)	10 (2.5)
6 month CD	42 (10.7)	8 (2.0)	72 (18.4)	12 (3.1)	31 (7.9)	63 (16.0)	14 (3.6)
p	0.229	1.000	0.268	0.774	0.189	0.690	0.388
Baseline CA	111 (28.2)	43 (10.9)	161 (41.2)	74 (18.9)	95 (24.3)	200 (50.8)	87 (22.1)
6 month CA	109 (27.7)	52 (13.2)	167 (42.7)	86 (22.0)	95 (24.3)	208 (52.9)	105 (26.6)
p	0.878	0.064	0.471	0.065	1.000	0.289	0.004
Baseline AB	2 (0.5)	1 (0.3)	12 (3.1)	9 (2.3)	92 (23.5)	69 (17.5)	1 (0.3)
6 month AB	0 (0.0)	0 (0.0)	10 (2.6)	6 (1.5)	82 (21.0)	50 (12.7)	1 (0.3)
p			1.000	0.549	0.302	0.036	1.000
Baseline IPD	30 (7.6)	17 (4.3)	49 (12.5)	53 (13.6)	52 (13.3)	61 (15.5)	5 (1.3)
6 month IPD	16 (4.1)	10 (2.5)	31 (7.9)	18 (4.6)	26 (6.6)	30 (7.7)	2 (0.5)
p	0.020	0.118	0.008	< 0.0005	< 0.0005	< 0.0005	0.250
Baseline PPD	56 (14.2)	37 (9.4)	42 (10.7)	40 (10.2)	54 (13.8)	84 (21.3)	32 (8.1)
6 month PPD	25 (6.4)	22 (5.6)	24 (6.1)	26 (6.6)	33 (8.4)	49 (12.5)	15 (3.9)
p	< 0.0005	0.011	0.001	0.013	0.002	< 0.0005	0.001

MA: morphologic abnormalities; CD: calcific deposit; CA: cortical abnormalities; AB: adjacent bursitis; IPD: intraentheses power Doppler signal; PPD: perientheses power Doppler signal; LEPY: lateral epicondyle entheses; MEPY: medial epicondyle entheses; QT: quadriceps tendon entheses; PPT: proximal patellar tendon entheses; DPT: distal patellar tendon entheses; ACHT: Achilles tendon entheses; PLF: plantar fascia entheses.

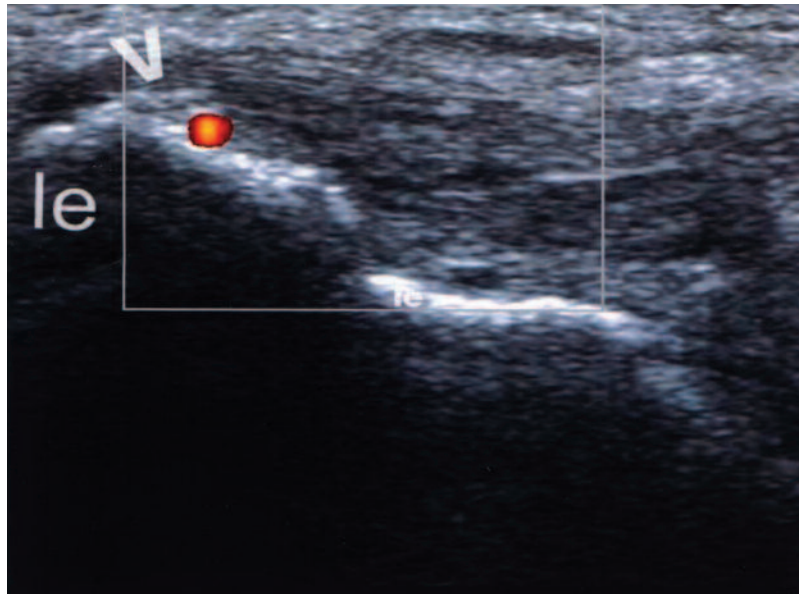


Figure 1. Longitudinal ultrasonography image of the common extensor tendon at the lateral epicondyle of the elbow. The enthesis shows abnormal thickening and hypoechoogenicity, calcific deposits (arrowhead), and intraentheses power Doppler signal. le: lateral epicondyle.

Table 5. Intraobserver reliability of the elementary lesion scores.

Scores	ICC (95% CI)	p
Morphologic abnormalities score	0.95 (0.930–0.958)	< 0.0005
Calcific deposit score	0.96 (0.948–0.968)	< 0.0005
Cortical abnormalities score	0.97 (0.966–0.979)	< 0.0005
Adjacent bursitis score	0.95 (0.936–0.961)	< 0.0005
Intraentheses power Doppler score	0.98 (0.979–0.987)	< 0.0005
Perienthesis power Doppler score	0.98 (0.977–0.986)	< 0.0005

ICC: intraclass correlation coefficient.

Intraentheses PD signal at the cortical bone insertion and perienthesis PD signal at tendon body and/or bursa were recorded independently in this study. The presence of PD signal at the cortical bone insertion has been shown to be a diagnostic hallmark of peripheral SpA enthesitis<sup>9</sup>. In the study by Morel, *et al*<sup>17</sup>, no vascularization was detected with contrast-enhanced US at the cortical bone insertion of normal heel enthesis, whereas some vascularization could be seen in proximity to these entheses. However, detection of flow at the cortical bone requires US machines with more sensitive Doppler technology than detection of perienthesis flow. In addition, the border of the true enthesis is not always easy to delimit with PDUS. Further studies should investigate if intraentheses PD signal has an added prognostic value over perienthesis PD signal in the outcome of SpA.

In keeping with other reports<sup>8,9,10,11,12,13,16</sup>, we obtained excellent PDUS reproducibility in image interpretation for all elementary lesions. Most previous studies have tested intraobserver and/or interobserver reliability on recorded US images<sup>8,9,11,16</sup>. Other investigators obtained good image

acquisition and interpretation reproducibility for detecting and scoring SpA enthesitis after standardization of the scanning technique, definition of abnormalities, and scoring system<sup>10,12,13</sup>.

Consistent with the previous findings<sup>8,10,15</sup>, we found no correlation between clinical and laboratory measures and PDUS abnormalities. As Lehtinen, *et al*<sup>19</sup> described in a cohort of SpA patients treated with sulfasalazine, changes in entheses abnormalities did not correlate with changes in clinical and laboratory measures. We did not take into account peripheral arthritis or axial involvement (e.g., sacroiliac joint) in the US assessment. Possibly due to this, there was no correlation between US entheses findings and clinical (BASDAI, BASFI) and laboratory (CRP, ESR) measures. It is noteworthy that, despite evaluation of different entheses, there was no correlation between MASES and PDUS findings. Responsive PDUS abnormalities seemed to be markers of SpA activity independent of conventional clinical and laboratory indicators.

Some limitations of our study should be noted. The study

was conducted in accord with daily clinical practice. In addition to anti-TNF therapy, patients were treated with NSAID and various DMARD at different dosage levels during the followup period. These differences in treatment could have introduced bias into the findings. However, since anti-TNF therapy was indicated because SpA remained active despite treatment with NSAID and DMARD, it may be accepted that changes in clinical and PDUS measures were due mainly to the anti-TNF treatment.

Intraobserver reliability was assessed on static images instead of on real-time US scanning. The absence of data on variability of US image acquisition may have overestimated our high reproducibility. In addition, interobserver reliability was not evaluated. However, the number of investigators involved in the study made it unfeasible to undertake real-time intraobserver-interobserver reliability assessment on SpA patients.

The objective of our study was to identify enthesal abnormalities that could be sensitive to change for monitoring response to therapy at the enthesis level in SpA. A semi-quantitative score of responsive enthesal abnormalities would probably have improved the sensitivity to change of PDUS assessment. However, appropriate training and implementation of agreed rules for semiquantitative scoring of elementary enthesal lesions was not feasible. Further longitudinal studies using semiquantitative scores of the responsive enthesal lesions are warranted.

Enthesal morphologic abnormalities, PD signal, and adjacent bursitis in SpA seem to be responsive PDUS abnormalities. Good reproducibility of PDUS for assessing abnormalities in SpA entheses, as previously reported, was also demonstrated in this multicenter study. Our results may contribute to development of a cumulative scoring system of combined semiquantitative responsive elementary lesions at the patient level that could be used to monitor therapeutic responses in patients with SpA.

## ACKNOWLEDGMENT

We thank the rheumatologists from the study centers who performed the clinical assessments. We gratefully acknowledge Dr. Jesús Garrido, Department of Methodology of the Universidad Autónoma de Madrid, for the statistical analysis.

## REFERENCES

1. D'Agostino MA, Olivieri I. Enthesitis. *Best Pract Res Clin Rheumatol* 2006;20:473-86.
2. McGonagle D, Khan MA, Marzo-Ortega H, O'Connor P, Gibbon W, Emery P. Enthesitis in spondyloarthropathy. *Curr Opin Rheumatol* 1999;11:244-50.
3. McGonagle D, Marzo-Ortega H, O'Connor P, Gibbon W, Hawkey P, Henshaw K, et al. Histological assessment of the early enthesitis lesion in spondyloarthropathy. *Ann Rheum Dis* 2002;61:534-7.
4. Eshed I, Bollow M, McGonagle DG, Tan AL, Althoff CE, Asbach P, et al. MRI of enthesitis of the appendicular skeleton in spondyloarthritis. *Ann Rheum Dis* 2007;66:1553-9.
5. Riente L, Delle Sedie A, Filippucci E, Iagnocco A, Meenagh G, Grassi W, et al. Ultrasound imaging for the rheumatologist IX. Ultrasound imaging in spondyloarthritis. *Clin Exp Rheumatol* 2007;25:349-53.
6. Kamel M, Eid H, Mansour R. Ultrasound detection of heel enthesitis: A comparison with magnetic resonance imaging. *J Rheumatol* 2003;30:774-8.
7. Kamel M, Eid H, Mansour R. Ultrasound detection of knee patellar enthesitis: A comparison with magnetic resonance imaging. *Ann Rheum Dis* 2004;63:213-4.
8. Balint PV, Kane D, Wilson H, McInnes IB, Sturrock RD. Ultrasonography of enthesal insertions in the lower limb in spondyloarthropathy. *Ann Rheum Dis* 2002;61:905-10.
9. D'Agostino MA, Said-Nahal R, Hacquard-Bouder C, Brasseur JL, Dougados M, Breban M. Assessment of peripheral enthesitis in the spondyloarthropathies by ultrasonography combined with power Doppler. *Arthritis Rheum* 2003;48:523-33.
10. Alcalde M, Acebes JC, Cruz M, González-Hombrado L, Herrero-Beaumont G, Sánchez-Pernaute O. A sonographic enthesitis index (SEI) at lower limbs is a valuable tool in the assessment of ankylosing spondylitis. *Ann Rheum Dis* 2007;66:1015-9.
11. De Miguel E, Cobo T, Muñoz-Fernández S, Naredo E, Usón J, Acebes JC, et al. Validity of enthesitis ultrasound assessment in spondyloarthropathy. *Ann Rheum Dis* 2009;68:169-74.
12. Filippucci E, Aydin SZ, Karadag O, Salaffi F, Gutierrez M, Direskeneli H, et al. Reliability of high-resolution ultrasonography in the assessment of Achilles tendon enthesopathy in seronegative spondyloarthropathies. *Ann Rheum Dis* 2009;68:1850-5.
13. D'Agostino MA, Aegerter P, Jousse-Joulin S, Chary-Valckenaere I, Lecoq B, Gaudin P, et al. How to evaluate and improve the reliability of power Doppler ultrasonography for assessing enthesitis in spondylarthritis. *Arthritis Rheum* 2009;61:61-9.
14. Lehtinen A, Taavitsainen M, Leirisalo-Repo M. Sonographic analysis of enthesopathy in the lower extremities of patients with spondylarthropathy. *Clin Exp Rheumatol* 1994;12:143-8.
15. Borman P, Koparal S, Babaoglu S, Bodur H. Ultrasound detection of enthesal insertions in the foot of patients with spondyloarthropathy. *Clin Rheumatol* 2006;25:373-7.
16. Kiris A, Kaya A, Ozgocmen S, Kocakoc E. Assessment of enthesitis in ankylosing spondylitis by power Doppler ultrasonography. *Skeletal Radiol* 2006;35:522-8.
17. Morel M, Boutry N, Demondion X, Legroux-Gerot I, Cotten H, Cotten A. Normal anatomy of the heel enthesitis: anatomical and ultrasonographic study of their blood supply. *Surg Radiol Anat* 2005;27:176-83.
18. Wakefield R, Balint PV, Szkudlarek M, Filippucci E, Backhaus M, D'Agostino MA, et al. Musculoskeletal ultrasound including definitions for ultrasonographic pathology. *J Rheumatol* 2005;32:2485-7.
19. Lehtinen A, Leirisalo-Repo M, Taavitsainen M. Persistence of enthesopathic changes in patients with spondyloarthropathy during a 6-month follow-up. *Clin Exp Rheumatol* 1995;13:733-6.
20. D'Agostino MA, Breban M, Said-Nahal R, Dougados M. Refractory inflammatory heel pain in spondylarthropathy: a significant response to infliximab documented by ultrasound. *Arthritis Rheum* 2002;46:840-1.
21. Dougados M, van der Linden SM, Jhulin R, Huitfeldt B, Amon B, Colin A, et al. The European Spondylarthropathy Study Group preliminary criteria for the classification of spondylarthropathy. *Arthritis Rheum* 1991;34:1218-27.
22. Amor B, Dougados M, Mijiyawa M. Criteria of the classification of spondylarthropathies [French]. *Rev Rhum Mal Osteoartic* 1990;57:85-9.
23. Van der Linden S, Valkenburg HA, Cats A. Evaluation of diagnostic criteria for ankylosing spondylitis: a proposal for modification of the New York criteria. *Arthritis Rheum* 1984;27:361-8.



24. Willkens RF, Arnett FC, Bitter T, Calin A, Fisher L, Ford DK, et al. Reiter's syndrome: evaluation of preliminary criteria for definite disease. *Arthritis Rheum* 1981;24:844-9.
25. Panel de Expertos de la Sociedad española de Reumatología. Primer documento de consenso de la Sociedad española de Reumatología sobre el uso de antagonistas del TNF- $\alpha$  en las espondiloartritis. *Reumatología Clínica* 2005;1:32-7.
26. Furst DE, Breedveld FC, Kalden JR, Smolen JS, Burmester GR, Emery P, et al. Updated consensus statement on biological agents for the treatment of rheumatic diseases, 2006. *Ann Rheum Dis* 2006;65 Suppl III:iii2-iii15.
27. Heuft-Dorenbosch L, Spoorenberg A, van Tubergen A, Landewe R, van der Tempel H, Mielants H, et al. Assessment of enthesitis in ankylosing spondylitis. *Ann Rheum Dis* 2003;62:127-32.
28. Coates LC, Cawkwell LS, Ng NW, Bennett AN, Bryer DJ, Fraser AD, et al. Real life experience confirms sustained response to long-term biologics and switching in ankylosing spondylitis. *Rheumatology* 2008;47:897-900.
29. Coates LC, Cawkwell LS, Ng NW, Bennett AN, Bryer DJ, Fraser AD, et al. Sustained response to long-term biologics and switching in psoriatic arthritis: results from real life experience. *Ann Rheum Dis* 2008;67:717-9.
30. Saad AA, Symmons DP, Noyce PR, Ashcroft DM. Risks and benefits of tumor necrosis factor-alpha inhibitors in the management of psoriatic arthritis: systematic review and metaanalysis of randomized controlled trials. *J Rheumatol* 2008;35:883-90.
31. Reed MR, Taylor AL. Tumour necrosis factor inhibitors in ankylosing spondylitis. *Intern Med J* 2008;38:781-9.