

# Ultrasound Elastography Assessment of Skin Involvement in Systemic Sclerosis: Lights and Shadows

ANNAMARIA IAGNOCCO, OLGA KALOUDI, CHIARA PERELLA, FRANCESCA BANDINELLI, VALERIA RICCIERI, MASSIMILIANO VASILE, FRANCESCO PORTA, GUIDO VALESINI, and MARCO MATUCCI-CERINIC

**ABSTRACT. Objective.** To assess skin elasticity in systemic sclerosis (SSc) by using a new imaging modality, ultrasound elastography (UE).

**Methods.** Our study included 18 consecutive patients with SSc and 15 healthy controls. Modified Rodnan skin score, physical examination, and assessment of organ involvement were performed. UE was carried out on the middle forearm and on the fingers of the dominant arm. The echo signals recorded in real time during freehand operations of probe compression and relaxation produced images representing tissue elasticity, consisting of translucent colored bands superimposed on the B-mode ultrasonographic images. The color scale varied within a large band spectrum from red, indicative of soft and highly elastic tissue, to blue, which denoted hard and barely elastic tissue.

**Results.** On the forearm of all patients, UE showed a homogeneous blue area corresponding to the dermis visualized in a B-mode ultrasonographic image; in controls, a blue pattern was never detected and a predominance of green with sporadic areas of pale blue was observed. At sequential evaluations, UE of fingers produced inconstant and changeable colored areas.

**Conclusion.** The imaging pattern observed in the forearm of patients with SSc may represent the reduction of strain in the dermis due to loss of elasticity. The variable pattern obtained by finger evaluation demonstrated that UE can assess skin involvement in SSc only in those areas where the dermis is known to be thicker and where the bone hyperreflection is minimal. Further studies are needed to confirm our results and determine the validity of this new imaging modality. (J Rheumatol First Release June 15 2010; doi:10.3899/jrheum.090974)

## Key Indexing Terms:

ULTRASOUND ELASTOGRAPHY

SYSTEMIC SCLEROSIS

SKIN

Systemic sclerosis (SSc) is characterized by progressive thickening and fibrosis of the skin and internal organs. The cutaneous involvement varies from limited to diffuse skin fibrosis<sup>1</sup>. High-frequency and high-resolution ultrasound probes offer the opportunity to evaluate not only skin thickness but also its echogenicity<sup>2</sup>. The mechanical properties of tissue depend on the constituent macromolecules, such as fat and collagen, and on the structural organization. Tissue elasticity is characterized by the degree of tissue displacement in response to compression in the axial direction. It cannot be assessed by conventional ultrasound. Considering

that echogenicity and the mechanical properties of body tissues are not correlated, a new tool to bridge the gap between ultrasound imaging and tissue structure and/or pathology, namely ultrasound elastography (UE), has been proposed and implemented<sup>3</sup>. UE is widely used in oncology to measure tissue elasticity, helping in the detection of malignant lesions and in the diagnosis and characterization of different types of cancer, such as breast, prostate, and thyroid<sup>4,5,6</sup>. It is considered a novel technique that can be used to assess tissue elasticity by detecting tissue deformities occurring after sequential movements of compression and relaxation determined by the operator through the ultrasound probe. UE allows noninvasive evaluation of tissue elasticity using conventional real-time ultrasound equipment with modified software. This technique is based on a high-speed processing algorithm, the combined autocorrelation method (CAM), which can estimate strain distribution<sup>7</sup>. According to this new modality, echo signals are recorded in real time while the probe compresses or relaxes the tissue through freehand operations. The strain profile is then converted into an elastic module with production of strain images representative of tissue elasticity, consisting of translucent colored bands that are superimposed on the B-mode ultrasonographic images<sup>8</sup>. In UE images, the color scale varies within a large band spectrum from red, which indicates a soft

From the Rheumatology Unit, Department of Clinical and Medical Therapy, Sapienza University of Rome; and Department of Biomedicine, Division of Rheumatology AOUC, Centre Denothe, University of Florence, Florence, Italy.

A. Iagnocco, MD, Assistant Professor of Rheumatology; C. Perella, MD; V. Riccieri, MD, Assistant Professor of Rheumatology; M. Vasile, MD; G. Valesini, MD, Full Professor of Rheumatology, Rheumatology Unit, Department of Clinical and Medical Therapy, Sapienza University of Rome; O. Kaloudi, MD; F. Bandinelli, MD; F. Porta, MD; M. Matucci-Cerinic, MD, Full Professor of Rheumatology, Department of Biomedicine, Division of Rheumatology AOUC, Centre Denothe, University of Florence.

Address correspondence to Prof. A. Iagnocco, Rheumatology Unit, Department of Clinical and Medical Therapy, Sapienza University, Viale del Policlinico 155, Rome 00161, Italy. E-mail: aiagnocco@tiscali.it  
Accepted for publication March 3, 2010.

and highly elastic tissue, to blue, which indicates a hard and barely elastic structure. The CAM algorithm conventionally uses a color scale ranging from red to blue. These 2 colors are positioned at the extremity of the scale to identify the softest tissue and the hardest tissue, respectively. The software identifies those specific colors. The new ultrasound image is then characterized by a superimposed composition of a translucent colored band produced by UE modality and a gray-scale image produced by conventional ultrasound.

On the basis of the presence of skin thickening and fibrosis in SSc, and considering that UE may evaluate tissue fibrosis and related elasticity, we investigated the role of UE in assessing skin involvement in SSc.

## MATERIALS AND METHODS

**Patients and controls.** Consecutive female patients with SSC, classified according to American College of Rheumatology criteria<sup>9</sup>, and healthy female controls were included in our study. Eighteen patients with SSC (10 presenting a diffuse form and 8 a limited form) and 15 age-matched controls were evaluated. Patients' mean age was 58.8 years (range 40–70) and mean disease duration was 202 months (range 36–328). Controls' mean age was 56.3 years (range 27–68).

Skin involvement was scored using the modified Rodnan skin score (mRSS), a standard measure for skin disease in SSc, calculated by summation of skin thickness in 17 different body sites (total score = 51). Patients underwent physical examination and assessment of organ involvement. The study was carried out in the outpatient clinic of the Rheumatology Unit of Sapienza University of Rome, Italy, and was conducted in compliance with good clinical practices. The study protocol was approved by the local Ethics Committee. Informed consent was obtained from all patients and controls.

**Imaging evaluation.** UE was performed using a HI Vision™ 8500 (Hitachi Medical Corp., Tokyo, Japan) machine equipped with the CAM algorithm and provided with an 18 MHz linear probe. The target sites of interest were

the skin of the volar aspect of the middle forearm and of the dorsal aspect of the fingers. Each UE examination was performed separately by 2 blinded sonographers who repeated each single examination twice. Then stored images obtained by each sonographer were evaluated separately by both operators. Each evaluation was then repeated, after an interval of 4 weeks, to calculate intraobserver and interobserver reliability.

UE evaluation was started after conventional ultrasound examination of the areas of interest, which was performed to identify the interface between the epidermis, dermis, and subcutis. Sonographic gel was applied to the skin, in order to provide an acoustic interface and to prevent local artifacts from interposition of air. The technique used to obtain the elastographic images consisted of 2 parts: at the beginning, attention was paid to not applying probe pressure on the anatomical structures under examination, to prevent artifacts due to excessive local compression and thus to obtain a high-quality elasticity image. Then we started the UE acquisition process, by giving the probe sequential presses, each movement having an amplitude of 1–2 mm. To limit the appearance of pressure artifacts, we considered that the appropriate width of movements of the probe should be minimal and the speed for sequential pressures should correspond to 1 or 2 actions/s.

The elastographic images were considered related to the degree of tissue elasticity in accordance with a color scale that varied from red to blue. In the interpretation of UE, red color conventionally indicates a soft and highly elastic tissue that is considered related to fluids, while blue color denotes a hard and scarcely elastic structure. Therefore we determined that intermediate colors such as green and pale blue were representative of soft dermis, while blue indicated hard dermis.

## RESULTS

Results of clinical assessment, physical evaluation, laboratory tests, and videocapillaroscopy are summarized in Table 1. Fourteen patients showed sclerodermic clinical involvement of their forearms according to the mRSS. On the forearm of all patients with SSc, with or without clinically detectable skin involvement, UE showed the presence of a

*Table 1.* Results of clinical assessment, physical evaluation, laboratory tests, and videocapillaroscopy in patients with SSc.

Patient	D/L	Cap	Fore	mRSS	Digital Ulcers	Tel	Pulmonary Fibrosis	PAH	ED	Antibody	ESR > 30	LC
1	D	Late	3	24	Yes	Yes	Yes	Yes	Yes	Scl70	Yes	Yes
2	D	Late	3	19	Yes	No	Yes	Yes	Yes	Scl70	No	No
3	D	Late	3	18	Yes	Yes	Yes	No	Yes	Scl70	No	Yes
4	D	Late	3	30	Yes	No	Yes	No	Yes	Scl70	No	No
5	L	Late	1	4	Yes	Yes	No	Yes	No	Centr	Yes	Yes
6	D	Late	3	16	Yes	Yes	No	No	Yes	Centr	No	No
7	L	Active	1	4	No	Yes	No	No	No	Centr	Yes	No
8	L	Late	1	12	Yes	Yes	Yes	Yes	Yes	Scl70	No	No
9	L	Active	1	12	No	Yes	Yes	No	No	Centr	No	No
10	D	Late	2	19	Yes	No	Yes	No	No	No	No	No
11	D	Active	0	13	No	Yes	No	No	Yes	Centr	No	No
12	D	Late	3	18	No	Yes	Yes	No	Yes	Scl70	Yes	No
13	L	Active	0	12	No	Yes	Yes	No	Yes	Centr	No	No
14	L	Active	0	6	Yes	Yes	Yes	No	Yes	Centr	No	No
15	L	Late	1	8	No	No	No	Yes	Yes	Centr	No	No
16	D	Late	3	20	No	Yes	Yes	No	Yes	Scl70	No	No
17	D	Late	3	20	Yes	No	Yes	Yes	Yes	Scl70	No	No
18	L	Early	0	2	No	No	No	No	Yes	Centr	No	No

SSc: systemic sclerosis; D/L: diffuse or limited involvement; Cap: capillaroscopic pattern; mRSS: modified Rodnan skin score for the forearm (Fore) and whole body; Tel: presence of telangiectasia; PAH: pulmonary arterial hypertension; ED: esophageal dysmotility; Antibody: presence of anticentromere (Centr) and anti-Scl-70 autoantibodies; ESR: erythrocyte sedimentation rate (> 30 mm/h); LC: low complement levels.

homogeneous blue area with either regular or minimally irregular margins corresponding to the dermis visualized in a B-mode ultrasonographic image (Figure 1a). In controls, a blue pattern was never detected and a predominance of green with sporadic areas of pale blue, corresponding to the dermis, was observed (Figure 1b). On the dorsal aspect of the fingers, both in patients and controls, the presence of inconstant and changeable colored areas, including red, green, pale blue, and blue, at sequential evaluations, were detected in the dermis.

The overall interobserver agreement between sonographers and the intraobserver reliability for the UE assessment of both patients and controls was 100% when the forearm was studied.

## DISCUSSION

Our study is the first investigation of the role of UE in the assessment of skin involvement in SSc. Recently, UE has

been used in the diagnosis of breast, thyroid, and prostate cancer, lymph node metastasis, liver fibrosis<sup>4,5,6,10</sup>, musculoskeletal disorders<sup>11</sup>, and skin diseases. UE has been used in particular in differentiation between benign and malignant lesions<sup>12</sup>.

SSc is characterized by reduced dermal elasticity due to changes in excessive dermal deposition of collagen and changes in the architecture of connective tissue, leading to skin thickness and fibrosis<sup>13</sup>. In all our patients with SSc, UE showed, independently from the disease subset or the presence of clinically detectable skin involvement of the forearms, a clear homogeneous blue color pattern in the dermal area. The blue color, according to the elastographic semiology, may be due to the presence of hard and inelastic tissue. In the UE color scale, the blue color identifies hard structures that in SSc are clearly correlated to fibrosis. In our patients, the homogeneous blue band in the anterior forearm may represent the reduction of dermal elasticity linked to

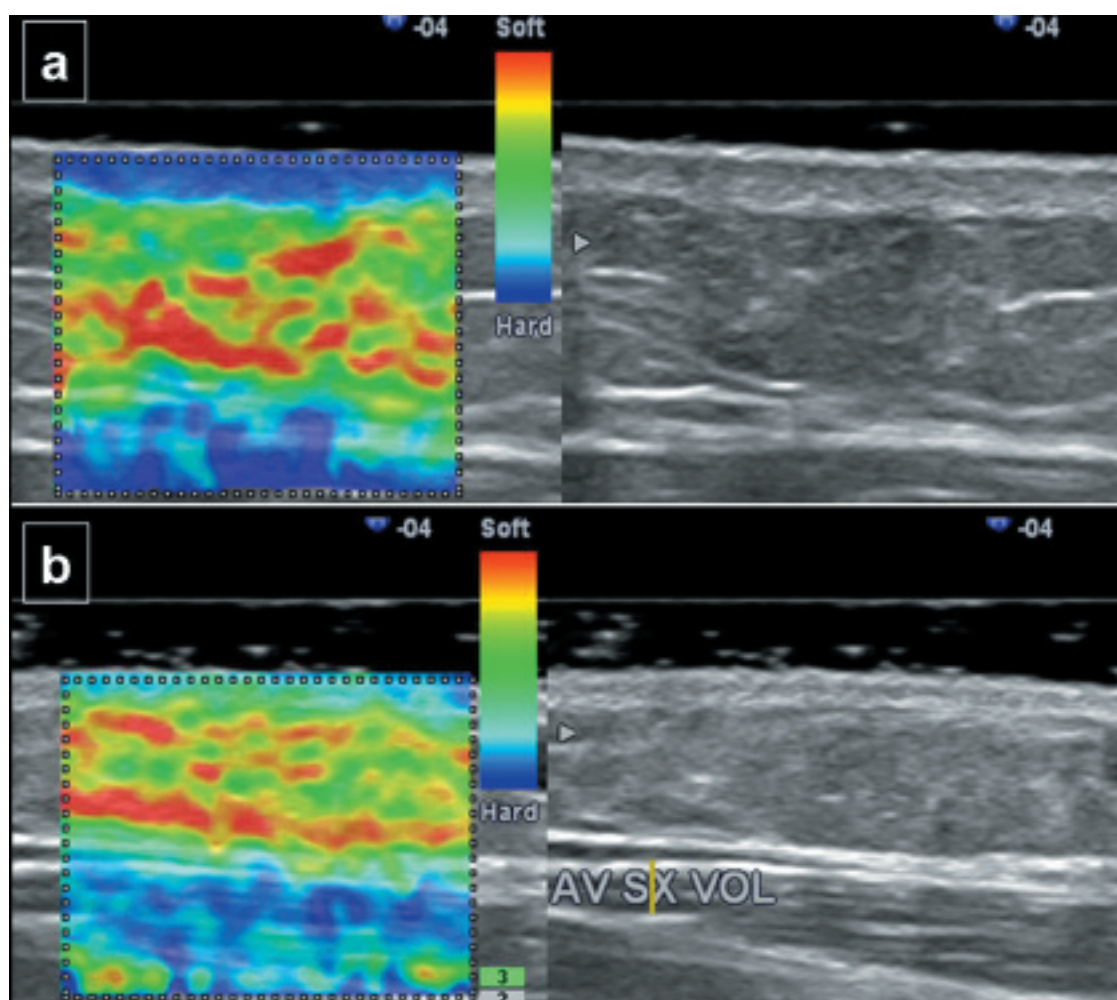


Figure 1. Ultrasound elastography of the volar aspect of the middle forearm in a patient with SSc (a) and in a healthy subject (b). On the left side of (a), a homogeneous blue area with regular margins appears to perfectly correspond to the dermis visualized in B-mode ultrasound (right side). The left side of (b) shows a predominance of green and sporadic areas of pale blue, corresponding to the dermis visualized in B-mode ultrasound (right side).

fibrotic tissue. In controls, the colors green and pale blue were prevalent, identifying healthy and elastic tissue.

It must be pointed out that skin UE has some technical limitations. Digital evaluation with UE has shown a color variability that may be due not only to the involvement of the dermal tissue but also to the prevalence of the bone profile of the phalanx within the elastographic field. The bone may interfere with correct functioning of the elastographic algorithm, compromising the correct evaluation of dermal elasticity in this area. This may be an obstacle for a correct representation of digital structures, suggesting that UE may not be a reliable tool to evaluate tissue elasticity of fingers affected by the disease. Thus, the variable pattern obtained by finger evaluation demonstrates that UE may consistently assess SSc skin involvement only in areas where the dermis is highly represented and where the bone hyperreflection is absent or minimal.

In our patients, similar UE elastographic images were obtained on the forearms independent of clinical evidence of skin involvement. These results need to be confirmed in larger cohorts, to verify whether UE may identify dermal edematous or fibrotic involvement, even in clinically asymptomatic early patients.

Owing to these apparently contrasting results, further studies are needed to confirm our findings and to determine the validity of this new imaging modality. In larger cohorts of patients with SSc, more comprehensive and extended data on other skin areas, in different phases of the disease, and in different SSc subsets are required to establish the contribution of UE in the assessment of dermal changes and tissue elasticity. In particular, a correlation with histopathologic findings, to determine the criterion validity of UE, is strongly warranted.

## REFERENCES

1. Gu YS, Kong J, Cheema GS, Keen CL, Wick G, Gershwinet ME. The immunobiology of systemic sclerosis. *Semin Arthritis Rheum* 2008;38:132-60.
2. Hesselstrand R, Scheja A, Wildt M, Akesson A. High-frequency ultrasound of skin involvement in systemic sclerosis reflects oedema, extension and severity in early disease. *Rheumatology* 2008;47:84-7.
3. Yu-Mee S, Min JK, Eun-Kyung K, Jin YK, Hee JM, Soo JK. Sonographic elastography combined with conventional sonography. How much is it helpful for diagnostic performance? *J Ultrasound Med* 2009;28:413-20.
4. Itoh A, Ueno E, Tohno E. Breast disease: clinical application of US elastography for diagnosis. *Radiology* 2006;239:341-50.
5. Miyagawa T, Tsutsumi M, Matsumura T. Real-time elastography for the diagnosis of prostate cancer: evaluation of elastographic moving images. *Jpn J Clin Oncol* 2009;39:394-8.
6. Asteria C, Giovanardi A, Pizzocaro A, Cozzaglio L, Morabito A, Somalvico F, et al. US-elastography in the differential diagnosis of benign and malignant thyroid nodules. *Thyroid* 2008;18:523-31.
7. Rivaz H, Boctor E, Foroughi P, Zellars R, Fichtinger G, Hager G. Ultrasound elastography: a dynamic programming approach. *IEEE Trans Med Imaging* 2008;27:1373-7.
8. Bae U, Kim Y. Angular strain estimation method for elastography. *IEEE Trans Ultrason Ferroelectr Freq Control* 2007;54:2653-61.
9. Subcommittee for scleroderma criteria of the American Rheumatism Association Diagnostic and Therapeutic Criteria Committee. Preliminary criteria for the classification of systemic sclerosis (scleroderma). *Arthritis Rheum* 1980;23:581-90.
10. Alam F, Naito K, Horiguchi J, Fukuda H, Tachikake T, Ito K. Accuracy of sonographic elastography in the differential diagnosis of enlarged cervical lymph nodes: comparison with conventional B-mode sonography. *AJR Am J Roentgenol* 2008;191:604-10.
11. Nordez A, Gennisson JL, Casari P, Catheline S, Cornu C. Characterization of muscle belly elastic properties during passive stretching using transient elastography. *J Biomech* 2008;41:2305-11.
12. Gennisson JL, Baldeweck T, Tanter M, Catheline S, Fink M, Sandrin L, et al. Assessment of elastic parameters of human skin using dynamic elastography. *IEEE Trans Ultrason Ferroelectr Freq Control* 2004;51:980-9.
13. Verrecchia F, Laboureaux J, Verola O, Roos N, Porcher R, Brunevalet P, et al. Skin involvement in scleroderma — where histological and clinical scores meet. *Rheumatology* 2007; 46:833-41.