

High Serum Cartilage Oligomeric Matrix Protein Determines the Subset of Patients with Early-Stage Rheumatoid Arthritis with High Serum C-Reactive Protein, Matrix Metalloproteinase-3, and MRI-Proven Bone Erosion

KEITA FUJIKAWA, ATSUSHI KAWAKAMI, MAMI TAMAI, MASATAKA UETANI, SHOICHIRO TAKAO, KAZUHIKO ARIMA, NAOKI IWAMOTO, TOSHIYUKI ARAMAKI, SHINYA KAWASHIRI, KUNIHIRO ICHINOSE, MAKOTO KAMACHI, HIDEKI NAKAMURA, TOMOKI ORIGUCHI, HIROAKI IDA, KIYOSHI AOYAGI, and KATSUMI EGUCHI

ABSTRACT. Objective. To identify the significance of serum cartilage oligomeric matrix protein (COMP), a marker of cartilage turnover, in patients with early-stage rheumatoid arthritis (RA) in relation to other serologic variables and magnetic resonance imaging (MRI) features.

Methods. Ninety-eight patients with early-stage RA, whose disease duration from onset was less than 2 years, were enrolled. The objective measures at baseline were Disease Activity Score (DAS28), serum C-reactive protein (CRP), serum matrix metalloproteinase-3 (MMP-3), serum antibodies against cyclic citrullinated peptide (anti-CCP), and MRI features of both wrist and finger joints. The MRI features included the number of sites scored positive for synovitis, bone edema, and bone erosion.

Results. Serum COMP concentration was not different among groups identified with low, moderate, and high DAS28-CRP values. However, COMP values were statistically high in subjects positive for bone erosions on MRI compared with the subjects who were negative for bone erosions. A positive correlation of COMP with CRP and with MMP-3 values was also identified.

Conclusion. Elevation of COMP may reflect joint damage that is dependent on the synovial inflammatory process in early-stage RA. (J Rheumatol First Release May 15 2009; doi:10.3899/jrheum.080926)

Key Indexing Terms:

EARLY-STAGE RHEUMATOID ARTHRITIS CARTILAGE OLIGOMERIC MATRIX PROTEIN
C-REACTIVE PROTEIN MATRIX METALLOPROTEINASE-3
BONE EROSION MAGNETIC RESONANCE IMAGING
ANTI-CYCLIC CITRULLINATED PEPTIDE ANTIBODIES

Synovitis in the context of rheumatoid arthritis (RA) leads to pathologic changes in adjacent structures, such as the articular cartilage, the cortical bone surfaces, and the underlying bone marrow, changes that have recently been verified by comparison of magnetic resonance images (MRI) on the day before surgery and the tissue specimens at joint replacement surgery (metacarpophalangeal or proximal interpha-

langeal joints) in patients with established RA¹. These findings were obtained in patients with late-stage RA. A similar process should be occurring in early-stage RA, but it is very difficult to prove, since joint replacement surgery is performed infrequently in cases of early-stage RA. In contrast, qualifying pathologic features in the rheumatoid inflammatory process by serologic variables and MRI is recommend-

From the Unit of Translational Medicine, Department of Immunology and Rheumatology; Department of Radiology and Radiation Research; and Department of Public Health, Graduate School of Biomedical Sciences, Nagasaki University School of Health Sciences, Nagasaki, Japan.

Supported by a grant from The Ministry of Health, Labour and Welfare, Japan.

K. Fujikawa MD, PhD; A. Kawakami, MD, PhD; M. Tamai, MD, PhD, Unit of Translational Medicine, Department of Immunology and Rheumatology; M. Uetani, MD, PhD; S. Takao, MD, PhD, Department of Radiology and Radiation Research; K. Arima, MD, PhD; N. Iwamoto, MD; T. Aramaki, MD, PhD; S. Kawashiri, MD; K. Ichinose, MD, PhD; M. Kamachi, MD, PhD; H. Nakamura, MD, PhD, Unit of Translational

Medicine, Department of Immunology and Rheumatology; T. Origuchi, MD, PhD, Department of Public Health, Graduate School of Biomedical Sciences; H. Ida, MD, PhD, Unit of Translational Medicine, Department of Immunology and Rheumatology; K. Aoyagi, MD, PhD, Department of Public Health, Graduate School of Biomedical Sciences; K. Eguchi, MD, PhD, Unit of Translational Medicine, Department of Immunology and Rheumatology, Nagasaki University School of Health Sciences.

Address reprint requests to Prof. K. Eguchi, Unit of Translational Medicine, Department of Immunology and Rheumatology, Graduate School of Biomedical Sciences, Nagasaki University, 1-7-1 Sakamoto, Nagasaki 852-8501, Japan. E-mail: eguchi@net.nagasaki-u.ac.jp

Accepted for publication December 3, 2008.

ed in early-stage patients rather than late-stage patients, since there may be fewer secondary disease process-independent phenomena in early-stage patients. We recently reported that MRI-proven synovitis, bone edema, and bone erosion in the wrist and finger joints in early-stage RA reflect systemic inflammatory indices of serum C-reactive protein (CRP) and serum matrix metalloproteinase-3 (MMP-3)².

An interesting serum biomarker is cartilage oligomeric matrix protein (COMP), which is thought to be increased in the serum early in the course of RA as a sign of cartilage involvement³. However, it is difficult to identify early cartilage involvement by radiography, even in MRI. Thus, the estimation of early cartilage involvement in early-stage RA using established variables, including COMP, would be valuable for prognostication. Our study is the first report to qualify serum COMP values in patients with early-stage RA, in conjunction with other inflammatory indices, as well as MRI detection of early joint damage.

MATERIALS AND METHODS

Ninety-eight patients with early stage RA were enrolled from the Early Arthritis Clinic at the Unit of Translational Medicine, Department of Immunology and Rheumatology (First Department of Internal Medicine), Graduate School of Biomedical Sciences, Nagasaki University. They gave their informed consent to the protocol, which was approved by the Institutional Review Board of Nagasaki University.

The mean disease duration from onset of symptoms to entry was 4.9 months. Disease duration for each of the 98 patients was < 2 years, similar to other recent reports^{3,4}. Baseline characteristics of the 98 patients are described in Table 1. All patients fulfilled the 1987 criteria of the American

College of Rheumatology for RA⁵. Since serum COMP is reported to be high in patients with osteoarthritis (OA) of large joints^{6,7}, we excluded the cases complicated with OA of hip or knee joint, classified according to the established criteria^{8,9}.

The following variables were examined at entry. Serologic tests included COMP (COMP ELISA[®], AnaMar Medical AB, Göteborg, Sweden), CRP (Eiken Chemical Co. Ltd., Tokyo, Japan), MMP-3 (Daiichi Pure Chemicals, Fukuoka, Japan), and anti-CCP antibodies (Diastat Anti-CCP, Axis-Shield, Dundee, UK; cutoff value 4.5 U/ml). Clinical disease activity was qualified by the Disease Activity Score (DAS28-CRP; high disease activity > 4.1, low disease activity < 2.7, remission < 2.3)¹⁰. MR images of both wrists and finger joints (1.5 Tesla Sigma device; GE Medical Systems, Milwaukee, WI, USA) were evaluated for bone edema, bone erosion, and synovitis in 15 sites in each finger and wrist, i.e., the distal radioulnar joint, radiocarpal joint, mid-carpal joint, first carpometacarpal joint, second–fifth carpometacarpal joint (together), and first–fifth metacarpophalangeal joints (proximal interphalangeal joints) separately (a total of 30 sites in both hands), as we reported^{2,11,12}. The MR images were interpreted independently by 2 board certified radiologists experienced in musculoskeletal imaging (MU and ST), who were blinded to the clinical status of the patients. Both radiologists read each image according to the definition, as described^{13,14}, and disagreements were resolved by consensus. The degree of MRI features was evaluated as we recently published: synovitis; the number of sites scored as positive for MRI synovitis, bone edema; number of bones scored positive for bone edema, bone erosion; and number of bones scored positive for MRI bone erosion².

Serum COMP concentration, in general, is reported to be elevated with age³, as we found in the 98 patients with early-stage RA we examined ($r = 0.39$, $p < 0.001$). Thus, a partial correlation coefficient adjusting for age was calculated. Since MMP-3 was not normally distributed, we conducted logarithmic transformation. Differences between groups were examined using the age-adjusted mean. A test for trend was performed using the general linear modeling method. A p value < 0.05 denoted the presence of a statistically significant difference.

RESULTS

Table 1 shows the baseline characteristics of the 98 patients. Briefly, the median DAS28-CRP at entry was 4.3. Forty-seven percent of subjects were positive for MRI-proven bone edema, and 33% were positive for bone erosions. The median serum COMP at entry was 10.3 U/ml, median titer of anti-CCP antibodies was 20.3 U/ml, and seropositivity to anti-CCP antibodies was found in 66% of subjects. For MMP-3, the median serum concentration was 66.6 ng/ml, and seropositivity for MMP-3, denoted as in the higher than normal range, was 42%. As described³, a positive correlation was found between serum COMP value and age in the 98 patients ($r = 0.39$, $p < 0.001$, Spearman's rank correlation test), and thus a partial correlation coefficient adjusting for age was calculated in the following data, as described above.

A partial correlation coefficient adjusting for age showed positive correlation of COMP with CRP ($r = 0.21$, $p = 0.035$) as well as MMP-3 values ($r = 0.20$, $p = 0.046$). Although the difference was not statistically significant, a weak association was determined between the number of MRI-proven bone erosions and the serum COMP ($r = 0.19$, $p = 0.06$). Therefore, we divided the 98 patients into 2 groups according to the MRI-proven bone erosions, and examined the distribution of serum COMP. Figure 1 shows that the age-adjusted mean concentration of serum COMP

Table 1. Baseline characteristics of the 98 patients with early-stage RA.

Age, yrs (range)	53 (16–80)
No. female/male	77/21
Duration of disease, mo (range)	3 (1.5–24)
Tender joint count, n (range)	6 (0–28)
Swollen joint count, n (range)	3 (0–24)
Global health, 100 mm VAS (range)	50.5 (0–100)
DAS28-CRP (range)	4.3 (2.1–8.2)
MRI	
Synovitis positivity, %	90
n (range)	11.5 (0–30)
Bone edema positivity, %	47
n (range)	0 (0–15) mean 2.1
Bone erosion positivity, %	33
n (range)	0 (0–11) mean 1.3
Serologic markers	
COMP, U/l (range)	10.3 (0.6–24.9)
CRP positivity, %	66
Titer, mg/dl (range)	0.52 (0.02–12.7)
Anti-CCP antibody positivity, %	66
Titer U/ml (range)	23 (0.2–2115.3)
MMP-3 positivity, %	42
Titer, ng/ml (range)	66.6 (12.5–1160)

VAS: visual analog scale, COMP: cartilage oligomeric matrix protein, MRI: magnetic resonance imaging, CRP: C-reactive protein, CCP: citric citrullinated peptide, MMP: matrix metalloproteinase.

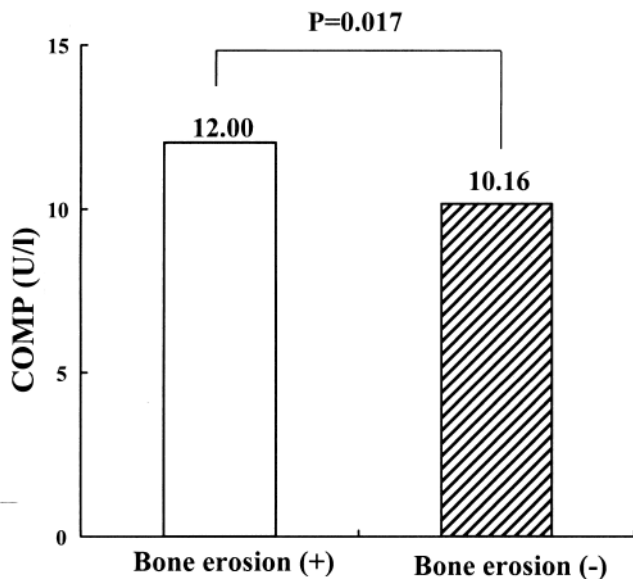


Figure 1. The age-adjusted mean serum COMP concentration was high in subjects with MRI-proven bone erosions (n = 32) compared to those without bone erosions (n = 66).

was statistically significantly high in the subjects who were positive for bone erosions on MRI, compared with subjects who were negative for erosions. As suspected, the mean values of CRP and MMP-3 were also high in the subjects who were positive for bone erosions on MRI (data not shown). We also examined the distribution of serum COMP by DAS28-CRP, and observed no differences among subjects who had low, moderate, and high DAS28-CRP scores (Figure 2). A test for trend showed no association between serum COMP and DAS28-CRP ($p = 0.31$). In addition, the

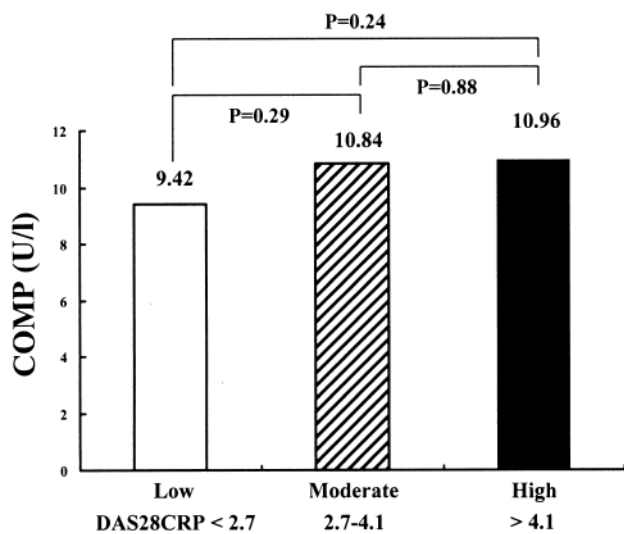


Figure 2. Serum COMP values of 98 patients with early-stage RA were not different among those with low, moderate, and high scores for DAS28-CRP. P value between the groups was calculated by age-adjusted mean. P value was nonsignificant.

age-adjusted mean concentration of serum COMP was not statistically different between subjects with different anti-CCP antibody status (mean COMP concentration was 10.54 U/I in subjects who were anti-CCP antibody-positive; and 11.26 U/I in subjects who were anti-CCP antibody-negative; $p = 0.36$).

DISCUSSION

COMP is a marker of articular cartilage damage, originally described as the determinant of radiographic progression in OA of the large joints, such as hip OA and knee OA^{6,7,15}. Recently, serum COMP was evaluated in patients with RA, and was found to be preferentially elevated not in late-stage RA but in early-stage RA³. In addition, high serum COMP at baseline in early-stage RA indicates future radiographic progression³. The serum COMP concentration at baseline may also reflect the therapeutic efficacy of radiography in patients with active RA: low COMP at baseline predicted a better radiographic outcome in clinical trials of adalimumab treatment in RA¹⁶. We have investigated the role of serologic variables as well as MRI features of the wrist and fingers in early-stage RA^{2,11,12}; in the present study we focused on the serum COMP value. MR images of the small joints in the wrist and fingers were closely examined, and thus patients with early-stage RA with clinically definite large-joint OA (hip and knee OA) were excluded, since a large amount of COMP could be produced from the affected articular cartilage, which might weaken the significance of the RA-related COMP value.

We initially expected COMP values to correlate with bone damage-prone markers, such as MMP-3, and MRI-proven bone edema and erosion. Raw data also showed an association of COMP with the number of MRI-proven bone erosions ($r = 0.33$, $p = 0.02$); however, age-adjusted data identified statistically significant association of COMP with only CRP and MMP-3. Since rheumatoid bone and cartilage damage are suggested to be driven by the neighboring synovial tissues¹, it was recognized that the inflammatory index provided by CRP and MMP-3 correlates with the cartilage turnover marker COMP. In addition, the findings that COMP concentrations were higher in the subjects with MRI-proven bone erosions than in those without erosions may support the speculation that rheumatoid synovial inflammation promotes articular cartilage turnover *in situ* in early-stage RA. Our findings that CRP and MMP-3 levels were high in the subjects with MRI-proven bone erosions also support this. Our recent study showed that MRI-proven bone edema, in early-stage RA, was significantly correlated with inflammatory indexes and DAS², but in the present study we did not see a relationship between the serum COMP value and MRI-proven bone edema. These observations may indicate that COMP reflects another aspect of the disease process of RA, which should be confirmed by our continuing prospective study.

This is the first report to investigate the significance of the relation of serum COMP value with MRI detection of early joint damage in early-stage RA. Serum COMP values at entry correlated with CRP and MMP-3 values, and MRI-proven bone erosion also predicted high serum COMP concentrations in study subjects.

REFERENCES

1. Jimenez-Boj E, Nöbauer-Huhmann I, Hanslik-Schnabel B, et al. Bone erosions and bone marrow edema as defined by magnetic resonance imaging reflect true bone marrow inflammation in rheumatoid arthritis. *Arthritis Rheum* 2007;56:1118-24.
2. Tamai M, Kawakami A, Uetani M, et al. Bone edema determined by magnetic resonance imaging reflects severe disease status in patients with early-stage rheumatoid arthritis. *J Rheumatol* 2007;34:2154-7.
3. Lindqvist E, Eberhardt K, Bendtzen K, et al. Prognostic laboratory markers of joint damage in rheumatoid arthritis. *Ann Rheum Dis* 2005;64:196-201.
4. van Gaalen FA, van Aken J, Huizinga TW, et al. Association between HLA class II genes and autoantibodies to cyclic citrullinated peptides (CCPs) influences the severity of rheumatoid arthritis. *Arthritis Rheum* 2004;50:2113-21.
5. Arnett FC, Edworthy SM, Bloch DA, et al. The American Rheumatism Association 1987 revised criteria for the classification of rheumatoid arthritis. *Arthritis Rheum* 1988;31:315-24.
6. Sharif M, Kirwan JR, Elson CJ, et al. Suggestion of nonlinear or phasic progression of knee osteoarthritis based on measurements of serum cartilage oligomeric matrix protein levels over five years. *Arthritis Rheum* 2004;50:2479-88.
7. Kelman A, Lui L, Yao W, et al. Association of higher levels of serum cartilage oligomeric matrix protein and N-telopeptide crosslinks with the development of radiographic hip osteoarthritis in elderly women. *Arthritis Rheum* 2006;54:236-43.
8. Altman R, Alarcon G, Appelrouth D, et al. The American College of Rheumatology criteria for the classification and reporting of osteoarthritis of the hip. *Arthritis Rheum* 1991;34:505-14.
9. Altman R, Asch E, Bloch DA, et al. Development of criteria for the classification and reporting of osteoarthritis. Classification of osteoarthritis of the knee. Diagnostic and Therapeutic Criteria Committee of the American Rheumatism Association. *Arthritis Rheum* 1986;29:1039-49.
10. Inoue E, Yamanaka H, Hara M, et al. Comparison of Disease Activity Score (DAS)28-erythrocyte sedimentation rate and DAS28-C-reactive protein threshold values. *Ann Rheum Dis* 2007;66:407-9.
11. Tamai M, Kawakami A, Uetani M, et al. The presence of anti-cyclic citrullinated peptide antibody is associated with magnetic resonance imaging detection of bone marrow oedema in early stage rheumatoid arthritis. *Ann Rheum Dis* 2006;65:133-4.
12. Tamai M, Kawakami A, Uetani M, et al. Early prediction of rheumatoid arthritis by serological variables and magnetic resonance imaging of the wrists and finger joints: results from prospective clinical examination. *Ann Rheum Dis* 2006;65:134-5.
13. McQueen FM, Benton N, Perry D, et al. Bone edema scored on magnetic resonance imaging scans of the dominant carpus at presentation predicts radiographic joint damage of the hands and feet six years later in patients with rheumatoid arthritis. *Arthritis Rheum* 2003;48:1814-2.
14. Conaghan PG, O'Connor P, McGonagle D, et al. Elucidation of the relationship between synovitis and bone damage: a randomized magnetic resonance imaging study of individual joints in patients with early rheumatoid arthritis. *Arthritis Rheum* 2003;48:64-71.
15. Clark AG, Jordan JM, Vilim V, et al. Serum cartilage oligomeric matrix protein reflects osteoarthritis presence and severity: the Johnston County Osteoarthritis Project. *Arthritis Rheum* 1999;42:2356-64.
16. den Broeder AA, Joosten LA, Saxne T, et al. Long term anti-tumour necrosis factor alpha monotherapy in rheumatoid arthritis: effect on radiological course and prognostic value of markers of cartilage turnover and endothelial activation. *Ann Rheum Dis* 2002;61:311-8.