New Developments in Magnetic Resonance Imaging of the Nail Unit

ERNESTO SOSCIA, CESARE SIRIGNANO, ONOFRIO CATALANO, MARIANGELA ATTENO, LUISA COSTA, FRANCESCO CASO, ROSARIO PELUSO, VINCENZO BRUNER, MARIA MADDALENA AQUINO, ANTONIO DEL PUENTE, MARCO SALVATORE, and RAFFAELE SCARPA

ABSTRACT. The evolution of dedicated magnetic resonance imaging (MRI) musculoskeletal equipment allows new sequences and better images of the nail unit. The use of MRI has modified the imaging strategies used in treating inflammatory arthritis. In the case of psoriatic arthritis (PsA), the MRI study of the nail unit identifies nail involvement, which appears as an initial lesion for the induction of distal phalanx damage and consequently of distal interphalangeal joint arthritis. All patients with psoriasis, even in the absence of a clinically evident onychopathy, show characteristic MRI changes in the nail. This evidence could have a practical diagnostic value, because MRI study of the nail could document diagnosis in patients with undifferentiated spondyloarthropathies who have a barely evident psoriasis. We discuss the advantages and problems related to the use of low-field and high-field MRI in the study of the nail unit of patients with PsA. (J Rheumatol 2012;39 Suppl 89:49–53; doi:10.3899/jrheum.120243)

Key Indexing Terms:
PSORIATIC ONYCHOPATHY NAIL PSORIATIC ARTHRITIS

The correlation between the involvement of nails and distal interphalangeal (DIP) joints in psoriatic arthritis (PsA) is well proven[1,2,3,4]. In the past, radiographic study of the distal phalanx in patients with PsA was used to study the relationship between nail and bone changes. Although DIP joint changes correlated with the duration of onychopathy, no statistical difference was found in the distribution of DIP joint arthritis in PsA patients with or without nail disease.

In the hypothesis of a pathogenetic link between bone changes of the distal phalanx and onychopathy of the adjacent nail, we used magnetic resonance imaging (MRI) to study the nail profile, the distal phalanx, and DIP joints of patients with PsA[5] (Figure 1B, IC). We found that nail involvement was present in almost all cases studied, even in those without clinically evident onychopathy. Nail thickening with or without surface irregularity was the most common finding, and MRI nail changes were more marked in patients who had an increased Nail Psoriasis Severity Index, a score for clinical changes of the matrix and of the nail bed[6]. In addition, we demonstrated the constant overlap between the presence of nail alteration and distal phalanx involvement. The involvement of the DIP joint was present instead in a smaller percentage of patients always showing distal phalanx involvement. This point suggested a primary involvement of entheses linking nail to distal phalanx and supported the idea that the involvement of the DIP joint could be secondary to that of the distal phalanx[4,5].

We obtained similar results also in fingers studied by dedicated low-field MRI apparatus[7] (Figure 1C); we have also tested a prototypal finger coil that gave us good results and images similar to or better than those obtained on commercial instruments[8] (Figure 2A). In this kind of coil we obtained, in less time, better images with a higher resolution when compared with the standard wrist coil.

The new generation of dedicated low-field MRI equipment, also with standard coils, allows the study of the nail with 3-D acquisition and complex sequences, giving more information about bone and soft tissue.

USEFULNESS IN CLINICAL PRACTICE OF MRI STUDY OF THE NAIL UNITS OF PATIENTS WITH ARTHRITIS

As we demonstrated, the use of MRI has modified the imaging strategies of ungual and subungual diseases[9,10]. The traditional radiographic plain film study is limited to the evaluation of bone structures. The MRI allows the evaluation of bone, soft tissue, and if adequately performed, the nail[11,12].

In the case of PsA, the MRI study of the nail unit revealed that nail involvement is the main lesion for the development of the distal phalanx damage and consequent-

From the Radiology Unit and the Rheumatology Unit, Department of Clinical and Experimental Medicine, University Federico II; Biostructures and Bioimaging Institute, National Council of Research; SDN Foundation, Institute of Diagnostic and Nuclear Development, Naples, Italy.

E. Soscia, MD, Radiology Unit, University Federico II; C. Sirignano, MD, Biostructures and Bioimaging Institute, National Council of Research; O. Catalano, MD, SDN Foundation, Institute of Diagnostic and Nuclear Development; M. Atteno, MD; L. Costa, MD; F. Caso, MD, R. Peluso, MD; V. Bruner, MD; M.M. Aquino, MD; A. Del Puente, MD, Rheumatology Unit, Department of Clinical and Experimental Medicine, University Federico II; M. Salvatore, MD, Radiology Unit, University Federico II, Biostructures and Bioimaging Institute, National Council of Research; R. Scarpa, MD, Rheumatology Unit, Department of Clinical and Experimental Medicine, University Federico II.

Address correspondence to Dr. E. Soscia, Radiology Unit, University Federico II, Naples, Italy. E-mail: ernesto.soscia@ibb.cnr.it

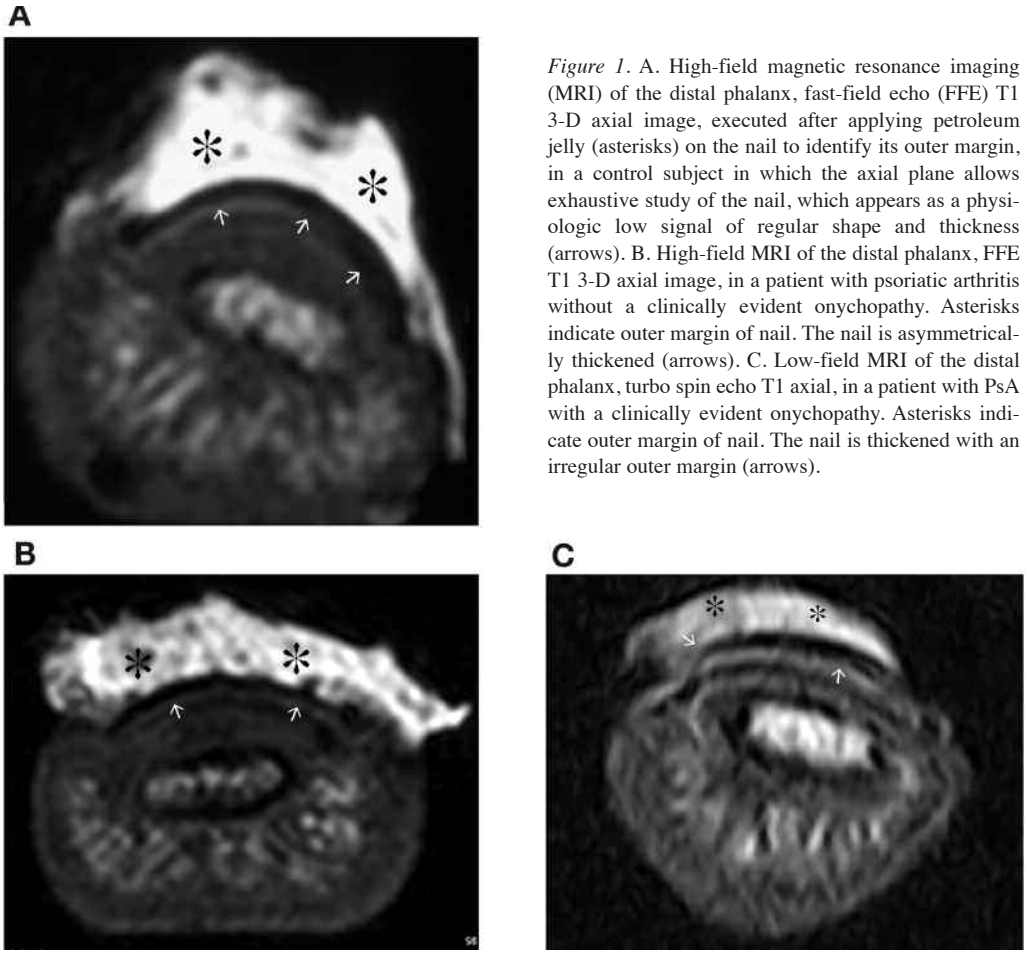

Figure 1. A. High-field magnetic resonance imaging (MRI) of the distal phalanx, fast-field echo (FFE) T1 3-D axial image, executed after applying petroleum jelly (asterisks) on the nail to identify its outer margin, in a control subject in which the axial plane allows exhaustive study of the nail, which appears as a physiologic low signal of regular shape and thickness (arrows). B. High-field MRI of the distal phalanx, FFE T1 3-D axial image, in a patient with psoriatic arthritis without a clinically evident onychopathy. Asterisks indicate outer margin of nail. The nail is asymmetrically thickened (arrows). C. Low-field MRI of the distal phalanx, turbo spin echo T1 axial, in a patient with PsA with a clinically evident onychopathy. Asterisks indicate outer margin of nail. The nail is thickened with an irregular outer margin (arrows).

ly of DIP joint arthritis. We also demonstrated that all patients with psoriasis, even in the absence of clinically evident onychopathy, show characteristic MRI nail changes. So MRI study of the nail could be used in patients belonging to the undifferentiated subset of spondyloarthropathies who have a barely evident psoriasis; the presence of typical nail psoriasis changes could permit a more precise classification of the cutaneous preclinical stage[13].

Moreover, as we have demonstrated, MRI of the nail could play a role in diagnostic differentiation in the case of patients with other inflammatory conditions such as rheumatoid arthritis (RA). In patients with RA, MRI has revealed the involvement of the DIP joint but it does not show alterations of the nail[14]. In addition, MRI could allow differential diagnosis between PsA and nodal osteoarthritis in patients with associated skin psoriasis.

MAGNETIC RESONANCE IMAGING

As reported, MRI of the finger, in the absence of ionizing radiation, is useful for the evaluation of patients who have borderline psoriasis.

The nail margin can be evaluated with MRI by putting petroleum jelly on its outer surface to outline the nail profile and to allow easy evaluation of the phalanx bone alterations and tendon involvement. The sensitivity of MRI in revealing bone erosion, bone edema, and soft tissue inflammation is higher than with plain radiograph studies[9,10,11,12]. The association with intravenous contrast medium administration, for example, is widely used to demonstrate synovial inflammation in RA and to increase the sensitivity in identifying bone alterations, before their morphological evidence[15].

When we started to perform nail studies, only high-field MRI (1.5 T superconductive magnet) was available. Study of the nail on high-field MRI was considered expensive and difficult to perform because it reduces the time that the machine is available to study other more severe and life-threatening pathologies such as those in the brain or abdomen, but also for vascular examinations, functional studies, spectroscopy, and so on. Moreover, to obtain high imaging quality in closed magnets, patients must keep an uncomfortable position with the hand above the head – a posture that can be difficult for patients with claustrophobia to assume and to keep, as well as for patients with arthritis.

Therefore, we started to perform similar studies on

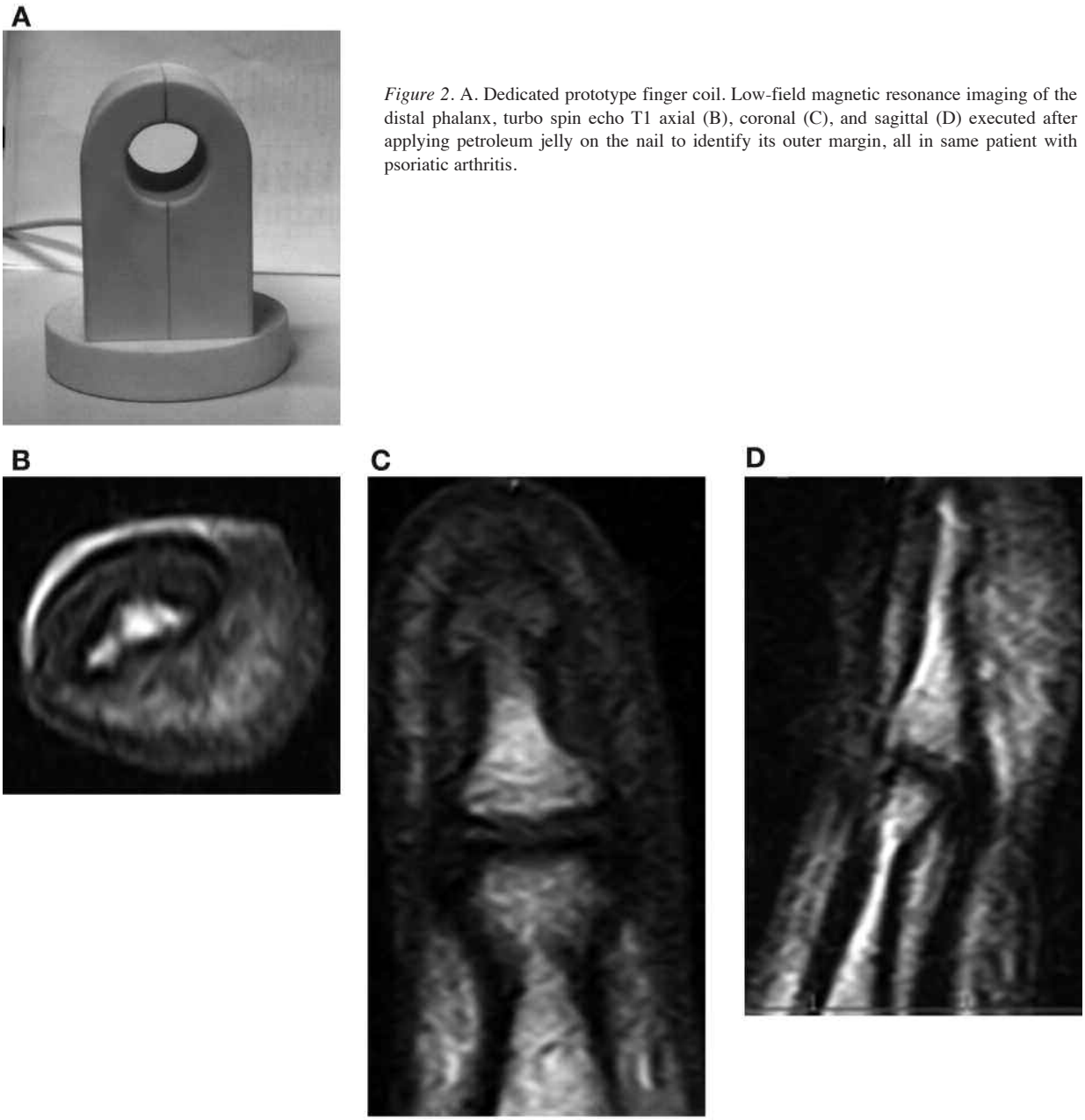

Figure 2. A. Dedicated prototype finger coil. Low-field magnetic resonance imaging of the distal phalanx, turbo spin echo T1 axial (B), coronal (C), and sagittal (D) executed after applying petroleum jelly on the nail to identify its outer margin, all in same patient with psoriatic arthritis.

low-field dedicated musculoskeletal MRI equipment. These machines are cheaper, cost less to install, take up less space, and are easier to use. The absence of a superconductive magnet avoids helium usage, reducing maintenance costs. The open structures allow easy access for the patients, avoiding claustrophobia and reducing anxiety; patients do not need to assume an uncomfortable position. During examination, they simply lie with the arms alongside the body. The anatomical region of interest, in our case the finger, is in the very center of the coil in the magnet. The patient is relaxed and movement artifacts are drastically reduced. Another point to be considered in low-field MRI is the reduction of safety risks mainly linked to the magnetic field strength (e.g., interaction with ferromagnetic or iron objects inside the patients).

The major drawback is a lower signal-to-noise ratio with more imaging noise: this means longer acquisition time. Another drawback was the lack of complex fat-suppressed sequences such as spoiled gradient echo or spectral saturation by inversion recovery, and the impossibility of performing 3-D complex sequences.

Our first studies showed a low sensitivity for bone marrow edema because of the small anatomical region examined. With regard to image resolution, the actual generation of open devices permits diagnostic images comparable (for the articular studies) to those of the high-field MRI; this is

A

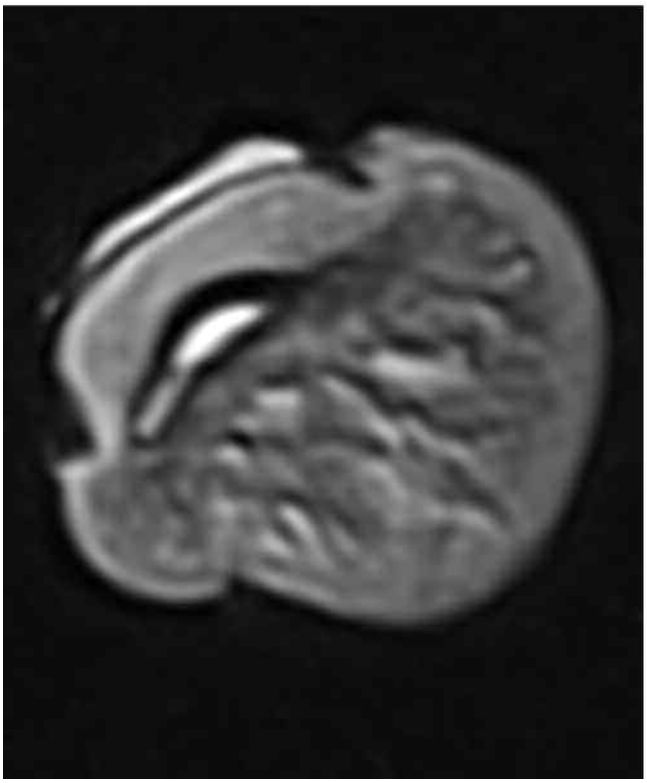

Figure 3. Low-field new generation magnetic resonance imaging of the distal phalanx, axial 3-D gradient echo T1 (A), executed after applying petroleum jelly on the nail to identify its outer margin in a patient with psoriatic arthritis, with standard wrist coil. Three-D images allow a high resolution and a bigger field of view to evaluate bone and nail (B).

B

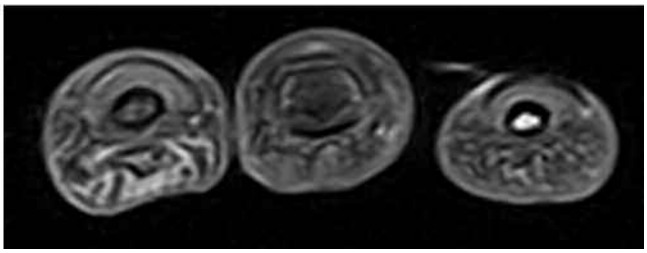

also confirmed in our study[13], in which results obtained on high-field MRI were comparable to those obtained on low-field dedicated machines.

DEDICATED MRI

We now have the opportunity to perform the examination with dedicated coils, to obtain a higher signal-to-noise ratio with a smaller field of view (FOV). The tested prototype of a dedicated finger coil allowed us to obtain better images in less time with a higher resolution compared with the standard wrist coil[8] in the same machine. The advantage of this coil, in addition to the resolution, is that it is easy to place the finger in the small hole at the center of the coil. This allows the region of interest to be easily centered in the magnetic field, in turn allowing a smaller FOV. In this way the signal is significantly increased and pixel size can be reduced, without image degradation, giving a higher resolution with a shorter time execution (Figures 2B-D).

Available dedicated MRI allows us to obtain better images than with the equipment of 10 years ago. The magnetic field is more or less the same, but new hardware and excellent new sequences now available allow images of higher quality and resolution. These kinds of sequences were intended for the study of the spine and for the evaluation of knee cartilage, but are also ideal for the study of the nail, allowing 3-D steady state high-contrast images; this means high spatial resolution, good contrast, and the possibility of multiplanar reconstruction on a single 7-min acquisition (Figure 3).

The 2-D base sequences have also been improved, and with the same contrast and same resolution, compared with high-field images. Fat suppression is also enhanced, and complex images subtracted using the Dixon method can be used to identify bone or soft tissue edema (Figures 4 and 5).

MRI, either with high-field or low-field apparatus, supports the diagnoses of rheumatologists and opens new perspectives in evaluation of patients with rheumatic conditions[13,14,15,16]. In particular it could be very helpful in cases of early or uncertain diagnosis of PsA.

REFERENCES

1. Bauer W, Bennett GA, Zeller JW. Pathology of joint lesions in patients with psoriasis and arthritis. Trans Assoc Am Physicians 1941;56:349-51.
2. Dawson MH, Tyson TL. Psoriasis arthropathica with observations on certain features common to psoriasis and rheumatoid arthritis. Trans Assoc Am Physicians 1938;53:303-6.
3. Sherman M. Psoriatic arthritis: observations of the clinical roentgenographic and pathological changes. J Bone Joint Surg 1952;34:831-52.
4. Scarpa R, Manguso F, Oriente A, Peluso R, Atteno M, Oriente P. Is the involvement of the distal interphalangeal joint in psoriatic patients related to nail psoriasis? Clin Rheumatol 2004;23:27-30.
5. Scarpa R, Soscia E, Peluso R, Atteno M, Manguso F, Del Puente A, et al. Nail and distal interphalangeal joint in psoriatic arthritis. J Rheumatol 2006;33:1315-9.
6. Rich P, Scher RK. Nail Psoriasis Severity Index: a useful tool for

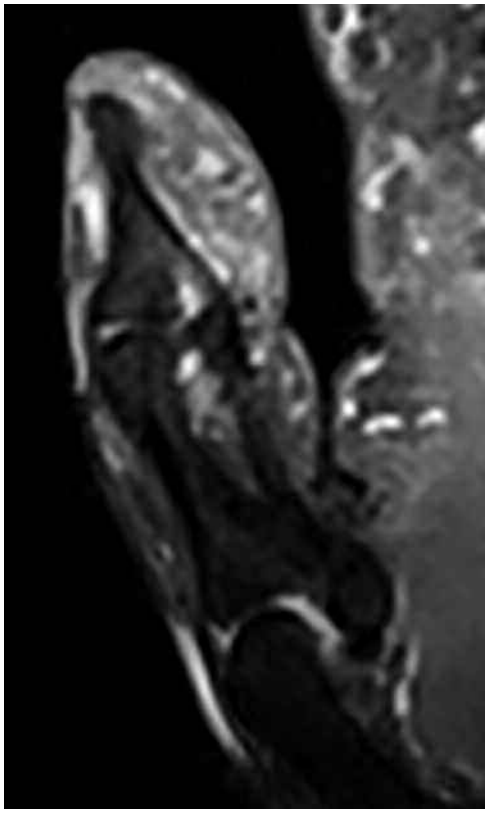

Figure 4. Low-field new generation magnetic resonance imaging of the distal phalanx, short-tau inversion recovery (STIR) sagittal, standard wrist coil. In the STIR image, thumb's normal bone and subcutaneous tissue appear dark due to suppression of fat signal.

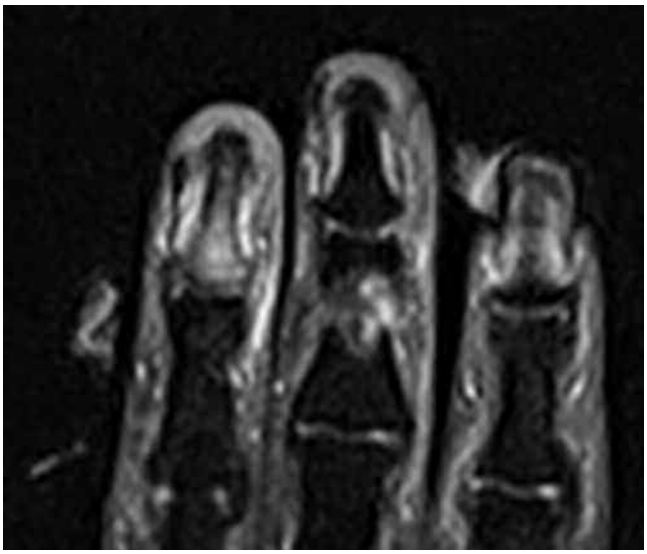

Figure 5. Low-field new generation magnetic resonance imaging of the distal phalanx, short-tau inversion recovery (STIR) coronal, standard wrist coil. Index, middle, and ring fingers in patient with psoriatic arthritis. In the STIR image, bone and soft tissue edema is clearly recognizable by high-intensity areas in the dark healthy structures.

evaluation of nail psoriasis. J Am Acad Dermatol 2003;49:206-12.

7. Scarpa R, Soscia E, Peluso R, Atteno M, Siringano C, Costa L, et al. Diagnostic reliability of low-field magnetic resonance imaging for the study of nail and distal interphalangeal joint in psoriatic arthritis. Rheumatology 2007;46 Suppl: 81.
8. Soscia E, Atteno M, Costa L, Peluso R, Iervolino S, Caso F, et al. Prototype finger coil for the study of nail unit in psoriatic arthritis patients using a low field MRI. Poster No. 69, submitted to British Society for Rheumatology Annual Conference, Glasgow 2009.
9. McGonagle D, Tan AL. What magnetic resonance imaging has told us about the pathogenesis of rheumatoid arthritis - the first 50 years. Arthritis Res Ther 2008;10:222.
10. Lubrano E, Scrivo R, Cantini F, Marchesoni A, Mathieu A, Olivieri I, et al. Is nail psoriasis severity index reliable in the assessment of nail psoriasis by rheumatologists? Arthritis Care Res 2012;64:455-8.
11. Poleksic L, Zdravkovic D, Jablanovic D, Watt I, Bacic G. Magnetic resonance imaging of bone destruction in rheumatoid arthritis: comparison with radiography. Skeletal Radiol 1993;22:577-80.
12. Drapé JL, Chevrolet A, Bittoun J. Ungual and subungual disease. In: Fundamentals of hand and wrist imaging. Guglielmi G, Van Kuijk C, Genant HK, eds. Berlin: Springer; 2001:481-505.
13. Soscia E, Scarpa R, Cimmino MA, Atteno M, Peluso R, Sirignano C, et al. Magnetic resonance imaging of nail unit in psoriatic arthritis. J Rheumatol Suppl 2009 Aug;83:42-5.
14. Scarpa R, Cimmino MA, Peluso R, Soscia E, Atteno M, Costa L, et al. Distal interphalangeal joint involvement is not exclusive finding of psoriatic arthritis [abstract]. Rheumatology 2007;46 Suppl:212.
15. König H, Sieper J, Wolf KJ. Rheumatoid arthritis: evaluation of hypervascular and fibrous pannus with dynamic MR imaging enhanced with Gd-DTPA. Radiology 1990;176:473-7.
16. Cimmino MA, Parodi M, Zampogna G, Paparo F, Silvestri E, Garlaschi G, et al. Magnetic resonance imaging of the hand in psoriatic arthritis. J Rheumatol Suppl 2009 Aug;83:39-41.