

Diagnosing Ankylosing Spondylitis

MAZEN ELYAN and MUHAMMAD ASIM KHAN

ABSTRACT. This article focuses on the early diagnosis and effective management of ankylosing spondylitis (AS), a disease that is not uncommon and that can cause early retirement and severe functional disability. AS, like most other rheumatologic diseases, has no diagnostic gold standard. Correct diagnosis depends largely on a constellation of clinical symptoms and signs in addition to radiological findings. Early diagnosis has become all the more important because effective therapies are available: tumor necrosis factor antagonists that suppress disease activity and improve functional ability in patients with AS refractory to conventional drug therapy. The biologic agents are probably even more effective if given early. Inflammation of the sacroiliac joints and the spine is a common, early feature and possibly the most frequent first manifestation of disease. Therefore, its early detection is important, and magnetic resonance imaging has proven useful in this regard. To optimize diagnostic accuracy of early disease, it is crucial to use a comprehensive approach and have a deep understanding of the disease and its clinical picture. The clinician should gather a complete history, paying close attention to all the elements of this multisystem disease, as well as judiciously ordering laboratory testing and imaging. New strategies are being developed to assist primary care physicians in their screening for these patients, which in turn should result in early referral to rheumatologists and early diagnosis. (J Rheumatol 2006;33 Suppl 78:12-23)

Key Indexing Terms:

ANKYLOSING SPONDYLITIS
SPONDYLOARTHTRITIS

DIAGNOSIS
SPONDYLOARTHROPATHIES

IMAGING
RADIOGRAPHY

INTRODUCTION

The hallmark of ankylosing spondylitis (AS), a chronic systemic rheumatic disorder of indeterminate etiology (but with a strong genetic predisposition), is sacroiliac (SI) joint inflammation (sacroiliitis). AS is the prototype and most common member of a group of diseases called the spondyloarthropathies (SpA), which also includes reactive arthritis, psoriatic spondyloarthritis, spondyloarthritis of inflammatory bowel disease, and undifferentiated spondyloarthritis¹. Their prevalence varies among ethnic and racial groups; in Europe this ranges from 0.1% to 1.4%; however, a more consistent number approaches 0.5%²⁻¹¹. These data suggest that AS and related SpA may be as common as rheumatoid arthritis (RA). Unlike RA, AS typically starts during the late teens and early twenties; however, the overall socioeconomic impact of both disease groups on the patient and society are about equal^{1,12-14}.

The early correct diagnosis of AS is important in order to decrease disease burden through early intervention to reduce disability experienced by many patients. Early diagnosis is more important now with availability of new

and effective treatments¹⁵. Historically, diagnosis has depended on the finding of radiographic sacroiliitis; however, symptoms of AS have been shown to precede radiographic changes by many years^{16,17}. A recent review of available evidence concludes that AS can and has to be diagnosed earlier, and that AS can be diagnosed prior to emergence of definite radiological changes¹⁸.

UNDERDIAGNOSIS

The diagnosis of AS or other related SpA is often missed or markedly delayed¹⁸, especially in a primary care setting¹⁹. A physician who is not fully aware of the clinical presentation of AS might overlook this diagnosis when a teenager or a young adult presents with chronic back pain, even though this is a very typical presentation. One reason is that back pain is very prevalent in the general population, while AS or other related SpA are not the most common cause of back pain. Moreover, in many patients with AS, it may take years from onset of inflammatory back pain to development of radiographic sacroiliitis, despite inflammation as detected by magnetic resonance imaging (MRI) and despite clinical manifestations such as back pain and stiffness. For example, in a study of patients with symptoms and signs consistent with early AS [inflammatory back pain, plus additional features of peripheral arthritis, heel pain, or acute uveitis; or elevated levels of C-reactive protein (CRP) and erythrocyte sedimentation rate (ESR) but radiographically normal sacroiliac joints], 36% developed radiographic evidence of sacroiliitis in 5 years and 59% did so in 10 years¹⁶. This was also shown in a study of HLA-B27-positive relatives of patients with AS⁹, where radiographic

From the Division of Rheumatology, Case Western Reserve University, MetroHealth Medical Center, Cleveland, Ohio, USA.

Funding for this supplement series was provided by Amgen, Inc. and Wyeth Research.

M. Elyan, MD; M.A. Khan, MD, MACP.

Address reprint requests to Dr. M.A. Khan, Division of Rheumatology, Case Western Reserve University, MetroHealth Medical Center, 2500 MetroHealth Drive, Cleveland, OH 44109-1998. E-mail: mkhan@metrohealth.org

Ankylosing Spondylitis

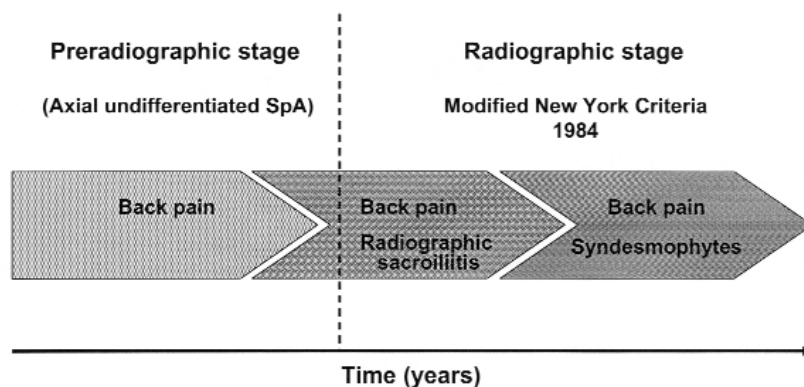


Figure 1. The concept of axial spondyloarthritis, showing the transition from early to late stages of axial spondyloarthritis. Symptoms of axial spondyloarthritis usually start before sacroiliitis can be seen on plain radiographs, but over years, sacroiliitis and possibly syndesmophytes will be visible. Back pain as the main symptom may be present throughout the disease course. The broken line marks the separation, according to established criteria, to distinguish axial undifferentiated spondyloarthritis without radiographic changes from ankylosing spondylitis. During early years, MRI can detect inflammatory changes of sacroiliitis before they become evident on plain radiographs. Modified from Rudwaleit, *et al.* Arthritis Rheum 2005;52:1000-8, with permission.

sacroiliitis was found in 16% of patients younger than 45 years and in 38% of patients older than 45 years. In another family study, radiographic evidence of sacroiliitis was found in 40% of patients with SpA with duration of symptoms of 10 years, in 70% with symptoms for 10 to 19 years, and in 86% with symptoms for 20 years or more²⁰. Recent use of MRI has confirmed that active inflammation of the sacroiliac joints and/or the spine is present long before the appearance of unequivocal sacroiliitis on plain radiography (Figure 1)^{18,21}. Therefore, the absence of radiographic sacroiliitis during the early years of disease should certainly not be used to rule out the diagnosis, especially when the presence of inflammation can be detected by other imaging modalities, such as MRI.

The average delay in diagnosis can vary from 3 to 11 years from onset of symptoms, depending on the type of symptoms and the clinical training of the physician^{13,22-26}. This delay is relatively longer in women than in men²⁷, in children and adolescents than in older patients²⁷, and in HLA-B27-negative patients than in HLA-B27-positive patients^{13,26}. The longer the diagnosis is delayed, the worse the functional outcome may be, especially with juvenile-onset AS²⁷.

Challenges identifying AS. AS, like most other diseases, does not have a diagnostic gold standard. Correct diagnosis largely depends on a constellation of clinical symptoms and signs, in addition to radiologic findings. During the last 5 decades, there have been many attempts to establish clinical criteria for AS diagnosis. To date, no

validated diagnostic criteria exist²⁸. Classification criteria exist, but they are used to ensure patients enrolled in clinical studies have a firm diagnosis and are a homogeneous group and are inappropriate for clinician diagnosis. Because classification criteria are designed to be highly specific, they may not be sensitive enough to establish diagnosis at an early stage of disease.

The 1961 Rome criteria were the first criteria developed for classification of AS; at later evaluation, thoracic pain and uveitis were removed owing to either low specificity or sensitivity, resulting in the 1966 New York classification criteria²⁹. In 1977, criteria for chronic inflammatory back pain were proposed to help differentiate it from other causes of chronic back pain³⁰. In 1984, the modified New York criteria²⁶ were proposed, incorporating the inflammatory back pain concept.

According to the modified New York criteria, a patient can be classified as having definite AS if at least 1 clinical criterion (inflammatory back pain, limitation of mobility of the lumbar spine, or limitation of chest expansion), plus the radiologic criterion, are met (Table 1). The modified New York classification criteria are currently the most commonly (and inappropriately) used for establishing the diagnosis of AS in clinical practice.

Another challenge to early diagnosis is the insidious onset of the disease, and symptoms can often be mild and nonspecific during the early stage. Many cases of early AS will be missed unless the physician has ample clinical experience and a high index of suspicion. Disease progression is sometimes slow and minimally symptomatic³¹.

Table 1. The modified New York classification criteria for ankylosing spondylitis. From van der Linden *et al.* *Arthritis Rheum* 1984;27:361-8, with permission.

Clinical criteria	
1.	Low back pain and stiffness for >3 months that improves with exercise but not with rest
2.	Limitation of lumbar spine mobility in both the sagittal and frontal planes
3.	Limitation in chest expansion as compared with normal range for age and sex
Radiologic criteria	
1.	Unilateral sacroiliitis of grade 3-4 <i>OR</i>
2.	Bilateral sacroiliitis of grade ≥ 2
Grading	
1.	Definite AS if the radiological criterion is associated with at least 1 clinical criterion
2.	Probable AS if:
a.	3 clinical criteria are present <i>OR</i>
b.	The radiological criterion is present without any signs or symptoms satisfying the clinical criteria

Further, some patients may be pain-free for long periods of time¹⁷. There is also significant overlap (Figure 2) in the clinical features of the SpA, especially in the early stages^{1,32,33}.

As mentioned above, what can make diagnosis even more challenging is that radiologic changes, the hallmark of the disease, are frequently not evident until later^{17,34,35}. This delay in detection of radiologic changes cannot always be simply explained by inter-examiner variability in the interpretation of the radiograph³⁶. Thus, the find-

ing of normal SI joints on plain pelvis films should not mislead the physician to prematurely rule out AS if clinical suspicion is sufficient.

The presence or absence of radiographic changes is not the primary determinant of the burden of illness in this disease. A study of the German SpA inception cohort demonstrated that patients with early disease without radiographic sacroiliitis (i.e., undifferentiated spondyloarthritis with axial involvement) are not different from those with definite AS with radiographic sacroiliitis of short (10 yrs) duration³⁷. The 2 groups of patients were found to be similar with regard to disease activity as judged by Bath Ankylosing Spondylitis Disease Activity Index (BASDAI), level of global pain, level of pain at night, patient global assessment of disease activity, need for treatment, response to treatment, and quality of life.

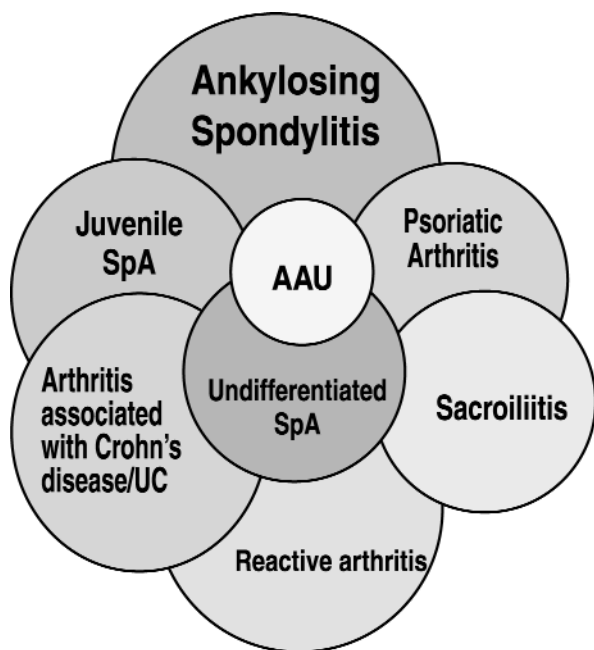


Figure 2. Overlapping clinical features shared by various spondyloarthropathies (SpA) can make them difficult to distinguish, especially during the early phases of disease. Ankylosing spondylitis can occur alone without any associated disease (the so-called “primary” AS), or be associated with psoriasis, reactive arthritis, or inflammatory bowel disease [ulcerative colitis (UC) and Crohn’s disease (“secondary” AS)]. AAU: acute anterior uveitis. ©M.A. Khan.

CLINICAL PRESENTATION: SYMPTOMS

The chronic low back pain of AS is usually of insidious onset, is often associated with stiffness that worsens late at night and early in the morning or after prolonged rest, and is alleviated with physical activity or a hot shower³⁸. The pain is usually dull in character, difficult to localize, felt initially deep in the gluteal area, and sometimes intermittent and alternating from side to side before it becomes bilateral²⁹. The pain and stiffness later involves the lumbar spine. The features suggestive of chronic inflammatory back pain, as proposed by Calin, *et al*³⁰, are not very specific. These authors define chronic inflammatory back pain as having at least 4 of the following characteristics: back pain starting insidiously before age 45 years, at least 3 months’ duration, worsening with inactivity, improving with physical exercise, and being associated with spinal morning stiffness.

The average age of onset of AS symptoms is about 25 years in developed countries and lower in developing countries³⁸. The symptoms rarely start after age 45 years; however, the diagnosis might be delayed until this age or

after. Disease onset occurs before age 16 years in about 15% of patients (40% of patients or higher in developing countries is possible). The development of definite symptoms and signs of axial disease in children with AS may be preceded by persistent or recurrent bouts of enthesitis and/or lower extremity oligoarthritis (seronegative enthesopathy and arthritis) for 5 to 10 years. Thus, juvenile AS should always be considered in the differential diagnosis of oligoarticular juvenile arthritis.

The main articular sites associated with AS include the axial skeleton (including sacroiliac, hip, and shoulder joints), and occasionally the peripheral joints^{12,39}. Spinal articular inflammation involves discovertebral, facet, costovertebral, and costotransverse joints of the spine and the paravertebral ligaments. This can result in chest pain or discomfort that worsens with coughing or sneezing or maneuvers that increase intrathoracic pressure²⁹.

Spinal inflammation can evolve into fibrous and bony ankylosis after many years^{12,40}. As the disease progresses, there is a gradual loss of mobility consistent with the gradual flattening of the lumbar spine and development of exaggerated thoracic spine kyphosis^{29,38,40}. The inflammation can extend to involve even the cervical spine. Limb joint involvement is mostly seen in the hip joints and shoulders. Less frequently other limb joints, including temporomandibular and knee joints, can be affected, and that involvement can often be asymmetric^{12,41,42}.

The entheses, the site of bony insertion of ligaments and tendons, are among the major affected sites in AS^{1,41,42}. The entheses are present throughout the body, and those in the axial skeleton, including the hip and shoulder girdles, are much more often affected. Thus, the patient can present with pain at the insertions of plantar fascia and Achilles tendon into the calcaneum, or patellar tendon insertion into the tibial tubercle. Enthesitis most frequently occurs at sites that are subject to greater physical stress¹.

Extraskelletal involvement, such as the eye, gastrointestinal tract, aorta, heart, and lung^{29,43}, can also be a clinical feature of this disease, emphasizing that AS is a systemic disease. Ocular symptoms (eye pain, redness, irritation, or vision blurriness) need urgent evaluation by an ophthalmologist because of the possibility of acute anterior uveitis⁴⁴, which occurs in 25% to 40% of patients^{1,40}, is typically unilateral and often recurrent, can affect either eye, and is relatively less common among HLA-B27-negative than HLA-B27-positive patients⁴⁵. Uveitis can result in visual impairment if not promptly and properly treated. It should be noted that enthesitis, peripheral arthritis, or extraarticular manifestations, especially acute anterior uveitis, may precede back symptoms in some patients^{1,40,46,47}.

Bowel involvement, another extraskelletal manifestation of AS, is usually asymptomatic. Enteric mucosal inflammation, both macroscopic and microscopic, has been found in the terminal ileum and proximal colon on ileocolonoscopy studies in 26% to 69% of AS patients with no gastrointestinal symptoms⁴⁸. About 6% of such patients will develop inflammatory bowel disease⁴⁹ and, among those with chronic bowel inflammation on biopsy, 15% to 25% will develop symptomatic Crohn's disease³⁸.

Other uncommon extraskelletal features include aortic insufficiency and cardiac conduction disturbances or heart block (reviewed by Bergfeldt⁵⁰). Inflammation at the aortic root (aortitis) can lead to fibrosis. Although this is often hemodynamically insignificant, some patients might develop aortic incompetence due to a dilated aortic ring and changes in the aortic valve. Extension of the inflammation and fibrosis to the atrioventricular conduction system can cause a variable degree of heart block⁵⁰.

Lung involvement, a late manifestation of AS in 1% to 2% of patients, usually presents as a slowly progressive bilateral apical pulmonary fibrobullous disease or cavitata-

Table 2. Sacroiliac joint stress maneuvers^{38,40,55}.

FABERE or Patrick's test	The patient lies supine on the examining table. One hip joint is flexed, abducted, externally rotated then extended, to form a figure-4 with the ankle on the contralateral knee. This maneuver stresses the ipsilateral sacroiliac joint. This test is then repeated on the contralateral side. If this maneuver causes posterior hip pain, mostly overlying the sacroiliac joint, sacroiliitis should be suspected
Gaenslen's test	The patient lies supine on the examining table with the lower extremities projecting over the end of the table. The patient draws his or her knees to the chest. The physician stabilizes the patient while the side being tested is left to drop off the table, fully extending the hip joint. The test is then repeated on the contralateral side. If this maneuver causes posterior hip pain, mostly overlying the sacroiliac joint, sacroiliitis should be suspected
Lateral pelvic compression test	The patient lies on their side on a firm examining table. The physician applies pressure on the iliac crest to compress the pelvis down toward the table top. Pain elicited in the sacroiliac joint area on either or both sides may be indicative of sacroiliitis
Anteroposterior pelvic compression test	The patient lies supine on the examining table. The physician applies pressure on the anterior superior iliac spine bilaterally to compress the pelvis. Pain elicited in the sacroiliac joint area on either side may be indicative of sacroiliitis

FABERE: hip flexion, abduction, external rotation, and extension.

tions⁵¹. The use of newer imaging modalities, such as high-resolution computed tomography, suggest a higher incidence of lung involvement in patients with AS than previously thought⁵².

Mild constitutional symptoms, including fatigue, malaise, loss of appetite, or low-grade fever, can be present in the early stages of the disease¹. Patients with AS have a higher incidence of fatigue than the general population⁵³. Also, patients with AS may be at increased risk for coronary artery disease as a result of the systemic inflammation⁵⁴. A positive family history of AS or related SpA can be helpful to support the clinical suspicion³⁴.

CLINICAL PRESENTATION: SIGNS

A careful and thorough physical examination should be conducted to look for signs that support the diagnosis and/or determine the severity of the disease. This includes looking for tenderness over the SI joints or eliciting SI joint pain by maneuvers to stress the joints. These include hip FABERE (flexion, abduction, external rotation, and extension) or Patrick's tests and Gaenslen's maneuvers and lateral pelvic compression or anteroposterior pelvic compression tests (Table 2)^{38,40,55}. Clinical indicators of enthesitis include tenderness over the SI

joints, the spinal processes, the heels, iliac crest, anterior chest wall, and other bony prominences^{38,56,57}. Anterior chest wall tenderness is localized over costochondral areas or the manubriosternal junction.

Chest expansion is at least 5 cm in healthy young individuals at the level of the xiphisternum, and it decreases with older age⁵⁸. Mild to moderate limitation of chest expansion can be an early physical finding in patients with AS, whereas severe limitation is typically a late physical finding³⁸. Although chest expansion is decreased in patients with AS when compared with healthy controls^{58,59}, this feature has limited sensitivity for diagnosis^{26,32}. Measures of spinal mobility (such as modified Schober's test⁶⁰ and lateral flexion⁶¹) may be better clinical indicators of AS (Table 3)⁶².

In patients with AS, there is gradual flattening of the anterior chest wall, shoulders become "stooped," the abdomen becomes protuberant, and breathing becomes increasingly diaphragmatic. Occiput-to-wall or tragus-to-wall distances measure forward stooping deformity of the cervical spine⁶³. Involvement of the cervical spine can gradually result in progressive limitation of the ability to turn or fully extend or laterally bend the neck. Although the rate and pattern of spinal ankylosis development vary

Table 3. Measures of spinal mobility. Modified from Haywood, *et al.* Rheumatology Oxford 2004;43:750-7, with permission

Measure*	Description
Cervical rotation	Measure the angle of the cervical rotation using a goniometer. Another method is to measure with a plastic tape the distance between the tip of the nose and the acromioclavicular joint at baseline (when the neck is in neutral position) and on maximal ipsilateral rotation. The difference between these 2 positions measures the rotation and is separately measured for right/left rotations. Smaller difference indicates a more restricted cervical rotation
Fingertip-to-floor distance	Distance between tip of right middle finger and the floor following maximal lumbar flexion, while maintaining full extension of the knee. Measurement is done ideally with a rigid tape measure. Smaller distance indicates greater movement
Lateral spinal flexion	The difference of the distance between the level of the tip of the ipsilateral middle finger when standing erect (and arm fully extended and by the side of the trunk) and the floor, and the one measured following maximal lateral flexion of the spine, maintaining heel contact with the floor and without trunk rotation. Measurements are done ideally with a rigid tape measure. Domjan method: the 2 marks are placed on the patient's skin on the above 2 maneuvers and the distance between those 2 marks reflects lateral flexion
Modified Schober's index	Two marks are placed 10 cm apart on the lumbar spine in the midline, with the patient standing upright; the lower mark is at the level of the dimples of Venus or that of the posterior superior iliac spines. The distance between these 2 marks is measured again while the patient is maximally forward-flexing the spine, with the knees fully extended. There is an expansion of at least 5 cm between the 2 marks. An expansion < 4 cm indicates decreased mobility of the lumbar spine. Measurements are done with a plastic tape measure
Tragus-to-wall distance	Horizontal distance between right tragus and wall, when the subject is standing erect with heels and buttocks against the wall (to prevent pivoting), knees fully extended and chin drawn in to keep a horizontal gaze. Larger distance indicates worse spinal/upper cervical posture. Measurements are done with a rigid tape measure
Occipital-to-wall distance	Horizontal distance between the posterior convexity of the occiput and the wall, when the subject is standing erect with heels and buttocks against the wall (to prevent pivoting), knees fully extended and chin drawn in to keep a horizontal gaze. Subjects with normal posture show no gap. Larger distance indicates worse spinal/upper cervical posture. Measured with a rigid tape measure

*All measurements should be recorded after the patient practices once.

among patients, the typical spinal deformities usually evolve after at least 10 years^{29,38}. The disease may occasionally remain limited, however, to a part of the spine, and spinal ankylosis may not occur at all in some patients with very mild disease^{38,64}.

Patients with AS can have a rigid osteoporotic spine that is prone to fracture after relatively minor trauma that may not be recalled by the patient^{38,65}. Spinal osteoporosis is caused in part by the ankylosis and lack of mobility, but it can also occur relatively early in the disease, possibly due to proinflammatory cytokines^{66,67}. Spinal fracture needs to be ruled out in any patient with advanced AS who has new onset of neck or back pain, even in the absence of a history of trauma. Transverse displaced fractures of the neck are associated with significant morbidity and mortality and can result in paraplegia or quadriplegia^{12,68,69}. Aseptic spondylodiscitis is more common in patients with cervical spine disease, occurs mostly in the midthoracic spine, is usually asymptomatic, and can occur with minimal or no trauma^{38,70}.

Patients with AS are also subject to neurologic manifestations that are often related to fractures or spine dislocation³⁸. Cauda equina syndrome is a rare and late complication of AS, characterized by dull pain in the lower back and upper buttock region; analgesia in the buttocks, genitalia, or thighs (saddle area); and a disturbance of bowel and bladder function. The syndrome probably results from chronic adhesive arachnoiditis, which results from fibrous entrapment and scarring of the sacral and lower lumbar nerve roots^{71,72}. Spontaneous atlantoaxial subluxation has also been reported in patients with AS^{73,74}.

IMAGING

The clinical diagnosis of AS is supported by radiologic evidence of sacroiliitis, which has been the traditional radiographic hallmark of this condition. There are already well-established criteria for the radiographic evidence of sacroiliitis (New York criteria; Table 4)⁷⁵. Radiographic sacroiliitis is a requirement for definite diagnosis of AS using the Modified New York classification criteria²⁶. However, the requirement for radiographic sacroiliitis for the diagnosis results in a low sensitivity for the criteria if applied to patients with early disease because patients who present with clinical symptoms but without radiographic sacroiliitis will not be recognized as having AS^{17,34,76}. Therefore, criteria are needed to diagnose AS in the early stage of the disease even before the erosions are detectable in the sacroiliac joints on conventional radiography. We do not wait for erosions to occur in the involved joints in rheumatoid arthritis before we diagnose this disease. Then why do we wait for the radiographic evidence of sacroiliitis before we make a diagnosis of AS, when such an occurrence is a reflection of disease duration?

Table 4. The New York Criteria for grading radiologic evidence of sacroiliitis. Adapted from Barozzi, *et al.* Eur J Radiol 1998;27 Suppl 1:S12-17, with permission.

Grade	Level	Description
0	Normal	Clear margins, uniform width, and no juxta-articular sclerosis
1	Suspicious	Suspicious but not definite abnormality
2	Minimal sacroiliitis	Evidence of some sclerosis and minimal erosions but no marked joint space narrowing
3	Moderate sacroiliitis	Definite sclerosis on both sides of the joint, erosions, and widening of the interosseous space
4	Ankylosis	Complete joint obliteration with or without residual sclerosis

There is also some concern about the specificity of radiographic sacroiliitis, especially grade 2 bilateral sacroiliitis, which is considered in all criteria to be sufficient for classification of definite AS. It is difficult to distinguish between grades 1 and 2 sacroiliitis, which is currently the borderline between disease and no disease. Indeed, it was estimated that in as many as 18% of cases, designations of grades 1 and 2 might be wrong⁷⁷. Nonetheless, the presence of grade 2 sacroiliitis bilaterally by radiography has remained part of these criteria for 2 reasons: First, sensitivity would have decreased significantly if only patients with grade 3 sacroiliitis had been included; second, no better imaging technique was available for early diagnosis at the time these criteria were established. This issue was also investigated in a Dutch study³⁶, which reported that specificity and sensitivity of sacroiliitis on radiographs as read by trained radiologists or rheumatologists are only about 70% to 75% and 80% to 84%, respectively, resulting in a relatively low likelihood ratio (LR) of AS (see Figure 3 for an explanation and calculation of LR). It should be remembered that the mere presence of sacroiliitis alone does not necessarily represent definite AS, which requires the added presence of one or more clinical feature(s)^{26,78}.

An anteroposterior radiograph of the pelvis in most patients is adequate by the time they are seen by a rheumatologist⁴². However, in patients in whom clinical suspicion of early disease is high, but standard radiography of the sacroiliac joints is normal or shows only equivocal changes, a computerized tomographic scan, or better (although more costly), MRI, can be helpful. MRI using the short-tau inversion recovery (STIR) technique is an excellent tool to demonstrate sacroiliitis and enthesitis without the risk of ionizing radiation. STIR technique can show nice evidence of inflammation and bone marrow edema, indicating active ongoing inflammation without the added cost of gadolinium enhancement⁷⁹⁻⁸². MRI may often detect evidence of bone edema and even bony erosions that are still not detectable by convention-

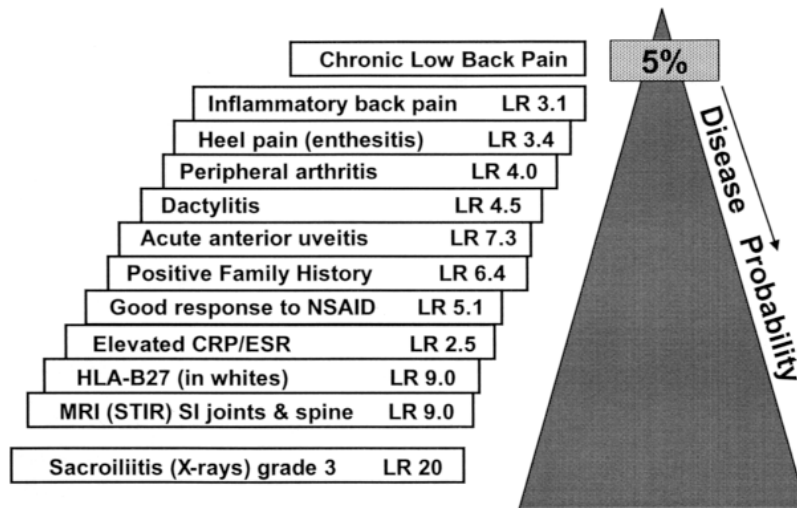


Figure 3. The disease probability of axial SpA is based on the presence of certain clinical features in each patient. Some of those features are included in this example. About 5% of patients with chronic back pain being seen at the primary care physician's office have AS or axial SpA. To calculate the actual disease probability in a given patient with chronic low back pain, the likelihood ratios (LR) of each clinical characteristic in that patient can be multiplied. The resulting LR product depends on both the number of characteristics and the LR of each characteristic. If the LR product is 20, the resulting disease probability will be 50%, if the LR product is 80, the disease probability will be 80%, and if the LR product is 200, the disease probability will be > 90%. A post-test probability of 90% or more (LR product ≥ 200) is regarded as definite disease, and a post-test probability of 80% to 89% is regarded as probable disease. This mathematical approach to clinical diagnosis and diagnostic probability is not meant to be routinely used in clinical practice; instead, it provides a framework of reasoning when considering the possibility of axial undifferentiated SpA. In this example, the presence of any 4 criteria will at least result in a LR product of 215 if you multiply the smallest 4 individual LR ($3.1 \times 3.4 \times 4 \times 5.1$). If any imaging criterion is present and the patient has HLA-B27, the presence of any additional clinical criterion in a patient with chronic inflammatory back pain will result in a diagnosis of AS with a reasonable level of confidence (for further details see Rudwaleit, *et al*¹⁸). CRP: C-reactive protein; ESR: erythrocyte sedimentation rate; LR: likelihood ratio; MRI: magnetic resonance imaging; NSAID: nonsteroidal antiinflammatory drugs; SI: sacroiliac; SpA: spondyloarthropathy; STIR: short-tau inversion recovery. From Rudwaleit, *et al.* *Ann Rheum Dis* 2004;63:535-43, with permission.

al radiographs²¹. MRI can also detect disease-related changes in the dura mater, soft tissues, and spinal ligaments, as well as inflammatory changes caused by enthesitis, fractures, or pseudoarthrosis³⁸. In addition, using MRI techniques to identify sacroiliitis is preferable in women of child-bearing age and in children and adolescents because it does not expose patients to radiation^{79,81}. Therefore, MRI is the most recent milestone in the diagnosis of the pre-radiographic phase of AS^{21,83,84}. However, a clear definition of positive and negative findings and additional data on the sensitivity and specificity of MRI in patients with early disease are needed and are under active investigation.

Early changes seen on conventional radiography include squaring of the vertebral bodies and formation of syndesmophytes⁷⁵. Spondylodiscitis, ligament ossification, and involvement of the facet joints can also be present. Spinal osteoporosis is frequently seen in patients with AS, especially in patients with longterm severe disease. The risk of vertebral compression fractures and pseudoarthrosis are increased in patients with spinal

osteoporosis³⁸. Dual x-ray absorptiometry is useful as a screening tool for osteoporosis in patients with AS, but presence of hip arthroplasty or extensive ligamentous ossification (bamboo spine) can influence the results.

Enthesitis may be detected radiographically, but not in early stages^{75,85}. Ultrasound and MRI, on the other hand, can detect early inflammatory changes even before they appear on conventional radiographs⁸⁵. It should be noted that conventional radiography and MRI can sometimes demonstrate some differences among patients with primary AS compared with psoriatic spondylitis and spondylitis in association with reactive arthritis (the so-called secondary form of spondylitis)^{86,87}.

LABORATORY FINDINGS

Ankylosing spondylitis has no specific laboratory markers that support diagnosis. Acute phase reactants such as elevated CRP and ESR are often used as part of the laboratory investigations of inflammatory rheumatic diseases. Other acute phase responses include elevated ferritin, mild thrombocytosis, and low albumin. The clinical

use of ESR and CRP is somewhat limited, however, for diagnosing AS or related SpA because of their suboptimal sensitivity, although they have some clinical value (with an estimated LR of 2.5)^{18,88,89}. Although these tests usually correlate better with RA and polymyalgia rheumatica, they have less precise correlation with disease activity in AS. Elevated ESR and CRP are more commonly found in AS patients with peripheral arthritis than in those with only axial disease⁸⁸. Positive rheumatoid factor and antinuclear antibody tests are not specific, nor are synovial fluid analysis and synovial biopsy³⁸. Testing for stool occult blood may be of value for inflammatory bowel disease.

HLA-B27 testing should not be used as a routine screening test because AS and other SpA can occur in the absence of HLA-B27⁹⁰, and HLA-B27 is present in healthy people (about 6% to 10% in Europe and slightly higher in Scandinavian countries, range 10%–16%)^{91,92}. The risk is 20% for development of any type of SpA among HLA-B27-positive individuals of European descent who have a first-degree relative with HLA-B27-positive AS⁹³.

The prevalence of HLA-B27 and the strength of its association with AS differ markedly among various ethnic and racial groups worldwide⁹⁴. For example, HLA-B27 is present in 3% of the African American general population and only about 50% of patients with AS^{95,96}.

Thus a negative test is not clinically helpful, but a positive test is more helpful diagnostically in African Americans (LR ~17) than in Caucasians (LR ~10)⁹⁷. Nevertheless, HLA-B27 may be of value as an aid to diagnosis in certain clinical situations⁹⁰. The value of the HLA-B27 test in diagnosing AS depends on the individual pretest probability of the disease and the patient's ethnicity. The test is most useful when the physician faces a clinical situation with a pretest probability of about 50% (toss-up) in the presence of equivocal findings on SI imaging; the HLA-B27 testing can be used as a tie-breaker⁹⁷.

ADVANCES IN DIAGNOSTIC CRITERIA

As mentioned above, radiographs are often normal in the early years of AS, and it usually takes several years for sacroiliitis to become radiographically evident¹⁷. This has often resulted in about a 3- to 11-year delay (or longer) in diagnosis^{13,22,23,25,26}. Thus, diagnosing AS in the absence of radiographic sacroiliitis can be challenging to many physicians. Attempts have been made in the past to classify SpA with predominant axial involvement before radiographic changes can be detected^{76,98-101}. The introduction of undifferentiated SpA as one of the subtypes of SpA was a major step forward. Decision trees have been proposed to help make an early diagnosis of axial undifferentiated SpA with greater confidence, and these include all clinically relevant characteristics, including

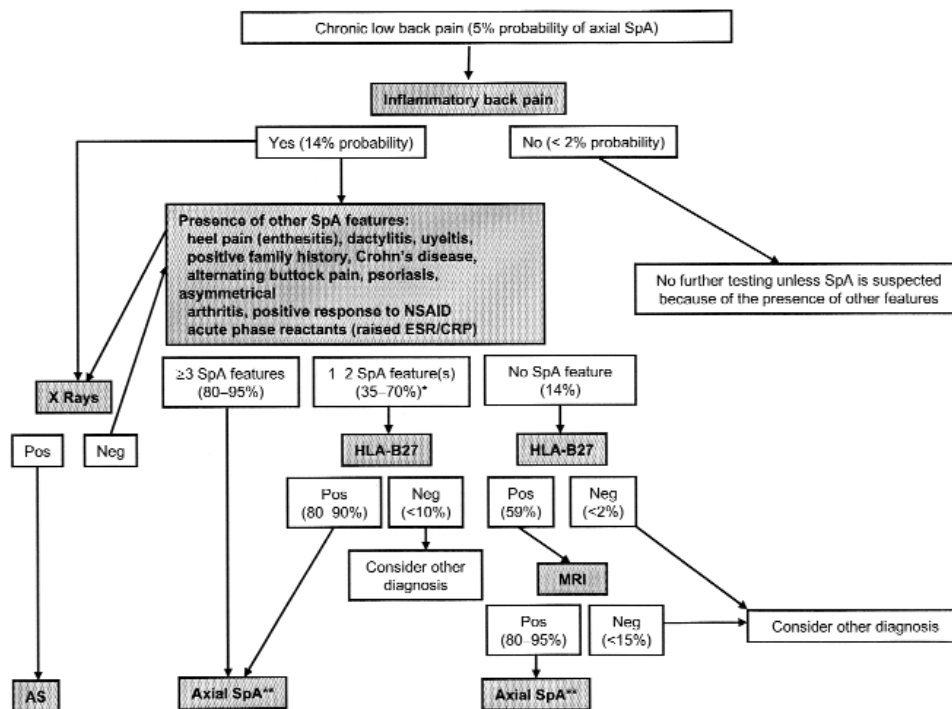


Figure 4. Decision tree to assist in the diagnosis of axial spondyloarthritis. AS: ankylosing spondylitis; CRP: C-reactive protein; ESR: erythrocyte sedimentation rate; MRI: magnetic resonance imaging; Neg: negative; NSAID: nonsteroidal antiinflammatory drugs; Pos: positive; SpA: spondyloarthritis. From Rudwaleit M, et al. *Ann Rheum Dis* 2004;63:535-43, with permission.

MRI findings (Figure 4)¹⁰². Some of the characteristics considered to be relevant for the diagnosis of axial spondyloarthritis are shown in Figure 3, and the legend explains their utility for diagnostic purposes. The clinical utility is different for each characteristic (shown as LR in Figure 3). Based on the considerations of LR and disease probabilities, it was suggested that the presence of 4 or more features of axial spondyloarthritis provides strong support for diagnosis of axial undifferentiated spondyloarthritis in the absence of radiographic sacroiliitis in a patient with chronic inflammatory back pain¹⁸. An international effort is under way to develop criteria for diagnosis of pre-radiographic AS (i.e., axial undifferentiated spondyloarthritis)¹⁸.

CASE STUDIES

Case 1. A 41-year-old Caucasian woman presented with chronic low back pain and stiffness for 2 years. The pain gets worse after inactivity and wakes her up late at night and early in the morning. She feels better after physical activity. The onset of low back pain was preceded by episodic alternating buttock pain for about 2 years. She also has had chest pain that is accentuated when sneezing and coughing. Her back has been gradually becoming stiffer, which has caused her difficulty in performing activities of daily living. She has had 8 episodes of HLA-B27-associated acute anterior uveitis (acute iritis) during the last 20 years and upper back pain (between shoulder blades) and sometimes pain in the lower cervical spine for 10 years. She has seen many doctors and has had many tests, including radiographs and bone scans. She had been previously treated with full doses of different non-steroidal antiinflammatory drugs (NSAID) without much relief. She was told she had fibromyalgia. Her personal and family medical histories were unremarkable. On examination she walked with a slightly stiff gait. She had tenderness over lower cervical spinal processes, over the whole thoracolumbar spine, and over both SI joints. She had diminished lumbar spinal motion in all planes (Schober's test showed only 2 cm mobility). Her neck motion was decreased in all planes. Chest expansion was only 3 cm. Her BASDAI score was high, indicating active disease. Laboratory tests showed elevation of ESR and CRP. A recent radiograph of the pelvis did not show definite evidence of sacroiliitis. MRI (STIR technique without gadolinium enhancement) clearly showed areas of edema of the sacrum and ilium adjacent to both SI joints, indicative of bilateral sacroiliitis and confirming the clinical diagnosis of AS.

This case exemplifies the frequent difficulties in establishing a definite diagnosis in the absence of sacroiliitis on conventional radiograph. It also confirms the role of MRI in making the diagnosis very clear. This patient was subsequently treated with a tumor necrosis factor (TNF)

antagonist, with excellent response. If we apply the concept of LR product here without knowing the results of the HLA-B27 or the MRI, we will have the following result: LR product equal to 56 ($3.1 \times 7.3 \times 2.5$; LR for inflammatory back pain, acute anterior uveitis, and elevated CRP/ESR), which corresponds to a post-test probability of about 75%. Knowing that the HLA-B27 was positive will bring the LR product up to 509, which corresponds to a post-test probability of 96% before knowing the results of the MRI. This exemplifies that a positive HLA-B27 can facilitate the diagnosis when conventional imaging is inconclusive and MRI is not available or feasible.

Case 2. A 41-year-old Middle Eastern woman presented with severe back pain and stiffness that did not respond to full doses of different NSAID. She had seen many physicians in more than one country, and her pain was thought to be due to active inflammation from her longstanding AS. She recalled that she was treated with methotrexate at one stage, which caused hair loss but did not relieve her symptoms. She was told that conventional radiography showed typical changes of advanced AS with bamboo spine.

A review of her clinical history revealed that her back pain worsened with physical activity, and radiography suggested the presence of discitis or pseudoarthrosis in her lumbar spine. MRI demonstrated pseudoarthrosis of her midlumbar spine, the cause of her pain. Initial treatment with a lumbar brace did not help, so she underwent spinal fusion with 2 metal rods, and subsequently all her pain resolved. This case exemplifies the importance of vigilance for the complications of AS.

CONCLUSIONS

Ankylosing spondylitis is a common disease that can result in early retirement and severe functional disability. Early diagnosis has become more important since the advent of effective biological therapies, including TNF antagonists, which suppress disease activity and improve function in disease refractory to conventional drug therapy. To optimize diagnostic accuracy of early disease, a comprehensive approach is crucial, with deep understanding of the disease and its clinical picture. The clinician should gather a complete history, do an appropriate physical examination with close attention to elements of multisystem disease, and judiciously utilize laboratory testing and appropriate imaging modalities. A common, early feature of the disease, and possibly the first manifestation in most patients, is inflammation of the SI joints and spine. Therefore, early detection is important, and MRI has proven useful in this regard. Thus absence of radiographic sacroiliitis during early years of disease should not rule out a diagnosis of AS, especially when the

presence of inflammation can be detected by other imaging modalities, such as MRI. New strategies being developed to help primary care physicians screen for these patients should assist in early referral to rheumatologists at an early stage of disease, resulting in an early diagnosis.

ACKNOWLEDGMENT

The authors wish to thank Debra Stamper, PhD, whose work was funded by Amgen, Inc., for her help in drafting this report.

REFERENCES

1. Khan MA. Update on spondyloarthropathies. *Ann Intern Med* 2002;136:896-907.
2. Gran JT, Husby G, Hordvik M. Prevalence of ankylosing spondylitis in males and females in a young middle-aged population of Tromsø, northern Norway. *Ann Rheum Dis* 1985;44:359-67.
3. Kaipainen-Seppänen O, Aho K, Heliovaara M. Incidence and prevalence of ankylosing spondylitis in Finland. *J Rheumatol* 1997;24:496-9.
4. Alamanos Y, Papadopoulos NG, Voulgari PV, Karakatsanis A, Siozos C, Drosos AA. Epidemiology of ankylosing spondylitis in Northwest Greece, 1983-2002. *Rheumatology Oxford* 2004;43:615-8.
5. Boyer GS, Templin DW, Cornoni-Huntley JC, et al. Prevalence of spondyloarthropathies in Alaskan Eskimos. *J Rheumatol* 1994;21:2292-7.
6. Braun J, Bollow M, Remlinger G, et al. Prevalence of spondyloarthropathies in HLA-B27 positive and negative blood donors. *Arthritis Rheum* 1998;41:58-67.
7. Dai SM, Han XH, Zhao DB, Shi YQ, Liu Y, Meng JM. Prevalence of rheumatic symptoms, rheumatoid arthritis, ankylosing spondylitis, and gout in Shanghai, China: a COPCORD study. *J Rheumatol* 2003;30:2245-51.
8. Hukuda S, Minami M, Saito T, et al. Spondyloarthropathies in Japan: nationwide questionnaire survey performed by the Japan Ankylosing Spondylitis Society. *J Rheumatol* 2001;28:554-9.
9. van der Linden SM, Valkenburg HA, de Jongh BM, Cats A. The risk of developing ankylosing spondylitis in HLA-B27 positive individuals. A comparison of relatives of spondylitis patients with the general population. *Arthritis Rheum* 1984;27:241-9.
10. Trontzas P, Andrianakos A, Miyakis S, et al. Seronegative spondyloarthropathies in Greece: a population-based study of prevalence, clinical pattern, and management. The ESORDIG study. *Clin Rheumatol* 2005;24:583-9.
11. Akkoc N, Khan MA. Overestimation of the prevalence of ankylosing spondylitis in the Berlin study: Comment on the article by Braun et al [letter]. *Arthritis Rheum* 2005;52:4048-9.
12. Sieper J, Braun J, Rudwaleit M, Boonen A, Zink A. Ankylosing spondylitis: an overview. *Ann Rheum Dis* 2002;61 Suppl 3:iii8-18.
13. Feldtkeller E, Khan MA, van der Heijde D, van der Linden S, Braun J. Age at disease onset and diagnosis delay in HLA-B27 negative vs. positive patients with ankylosing spondylitis. *Rheumatol Int* 2003;23:61-6.
14. Zink A, Braun J, Listing J, Wollenhaupt J. Disability and handicap in rheumatoid arthritis and ankylosing spondylitis — results from the German rheumatological database. German Collaborative Arthritis Centers. *J Rheumatol* 2000;27:613-22.
15. Braun J, Sieper J, Breban M, et al. Anti-tumour necrosis factor alpha therapy for ankylosing spondylitis: international experience. *Ann Rheum Dis* 2002;61 Suppl 3:iii51-60.
16. Mau W, Zeidler H, Mau R, et al. Evaluation of early diagnostic criteria for ankylosing spondylitis in a 10 year follow-up. *Z Rheumatol* 1990;49:82-7.
17. Mau W, Zeidler H, Mau R, et al. Clinical features and prognosis of patients with possible ankylosing spondylitis. Results of a 10-year followup. *J Rheumatol* 1988;15:1109-14.
18. Rudwaleit M, Khan MA, Sieper J. The challenge of diagnosis and classification in early ankylosing spondylitis: do we need new criteria? *Arthritis Rheum* 2005;52:1000-8.
19. Boyer GS, Templin DW, Bowler A, et al. A comparison of patients with spondyloarthropathy seen in specialty clinics with those identified in a communitywide epidemiologic study. Has the classic case misled us? *Arch Intern Med* 1997;157:2111-7.
20. Said-Nahal R, Miceli-Richard C, Berthelot JM, et al. The familial form of spondylarthropathy: a clinical study of 115 multiplex families. *Groupe Francais d'Etude Genetique des Spondylarthropathies. Arthritis Rheum* 2000;43:1356-65.
21. Oostveen J, Prevo R, den Boer J, van de Laar M. Early detection of sacroiliitis on magnetic resonance imaging and subsequent development of sacroiliitis on plain radiography. A prospective, longitudinal study. *J Rheumatol* 1999;26:1953-8.
22. Calin A, Elswood J, Rigg S, Skevington SM. Ankylosing spondylitis — an analytical review of 1500 patients: the changing pattern of disease. *J Rheumatol* 1988;15:1234-8.
23. Feldtkeller E, Bruckel J, Khan MA. Scientific contributions of ankylosing spondylitis patient advocacy groups. *Curr Opin Rheumatol* 2000;12:239-47.
24. Kidd BL, Cawley MI. Delay in diagnosis of spondylarthritis. *Br J Rheumatol* 1988;27:230-2.
25. Khan MA. Ankylosing spondylitis: introductory comments on its diagnosis and treatment. *Ann Rheum Dis* 2002;61 Suppl 3:iii3-7.
26. van der Linden S, Valkenburg HA, Cats A. Evaluation of diagnostic criteria for ankylosing spondylitis. A proposal for modification of the New York criteria. *Arthritis Rheum* 1984;27:361-8.
27. Stone M, Warren RW, Bruckel J, Cooper D, Cortinovis D, Inman RD. Juvenile-onset ankylosing spondylitis is associated with worse functional outcomes than adult-onset ankylosing spondylitis. *Arthritis Rheum* 2005;53:445-51.
28. Khan MA. Thoughts concerning the early diagnosis of ankylosing spondylitis and related diseases. *Clin Exp Rheumatol* 2002;20 Suppl 28:S6-10.
29. van der Linden S, van der Heijde D, Braun J. Ankylosing spondylitis. In: Harris EJ, Budd R, Firestein GS, Genovese MC, Sledge CB, editors. *Kelley's textbook of rheumatology*. 7th ed. Philadelphia: Elsevier Saunders; 2005:1125-41.
30. Calin A, Porta J, Fries JF, Schurman DJ. Clinical history as a screening test for ankylosing spondylitis. *JAMA* 1977;237:2613-4.
31. Carette S, Graham D, Little H, Rubenstein J, Rosen P. The natural disease course of ankylosing spondylitis. *Arthritis Rheum* 1983;26:186-90.
32. Cats A, van der Linden SJ, Goei The HS, Khan MA. Proposals for diagnostic criteria of ankylosing spondylitis and allied disorders. *Clin Exp Rheumatol* 1987;5:167-71.
33. Khan MA, van der Linden SM. A wider spectrum of spondyloarthropathies. *Semin Arthritis Rheum* 1990;20:107-13.
34. Khan MA, van der Linden SM, Kushner I, Valkenburg HA, Cats A. Spondylitic disease without radiologic evidence of sacroiliitis in relatives of HLA-B27 positive ankylosing spondylitis patients. *Arthritis Rheum* 1985;28:40-3.
35. van der Heijde D. New directions in classification and outcome assessment in ankylosing spondylitis. *Curr Rheumatol Rep* 2004;6:98-101.
36. van Tubergen A, Heuft-Dorenbosch L, Schulpen G, et al.

- Radiographic assessment of sacroiliitis by radiologists and rheumatologists: does training improve quality? *Ann Rheum Dis* 2003;62:519-25.
37. Rudwaleit M. Inception cohort on spondyloarthritides. (Personal communication).
 38. Khan MA. Clinical features of ankylosing spondylitis. In: Hochberg M, Silman A, Smolen J, Weinblatt M, Weinblatt M, editors. *Rheumatology*. London: Mosby: A Division of Harcourt Health Sciences Ltd; 2003:1161-81.
 39. Helewa A, Stokes B. Spondylarthropathies. In: Robbins L, Burckhardt C, Hannan MT, DeHoratius RJ, editors. *Clinical care in the rheumatic diseases*. 2nd ed. Atlanta: Association of Rheumatology Health Professionals; 2001:105-11.
 40. Khan MA. Spondylarthropathies. In: Hunder GG, editor. *Atlas of rheumatology*. Philadelphia: Current Medicine; 2002:141-67.
 41. Olivieri I, Barozzi L, Padula A, De Matteis M, Pavlica P. Clinical manifestations of seronegative spondylarthropathies. *Eur J Radiol* 1998;27 Suppl 1:S3-6.
 42. Bennett DL, Ohashi K, El-Khoury GY. Spondylarthropathies: ankylosing spondylitis and psoriatic arthritis. *Radiol Clin North Am* 2004;42:121-34.
 43. Benjamin M, McGonagle D. The anatomical basis for disease localisation in seronegative spondylarthropathy at entheses and related sites. *J Anat* 2001;199 Pt 5:503-26.
 44. Banares A, Hernandez-Garcia C, Fernandez-Gutierrez B, Jover JA. Eye involvement in the spondylarthropathies. *Rheum Dis Clin North Am* 1998;24:771-84, ix.
 45. Khan MA, Kushner I, Braun WE. Comparison of clinical features in HLA-B27 positive and negative patients with ankylosing spondylitis. *Arthritis Rheum* 1977;20:909-12.
 46. Fernandez-Melon J, Munoz-Fernandez S, Hidalgo V, et al. Uveitis as the initial clinical manifestation in patients with spondylarthropathies. *J Rheumatol* 2004;31:524-7.
 47. Monnet D, Breban M, Hudry C, Dougados M, Brezin AP. Ophthalmic findings and frequency of extraocular manifestations in patients with HLA-B27 uveitis: a study of 175 cases. *Ophthalmology* 2004;111:802-9.
 48. Smale S, Natt RS, Orchard TR, Russell AS, Bjarnason I. Inflammatory bowel disease and spondylarthropathy. *Arthritis Rheum* 2001;44:2728-36.
 49. De Keyser F, Baeten D, van den Bosch F, et al. Gut inflammation and spondylarthropathies. *Curr Rheumatol Rep* 2002;4:525-32.
 50. Bergfeldt L. HLA-B27-associated cardiac disease. *Ann Intern Med* 1997;127 Pt 1:621-9.
 51. Rosenow E, Strimlan CV, Muhm JR, Ferguson RH. Pleuropulmonary manifestations of ankylosing spondylitis. *Mayo Clin Proc* 1977;52:641-9.
 52. Turetschek K, Ebner W, Fleischmann D, et al. Early pulmonary involvement in ankylosing spondylitis: assessment with thin-section CT. *Clin Radiol* 2000;55:632-6.
 53. Dagfinrud H, Vollestad NK, Loge JH, Kvien TK, Mengshoel AM. Fatigue in patients with ankylosing spondylitis: A comparison with the general population and associations with clinical and self-reported measures. *Arthritis Rheum* 2005;53:5-11.
 54. Divecha H, Sattar N, Rumley A, Cherry L, Lowe GD, Sturrock R. Cardiovascular risk parameters in men with ankylosing spondylitis in comparison with non-inflammatory control subjects: relevance of systemic inflammation. *Clin Sci Lond* 2005;109:171-6.
 55. Moses S. Ankylosing spondylitis. Available at: <http://www.fpnotebook.com/RHE133.htm>. Accessed May 18, 2006.
 56. van der Linden SM, Khan MA, Rentsch HU, et al. Chest pain without radiographic sacroiliitis in relatives of patients with ankylosing spondylitis. *J Rheumatol* 1988;15:836-9.
 57. Dawes PT, Sheeran TP, Hothersall TE. Chest pain — a common feature of ankylosing spondylitis. *Postgrad Med J* 1988;64:27-9.
 58. Moll JM, Wright V. An objective clinical study of chest expansion. *Ann Rheum Dis* 1972;31:1-8.
 59. Moll JM, Wright V. The pattern of chest and spinal mobility in ankylosing spondylitis. An objective clinical study of 106 patients. *Rheumatol Rehabil* 1973;12:115-34.
 60. van der Heijde D, Calin A, Dougados M, Khan MA, van der Linden S, Bellamy N. Selection of instruments in the core set for DC-ART, SMARD, physical therapy, and clinical record keeping in ankylosing spondylitis. Progress report of the ASAS Working Group. Assessments in Ankylosing Spondylitis. *J Rheumatol* 1999;26:951-4.
 61. Domjan L, Nemes T, Balint GP, Toth Z, Gomor B. A simple method for measuring lateral flexion of the dorsolumbar spine. *J Rheumatol* 1990;17:663-5.
 62. Haywood KL, Garratt AM, Jordan K, Dziedzic K, Dawes PT. Spinal mobility in ankylosing spondylitis: reliability, validity and responsiveness. *Rheumatology Oxford* 2004;43:750-7.
 63. Heuft-Dorenbosch L, Vosse D, Landewe R, et al. Measurement of spinal mobility in ankylosing spondylitis: comparison of occiput-to-wall and tragus-to-wall distance. *J Rheumatol* 2004;31:1779-84.
 64. Brophy S, Mackay K, Al-Saidi A, Taylor G, Calin A. The natural history of ankylosing spondylitis as defined by radiological progression. *J Rheumatol* 2002;29:1236-43.
 65. Vosse D, Feldtkeller E, Erelndsson J, Geusens P, van der Linden S. Clinical vertebral fractures in patients with ankylosing spondylitis. *J Rheumatol* 2004;31:1981-5.
 66. Gratacos J, Collado A, Pons F, et al. Significant loss of bone mass in patients with early, active ankylosing spondylitis: a follow up study. *Arthritis Rheum* 1999;42:2319-24.
 67. Lange U, Jung O, Teichmann J, Neeck G. Relationship between disease activity and serum levels of vitamin D metabolites and parathyroid hormone in ankylosing spondylitis. *Osteoporos Int* 2001;12:1031-5.
 68. Tico N, Ramon S, Garcia-Ortun F, et al. Traumatic spinal cord injury complicating ankylosing spondylitis. *Spinal Cord* 1998;36:349-52.
 69. Hitchon PW, From AM, Brenton MD, Glaser JA, Torner JC. Fractures of the thoracolumbar spine complicating ankylosing spondylitis. *J Neurosurg* 2002;97 Suppl:218-22.
 70. Langlois S, Cedoz JP, Lohse A, Toussiro E, Wendling D. Aseptic discitis in patients with ankylosing spondylitis: a retrospective study of 14 cases. *Joint Bone Spine* 2005;72:248-53.
 71. Ginsburg WW, Cohen MD, Miller GM, Bartleson JD. Posterior vertebral body erosion by arachnoid diverticula in cauda equina syndrome: an unusual manifestation of ankylosing spondylitis. *J Rheumatol* 1997;24:1417-20.
 72. Bilgen IG, Yuntun N, Ustun EE, Oksel F, Gumusdis G. Adhesive arachnoiditis causing cauda equina syndrome in ankylosing spondylitis: CT and MRI demonstration of dural calcification and a dorsal dural diverticulum. *Neuroradiology* 1999;41:508-11.
 73. Thompson GH, Khan MA, Bilenker RM. Spontaneous atlantoaxial subluxation as a presenting manifestation of juvenile ankylosing spondylitis. A case report. *Spine* 1982;7:78-9.
 74. Shim SC, Yoo DH, Lee JK, et al. Multiple cerebellar infarction due to vertebral artery obstruction and bulbar symptoms associated with vertical subluxation and atlanto-occipital subluxation in ankylosing spondylitis. *J Rheumatol* 1998;25:2464-8.
 75. Barozzi L, Olivieri I, De Matteis M, Padula A, Pavlica P. Seronegative spondylarthropathies: imaging of spondylitis, enthesitis and dactylitis. *Eur J Radiol* 1998;27 Suppl 1:S12-7.
 76. Doodads M. Diagnostic features of ankylosing spondylitis. *Br J Rheumatol* 1995;34:301-5.

77. Gofton JP, Lawrence JS, Bennett PH, Burch TA. Sacroiliitis in eight populations. *Ann Rheum Dis* 1966;25:528-33.
78. Brandt J, Bollow M, Haberle J, et al. Studying patients with inflammatory back pain and arthritis of the lower limbs clinically and by magnetic resonance imaging: many, but not all patients with sacroiliitis have spondyloarthropathy. *Rheumatology Oxford* 1999;38:831-6.
79. Braun J, Bollow M, Sieper J. Radiologic diagnosis and pathology of the spondyloarthropathies. *Rheum Dis Clin North Am* 1998;24:697-735.
80. Baraliakos X, Hermann KG, Landewe R, et al. Assessment of acute spinal inflammation in patients with ankylosing spondylitis by magnetic resonance imaging: a comparison between contrast enhanced T1 and short tau inversion recovery (STIR) sequences. *Ann Rheum Dis* 2005;64:1141-4.
81. Braun J, van der Heijde D. Imaging and scoring in ankylosing spondylitis. *Best Pract Res Clin Rheumatol* 2002;16:573-604.
82. Hermann KG, Landewe RB, Braun J, van der Heijde DM. Magnetic resonance imaging of inflammatory lesions in the spine in ankylosing spondylitis clinical trials: is paramagnetic contrast medium necessary? *J Rheumatol* 2005;32:2056-60.
83. Ahlstrom H, Feltelius N, Nyman R, Hallgren R. Magnetic resonance imaging of sacroiliac joint inflammation. *Arthritis Rheum* 1990;33:1763-9.
84. Braun J, Bollow M, Eggens U, Konig H, Distler A, Sieper J. Use of dynamic magnetic resonance imaging with fast imaging in the detection of early and advanced sacroiliitis in spondylarthropathy patients. *Arthritis Rheum* 1994;37:1039-45.
85. Francois RJ, Braun J, Khan MA. Entheses and enthesitis: a histopathologic review and relevance to spondyloarthritides. *Curr Opin Rheumatol* 2001;13:255-64.
86. Kettering JM, Towers JD, Rubin DA. The seronegative spondyloarthropathies. *Semin Roentgenol* 1996;31:220-8.
87. Ory PA, Gladman DD, Mease PJ. Psoriatic arthritis and imaging. *Ann Rheum Dis* 2005;64 Suppl 2:ii55-7.
88. Spoorenberg A, van der Heijde D, de Klerk E, et al. Relative value of erythrocyte sedimentation rate and C-reactive protein in assessment of disease activity in ankylosing spondylitis. *J Rheumatol* 1999;26:980-4.
89. Dougados M, Gueguen A, Nakache JP, et al. Clinical relevance of C-reactive protein in axial involvement of ankylosing spondylitis. *J Rheumatol* 1999;26:971-4.
90. Gran JT, Husby G. HLA-B27 and spondyloarthropathy: value for early diagnosis? *J Med Genet* 1995;32:497-501.
91. Khan MA. HLA-B27 and its subtypes in world populations. *Curr Opin Rheumatol* 1995;7:263-9.
92. Brown MA, Pile KD, Kennedy LG, et al. HLA class I associations of ankylosing spondylitis in the white population in the United Kingdom. *Ann Rheum Dis* 1996;55:268-70.
93. van der Linden SM, Khan MA. The risk of ankylosing spondylitis in HLA-B27 positive individuals: a reappraisal. *J Rheumatol* 1984;11:727-8.
94. Khan M. Prevalence of HLA-B27 in world populations. In: Lopez-Larrea C, editor. *HLA-B27 in the development of spondyloarthropathies*. Austin, TX: RG Landes Company; 1997:95-112.
95. Khan MA, Braun WE, Kushner I, Grecek DE, Muir WA, Steinberg AG. HLA B27 in ankylosing spondylitis: differences in frequency and relative risk in American Blacks and Caucasians. *J Rheumatol* 1977;4 Suppl 3:39-43.
96. Khan MA. Clinical application of the HLA-B27 test in rheumatic diseases. A current perspective. *Arch Intern Med* 1980;140:177-80.
97. Khan MA, Khan MK. Diagnostic value of HLA-B27 testing in ankylosing spondylitis and Reiter's syndrome. *Ann Intern Med* 1982;96:70-6.
98. Dougados M, van der Linden S, Juhlin R, et al. The European Spondylarthropathy Study Group preliminary criteria for the classification of spondylarthropathy. *Arthritis Rheum* 1991;34:1218-27.
99. Amor B, Dougados M, Mijiyawa M. Criteria of the classification of spondylarthropathies [French]. *Rev Rhum Mal Osteoartic* 1990;57:85-9.
100. Amor B. Usefulness of criteria for spondyloarthropathies. *Joint Bone Spine* 2000;67:502-3.
101. Zeidler H, Mau R, Mau W, Freyschmidt J, Majewski A, Deicher H. Evaluation of early diagnostic criteria including HLA-B27 for ankylosing spondylitis in a follow-up study. *Z Rheumatol* 1985;44:249-53.
102. Rudwaleit M, van der Heijde D, Khan MA, Braun J, Sieper J. How to diagnose axial spondyloarthritis early. *Ann Rheum Dis* 2004;63:535-43.