

# Nail Enthesis Ultrasound in Psoriasis and Psoriatic Arthritis: A Report from the 2016 GRAPPA Annual Meeting

Joanne Szczygiel Cunha, Abrar A. Qureshi, and Anthony M. Reginato

**ABSTRACT.** Musculoskeletal ultrasonography is gaining favor in the evaluation of enthesitis in patients with psoriasis and psoriatic arthritis (PsA). Imaging modalities have shown that the enthesis of the distal interphalangeal joint has a close relationship to the nail itself. Studies have focused on the structure and morphology of nails to determine an association between psoriasis nail changes and the presence or severity of PsA. With the use of higher frequency probes, power Doppler (PD) can determine subclinical inflammation of the area under ultrasound examination. At the 2016 meeting of the Group for Research and Assessment of Psoriasis and Psoriatic Arthritis (GRAPPA), we proposed an ultrasonographic index for the assessment of the nail enthesis to identify the morphologic and PD findings of the nail, with the potential that both rheumatologists and dermatologists can use it to evaluate their patients. (J Rheumatol 2017;44:688–90; doi:10.3899/jrheum.170146)

## Key Indexing Terms:

MUSCULOSKELETAL ULTRASONOGRAPHY      PSORIASIS      PSORIATIC ARTHRITIS  
NAIL BED      NAIL PLATE      GRAPPA

## Nail Anatomy

About 10%–55% of patients with psoriasis have clinical nail involvement<sup>1</sup>. About 53%–86% of patients with psoriatic arthritis (PsA) have nail disease<sup>2</sup>, most commonly onycholysis and nail pitting, which have been found to predict the development of PsA<sup>3</sup>. Magnetic resonance imaging of the nail enthesis demonstrated an association between the nail, distal phalanx, and distal interphalangeal (DIP) joint<sup>4</sup>.

The nail unit is composed of the nail plate, matrix, and bed (Figure 1)<sup>5</sup>. The nail plate has 3 layers (dorsal, intermediate, and ventral), each corresponding to their respective nail matrices (dorsal, intermediate, and ventral), and lies over the distal phalanx, with the nail bed extending from the distal phalanx to the ventral portion of the nail plate. Inflammation that occurs in either the nail matrix or nail bed will cause clinical PsA nail changes<sup>6</sup>.

---

*From the Division of Rheumatology, and Division of Dermatology, The Warren Alpert Medical School of Brown University, Providence, Rhode Island, USA.*

*As part of the supplement series GRAPPA 2016, this report was reviewed internally and approved by the Guest Editors for integrity, accuracy, and consistency with scientific and ethical standards.*

*J.S. Cunha, MD, Division of Rheumatology, The Warren Alpert Medical School of Brown University; A.A. Qureshi, MD, Division of Dermatology, The Warren Alpert Medical School of Brown University; A.M. Reginato, PhD, MD, Division of Rheumatology, The Warren Alpert Medical School of Brown University.*

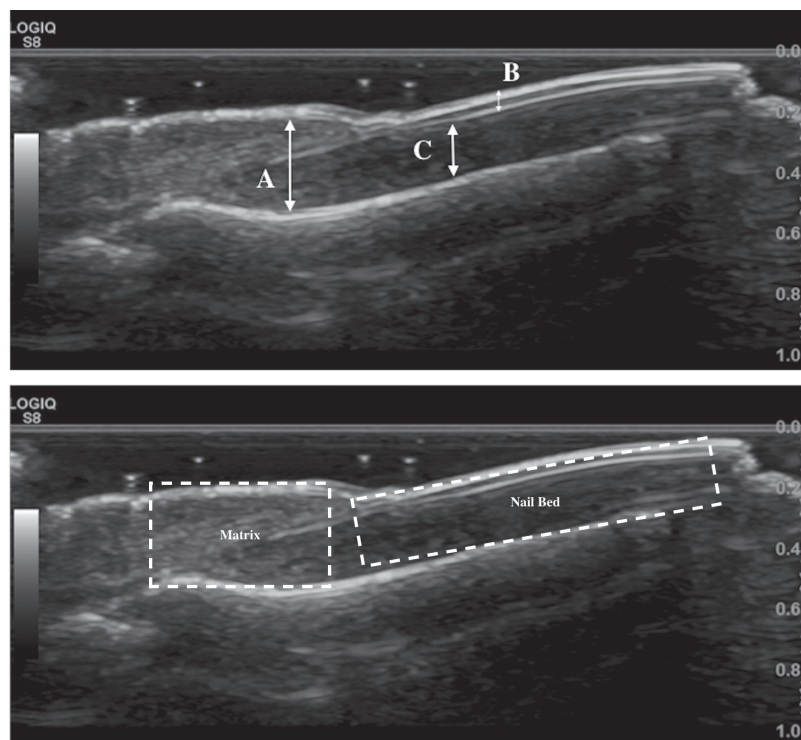
*Address correspondence to Dr. J.S. Cunha, Division of Rheumatology, The Warren Alpert Medical School of Brown University, 375 Wampanoag Trail, Suite 202, East Providence, Rhode Island 02915, USA.  
E-mail: Joanne\_szczygiel@brown.edu*

## Nail Enthesis

The digital extensor tendon crosses the DIP joint, inserting into the distal phalanx where connective tissue fibers link the extensor tendon to the nail root and matrix at its insertion point<sup>7</sup>. The extensor tendon and collateral ligaments of the interphalangeal joint merge with the joint capsule, forming a close association with the underlying synovium<sup>8</sup>. Because it arises from the nail matrix, the nail plate is closely associated with the digital extensor tendon enthesis. It is thought that inflammation begins in the nail and moves proximally to the distal phalanx, involving the synovio-entheseal complex and eventually the DIP joint<sup>6</sup>.

## Normal Nail Ultrasound (US)

High-frequency transducers available on US machines with power Doppler (PD) provide intricate details of nails, soft tissue structures, and microvasculature<sup>9</sup>. The structures of a healthy nail can be visualized as 2 hyperechoic lines representing the dorsal and ventral areas of the nail plate, with a virtual anechoic space between them serving as the intermediate nail plate<sup>10</sup>. The nail bed appears as a hypoechoic band under the nail plate and the distal phalanx is a hyperechoic line under the nail bed. The nail matrix is visualized as an isoechoic region under the proximal nailfold at the proximal portion of the nail bed. The thickness of different nail structures can be measured, but formal measurements of each have yet to be reported. Thin arterial and venous blood vessels course through the nail bed and PD imaging may show a small amount of blood flow in this area<sup>10</sup>.



**Figure 1.** (A) Areas of morphologic changes in the nail. (B) Areas (nail bed and matrix) to assess for power Doppler signaling. A: measurement of the thickness of the nail matrix; B: assessment of the morphologic changes of the nail plate; C: measurement of nail bed thickness.

## Psoriatic Nail US

Early changes (nail bed thickening and loss of definition of the ventral plate) and late findings (thickening of the ventral and dorsal plates) in psoriatic nails can be identified with US<sup>10,11</sup>. Morphologic changes of the psoriatic nail plate have been described in order of increasing severity: (1) focal hyperechoic areas of the ventral plate (without involvement of the dorsal plate), (2) loosening of the borders of the ventral plate, (3) wavy appearance of both ventral and dorsal plates, and (4) loss of definition of both plates<sup>12</sup>. The nail bed in psoriatic nails is usually thickened (2.0–3.0 mm)<sup>1,11</sup>. Blood vessels in the dermis become elongated, dilated, and tortuous as a result of inflammation, making the increased blood flow identifiable by PD<sup>10</sup>. A scoring system to quantify the PD signal activity in the areas has been developed: 0 = no signal, 1 = confluent signal in < 25% of the area, 2 = confluent signal in > 25% and < 50%, 3 = confluent signal > 50%<sup>13</sup>. Spectral Doppler is used to assess the amount and velocity of blood flow and determines the resistance index (RI), a calculation of the systolic and diastolic peak flows of small blood vessels (RI < 1 = inflammation)<sup>6</sup>.

## Brown University Nail Enthesis Scale (BUNES)

We proposed an index to evaluate the different structures of the nail and assess PD activity (Table 1) using US (Figure 1A). Normal findings would indicate a score of 0 for each

**Table 1.** Brown University Nail Enthesis Scale to evaluate nail structures. Normal findings (morphometry) = score of 0 for each area scanned; nail plate changes (B), abnormal or thickened nail beds (C), and/or matrix (A) = score of 1. Power Doppler used to assess nail bed and nail matrix, graded 1–3.

Variables	Morphometry	Power Doppler
A	0/1	0/1/2/3
B	0/1	
C	0/1	0/1/2/3
Max score	3	6

area scanned; nail plate changes and abnormal or thickened nail beds and/or matrix would receive a score of 1. Nail bed and nail matrix would be assessed with PD (Figure 1B) in longitudinal and transverse views, and graded using the scoring system described above<sup>13</sup>.

Further studies of the BUNES must be performed to determine formal measurements for all the nail structures and its validity in predicting patients at risk for developing PsA. The index has potential for use by rheumatologists and dermatologists, who are often the first to evaluate patients with psoriasis. A survey was distributed at the 2016 GRAPPA annual meeting; 67% of respondents were rheumatologists and 16% were dermatologists. Seventy-six percent of participants thought that US of the nail entheses has the potential

to evaluate the risk of developing PsA among patients with psoriasis; 78% favored training dermatologists in US. Future studies are needed to validate US in the care of patients with psoriasis, with a potential effect in both rheumatology and dermatology.

## REFERENCES

1. Sandobal C, Carbó E, Iribas J, Roverano S, Paira S. Ultrasound nail imaging on patients. *Clin Rheumatol* 2014;20:21-4.
2. El Miedany Y, El Gaafary M, Youssef S, Ahmed I, Nasr A. Tailored approach to early psoriatic arthritis patients: clinical and ultrasonographic predictors for structural joint damage. *Clin Rheumatol* 2015;34:307-13.
3. Wilson FC, Icen M, Crowson CS, McEvoy MT, Gabriel SE, Kremers HM. Incidence and clinical predictors of psoriatic arthritis in patients with psoriasis: a population-based study. *Arthritis Rheum* 2009;61:233-9.
4. Scarpa R, Soscia E, Peluso R, Atteno M, Manguso F, Del Puente A, et al. Nail and distal interphalangeal joint in psoriatic arthritis. *J Rheumatol* 2006;33:1315-9.
5. Jiaravuthisan MM, Sasseville D, Vender RB, Murphy F, Muhn CY. Psoriasis of the nail: anatomy, pathology, clinical presentation, and a review of the literature on therapy. *J Am Acad Dermatol* 2007; 57:1-27.
6. Sandre MK, Rohekar S. Psoriatic arthritis and nail changes: exploring the relationship. *Semin Arthritis Rheum* 2014;44:162-9.
7. Tan AL, Benjamin M, Toumi H, Grainger AJ, Tanner SF, Emery P, et al. The relationship between the extensor tendon enthesis and the nail in distal interphalangeal joint disease in psoriatic arthritis—a high-resolution MRI and histological study. *Rheumatology* 2007;46:253-6.
8. Benjamin M, Moriggl B, Brenner E, Emery P, McGonagle D, Redman S. The “enthesis organ” concept: why enthesopathies may not present as focal insertional disorders. *Arthritis Rheum* 2004;50:3306-13.
9. Arbault A, Devilliers H, Laroche D, Cayot A, Vabres P, Maillefert JF, et al. Reliability, validity and feasibility of nail ultrasonography in psoriatic arthritis. *Joint Bone Spine* 2016;83:539-44.
10. Gutierrez M, Wortsman X, Filippucci E, De Angelis R, Filosa G, Grassi W. High-frequency sonography in the evaluation of psoriasis: nail and skin involvement. *J Ultrasound Med* 2009;28:1569-74.
11. Marina ME, Botar Jid C, Roman II, Miha CM, Tătaru AD. Ultrasonography in psoriatic disease. *Med Ultrason* 2015;17:377-82.
12. Wortsman X, Jemec GB. Ultrasound imaging of nails. *Dermatol Clin* 2006;24:323-8.
13. Gutierrez M, Filippucci E, De Angelis R, Filosa G, Kane D, Grassi W. A sonographic spectrum of psoriatic arthritis: “the five targets”. *Clin Rheumatol* 2010;29:133-42.