

# Gamma Delta T Cell Subset V Gamma 2+ Expansion Associated with Longterm Infliximab Treatment in a Patient with Ankylosing Spondylitis

To the Editor:

Tumor necrosis factor inhibitors (TNFi) are widely used for the treatment of ankylosing spondylitis (AS), with infliximab (IFX) being approved by the US Food and Drug Administration for AS in 2004. Adverse event rates remain low for IFX, with risk of infection being the primary concern. IFX is accompanied by a black box warning highlighting reports of T cell lymphoma in young male patients with inflammatory bowel disease (IBD). These are often rare  $\gamma\delta$  T cell lymphomas occurring in the setting of concomitant immunosuppressive therapies<sup>1</sup>.

The patient, an HLA-B27+ white man, first developed back pain at the age of 19 following an episode of trauma. He was diagnosed with AS at 23 and started treatment with IFX (5 mg/kg/6 weeks) in 2003 in addition to naproxen (1000 mg/day). This patient had no comorbidities. February 2015 radiographs documented fusion of the sacroiliac joints (modified New York criteria grade 4) and spinal ankylosis (modified Stoke Ankylosing Spondylitis Spine Score = 72). He has had sustained symptomatic response to IFX with the Bath Ankylosing Spondylitis Disease Activity Index consistently < 4.

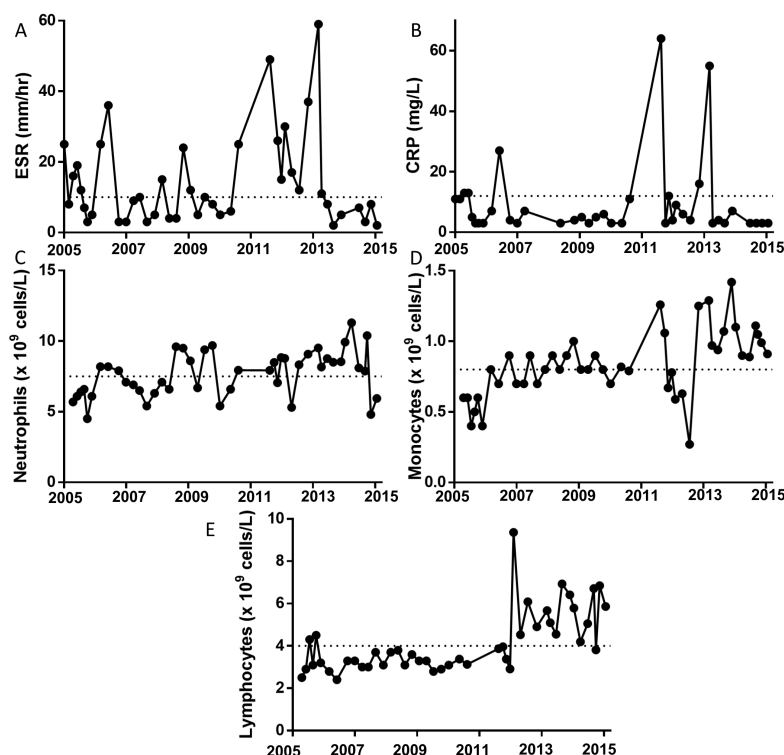
Routine clinical laboratory tests revealed an asymptomatic, afebrile inflammatory event in 2010. This was reflected in an abrupt elevation in erythrocyte sedimentation rate (ESR) and C-reactive protein (CRP; Figures 1A–B), with an elevation in neutrophils and monocytes (Figures 1C–D). Thorough clinical evaluation revealed no evidence for antecedent infection and therefore no grounds for culture testing. Fecal calprotectin was not measured because colitis was not suspected. For these reasons, elevated

CRP/ESR was viewed as an AS flare. Following this event, the patient's lymphocyte count exceeded normal levels (Figure 1E). This lymphocytosis persisted, prompting us to define its cellular nature.

Flow cytometry performed by the clinical hematology laboratory confirmed a normal  $\alpha\beta$  CD4:CD8 T cell ratio of 1.9, and B cells with polytypical light chain expression. The lymphocytosis was found to be because of an expansion of CD2/CD5/CD7 dim  $\gamma\delta$  T cells. Diagnostic multiplex PCR was performed to assess T cell receptor (TCR)  $\beta$  and TCR $\gamma$  repertoire. Results were suggestive of clonal proliferation for TCR $\gamma$ . Further consultation with hematology included computed tomography imaging, which documented no abnormalities in the lymph nodes or spleen.

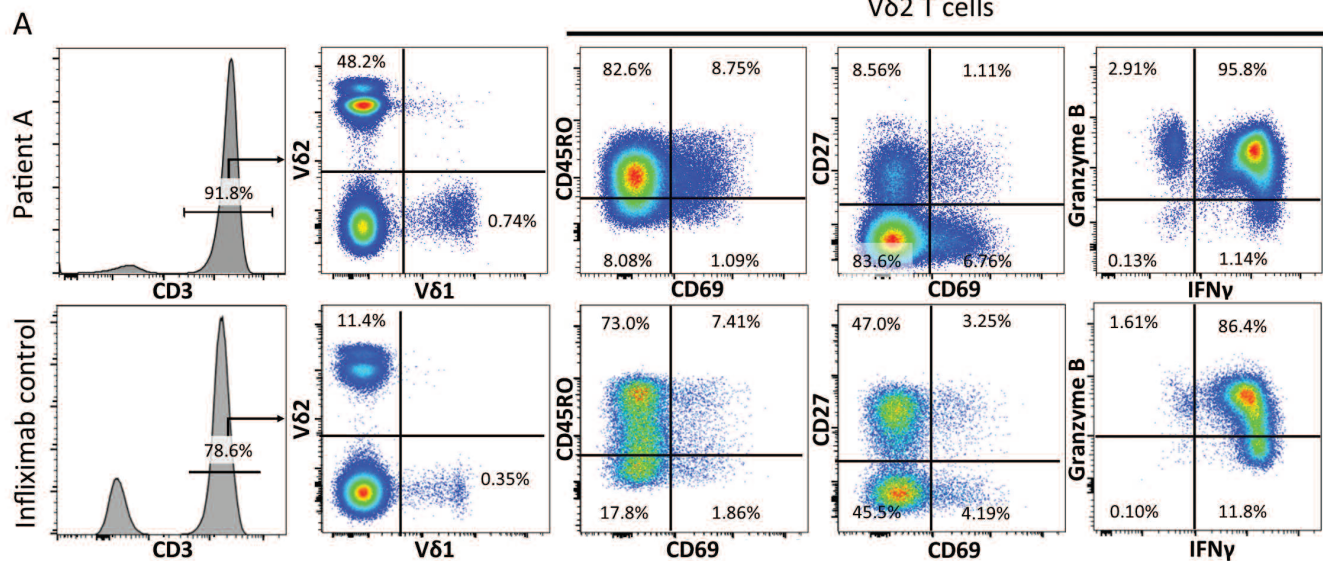
Flow cytometry on peripheral blood mononuclear cells (PBMC) was performed in a research laboratory to characterize the expanded  $\gamma\delta$  T cells. Blood was obtained from repeat visits over a period of 6 months (November 2014 to June 2015) and frozen cells were processed for analysis as previously described<sup>2</sup>. This demonstrated that the  $\gamma\delta$  T cell expansion of the patient was restricted to the T cell subset V $\delta$ 2+ (Figure 2A). Although normal for CD45RO, the V $\delta$ 2+ T cells were low for CD69 and largely CD27-negative. Stimulated V $\delta$ 2+ cells produced negligible interleukin 17A (IL-17A), yet were granzyme B+ and interferon- $\gamma$  (IFN- $\gamma$ )+. We further characterized the patient's PBMC with mass cytometry, which showed that his  $\gamma\delta$  T cells were homogeneous for the 36 markers tested (Figure 2B). Analysis using the viSNE<sup>3</sup> data visualization tool demonstrated a tight clustering of the  $\gamma\delta$  T cells in comparison with the heterogeneous character of CD4+ and CD8+ T cells (Figure 2C), supporting the observations of oligoclonality. The location of the patient's  $\gamma\delta$  T cell cluster was distinct from that seen in 5 other male patients with AS of a similar age (3 of the 5 patients were receiving TNFi), suggesting a distinct cell phenotype.

We compared the cell profile of the patient to 14 healthy controls (HC),



**Figure 1.** Lymphocytosis following an inflammatory flare in a male patient with AS (Patient A) receiving longterm infliximab. (A) ESR, (B) CRP, and (C–E) WBC count on venous blood performed by clinical diagnostic laboratory on indicated dates. Dotted lines represent limit of normal values. AS: ankylosing spondylitis; CRP: C-reactive protein; ESR: erythrocyte sedimentation rate; WBC: white blood cell.

# Vδ2 T cells



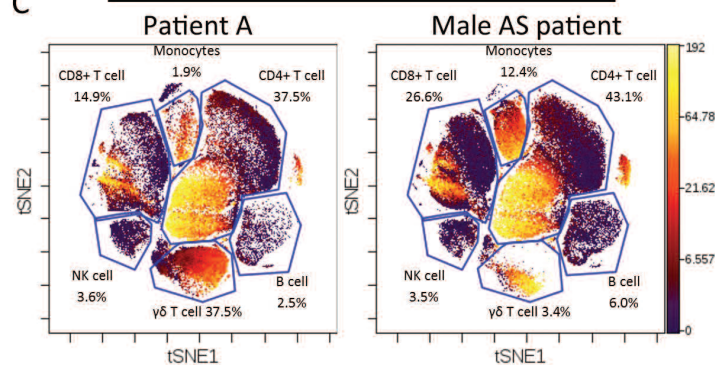
## B Patient A $\gamma\delta$ T cell phenotype

CD11a	CD56	CD49b
CD18	CD161	CD61
CD29	CCR2	CD62L
CD49d	CCR5	CD66a
CXCR4	CXCR3	CD103
CD8a	HLA-DR	CD122
CD7	CD4	CCR1
CD16	CD11b	CCR6
CD45RO	CD11c	CCR9
CD49a	CD25	CXCR6
	CD41	CX3CR1

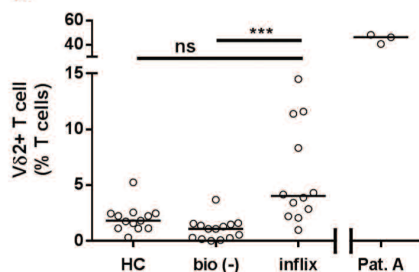
■ high   
 ■ low   
 ■ negative

## C

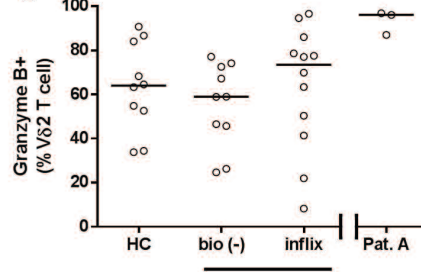
### CD45RO expression



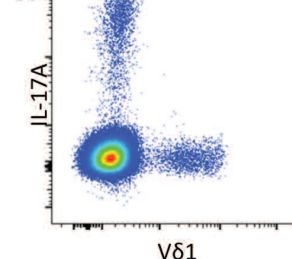
## D



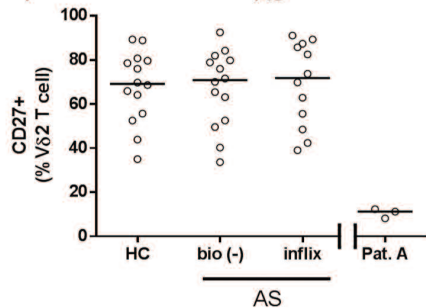
## E



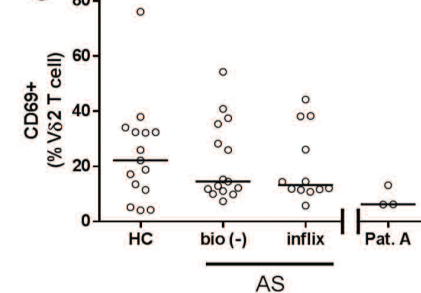
## H



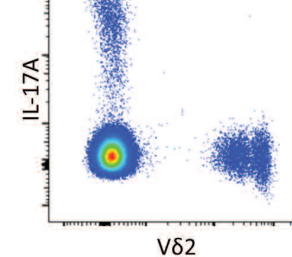
## F



## G



## I



**Figure 2.** Flow cytometric characterization of  $\gamma\delta$  T cells in our patient demonstrates specific expansion of a homogeneous V $\delta$ 2+ T cell population. Flow cytometry performed on frozen PBMC either unstimulated for surface markers or PMA/ionomycin/brefeldin A stimulated for intracellular molecules. (A) FACS used to identify live, singlet lymphocytes (not shown), which were gated on to identify CD3+ T cells in the patient and a representative IFX-treated control (HC). CD3+ cells further gated on to identify V $\delta$ 1+/V $\delta$ 2+ T cells. The indicated plots display markers specific to the V $\delta$ 2+ T cell population with gates based on FMO control (not shown). (B) Mass cytometry used to identify live, singlet, CD3+CD14-CD19-TCR $\gamma\delta$ + cells in the patient's PBMC for expression of the indicated markers. (C) viSNE analysis performed using 36 markers to cluster PBMC populations in the patient and 5 age-matched male patients with AS. CD3 $\epsilon$ , CD4, CD8 $\alpha$ , CD14, CD19, CD56, and TCR $\gamma\delta$  antigens were used to gate indicated cell populations, with CD45RO signal indicated in color scale (yellow = positive, purple = negative). Graphs show frequency of cells in gate as percent of total live PBMC. (D–G) PBMC from male HC and patients with AS either biologic-naïve (–) or receiving longterm IFX examined by FACS using the gating in panel A. Our patient's PBMC examined at 3 timepoints over 6 months for comparison. Pooled results from 3 independent experiments for (D) V $\delta$ 2+ T cell as a frequency of total T cells, (E) granzyme B+, (F) CD27+, and (G) CD69+ as a frequency of V $\delta$ 2+ T cells. Graphs displayed as scatterplot with median. Where indicated, HC, bio (–), and IFX-treated patients with AS analyzed by Kruskal-Wallis test with Dunn post-test. Data from single subject representative of all subjects. \*\*\*  $p < 0.0001$  (H) IL-17A expression by  $\gamma\delta$  cell subset in CD3+ PBMC. PBMC: peripheral blood mononuclear cells; PMA: phorbol myristate acetate; IFX: infliximab; HC: healthy control; FMO: fluorescence minus one; AS: ankylosing spondylitis; IFN $\gamma$ : interferon- $\gamma$ ; bio (–): biologic-naïve; Pat. A: our patient; ns: not significant; IL: interleukin; TCR: T cell receptor; NK: natural killer; inflix: infliximab.

14 biologic-naïve patients with AS, and 12 IFX-treated patients with AS (Table 1 and Figures 2D–G). This comparison demonstrated a distinct elevation in V $\delta$ 2+ T cells in IFX-treated patients. IFX-treated patients had a higher frequency of V $\delta$ 2+ T cells than HC when compared head-to-head (Mann-Whitney U test,  $p = 0.006$ ). V $\delta$ 2+ T cells from other IFX-treated patients with AS did not display the phenotype seen in our patient. Interestingly, our IFX control cohort contained HLA-B27+ twins, who were disparate for V $\delta$ 2 frequency (11.4% vs 4.2%) despite having been treated with IFX for a comparable time period. This observation suggests that the TNFi-associated V $\delta$ 2 cell expansion is not genetically determined.

In contrast to previous reports in patients with AS<sup>4</sup>, IL-17A was barely detected in  $\gamma\delta$  T cells, despite being identifiable in the CD3+ population (Figure 2H). Although reports on IL-17A expression by human peripheral blood  $\gamma\delta$  T cells are conflicting, a strong body of evidence suggests they require extensive *ex vivo* cytokine priming to induce IL-17 expression<sup>5</sup>. In contrast, IL-17–producing  $\gamma\delta$  T cells can be easily identified in cord blood, mucosal tissue, and murine peripheral blood<sup>6</sup>.

These results demonstrate that our patient has an expansion of V $\delta$ 2+ T cells with an abnormal phenotype. V $\delta$ 2+ T cells are known to produce TNF- $\alpha$ , IFN- $\gamma$ , and granzyme, are abundant in gut tissue, especially in patients with IBD<sup>7,8,9</sup>, and are responsive to bacterial phosphoantigens through the atypical activating molecule CD277 (butyrophilin-3). Antigenic stimulation can cause a robust expansion of V $\delta$ 2+ T cells, which is self-limiting<sup>9</sup>. The TCR-PCR was suggestive of a clonal expansion, but was not considered diagnostic of lymphoma. The lack of CD62L expression suggests that the patient's  $\gamma\delta$  T cells were likely not found in secondary lymphoid organs, which may explain the lack of lymph node/spleen enlargement.

Because TNF- $\alpha$  is inhibitory to V $\delta$ 2+ T cell proliferation<sup>10</sup>, it is possible that IFX has promoted the proliferation of these cells. Further work is required to elucidate such a mechanism. Abnormal cell growth is supported

by the striking lack of CD27 expression, an important mediator of apoptosis<sup>11,12</sup>. With the continued symptomatic control of his AS, the stability of the hematologic variables, and lack of any symptoms consistent with a progressive lymphoid abnormality, the patient elected to continue his IFX treatment because of its profound effect on his quality of life.

We present a case of abnormal expansion of V $\delta$ 2+  $\gamma\delta$  T cells associated with longterm IFX use. Although there are reports in the literature of IFX-associated  $\gamma\delta$  T cell lymphomas, especially in young men with IBD, data are lacking on the causation and diagnostic criteria. Our case report may be informative to clinicians noting the development of lymphocytosis during the course of IFX treatment of patients with AS.

ERIC GRACEY, PhD, Department of Immunology, University of Toronto, and Toronto Western Hospital, University Health Network; ZOYA QAIYUM, BSc, Department of Immunology, University of Toronto, and Toronto Western Hospital, University Health Network; JOHN KURUVILLA, MD, Princess Margaret Hospital, University Health Network; ROBERT D. INMAN, MD, Department of Immunology, University of Toronto, and Toronto Western Hospital, University Health Network, Toronto, Ontario, Canada. Funded by Canadian Institutes of Health Research. Address correspondence to Professor R.D. Inman, Toronto Western Hospital, 5th Floor 5KD412, 60 Leonard Ave., Toronto, Ontario M5T 2S8, Canada. E-mail: Robert.Inman@uhn.ca

### REFERENCES

1. Foppoli M, Ferreri AJ. Gamma-delta t-cell lymphomas. *Eur J Haematol* 2015;94:206-18.
2. Gracey E, Yao Y, Green B, Qaiyum Z, Baglaenko Y, Lin A, et al. Sexual dimorphism in the Th17 signature of ankylosing spondylitis. *Arthritis Rheumatol* 2016;68:679-89.
3. Amir ED, Davis KL, Tadmor MD, Simonds EF, Levine JH, Bendall

**Table 1.** Patient demographics for flow cytometry. Values are mean (range) unless otherwise specified.

Variables	Patient A	Infliximab	Biologic-naïve	Healthy Controls
Number	1	12	14	14
Sex	M	M	M	M
Age, yrs	36	50 (28–66)	43 (23–73)	35 (20–66)
HLA-B27, +/-	Positive	11/2	12/2	Unknown
Infliximab, yrs	12	11 (8–15)	0	N/A
BASDAI	2.7	2.6 (1.6–5.2)	4.7 (0.8–8.1)	N/A
CRP, mg/l	7	5.1 (3–26)	10.7 (3–30)	N/A
ESR, mm/h	3	9.25 (2–34)	12 (2–34)	N/A
Age at back pain, yrs	19	22 (10–40)	23 (12–52)	N/A

BASDAI: Bath Ankylosing Spondylitis Disease Activity Index; CRP: C-reactive protein; ESR: erythrocyte sedimentation rate; N/A: not applicable.

- SC, et al. ViSNE enables visualization of high dimensional single-cell data and reveals phenotypic heterogeneity of leukemia. *Nat Biotechnol* 2013;31:545-52.
4. Kenna TJ, Davidson SI, Duan R, Bradbury LA, McFarlane J, Smith M, et al. Enrichment of circulating interleukin-17-secreting interleukin-23 receptor-positive  $\gamma/\delta$  T cells in patients with active ankylosing spondylitis. *Arthritis Rheum* 2012;64:1420-9.
  5. Michel ML, Pang DJ, Haque SF, Potocnik AJ, Pennington DJ, Hayday AC. Interleukin 7 (IL-7) selectively promotes mouse and human IL-17-producing  $\gamma\delta$  cells. *Proc Natl Acad Sci U S A* 2012;109:17549-54.
  6. Chien YH, Zeng X, Prinz I. The natural and the inducible: interleukin (IL)-17-producing  $\gamma\delta$  T cells. *Trends Immunol* 2013;34:151-4.
  7. McCarthy NE, Hedin CR, Sanders TJ, Amon P, Hoti I, Ayada I, et al. Azathioprine therapy selectively ablates human V $\delta$ 2<sup>+</sup> T cells in Crohn's disease. *J Clin Invest* 2015;125:3215-25.
  8. Liuzzi AR, McLaren JE, Price DA, Eberl M. Early innate responses to pathogens: Pattern recognition by unconventional human T-cells. *Curr Opin Immunol* 2015;36:31-7.
  9. Tyler CJ, Doherty DG, Moser B, Eberl M. Human V $\gamma$ 9/V $\delta$ 2 T cells: innate adaptors of the immune system. *Cell Immunol* 2015; 296:10-21.
  10. Kelsen J, Dige A, Schwindt H, D'Amore F, Pedersen FS, Agnholt J, et al. Infliximab induces clonal expansion of  $\gamma\delta$ -T cells in Crohn's disease: a predictor of lymphoma risk? *PLoS ONE* 2011;6:e17890.
  11. Py B, Slomianny C, Auberger P, Petit PX, Benichou S. Siva-1 and an alternative splice form lacking the death domain, Siva-2, similarly induce apoptosis in T lymphocytes via a caspase-dependent mitochondrial pathway. *J Immunol* 2004;172:4008-17.
  12. Prasad KV, Ao Z, Yoon Y, Wu MX, Rizk M, Jacquot S, et al. CD27, a member of the tumor necrosis factor receptor family, induces apoptosis and binds to Siva, a proapoptotic protein. *Proc Natl Acad Sci U S A* 1997;94:6346-51.

*J Rheumatol* 2016;43:11; doi:10.3899/jrheum.160425

## Correction

### **Gamma Delta T Cell Subset V Gamma 2+ Expansion Associated with Longterm Infliximab Treatment in a Patient with Ankylosing Spondylitis [letter]**

Gracey E, Qaiyum Z, Kuruvilla J, Inman RD. Gamma delta T cell subset V gamma 2+ expansion associated with longterm infliximab treatment in a patient with ankylosing spondylitis. J Rheumatol 2016; doi:10.3899/jrheum.160425. The title of this letter to the editor is incorrect. The correct title is “Gamma Delta T Cell Subset V **Delta** 2+ Expansion Associated with Longterm Infliximab Treatment in a Patient with Ankylosing Spondylitis.” The error does not affect the results reported in the letter.

doi:10.3899/jrheum.160425.C1