

Prolonged Remission of Marginal Zone Lymphoma in a Patient with Rheumatoid Arthritis Treated with Anti-tumor Necrosis Factor Agents

To the Editor:

Anti-tumor necrosis factor (TNF) agents are widely used in the treatment of rheumatoid arthritis (RA). Some randomized controlled trials and a metaanalysis have raised the possibility of an increased occurrence of cancer associated with anti-TNF therapy¹. In the context of hematological malignancies, there are reports of myeloma, as well as monoclonal gammopathy of undetermined significance (MGUS), progressing while receiving anti-TNF treatment². The British Society for Rheumatology states that there is no conclusive evidence for an increase in risk of solid tumors or lymphoproliferative disease with anti-TNF therapies above what would be expected for the rest of the RA population³. Further, several studies have reported anti-TNF working against solid cancers^{4,5}. We report

a case of marginal zone lymphoma (MZL) that appeared to respond to sequential anti-TNF therapy with infliximab (IFX) and etanercept (ETN) in a patient with RA.

A 55-year-old woman was diagnosed with RA in 1991 and was noted to have a lymphocytosis (white cell count $20 \times 10^9/l$) when being considered for IFX therapy in September 2002. This was confirmed as an MZL following detailed morphological and flow cytometric assessment of the peripheral blood and bone marrow. She had no B symptoms, serum paraprotein, lymphadenopathy, or hepatosplenomegaly consistent with early stage disease^{6,7}, and a “watch and wait” strategy was adopted. She received IFX for her RA in September 2002 and achieved a good response.

During routine clinical followup, a consistent and sustained decline in the peripheral blood lymphocyte count was noted with a normal lymphocyte count recorded in November 2003. Given the apparent tumor response seen, further lymphoma staging was performed in July 2007 and showed no evidence of circulating disease by flow cytometry and a consid-

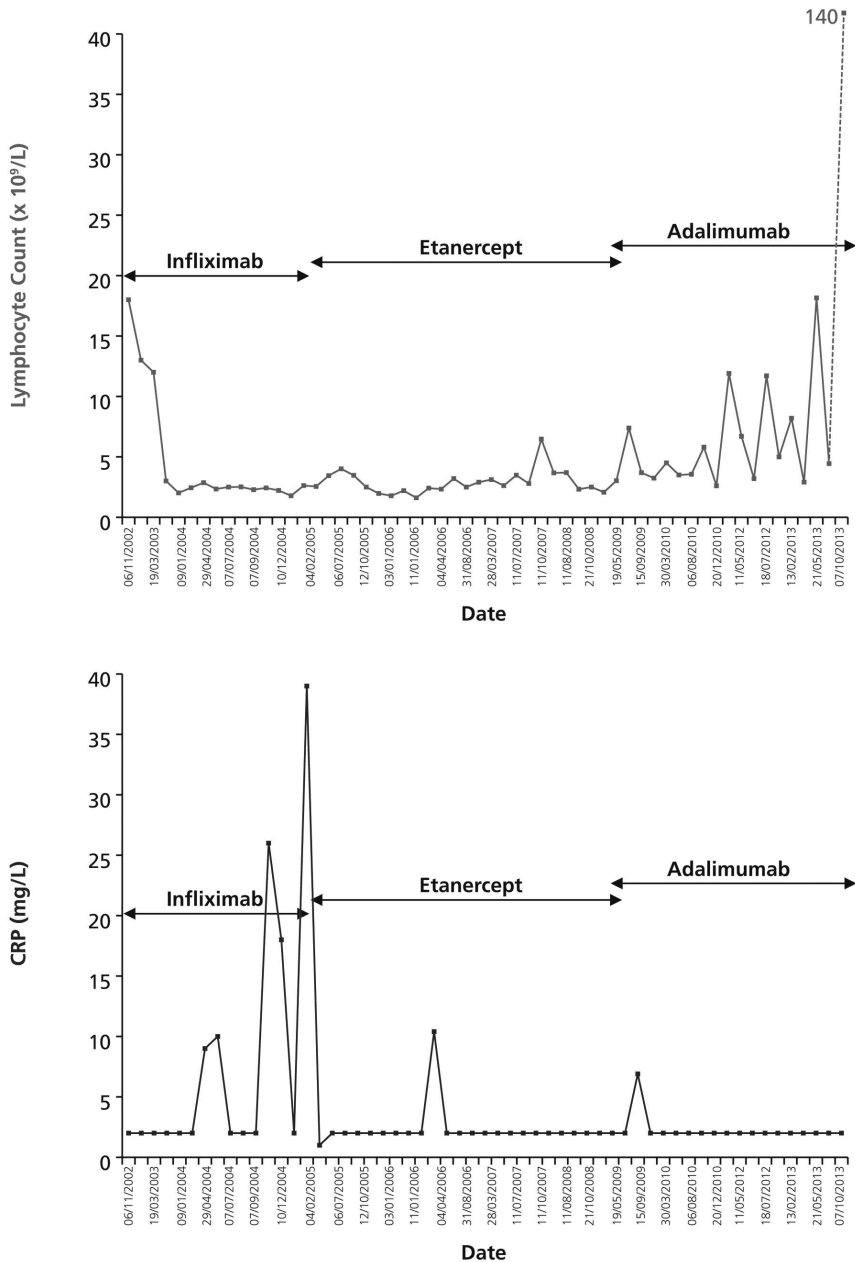


Figure 1. Lymphocyte count and CRP against time during anti-TNF treatment. CRP: C-reactive protein; TNF: tumor necrosis factor.

erable reduction in bone marrow infiltration — a level of disease consistent with a partial response to therapy (Figure 1). We speculate that this apparent clinical response was a result of the anti-TNF therapy because spontaneous remissions are rarely if ever seen in MZL and the patient had not received any other cytotoxic agents or corticosteroids. Ongoing monitoring demonstrated this response to be durable because low-level circulating lymphoma became detectable once more only in March 2009. Midway through this period, in March 2005, she was switched to ETN following a secondary nonresponse to IFX.

In June 2009, she was switched to adalimumab (ADA), because of loss of response to ETN, with a good clinical response. A fluctuating and slowly progressive increase in circulatory B cells occurred thereafter, however, and reappearance of the peripheral blood lymphocytosis was noted in September 2009 and December 2010, consistent with progressive MZL. Again this was not associated with B symptoms, lymphadenopathy, or splenomegaly and no specific antilymphoma therapy was considered necessary. Unfortunately, during 2013, a more rapid and sustained rise in the lymphocyte count was noted. This peaked at $151 \times 10^9/l$ and was associated with the development of anemia, thrombocytopenia, and splenomegaly — a clinical phenotype consistent with splenic MZL. Bone marrow examination in June 2013 revealed diffuse infiltration by MZL consistent with disease progression, but with no evidence of large cell transformation. A decision was made to withhold ADA and she was treated with cytotoxic chemotherapy (fludarabine and cyclophosphamide with the addition of rituximab in Cycle 2). Six cycles of chemotherapy have been completed with resolution of splenomegaly and bone marrow infiltration consistent with a complete response.

A link between the chronicity of inflammation in RA and disease-associated diffuse large cell lymphoma has been reported⁸. In this particular case, a link between C-reactive protein (CRP) and disease flares and change of anti-TNF therapy was noted as expected. However, there was no link between the burden of systemic inflammation as determined by CRP and the MZL.

The term “MZL” covers a wide range of indolent B cell lymphoproliferative disorders and the World Health Organization classically recognizes extranodal, nodal, and splenic forms of the disease. It is increasingly recognized that some patients present with asymptomatic peripheral blood and bone marrow disease. Some investigators have used the term “monoclonal B cell lymphocytosis with marginal zone features” in this instance, although it is clear that such cases possess all the immunophenotypic and genetic characteristics seen in patients with symptomatic MZL, most notably of the splenic type^{6,7}. In such patients, an indolent clinical course is typical, but spontaneous resolution of disease is rarely if ever noted. To our knowledge, ours is the first case report showing a possible prolonged response of lymphoma to anti-TNF treatment. The white cell count remained stable throughout treatment with IFX — a durable response comparable with chemotherapy (Figure 1). Indeed, this response was maintained following a switch to ETN treatment (Figure 1). Clonal B cells reappeared in the blood a few months before the switch from ETN to ADA. In total, a progression-free interval of about 7 years was observed. It is clear that the initial tumor response occurred while the patient was receiving IFX, but the effect of ongoing therapy with ETN is difficult to assess.

Our case report provides clinical evidence supporting a review of TNF- α effects on experimental and human cancer, suggesting that TNF- α inhibition could impede tumorigenesis and reduce neoplasia by one of several different mechanisms⁹. Given the varied reported effects of anti-TNF agents in hematology-oncology¹⁰ with some reports of clinical

progression, particularly in patients with MGUS and myeloma, close monitoring of patients with coexisting hematological malignancies is required.

SARAH L. DONALDSON, MBBS, MA, Core Medical Trainee, Rheumatology Department, Leeds Teaching Hospitals National Health Service (NHS) Trust; ROGER G. OWEN, MBBCH, MRCP, FRCPath, MD, Consultant Hematologist, Haematological Malignancy Diagnostic Service (HMDS) laboratory, St James's Institute of Oncology; DENNIS G. McGONAGLE, MB, FRCPI, PhD, Professor of Investigative Rheumatology, University of Leeds, and Honorary NHS Consultant, Leeds Teaching Hospitals NHS Trust, Leeds, UK. Address correspondence to Dr. S.L. Donaldson, 25 Oakdale Glen, Harrogate, HG1 2JY, North Yorkshire, UK. E-mail: s.donaldson@doctors.org.uk

ACKNOWLEDGMENT

We thank Dr. Andy C. Rawstron, PhD, Clinical Scientist of HMDS Laboratory, St James's Institute of Oncology, Leeds, UK.

REFERENCES

1. Bongartz T, Sutton AJ, Sweeting MJ, Buchan I, Matteson EL, Montori V. Anti-TNF antibody therapy in rheumatoid arthritis and the risk of serious infections and malignancies: systematic review and meta-analysis of rare harmful effects in randomized controlled trials. *JAMA* 2006;295:2275-85.
2. Shareef MS, Munro LR, Owen RG, Highet AS. Progression of IgA gammopathy to myeloma following infliximab treatment for pyoderma gangrenosum. *Clin Exp Dermatol* 2012;37:146-8.
3. Ding T, Ledingham J, Lugmani R, Westlake S, Hyrich K, Lunt M, et al. BSR and BHRP rheumatoid arthritis guidelines on safety of anti-TNF therapies. *Rheumatology* 2010;49:2217-9.
4. Madhusudan S, Muthuramalingam SR, Braybrooke JP, Wilner S, Kaur K, Han C, et al. Study of etanercept, a tumor necrosis factor-alpha inhibitor, in recurrent ovarian cancer. *J Clin Oncol* 2005;23:5950-9.
5. Harrison ML, Obermueller E, Maisey NR, Hoare S, Edmonds K, Li NF, et al. Tumor necrosis factor alpha as a new target for renal cell carcinoma: two sequential phase II trials of infliximab at standard and high dose. *J Clin Oncol* 2007;25:4542-9.
6. Xochelli A, Kalpadakis C, Gardiner A, Baliaskas P, Vassilakopoulos TP, Mould S, et al. Clonal B-cell lymphocytosis exhibiting immunophenotypic features consistent with a marginal-zone origin: is this a distinct entity? *Blood* 2014;123:1199-206.
7. Brusca A, Monti S, Arcaini L, Ramponi A, Rattotti S, Lucioni M, et al. Molecular lesions of signalling pathway genes in clonal B-cell lymphocytosis with marginal zone features. *Br J Haematol* 2014;10:1111.
8. Baecklund E, Iliadou A, Askling J, Ekborn A, Backlin C, Granath F, et al. Association of chronic inflammation, not its treatment, with increased lymphoma risk in rheumatoid arthritis. *Arthritis Rheum* 2006;54:692-701.
9. Williams GM. Antitumor necrosis factor-alpha therapy and potential cancer inhibition. *Eur J Cancer Prev* 2008;17:169-77.
10. Bertazza L, Mocellin S. The dual role of tumor necrosis factor (TNF) in cancer biology. *Curr Med Chem* 2010;17:3337-52.

J Rheumatol 2014;41:12; doi:10.3899/jrheum140725