

Longterm Effects of Endothelin Receptor Antagonism on Microvascular Damage Evaluated by Nailfold Capillaroscopic Analysis in Systemic Sclerosis

MAURIZIO CUTOLO, GIUSEPPE ZAMPOGNA, LAURA VREMIS, VANESSA SMITH, CARMEN PIZZORNI, and ALBERTO SULLI

ABSTRACT. Objective. Systemic sclerosis (SSc) is characterized by microvascular injury, fibrosis, and hypoxia of involved tissues. The vasoactive peptide endothelin-1 (ET-1) seems to be implicated in these events. Using nailfold videocapillaroscopy (NVC), we evaluated longterm effects of ET-1 antagonist treatment on nailfold microvascular damage in patients with SSc, over a 3-year followup period.

Methods. Thirty patients with SSc (mean age 64 ± 5 yrs, mean disease duration 8 ± 1 yrs) were recruited during their programmed standard treatment protocols. At baseline (T0), 15 patients with SSc (mean age 63 ± 15 yrs, mean disease duration 7 ± 3 yrs), already receiving cyclic intravenous infusion of iloprost (5 continuous days, average $80 \mu\text{g/day}$, every 3 mo), continued the treatment for a further 3 years (ILO group). The remaining 15 patients with SSc (mean age 68 ± 13 yrs, mean disease duration 8 ± 4 yrs), although they continued the same cyclic intravenous iloprost treatment as the previous group, also received bosentan 125 mg twice a day for 3 years (ILO+BOS group). Qualitative analysis (scleroderma patterns) and semiquantitative scoring of the microvascular damage were performed by validated routine NVC methods.

Results. During followup, a statistically significant increase of capillary number was observed in the ILO+BOS group ($p < 0.02$), with a significant and progressive increase of angiogenesis ($p < 0.01$). In contrast, the ILO group showed a statistically significant decrease of capillary number ($p < 0.05$). After 3 years the number of capillaries was significantly higher in the ILO+BOS group than in the ILO group ($p < 0.05$). The score for giant capillaries decreased significantly in both groups of patients with SSc ($p < 0.05$).

Conclusion. In this open study, longterm treatment with ET-1 receptor antagonist in combination with iloprost was found to interfere with progression of nailfold microvascular damage in patients with SSc, as assessed by NVC over a 3-year followup period. (First Release Nov 1 2012; J Rheumatol 2013;40:40–5; doi:10.3899/jrheum.120416)

Key Indexing Terms:

NAILFOLD VIDEOCAPILLAROSCOPY SYSTEMIC SCLEROSIS MICROANGIOPATHY
ENDOTHELIN-1 BOSENTAN

Systemic sclerosis (SSc) is characterized mainly by microvascular damage, fibrosis, and hypoxia of involved tissues causing progressive organ failure¹. SSc microangiopathy is a dynamic and sequential process, progressing

from early enlargement of capillaries (giant capillaries) to capillary loss, tissue ischemia, and finally tissue fibrosis and reactive neoangiogenesis (capillary ramifications)².

Currently, the structural capillary changes are investigated by nailfold videocapillaroscopy (NVC) and 3 different and progressive patterns of nailfold microvascular damage have been described in SSc, i.e., the early, active, and late scleroderma patterns³.

Briefly, NVC allows the investigator to carry out early diagnosis of SSc, and to characterize, quantify, and monitor the progression of nailfold microvascular damage⁴. Therefore, SSc microangiopathy was found to be predictive for progression of primary Raynaud's phenomenon (RP) to SSc and related clinical complications such as digital ulcers^{5,6,7}.

There are several therapeutic approaches to improve RP or to reduce the appearance of new digital ulcers⁸. Iloprost is a prostacyclin analog that blocks platelet aggregation and adhesion, dilates arterioles and venules, activates fibrinolysis, and reduces the release of oxygen-reactive species,

From the Research Laboratory and Academic Unit of Clinical Rheumatology, Department of Internal Medicine, University of Genoa, Genoa, Italy; Division of Rheumatology, State University of Medicine and Pharmacy Nicolae Testemitanu, Chisinau, Moldova; and Department of Rheumatology, Ghent University Hospital, Ghent, Belgium.

M. Cutolo, MD, Full Professor, Director; G. Zampogna, MD, Rheumatology Trainee, Research Laboratory and Academic Unit of Clinical Rheumatology, University of Genoa; L. Vremis, MD, PhD, Rheumatologist, Division of Rheumatology, State University of Medicine and Pharmacy; V. Smith MD, PhD, Rheumatologist, Adjunct Chief in Clinics, Department of Rheumatology, Ghent University Hospital; C. Pizzorni, MD, PhD, Academic Clinical Researcher; A. Sulli, MD, Assistant Professor, Research Laboratory and Academic Unit of Clinical Rheumatology, University of Genoa.

Address correspondence to Prof. M. Cutolo, Research Laboratory and Academic Unit of Clinical Rheumatology, Department of Internal Medicine, University of Genoa, Viale Benedetto XV – 6, 16132 Genoa, Italy. E-mail: mcutolo@unige.it

Accepted for publication September 12, 2012.

reducing the effects of RP⁹. Endothelin-1 (ET-1), a 21-amino acid peptide, is a potent vasoconstrictor, mainly produced by endothelial cells, that is found in high concentrations in the skin as well as in lung, kidney, and plasma of patients with SSc^{10,11}. Bosentan, a dual ET-1 receptor antagonist, has been licensed to treat pulmonary hypertension and to prevent the onset of new digital ulcers in patients with SSc and history of digital ulcers⁸.

This investigation was planned to evaluate by NVC the longterm effects (3 years) of bosentan treatment on progression of nailfold microvascular damage in patients with SSc who were already receiving cyclic treatment with intravenous iloprost.

MATERIALS AND METHODS

Patients. Thirty patients (mean age 64 ± 5 years) with SSc (mean disease duration 8 ± 1 yrs) according to the American College of Rheumatology criteria for SSc¹² or the LeRoy criteria for the classification of early SSc¹³, and who were attending the Academic Unit of Clinical Rheumatology at the University of Genoa during 2007-2008, were followed during their standard treatment protocols. All patients provided informed consent.

A complete medical history and comprehensive laboratory examination results were available for all patients, including results of a full medical assessment. All patients were regularly taking aspirin (100–150 mg/day) and buflomedil (300–600 mg/day), a vasoactive drug mainly inhibiting α -adrenoceptors and platelet aggregation. In addition, all patients were treated with intravenous iloprost in cycles of 5 days, by continuous 24-h intravenous infusion (median 80 μ g/day) every 3 months, with temporary withdrawal of buflomedil.

At study baseline (T0), 15 patients (mean age 63 ± 15 yrs, mean disease duration 7 ± 3 yrs) already receiving cyclic intravenous iloprost for an average of 5 ± 1 years continued such treatment for 3 additional years (ILO group). The remaining 15 patients (mean age 68 ± 13 yrs, mean disease duration 8 ± 4 yrs), although they continued the same cyclic intravenous iloprost treatment as the previous group (for an average time of 7 ± 3 yrs), also received bosentan, according to the general recommendations, since they experienced the appearance of new digital ulcers (ILO+BOS group). Bosentan was administered at a dosage of 62.5 mg twice a day orally for 1 month; after liver function assessment, the dosage was increased to 125 mg twice a day. All patients with SSc were followed for at least 3 years and were assessed yearly by NVC (i.e., T0, T1, T2, T3). Liver function and other serum measurements were monitored every 4–6 months. Patients' demographic data are reported in Table 1.

Nailfold videocapillaroscopy. NVC was performed yearly in each patient using an optical probe videocapillaroscope equipped with a 200× contact lens and connected to image analysis software (Videocap, DS MediGroup). The same operator (CP), blinded to patients' clinical data, performed all NVC examinations and scored all images. Each patient was inside the building for a minimum of 15 min before the nailfold was examined and the room temperature was 22°–23°C. Nailfolds of second, third, fourth, and fifth fingers of both hands (sparing the thumbs) were examined in each patient, after a drop of immersion oil was placed on the nailfold bed to improve image resolution^{3,14}. The first line of capillaries at the nailfold was evaluated, and the following capillaroscopic variables were considered, based on our previous studies: number of capillaries, presence of giant capillaries, microhemorrhages, capillary ramifications (reactive angiogenesis), and disorganization^{2,3,4}.

A semiquantitative and validated rating scale to score each capillary abnormality was adopted, in accord with previous studies (0–3 score for each variable: 0 = no changes, 1 = less than 33% capillary alterations/reduction, 2 = 33%–66% of capillary alterations/reduction, 3 = greater than 66% capillary alterations/reduction, per linear mm)^{15,16}.

Table 1. Demographic characteristics of patients with systemic sclerosis. Incidence of new digital ulcers is also reported at baseline (T0) and after 3 years (T3).

Characteristic	ILO Group (15 patients)	ILO+BOS Group (15 patients)
Mean age, yrs	63 ± 15	68 ± 13
Mean SSc duration, yrs	7 ± 3	8 ± 4
Sex (male/female)	1/14	2/13
LSSc, n	3	0
LcSSc, n	9	7
DcSSc, n	3	8
ANA speckled pattern, %	13	27
ANA homogeneous, %	13	40
ANA nucleolar, %	7	7
ANA centromeric, %	67	27
Scl70-positive, %	20	27
New digital ulcers, n		
T0	0/15	15/15*
T3	2/15	0/15

* Patients were enrolled in the ILO+BOS group upon the appearance of new digital ulcers. LSSc: limited systemic sclerosis; LcSSc: limited cutaneous systemic sclerosis; DcSSc: diffuse cutaneous systemic sclerosis; ILO: iloprost; BOS: bosentan; ANA: antinuclear antibodies.

In relation to nailfold capillary abnormalities, patients were distributed within the appropriate NVC pattern of microangiopathy (i.e., early, active, and late scleroderma patterns), as described^{2,3}. The “microangiopathy evolution score” (MES; the sum of 3 scores: loss of capillaries, disorganization of the microvascular array, and capillary ramifications) was also adopted to globally assess the progression of vascular damage, as reported^{15,17}.

Statistical analysis. Statistical analysis was carried out with nonparametric tests. Mann-Whitney U test was performed to compare unpaired groups of variables, Friedman test to compare repeated observations, and the Wilcoxon signed-rank test to compare paired groups of variables. A p value < 0.05 was considered statistically significant.

RESULTS

Baseline NVC findings and pattern transition. No statistically significant difference was observed between the 2 groups of patients concerning the scores for different NVC measures at the baseline visit (Table 2).

At baseline (T0), in the ILO group the late NVC pattern was present in 5 of 15 patients (33%), the active pattern in 7 (47%), and the early pattern in 3 (20%), while in the ILO+BOS group, 11 of 15 patients (73%) showed the late NVC pattern and 4 (26%) the active pattern of microangiopathy.

Progression of nailfold microvascular damage. At the end of the followup (T3), in the ILO group 1 patient with the early and 3 patients with the active pattern at baseline shifted to the late microangiopathy pattern. Conversely, in the ILO+BOS group, 1 patient shifted from the late to the active pattern of microangiopathy.

Statistically significant modifications of the scores for the capillaroscopic measures were observed in the 2 groups of patients with SSc, as described below.

Table 2. Mean score (range 0–3 \pm SD) for the single nailfold videocapillaroscopy morphological markers during followup in the 2 groups of patients with SSc.

	T0	Time, yrs			P
		T1	T2	T3	(T0 vs T3)
ILO group					
Loss of capillaries	1.71 \pm 0.70	1.86 \pm 0.52	1.93 \pm 0.46	2.00 \pm 0.38	0.05
Giant capillaries	1.14 \pm 0.83	1.29 \pm 0.59	1.14 \pm 0.64	0.93 \pm 0.59	0.05
Microhemorrhages	0.86 \pm 0.52	0.93 \pm 0.46	0.93 \pm 0.46	0.86 \pm 0.52	NS
Ramifications	1.50 \pm 0.91	1.64 \pm 0.72	1.79 \pm 0.56	1.71 \pm 0.88	0.05
ILO+BOS group					
Loss of capillaries	1.79 \pm 0.89	1.79 \pm 0.89	1.71 \pm 0.88	1.43 \pm 0.65	0.02
Giant capillaries	0.93 \pm 0.73	1.00 \pm 0.78	1.00 \pm 0.78	0.71 \pm 0.83	NS
Microhemorrhages	0.57 \pm 0.65	0.50 \pm 0.65	0.43 \pm 0.65	0.36 \pm 0.63	NS
Ramifications	1.21 \pm 0.80	1.43 \pm 0.51	1.79 \pm 0.70	2.07 \pm 0.83	0.003

ILO: iloprost; BOS: bosentan; T0: baseline; T1: 1 year; T2: 2 years; T3: 3 years; NS: nonsignificant.

Iloprost treatment. During the followup, patients with SSc in the ILO group showed a statistically significant progressive increase of the mean score for loss of capillaries, suggesting a worsening of the microvessel injury and lack of protection from progression of microvascular damage under treatment with iloprost (Figure 1). Mean scores for capillary ramifications were significantly higher at T3 compared to T0 (Table 2). The detailed variations of the scores for single NVC morphological markers (capillary loss, giant capillaries, microhemorrhages, and capillary ramifications) during the followup are reported in Table 2.

In addition, the MES, the composite score globally evaluating capillary markers of microvascular damage, was found to be significantly increased (worsened) in patients treated with iloprost at 3 years (mean 5.1 ± 1.8 , 5.3 ± 1.5 , 5.5 ± 1.4 , and 5.7 ± 1.6 at T0, T1, T2, and T3, respectively; $p = 0.03$). Giant capillaries decreased significantly from T0 to T3 (Figure 1).

Two out of 15 patients (13%) experienced new digital ulcers during the followup; both patients were showing the late SSc pattern of microangiopathy.

No serious adverse events were observed during iloprost infusions; and otherwise minor events such as blood pressure increase, headache, and flushing were managed by temporary reduction of the drug infusion rate.

Combined treatment with iloprost and bosentan. A statistically significant progressive increase of capillary number was observed in the ILO+BOS group of patients, together with a significant and progressive increase of capillary ramifications (Figure 1). Interestingly, the increase of capillary ramifications was greater than that observed in the ILO group. These results suggest a reduced progression of the microvascular damage, along with a greater amount of reactive angiogenesis.

The detailed variations of scores for the single NVC morphological markers (capillary loss, giant capillaries, microhemorrhages, and capillary ramifications) during the followup are reported in Table 2.

Of note, after 3 years (T3), the number of capillaries was significantly higher in the ILO+BOS group than in the ILO group and the difference was statistically significant (Figure 1). Giant capillaries decreased significantly from T1 to T3 (Figure 1).

No relevant side effects leading to withdrawal of treatment and no new digital ulcers were observed in the ILO+BOS patient group at the end of the followup. Minor side effects such as nausea and mild increases of transaminase were managed by temporary reduction of dosages.

DISCUSSION

Our study reports the longterm effects of ET-1 receptor antagonism on nailfold microvascular damage changes, as assessed by NVC analysis in patients with SSc who had digital ulcers. In particular, NVC revealed that treatment with the combination of bosentan with iloprost significantly increased the number of capillaries after 2 years of treatment; in contrast, a progressive and significant loss of capillaries, as expected in the natural followup of the disease, was observed under iloprost treatment alone. These data are intriguing, but should be interpreted with caution because this was a nonrandomized, unblinded, uncontrolled trial, with 2 groups of patients with dissimilar baseline characteristics.

Dynamic modifications of the nailfold microvascular bed during the course of SSc have been demonstrated by a 20-year longitudinal study, and progressive transition through NVC patterns has been linked to the progression of clinical complications in SSc^{4,5,18}. However, the therapeutic influence on transition of the NVC pattern has rarely been evaluated in SSc, excluding the effects of immunosuppressive treatments (i.e., cyclosporine, cyclophosphamide) that showed a regression from active/late compared to the early/active NVC patterns, respectively^{19,20}.

Besides being a potent vasoconstrictor, ET-1 is a direct downstream target of transforming growth factor- β 1 (TGF- β 1) and it behaves as a profibrotic cytokine, stimu-

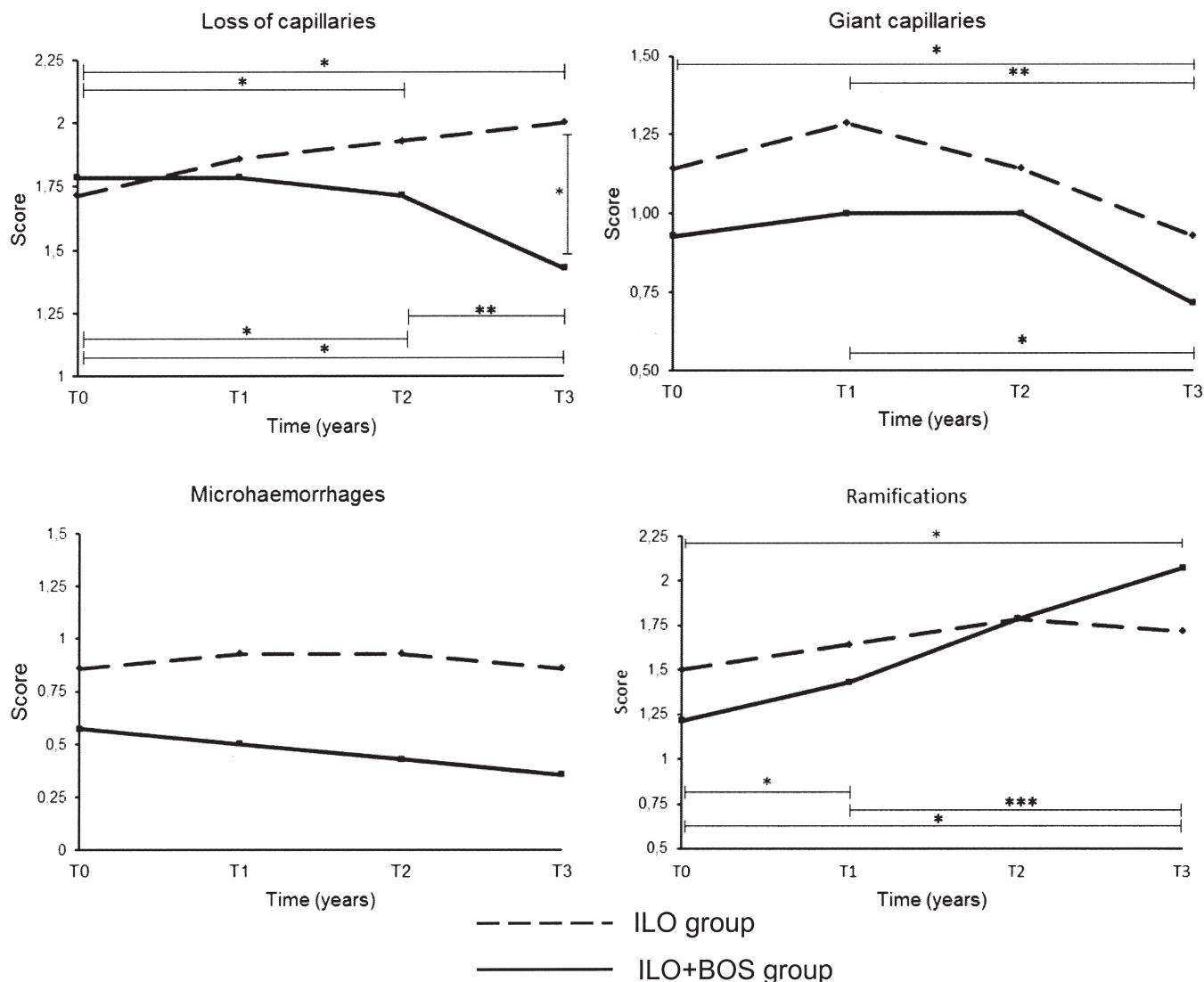


Figure 1. Mean score variations of morphological markers from nailfold videocapillaroscopy during 3-year followup in 2 study groups of patients with systemic sclerosis. Upper significance lines refer to ILO group; lower significance lines refer to ILO+BOS group. * $p < 0.05$; ** $p < 0.02$; *** $p < 0.01$. ILO: iloprost; BOS: bosentan.

lating fibroblast chemotaxis and proliferation and inducing procollagen and fibronectin synthesis^{21,22}. Further, increased circulating ET-1 levels have been observed in patients with diffuse SSc with widespread fibrosis and those with limited SSc and hypertensive disease, suggesting that soluble ET-1 levels may be a marker of vascular damage^{23,24}. Thus, ET-1 is suggested to contribute significantly to fibrogenesis, linking between vasculopathy and fibrosis, and the blockade of ET-1 signaling might lead to the reduction of fibrogenesis.

Because ET-1 mediates its biological effects on fibroblasts through endothelin A and B receptors (ET_{A/B}R), there is growing evidence that antagonizing the interaction with these receptors might represent a possible strategy to downregulate the effects of ET-1 at least on the skin fibrosis of SSc disease^{25,26}.

The significant increase of normal capillaries observed during longterm ET-1 receptor antagonism in SSc patients with digital ulcers, as assessed by NVC, suggests important interference exerted on the TGF- β 1/ET-1 axis, particularly through the mechanisms involved in the endothelial-to-mesenchymal cell transition (EndMT)²⁷. The importance of the EndMT as one of the leading processes in fibrosis, including a role for ET-1, has recently been supported, because diabetes-induced cardiac fibrosis seems to be associated with the emergence of fibroblasts from endothelial cells, and this transition process is stimulated by ET-1²⁸.

Thus, the results of our study might suggest that ET-1 receptor antagonism exerted over the long term in patients with SSc may interfere with the mechanisms inducing progressive microvascular damage such as capillary loss

and consequent tissue hypoxia and fibrosis. In addition, the larger extent of angiogenesis observed in SSc patients treated with bosentan might be explained as an attempt to revascularize the tissues under hypoxia. It is suggested that elevated angiogenic serum markers, as reported in patients with SSc, may appear as a compensatory response to maintain vascular function with the formation of new vessels, which might lead to enhanced capillary formation²⁹.

However, angiogenesis resulting from defective vascularization and tissue hypoxia is insufficient in SSc, despite elevated levels of proangiogenic factors (i.e., vascular endothelial growth factor and circulating endothelial progenitor cells)^{30,31}. Therefore, the reasons that a significant increase of angiogenesis together with increased capillary formation was observed by NVC in SSc patients treated with bosentan are not clear at present, but deserve further investigation.

Nevertheless, the reversal of progressive loss of capillaries by ET-1 receptor blocker treatment needs to be interpreted with caution. First, our study was observational, and not a randomized controlled trial; second, because the ET-1 receptor blocker therapy was added upon clinical indication (the appearance of digital ulcers), baseline characteristics of our 2 study groups were different, which may bias our results.

Interestingly, no new digital ulcers were detected in the patients with SSc during longterm treatment with ET-1 receptor antagonist combined with iloprost, in contrast to findings in other studies, in which the treatment with bosentan alone was associated with a reduction of only 30% in the number of new digital ulcers in the short term (24 weeks)³². Therefore, the intensive longterm combination treatment with intravenous iloprost (5-day cycles, with 24-h continuous intravenous infusion, every 3 months) seems to further enhance the effects of the ET-1 receptor antagonism compared to the monotherapy. It is known that ET-1 receptor antagonism combined with vasoactive drugs (i.e., iloprost or sildenafil) induces significant improvement in pulmonary arterial hypertension and reduces the appearance of new digital ulcers in patients with SSc^{33,34}. From the capillaroscopic viewpoint, in SSc patients with the more severe (late) NVC pattern at baseline (i.e., most patients in the ILO+BOS group), based only on the natural history of the disease, one should wait for further worsening of the microangiopathy during followup; but on the contrary, an increase of capillary number was observed precisely in the ILO+BOS group compared to the ILO group, showing the latter had less severe nailfold microangiopathy at baseline. This observation underlines the possibility of a real treatment-related effect of ET-1 receptor antagonism on nailfold microvascular damage. Nevertheless, for some clinical complications in SSc (pulmonary arterial hypertension and digital ulcers), progressive capillary loss, as

detected by NVC, seems to have predictive value, and specific predictive indexes have been proposed^{16,7,35,36}.

Longterm, randomized, blinded, controlled trials should be performed to confirm our results.

Longterm treatment of patients with SSc who have digital ulcers with the ET-1 receptor antagonist in combination with iloprost seems to interfere with the progression of nailfold microvascular damage, as assessed by NVC.

REFERENCES

- Guillemin L. A contemporary update on scleroderma. *Clin Rev Allergy Immunol* 2011;40:75-7.
- Cutolo M, Sulli A, Smith V. Assessing microvascular changes in systemic sclerosis diagnosis and management. *Nat Rev Rheumatol* 2010;6:578-87.
- Cutolo M, Sulli A, Pizzorni C, Accardo S. Nailfold videocapillaroscopy assessment of microvascular damage in systemic sclerosis. *J Rheumatol* 2000;27:155-60.
- Sulli A, Pizzorni C, Smith V, Zampogna G, Ravera F, Cutolo M. Timing of transition between capillaroscopic patterns in systemic sclerosis. *Arthritis Rheum* 2012;64:821-5.
- Koenig M, Joyal F, Fritzler MJ, Roussin A, Abrahamowicz M, Boire G, et al. Autoantibodies and microvascular damage are independent predictive factors for the progression of Raynaud's phenomenon to systemic sclerosis: A twenty-year prospective study of 586 patients, with validation of proposed criteria for early systemic sclerosis. *Arthritis Rheum* 2008;58:3902-12.
- Sebastiani M, Manfredi A, Vukatana G, Moscatelli S, Riato L, Bocci M et al. Predictive role of capillaroscopic skin ulcer risk index in systemic sclerosis: A multicentre validation study. *Ann Rheum Dis* 2012;71:67-70.
- Smith V, De Keyser F, Pizzorni C, Van Praet JT, Decuman S, Sulli A, et al. Nailfold capillaroscopy for day-to-day clinical use: Construction of a simple scoring modality as a clinical prognostic index for digital trophic lesions. *Ann Rheum Dis* 2011;70:180-3.
- Herrick AL. Contemporary management of Raynaud's phenomenon and digital ischaemic complications. *Curr Opin Rheumatol* 2011;23:555-61.
- Mubarak KK. A review of prostaglandin analogs in the management of patients with pulmonary arterial hypertension. *Respir Med* 2010;104:9-21.
- Vancheeswaran R, Azam A, Black C, Dashwood MR. Localization of endothelin-1 and its binding sites in scleroderma skin. *J Rheumatol* 1994;21:1268-76.
- Silver RM. Endothelin and scleroderma lung disease. *Rheumatology* 2008;47 Suppl 5:v25-6.
- Subcommittee for Scleroderma Criteria of the American Rheumatism Association Diagnostic Therapeutic Criteria Committee. Preliminary criteria for the classification of systemic sclerosis (scleroderma). *Arthritis Rheum* 1980;23:581-90.
- LeRoy EC, Medsger TA Jr. Criteria for the classification of early systemic sclerosis. *J Rheumatol* 2001;28:1573-6.
- Chikura B, Moore TL, Manning JB, Vail A, Herrick AL. Sparing of the thumb in Raynaud's phenomenon. *Rheumatology* 2008; 47:219-21.
- Sulli A, Secchi ME, Pizzorni C, Cutolo M. Scoring the nailfold microvascular changes during the capillaroscopic analysis in systemic sclerosis patients. *Ann Rheum Dis* 2008;67:885-7.
- Smith V, Pizzorni C, De Keyser F, Decuman S, Van Praet JT, Deschepper E, et al. Reliability of the qualitative and semiquantitative nailfold videocapillaroscopy assessment in a systemic sclerosis cohort: A two-centre study. *Ann Rheum Dis* 2010;69:1092-6.

17. Cutolo M, Ferrone C, Pizzorni C, Soldano S, Seriola B, Sulli A. Peripheral blood perfusion correlates with microvascular abnormalities in systemic sclerosis: A laser-Doppler and nailfold videocapillaroscopy study. *J Rheumatol* 2010;37:1174-80.
18. Smith V, Decuman S, Sulli A, Bonroy C, Piette Y, Deschepper E, et al. Do worsening scleroderma capillaroscopic patterns predict future severe organ involvement? A pilot study. *Ann Rheum Dis* 2012;71:1636-9.
19. Filaci G, Cutolo M, Basso M, Murdaca G, Derchi L, Gianrossi R, et al. Long-term treatment of patients affected by systemic sclerosis with cyclosporin A. *Rheumatology* 2001;40:1431-2.
20. Aschwanden M, Daikeler T, Jaeger KA, Thalhammer C, Gratwohl A, Matucci-Cerinic M, et al. Rapid improvement of nailfold capillaroscopy after intense immunosuppression for systemic sclerosis and mixed connective tissue disease. *Ann Rheum Dis* 2008;67:1057-9.
21. Shi-Wen X, Kennedy L, Renzoni EA, Bou-Gharios G, Black CM, Denton CP, et al. Endothelin is a downstream mediator of profibrotic responses to transforming growth factor β in human lung fibroblasts. *Arthritis Rheum* 2007;56:4189-94.
22. Shi-Wen X, Renzoni EA, Kennedy L, Howat S, Chen Y, Pearson JD, et al. Endogenous endothelin-1 signaling contributes to type I collagen and CCN2 overexpression in fibrotic fibroblasts. *Matrix Biol* 2007;26:625-32.
23. Sulli A, Soldano S, Pizzorni C, Montagna P, Secchi ME, Villaggio B, et al. Raynaud's phenomenon and plasma endothelin: Correlations with capillaroscopic patterns in systemic sclerosis. *J Rheumatol* 2009;36:1235-9.
24. Vancheeswaran R, Magoulas T, Efrat G, Wheeler-Jones C, Olsen I, Black CM. Circulating endothelin-1 levels in systemic sclerosis subsets — A marker of fibrosis or vascular dysfunction? *J Rheumatol* 1994;21:1838-44.
25. Leask A. The role of endothelin-1 signaling in the fibrosis observed in systemic sclerosis. *Pharmacol Res* 2011;63:502-3.
26. Leask A. Towards an anti-fibrotic therapy for scleroderma: Targeting myofibroblast differentiation and recruitment. *Fibrogenesis Tissue Repair* 2010;3:8-12.
27. Díez M, Musri MM, Ferrer E, Barberà JA, Peinado VI. Endothelial progenitor cells undergo an endothelial-to-mesenchymal transition-like process mediated by TGF- β -RI. *Cardiovasc Res* 2010;88:502-11.
28. Widyantoro B, Emoto N, Nakayama K, Anggrahini DW, Adiarto S, Iwasa N, et al. Endothelial cell-derived endothelin-1 promotes cardiac fibrosis in diabetic hearts through stimulation of endothelial-to-mesenchymal transition. *Circulation* 2010; 121:2407-18.
29. Avouac J, Meune C, Ruiz B, Couraud PO, Uzan G, Boileau C, et al. Angiogenic biomarkers predict the occurrence of digital ulcers in systemic sclerosis. *Ann Rheum Dis* 2012;71:394-9.
30. Distler JH, Gay S, Distler O. Angiogenesis and vasculogenesis in systemic sclerosis. *Rheumatology* 2006;45 Suppl 3:iii26-7.
31. Distler O, Del Rosso A, Giacomelli R, Cipriani P, Conforti ML, Guiducci S, et al. Angiogenic and angiostatic factors in systemic sclerosis: Increased levels of vascular endothelial growth factor are a feature of the earliest disease stages and are associated with the absence of fingertip ulcers. *Arthritis Res* 2002;4:R11.
32. Matucci-Cerinic M, Denton CP, Furst DE, Mayes MD, Hsu VM, Carpentier P, et al. Bosentan treatment of digital ulcers related to systemic sclerosis: Results from the RAPIDS-2 randomised, double-blind, placebo-controlled trial. *Ann Rheum Dis* 2011; 70:32-8.
33. Mathai SC, Girgis RE, Fisher MR, Champion HC, Houston-Harris T, Zaiman A, et al. Addition of sildenafil to bosentan monotherapy in pulmonary arterial hypertension. *Eur Respir J* 2007;29:469-75.
34. Moinezhadeh P, Hunzelmann N, Krieg T. Combination therapy with an endothelin-1 receptor antagonist (bosentan) and a phosphodiesterase V inhibitor (sildenafil) for the management of severe digital ulcerations in systemic sclerosis. *J Am Acad Dermatol* 2011;65:102-4.
35. Hofstee HM, Vonk Noordegraaf A, Voskuyl AE, Dijkmans BA, Postmus PE, Smulders YM, et al. Nailfold capillary density is associated with the presence and severity of pulmonary arterial hypertension in systemic sclerosis. *Ann Rheum Dis* 2009;68:191-5.
36. Lambova S, Müller-Ladner U. Capillaroscopic findings in systemic sclerosis — Are they associated with disease duration and presence of digital ulcers? *Discov Med* 2011;12:413-8.