

Magnetic Resonance Angiography in Psoriatic Arthritis of the Hand

RYO ROKUTANDA, MD; MITSUMASA KISHIMOTO, MD, PhD; MASATO OKADA, MD, Division of Allergy and Rheumatology, St. Luke's International Hospital, 9-1 Akashi-cho, Chuo-ku, Tokyo 104-8560, Japan. Address correspondence to Dr. Rokutanda; E-mail: rrokutandah1@gmail.com
J Rheumatol 2012;39:1700; doi:10.3899/jrheum.120483

A 45-year-old woman presented with a complaint of finger arthralgia. Examination revealed bilateral swelling of distal interphalangeal (DIP) joints, nail pitting, and onycholysis (Figure 1A); a diagnosis of psoriatic arthritis (PsA) was made. Laboratory investigations showed elevated erythrocyte sedimentation rate of 23 mm/h and C-reactive protein 1.47 mg/dl. Gadolinium-enhanced magnetic resonance angiography (MRA) scans of the hands disclosed marked enhancement of all DIP joints (Figure 1B) without bony erosion or bone marrow edema. The skin lesions and arthritis improved upon treatment with tumor necrosis factor (TNF) inhibitor. However, she subsequently developed palmoplantar pustulosis, which persisted despite switching TNF inhibitors. Eventually, all symptoms resolved after treatment with cyclosporine.

Recently, synovial angiogenesis has been proposed as one of the earliest markers of inflammatory arthritis¹. Although there have been studies reporting the reliability of MRA in rheumatoid arthritis², this is the first report, to our knowledge, of MRA imaging in PsA.

REFERENCES

1. Gaffney K, Cookson J, Blades S, Coumbe A, Blake D. Quantitative assessment of the rheumatoid synovial microvascular bed by gadolinium-DTPA enhanced magnetic resonance imaging. *Ann Rheum Dis* 1998;57:152-7.
2. Vasanth LC, Foo LF, Potter HG, Adler RS, Finzel KC, Pavlov H, et al. Using magnetic resonance angiography to measure abnormal synovial blood vessels in early inflammatory arthritis: A new imaging biomarker? *J Rheumatol* 2010;37:1129-35.

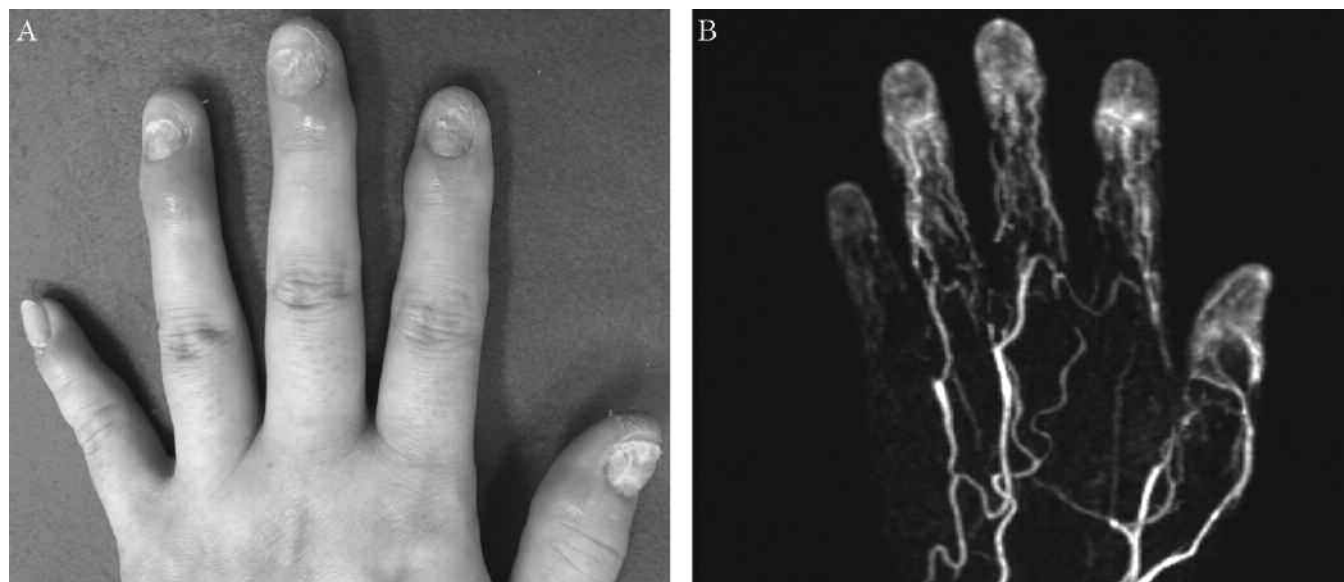


Figure 1. A. Bilateral swelling of distal interphalangeal (DIP) joints, nail pitting, and onycholysis in a 45-year-old woman with finger arthralgia. B. Gadolinium-enhanced magnetic resonance angiography shows marked enhancement of all DIP joints.