

Digital Amputation in Systemic Sclerosis: Prevalence and Clinical Associations. A Retrospective Longitudinal Study

PAOLA CARAMASCHI, DOMENICO BIASI, CRISTIAN CAIMMI, GIOVANNI BARAUSSE, DANIA SABBAGH, ILARIA TINAZZI, VALENTINA LA VERDE, SARA TONETTA, and SILVANO ADAMI

ABSTRACT. Objective. To evaluate the prevalence of digital necrosis requiring surgical amputation in a single-center group of patients with systemic sclerosis (SSc) and to compare the characteristics of patients with and those without this severe complication.

Methods. We reviewed the medical records of 188 patients with SSc [162 women, 26 men, mean age 59.2 yrs, mean disease duration 8.0 yrs, mean time from onset of Raynaud's phenomenon (RP) 11.7 yrs, median followup duration 92 mo] enrolled in the Rheumatology Unit since 2004. Demographic and clinical features were collected, as well as the presence of the typical risk factors for atherosclerosis.

Results. Nine patients (4.8%) underwent partial or total surgical digital amputation because of necrotic process; all these patients except 1 had a long history of multiple and persisting digital ulcers. All 9 patients had concomitant large-vessel involvement. Comparison of cases with and without digital amputation showed that this complication was associated with older age, long history of RP, long disease duration, presence of anticentromere antibody, and coexistence of peripheral artery disease and hypercholesterolemia.

Discussion. We noted that 4.8% of patients with SSc underwent digital amputation. Our retrospective analysis suggests that peripheral artery disease is strongly associated with digital amputation. The preventive strategy for digital ulcers and amputation associated with SSc should include an extensive diagnostic and preventive investigation for peripheral atherosclerosis. (First Release June 15 2012; *J Rheumatol* 2012;39:1648–53; doi:10.3899/jrheum.111506)

Key Indexing Terms:

SYSTEMIC SCLEROSIS

RAYNAUD'S PHENOMENON

DIGITAL ULCERS

DIGITAL AMPUTATION

PERIPHERAL ARTERY DISEASE

HYPERCHOLESTEROLEMIA

ATHEROSCLEROSIS

Systemic sclerosis (SSc) is a chronic autoimmune disease of unknown etiology characterized by widespread microvascular damage, immunologic abnormalities, skin fibrosis, and visceral involvement. The clinical picture is heterogeneous; some manifestations are due to the fibrotic process, e.g., skin sclerosis, lung fibrosis, myocardial involvement, joint contractures, and tendon friction rubs; others are caused by microvascular injury, e.g., Raynaud's phenomenon (RP), digital ulcers and digital necrosis, scleroderma renal crisis, pulmonary arterial hypertension (PAH), telangiectasias, and watermelon stomach.

Digital ulcers affect about half of patients during the dis-

ease course^{1,2,3} and occur in about 30% of patients every year⁴. Digital ulcers have a negative effect on quality of life; they cause local pain and functional impairment and may predispose to severe complications such as soft-tissue infections, osteomyelitis, and gangrene⁵. In the Pittsburgh database, about 11% of patients underwent amputation or experienced gangrene⁶. Harrison, *et al* reported digital amputation in 15 out of 101 patients with SSc (15%)⁷. A French study estimated an incidence of finger amputation of 1.2% per year among subjects with a history of digital ulcers, or globally, 4 out of 103 patients (3.9%)³. A study comparing bosentan to placebo in the prevention of digital ulcers (RAPIDS-2) reported digital amputation in 1% to 2% of patients per year⁸.

The aim of our retrospective single-center study was to evaluate the prevalence of digital necrosis requiring amputation in SSc and to compare the characteristics of patients with and those without this severe vascular complication.

MATERIALS AND METHODS

Study population. In September 2011 we reviewed the medical records of 188 patients with SSc followed in the Rheumatology Unit since 2004.

All patients fulfilled the American College of Rheumatology criteria for

From the Rheumatology Unit, Department of Medicine, University of Verona, Italy.

P. Caramaschi, MD; D. Biasi, MD, Professor of Rheumatology; C. Caimmi, MD; G. Barausse, MD; D. Sabbagh, MD; I. Tinazzi, MD; V. La Verde, PhD; S. Tonetta, MD; S. Adami, MD, Professor of Rheumatology, University of Verona.

Address correspondence to Dr. P. Caramaschi, Unità di Reumatologia, Policlinico G.B. Rossi, Piazzale Scuro, 37134 Verona, Italy.

E-mail: paola.caramaschi@ospedaleuniverona.it

Accepted for publication April 16, 2012.

the diagnosis of SSc⁹. The distinction between limited and diffuse cutaneous SSc was made according to the criteria of LeRoy, *et al*¹⁰.

All patients underwent examination and laboratory evaluation including antinuclear antibody (ANA) and antiextractable nuclear antigen antibody detection by indirect immunofluorescence on HEp-2 cells and ELISA method, respectively. Skin involvement was assessed by modified Rodnan skin score (mRSS)¹¹.

Patients underwent the following investigations: chest radiograph; pulmonary function test with diffusing capacity for carbon monoxide adjusted to hemoglobin (DLCO); Doppler echocardiogram to estimate systolic pulmonary artery pressure (sPAP) and nailfold videocapillaroscopy (NVC); the microvascular alterations were classified into 3 different patterns: early, active, and late, according to Cutolo, *et al*¹².

Right heart catheterization was performed in cases of dyspnea of unknown origin or when estimated sPAP was > 40 mm Hg or DLCO < 50% predicted, in patients without pulmonary fibrosis. Diagnosis of PAH was made when mean PAP at rest was \geq 25 mm Hg in the presence of normal capillary wedge pressure. Pulmonary fibrosis was diagnosed by high-resolution computed tomography. Digital ulcers were defined as ischemic ulcers located at the digit tip; ulcers overlying a bony prominence at the site of joint contractions were not considered.

Digital necrosis was recorded in cases of extensive and prolonged ischemic phenomena with significant tissue loss requiring amputation of 1 or more phalanges.

Comorbidities such as diabetes mellitus, hypercholesterolemia, hypertension, overweight/obesity, and peripheral arterial disease were recorded, as well as smoking habits. Diabetes mellitus, hypercholesterolemia, and hypertension were defined according to international criteria^{13,14,15}; patients were classified as having hypercholesterolemia if total cholesterol value exceeded 200 mg/dl while not taking statins¹⁵. Overweight was defined as body mass index (BMI) > 25 kg/m² and obesity as BMI > 30 kg/m². Smoking history was considered positive in cases of current or past smoking habit.

Peripheral arterial disease was suspected in cases of reduction or absence of arterial pulses at the limbs that was confirmed by echo color Doppler sonography investigation.

Patients were receiving a wide variety of drugs including vasodilators, immunosuppressants, low-dose prednisone, aspirin, statins, and H₂-receptor antagonists.

All investigations were performed at University Hospital of Verona as part of routine diagnostic procedures applied to patients with scleroderma. Written informed consent was obtained from all participants and registered at the local ethics committee.

Statistics. Statistical analysis was performed using SPSS 17.0 (SPSS Inc., Chicago, IL, USA). Distributions of skewed continuous variables (i.e. age, SSc duration, duration from RP onset, skin involvement evaluated by mRSS) were expressed as geometric mean \pm SD after logarithmic transformation. Duration of followup was reported as median with interquartile range (IQR). Categorical variables were expressed as absolute numbers. For categorical variables, statistical analysis was carried out using Fisher's exact test or chi-square test where appropriate. In studying peripheral artery diseases we added 0.5 to all cells according to the Cochrane Collaboration *Handbook*¹⁶, because the OR cannot be calculated if there is "zero" in one box; indeed, there was no patient who had undergone digital amputation in the absence of peripheral artery disease.

Differences between groups were analyzed by ANOVA and Kolmogorov-Smirnov test for continuous and ordinal variables, respectively. Prediction factors for surgical digital amputation were investigated using a multivariate logistic regression model. A Kaplan-Meier curve was created for the first episode of digital amputation.

RESULTS

The study population included 188 patients: 162 women and 26 men. The mean age was 59.2 \pm 1.2 years, mean disease duration 8.0 \pm 2.3 years, mean duration from onset of RP 11.7

\pm 2.2 years, and the median followup duration 92 months (IQR 7–177). Clinical and demographic characteristics of the SSc population are shown in Table 1.

One hundred fifty-six patients are currently being followed; 19 patients had died and 13 cases were lost to followup. Sixty-four patients (34.0%) reported a history of 1 or more digital ulcers.

Nine patients (4.8%) underwent partial or total surgical amputation of 1 or more fingers or toes because of digital necrosis; all but 1 had a long history of multiple and persistent digital ulcers. Figure 1 shows the Kaplan-Meier curve for the first episode of digital amputation.

All the patients who required digital amputation were women; anti-Scl70 antibodies were positive in 1 subject, anticentromere antibodies (ACA) were detected in 8 patients. The diffuse disease pattern was present in 3 cases. Four patients underwent amputation of 1 or more toes and 3 underwent amputation of 1 or more fingers; 2 patients had either toes or fingers amputated. Six patients had multiple digital amputations and 3 presented a single episode. After the loss of multiple toes, 2 patients underwent amputation of both legs.

Table 1. Demographic and clinical characteristics of the 188 patients with systemic sclerosis. Values are mean \pm SD after logarithmic transformation, or number (%).

Characteristic	
Age, yrs, mean (SD)	59.2 (1.2)
Sex, men/women, n (%)	26/162 (13.8/86.2)
Disease duration, yrs, mean (SD)	8.0 (2.3)
Duration from RP onset, yrs, mean (SD)	11.7 (2.2)
mRSS, mean (SD)	8.7 (1.7)
Disease pattern, n (%)	
Diffuse	65 (34.6)
Limited	123 (65.4)
Autoantibody pattern, n (%)	
ACA-positive	100 (53.2)
Anti-Scl70-positive	58 (30.9)
ANA-positive (absent ACA and anti-Scl70)	30 (16.0)
NVC pattern, 160 cases, n (%)	
Normal/aspecific	11 (5.9)
Early	34 (18.9)
Active	68 (36.2)
Late	47 (25)
Previous or present history of digital ulcers, n (%)	64 (34.0)
Digital amputation, n (%)	9 (4.8)
Peripheral arterial disease involving upper limbs, n (%)	1 (0.5)
Peripheral arterial disease involving lower limbs, n (%)	12 (6.4)
Hypercholesterolemia, n (%)	89 (47.3)
Hypertension, n (%)	58 (30.9)
Diabetes, n (%)	8 (4.3)
Smoking habit, n (%)	38 (20.2)
Overweight/obese, n (%)	56 (29.8)
Pulmonary fibrosis, n (%)	51 (27.1)
Pulmonary artery hypertension, n (%)	11 (5.9)

RP: Raynaud's phenomenon; mRSS: modified Rodnan skin score; ACA: anticentromere antibodies; anti-Scl70: anti-Scl70 antibodies; ANA: antinuclear antibodies; NVC: nailfold videocapillaroscopy.

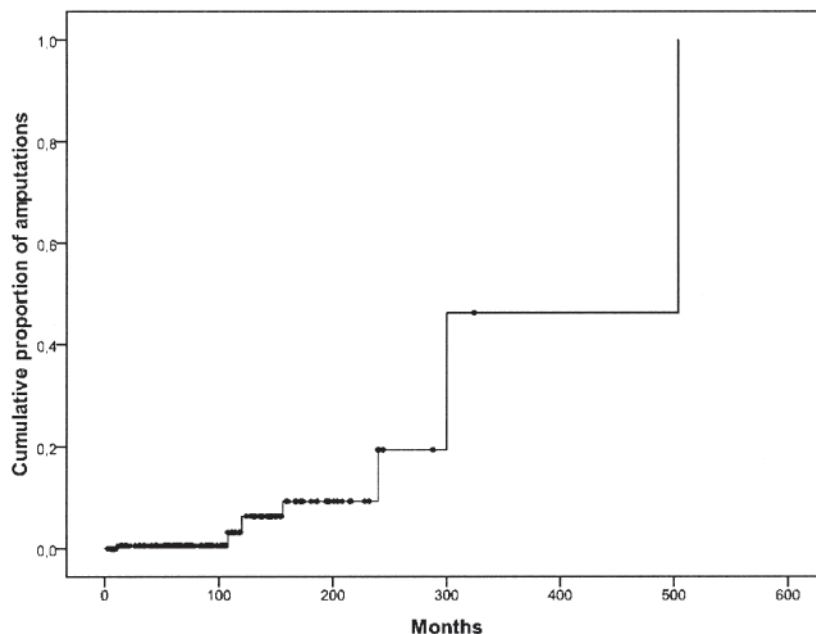


Figure 1. Kaplan-Meier curve for the first episode of digital amputation.

The annual incidence of digital necrosis requiring the amputation of 1 or more fingers or 1 or more toes was 1.19 per 100 patient-years.

During the followup the patients received a wide variety of treatments; almost all patients had been given oral and/or intravenous vasodilators both before and after digital amputation. Only 2 patients were receiving cyclic iloprost infusion before developing the first episode of digital necrosis requiring amputation: 1 underwent amputation of 1 toe soon after starting iloprost treatment, the other after prolonged iloprost administration. Five patients were cyclically treated with iloprost after 1 or more digital amputation; 3 of these patients presented with a relapse of digital necrosis involving toes even during iloprost therapy. The majority of digital amputations occurred when bosentan had not yet been licensed for prevention of digital ulcers in SSc; therefore none of the patients was receiving the drug at the time of the first digital necrosis. Subsequently, 2 patients were given bosentan. One of them, with concomitant severe atherosclerosis, was treated with the drug after toe amputation, but the treatment did not prevent the occurrence of new digital ulcers and the patient died soon after with a bowel infarction. The second patient discontinued bosentan because of the appearance of leg edema. Another patient was not given bosentan for concomitant hepatopathy.

A reduction/absence of 1 or more arterial pulses at the lower limbs was observed in 8 out of the 9 subjects who underwent digital amputation; echo color Doppler sonography evaluation revealed atherosclerotic plaques with multiple arterial stenosis and/or occlusions. In 4 cases the peripheral artery disease was also documented by angiography and treated with

angioplasty, with partial or transitory benefit. All patients exhibited 1 or more cardiovascular risk factors. Hypercholesterolemia was observed in all the cases, while high blood pressure, smoking history, and obesity were recorded in 5 cases, 1 case, and 1 case, respectively. None of these patients had diabetes.

In the ninth patient, who lost 3 fingers of the right hand, no cardiovascular risk factors were documented, but angiography showed occlusion of the ulnar artery and stenosis of the radial artery at the same side without evidence of atherosclerotic plaques.

The comparison of patients with and those without digital amputations showed that those who developed this severe complication were older (70.0 ± 1.0 vs 58.7 ± 1.2 years, respectively; $p = 0.040$ by ANOVA), had longer duration of RP (29.2 ± 1.5 vs 11.2 ± 2.1 years; $p = 0.001$ by ANOVA), and had longer disease duration (18.9 ± 1.6 vs 7.6 ± 2.5 years; $p = 0.002$ by ANOVA). Digital amputations were significantly associated with peripheral artery diseases ($p < 0.001$ by Fisher exact test; OR 352, 95% CI 37.5–3305) and hypercholesterolemia ($p = 0.014$ by Fisher exact test; OR 9.67, 95% CI 1.18–79.0). These data are reported in Table 2.

We divided the patients with SSc into 2 subgroups based on the autoantibody profile, i.e., subjects with positivity for ACA and patients with positivity for anti-Scl70 or ANA in the absence of SSc-associated autoantibodies. The positivity for ACA was significantly associated with digit amputation ($p = 0.038$ by Fisher exact test).

There was no association between digital amputation and the following variables: sex, mRSS, limited or diffuse disease pattern, NVC patterns, lung fibrosis, PAH, smoking

Table 2. Characteristics of systemic sclerosis (SSc) patients with or without digital necrosis requiring amputation. Values are mean \pm SD after logarithmic transformation, or number (%).

Characteristic	With Digital Amputation, n = 9	Without Digital Amputation, n = 179	p
Age, yrs, mean (SD)	70.0 (1.0)	58.7 (1.2)	0.040*
Male, n (%)	0	26 (14.5)	NS**
Disease duration, yrs, mean (SD)	18.9 (1.6)	7.6 (2.3)	0.002*
Duration from RP onset, yrs, mean (SD)	29.2 (1.5)	11.2 (2.1)	0.001*
mRSS, mean (SD)	9.8 (1.3)	8.6 (1.8)	NS*
SSc subset, n (%)			
Limited	6 (66.6)	117 (65.4)	NS**
Diffuse	3 (33.3)	62 (34.6)	
Autoantibody pattern, n (%)			
ACA-positive	8 (88.9)	92 (51.4)	0.038**
ACA-negative	1 (11.1)	87 (48.6)	
NVC pattern, 160 cases, n (%)			
Normal/aspecific	0	11 (7.2)	
Early	0	34 (22.2)	NS***
Active	3 (42.9)	65 (42.5)	
Late	4 (57.1)	43 (28.1)	
Peripheral arterial disease, n (%)	9 (100)	4 (2.2)	< 0.001**
Hypercholesterolemia, n (%)	8 (88.9)	81 (45.3)	0.014**
Hypertension, n (%)	5 (55.6)	53 (29.6)	NS**
Diabetes, n (%)	0	8 (4.5)	NS**
Smoking habits, n (%)	1 (11.1)	37 (20.7)	NS**
Overweight/obesity, n (%)	1 (11.1)	55 (30.7)	NS**
Pulmonary fibrosis, n (%)	1 (11.1)	50 (27.9)	NS**
Pulmonary artery hypertension, n (%)	0	11 (6.1)	NS**

* ANOVA; ** Fisher's exact test; *** chi-square test. RP: Raynaud's phenomenon; mRSS: modified Rodnan skin score; ACA: anticentromere antibodies; anti-Scl70: anti-Scl70 antibodies; NVC: nailfold videocapillaroscopy; NS: nonsignificant.

history, concomitant diabetes, hypertension, or overweight/obesity.

Multivariate logistic regression models were applied to the following variables: age, time from onset of RP, disease duration, hypercholesterolemia, and autoantibody pattern (ACA positivity vs anti-Scl70 antibody or ANA positivity). Time from RP onset turned out to be the variable independently associated with digit amputation ($p < 0.01$). Because there was no patient who had undergone digital amputation in the absence of concomitant peripheral artery disease, this variable could not be included in the analysis.

DISCUSSION

We investigated the role of risk factors for digital necrosis requiring amputation, one of the most severe complications of SSc disease. Severe digital vasculopathy has a negative effect on quality of life and self-image, may cause pain and disability, and requires frequent and prolonged hospital admission for treatment with intravenous vasodilators like prostacyclin, oral and parenteral antibiotics, and opioid analgesia, or for digital sympathectomy, digital amputation, or other surgical interventions^{5,6}. The burden for the community is very high considering direct costs together with indirect costs because of absence from work.

Digital necrosis requiring amputation is commonly preceded by recurrent ischemic digital ulcers, which were observed in one-third of the cases in our population. This proportion is lower than previously reported^{1,2,3} and this might be due to the large use of iloprost in cases of severe RP¹⁷.

The prevalence of digital amputation in our population was similar to that observed in a French study³ and lower than that reported by others^{6,7,18}; these discrepancies can be explained by the large heterogeneity of the study populations regarding ethnic origin, different length of followup, and the therapeutic approach.

We have demonstrated that patients who required digital amputation suffered from a concomitant peripheral artery disease. Eight patients had concomitant atherosclerosis, with evidence of multiple plaques of the lower limb arteries. The ninth case did not show evidence of atherosclerosis, cardiovascular risk factors, or Buerger's disease. Involvement of the ulnar artery in this patient was similar to that observed by Stafford, *et al*¹⁹. Interestingly, they reported wall thickening and lumen narrowing of the ulnar artery in a cohort of SSc patients with an unexpected higher incidence compared to controls matched for age, sex, and cardiovascular risk factors. The same group also reported a case of SSc with concomitant large-vessel involvement in which histologic examination of the ulnar

artery showed medial thickening with circumferential luminal narrowing and occlusion by acellular material. The authors concluded that ulnar arteriopathy in the absence of atherosclerosis and Buerger's disease may represent a clinical feature of SSc²⁰.

A recent metaanalysis showed an increased incidence of atherosclerosis in SSc; robust data were reported regarding carotid intima-media thickness and reduced flow-mediated vasodilation²¹. The increased incidence of atherosclerosis in SSc may be related to multiple factors, such as hyperhomocysteinemia²², high levels of oxidized low-density lipoprotein antibodies²³, high level of lipoprotein(a)²⁴, and presence of abnormally functioning proinflammatory high-density lipoprotein²⁵. Moreover, inflammatory involvement of the large-vessel wall²⁶ might contribute to the development of atherosclerosis. There is a growing body of evidence concerning the association between atherosclerosis and other systemic autoimmune diseases such as rheumatoid arthritis²⁷ and systemic lupus erythematosus²⁸.

The co-occurrence of large-vessel involvement and the typical SSc microvasculopathy observed in our patients with SSc who underwent digital amputation likely exceeds the compensation capacity of the peripheral circulation, thus favoring severe vascular complications. Nihtyanova, *et al*, in agreement with our observations, identified concomitant atherosclerosis and Buerger's disease as risk factors for severe digital vasculopathy in SSc⁵. The involvement of large vessels in SSc associated with digital or limb amputation has been reported by others^{19,20,26}.

In our study, digital amputation was associated with hypercholesterolemia; this observation may further support the use of statins in SSc. Statins are known to have pleiotropic effects; it has been reported that in SSc these drugs are able to increase the number of circulating endothelial progenitors²⁹, which might counteract insufficient vascular repair due to defective vasculogenesis. Moreover, statins decrease the markers of endothelial injury/dysfunction^{30,31}. From a clinical viewpoint, atorvastatin has been shown to reduce the incidence of new digital ulcers³² and ameliorate RP^{29,32}.

We did not observe a correlation between smoking habits and digital amputation, but this might be due to the low prevalence of smokers in our cohort. Tobacco use, in fact, was previously identified as one of the risk factors for digital ulcers in a subgroup of SSc cases cyclically treated with iloprost infusions¹⁷. A study regarding cigarette smoking habit and digital vascular disease in SSc showed that current smokers were more frequently admitted to hospital for intravenous vasodilator therapy and had more digital debridements compared to never-smokers; digital amputations were more frequent in current smokers, but this data did not achieve statistical significance⁷. The SSc database of the Royal Free Hospital, London, UK, showed that patients with persistent digital ulcers are more likely to be current smokers than those without¹, but this observation is in contrast with others^{3,18}.

The incidence of digital gangrenous lesions in the Pittsburgh University SSc cohort increased with the time elapsed since the development of digital ulcers. Moreover, digital gangrene leading to amputation developed in the subset of patients with persistent digital ulcers¹, and this was in agreement with our observations. In addition, our experience showed that digital loss was independently associated with a prolonged duration of RP, confirming that longstanding repeated hypoperfusion negatively interferes with tissue trophism, thus favoring digital necrosis.

Digital amputation was also associated with positivity for ACA; this result is in agreement with a report by Wigley, *et al*¹⁸ in 98 subjects, 20.4% of whom experienced 1 or multiple digit losses. In this latter study digital amputation did not appear to be associated with other variables such as age, smoking status, disease duration, and time from RP onset¹⁸. To our knowledge, however, no relationship between digital tip gangrene and pattern of SSc-associated autoantibodies has been reported elsewhere³³.

We did not observe a correlation between digital amputation and NVC pattern, likely because of the low number of cases; a larger cohort of patients might identify a positive correlation with this pattern, which in our study was more represented among patients who experienced the complication.

A limitation of our study is its retrospective design. Digital amputation, the main clinical characteristic analyzed, could not be underestimated for its obvious clinical impact. In addition, echo color Doppler of upper and lower limbs was not performed in all cases but only when it was considered clinically relevant; therefore we do not know the prevalence of peripheral artery disease among the patients with SSc who did not have digital amputation. Moreover, the small number of SSc patients with digital amputation may have led to underestimation of the risk factors for this severe complication; a prospective multicenter study would be useful to confirm our results.

Our experience clearly shows that concomitant involvement of large vessels is a strong risk factor for digital amputation in patients with SSc; atherosclerosis was the cause of the concomitant peripheral artery disease in the majority of patients in the presence of abnormal cholesterol levels. These data may further support the use of statins in SSc. Additional risk factors for amputation were the history of multiple and persistent digital ulcers, prolonged duration of RP, and the presence of ACA. These findings may assist identification of patients for whom powerful and protracted vasodilator therapy may be recommended.

REFERENCES

1. Ingraham KM, Steen VD. Morbidity of digital tip ulcerations in scleroderma [abstract]. *Arthritis Rheum* 2006;54 Suppl:578.
2. Ferri C, Valentini G, Cozzi F, Sebastiani M, Michelassi C, La Montagna G, et al. Systemic sclerosis: demographic, clinical, and serologic features and survival in 1,012 Italian patients. *Medicine* 2002;81:139-53.

3. Hachulla E, Clerson P, Launay D, Lambert M, Morell-Dubois S, Queyrel V, et al. Natural history of ischemic digital ulcers in systemic sclerosis: Single-center retrospective longitudinal study. *J Rheumatol* 2007;34:2423-30.
4. Denton CP, Korn JH. Digital ulceration and critical digital ischemia in scleroderma. *Scleroderma Care Res* 2003;1:12-6.
5. Nihtyanova SI, Brough GM, Black CM, Denton CP. Clinical burden of digital vasculopathy in limited and diffuse cutaneous systemic sclerosis. *Ann Rheum Dis* 2008;67:120-3.
6. Steen V, Denton CP, Pope JE, Matucci-Cerinic M. Digital ulcers: Overt vascular disease in systemic sclerosis. *Rheumatology* 2009;48 Suppl:19-24.
7. Harrison BJ, Silman AJ, Hider SL, Herrick AL. Cigarette smoking as a significant risk factor for digital vascular disease in patients with systemic sclerosis. *Arthritis Rheum* 2002;46:3312-6.
8. Seibold JR, Denton CP, Furst DE, Matucci-Cerinic M, Mayes MD, Morganti A, et al. Bosentan prevents occurrence but does not speed healing of digital ulcers in patients with systemic sclerosis (SSc) [poster]. *Arthritis Rheum* 2005;52 Suppl:552.
9. Subcommittee for scleroderma criteria of the American Rheumatism Association diagnostic and therapeutic criteria committee. Preliminary criteria for the classification of systemic sclerosis (scleroderma). *Arthritis Rheum* 1980;23:581-90.
10. LeRoy EC, Black CM, Fleischmajer R, Jablonska S, Krieg T, Medsger TA Jr, et al. Scleroderma (systemic sclerosis): Classification, subsets and pathogenesis. *J Rheumatol* 1988;15:202-5.
11. Akesson A, Fiori G, Krieg T, van den Hoogen FHJ, Seibold JR. Assessment of skin, joint, tendon and muscle involvement. *Clin Exp Rheumatol* 2002;21 Suppl:S5-8.
12. Cutolo M, Sulli A, Pizzorni C, Accardo S. Nailfold videocapillaroscopy assessment of microvascular damage in systemic sclerosis. *J Rheumatol* 2000;27:155-60.
13. Alberti KG, Zimmet PZ. Definition, diagnosis and classification of diabetes mellitus and its complications. Part 1: Diagnosis and classification of diabetes mellitus provisional report of a WHO consultation. *Diabet Med* 1998;15:539-53.
14. Mancia G, De Backer G, Dominiczak A, Cifkova R, Fagard R, Germano G, et al. 2007 Guidelines for the management of arterial hypertension: The Task Force for the Management of Arterial Hypertension of the European Society of Hypertension (ESH) and of the European Society of Cardiology (ESC). *J Hypertens* 2007;25:1105-87.
15. Executive summary of the third report of the National Cholesterol Education Program (NCEP). Expert panel on detection, evaluation, and treatment of high blood cholesterol in adults (Adult Treatment Panel III). *JAMA* 2001;285:2486-97.
16. Higgins JPT, Green S, editors. *Cochrane handbook for systematic reviews of interventions 4.2.5 [updated May 2005]; Section 8. In: The Cochrane Library, Issue 3, 2005. Chichester, UK: John Wiley & Sons; 2005.*
17. Caramaschi P, Martinelli N, Volpe A, Pieropan S, Tinazzi I, Patuzzo G, et al. A score of risk factors associated with ischemic digital ulcers in patients affected by systemic sclerosis treated with iloprost. *Clin Rheumatol* 2009;28:807-13.
18. Wigley FM, Wise RA, Miller R, Needleman BW, Spence RJ. Anticentromere antibodies as a predictor of digit ischemic loss in patients with systemic sclerosis. *Arthritis Rheum* 1992;35:688-93.
19. Stafford L, Englert H, Gover J, Bertouch J. Distribution of macrovascular disease in scleroderma. *Ann Rheum Dis* 1998;57:476-9.
20. Youssef P, Englert H, Bertouch J. Large vessel occlusive disease associated with CREST syndrome and scleroderma. *Ann Rheum Dis* 1993;52:464-6.
21. Au K, Singh MK, Bodukam V, Bae S, Maranian P, Ogawa R, et al. Atherosclerosis in systemic sclerosis: A systematic review and meta-analysis. *Arthritis Rheum* 2011;63:2078-90.
22. Caramaschi P, Martinelli N, Biasi D, Carletto A, Faccini G, Volpe A, et al. Homocysteine plasma level is related to the severity of lung impairment in scleroderma. *J Rheumatol* 2003;30:298-304.
23. Herrick AL, Illingworth KJ, Hollis S, Gomez-Zumaquero JM, Tinahones FJ. Antibodies against oxidized low-density lipoproteins in systemic sclerosis. *Rheumatology* 2001;40:401-5.
24. Lippi G, Caramaschi P, Montagnana M, Salvagno GL, Volpe A, Guidi G. Lipoprotein[a] and the lipid profile in patients with systemic sclerosis. *Clin Chim Acta* 2006;364:345-8.
25. Khurma V, Meyer C, Park GS, McMahan M, Lin J, Singh RR, et al. A pilot study of subclinical coronary atherosclerosis in systemic sclerosis: Coronary artery calcification in cases and controls. *Arthritis Rheum* 2008;59:591-7.
26. Youssef P, Brama T, Englert H, Bertouch J. Limited scleroderma is associated with increased prevalence of macrovascular disease. *J Rheumatol* 1995;22:469-72.
27. Ozbalkan Z, Efe C, Cesur M, Ertek S, Nasiroglu N, Berneis K, et al. An update on the relationships between rheumatoid arthritis and atherosclerosis. *Atherosclerosis* 2010;212:377-82.
28. Sherer Y, Zinger H, Shoenfeld Y. Atherosclerosis in systemic lupus erythematosus. *Autoimmunity* 2010;43:98-102.
29. Kuwana M, Kaburaki J, Okazaki Y, Yasuoka H, Kawakami Y, Ikeda Y. Increase in circulating endothelial precursors by atorvastatin in patients with systemic sclerosis. *Arthritis Rheum* 2006;54:1946-51.
30. Abou-Raya A, Abou-Raya S, Helmii M. Statins as immunomodulators in systemic sclerosis. *Ann NY Acad Sci* 2007;1110:670-80.
31. Del Papa N, Cortiana M, Vitali C, Silvestris I, Maglione W, Comina DP, et al. Simvastatin reduces endothelial activation and damage but is partially ineffective in inducing endothelial repair in systemic sclerosis. *J Rheumatol* 2008;35:1323-8.
32. Abou-Raya A, Abou-Raya S, Helmii M. Statins: potentially useful in therapy of systemic sclerosis-related Raynaud's phenomenon and digital ulcers. *J Rheumatol* 2008;35:1801-8.
33. Steen VD. Autoantibodies in systemic sclerosis. *Semin Arthritis Rheum* 2005;35:35-42.