

Changes in Regional Brain Morphology in Neuropsychiatric Systemic Lupus Erythematosus

PATRICIA C. CAGNOLI, PIA C. SUNDGREN, ANSON KAIRYS, COURTNEY C. GRAFT, DANIEL J. CLAUW, STEPHEN GEBARSKI, W. JOSEPH McCUNE, and TOBIAS SCHMIDT-WILCKE

ABSTRACT. Objective. Neuropsychiatric lupus (NPSLE) is a severe and potentially life-threatening condition, reported to occur in 25%–70% of patients with systemic lupus erythematosus (SLE). Brain imaging, especially magnetic resonance imaging, is frequently used to diagnose or exclude overt cerebral pathologies such as edema, hemorrhage, and central thrombosis. More advanced imaging techniques have been applied to demonstrate subtle changes in regional cerebral blood flow and brain structure. We investigated changes in regional gray-matter (GM) volume in SLE patients without neurological manifestations and NPSLE patients at an acute stage of the disease.

Methods. Using high-resolution structural images and voxel-based morphometry (VBM), we investigated regional GM volume in 20 NPSLE patients (within 2 weeks of the acute manifestation), 18 SLE patients without neurologic and/or psychiatric manifestations, and 18 healthy controls.

Results. VBM analyses revealed several regions of GM atrophy in various parts of the brain in NPSLE and SLE patients. GM atrophy was seen in both groups in the temporal and parietal lobes and was most pronounced in the posterior thalamus bilaterally. Both groups showed an increase in regional GM volume in the posterior parahippocampal gyrus.

Conclusion. Our data suggest that changes in regional brain morphology are present in acute NPSLE, but also in SLE (as compared to controls), which might be indicative of a subclinical neurodegenerative process. Further research is needed to investigate whether specific neuropsychiatric symptoms are related to these changes. (First Release April 1 2012; *J Rheumatol* 2012;39:959–67; doi:10.3899/jrheum.110833)

Key Indexing Terms:

SYSTEMIC LUPUS ERYTHEMATOSUS

NEUROPSYCHIATRIC LUPUS

BRAIN MORPHOLOGY

VOXEL-BASED MORPHOMETRY

THALAMUS

From the Department of Internal Medicine, Division of Rheumatology; Department of Radiology, Division of Neuroradiology; and Department of Anesthesiology, Chronic Pain and Fatigue Research Center, University of Michigan, Ann Arbor, Michigan, USA; and Department of Diagnostic Radiology, Clinical Sciences Lund, Lund University, Lund, Sweden.

Dr. Cagnoli was supported by MICH Pilot Grant Program UL1RR024986. Dr. Sundgren was supported by a Department of Radiology, University of Michigan, Seed Grant, a Berlex research grant, and by grant UL1RR024986. Dr. Schmidt-Wilcke is supported by a grant of the Deutsche Forschungsgemeinschaft (GZ SchM 2665/1-1).

P.C. Cagnoli, MD, Department of Internal Medicine, Division of Rheumatology, University of Michigan; P.C. Sundgren, MD, PhD, Department of Radiology, Division of Neuroradiology, University of Michigan, and Department of Diagnostic Radiology, Clinical Sciences Lund, Lund University; A. Kairys, BA, Department of Anesthesiology, Chronic Pain and Fatigue Research Center; C.C. Graft, BA, Department of Internal Medicine, Division of Rheumatology; D.J. Clauw, MD, Department of Anesthesiology, Chronic Pain and Fatigue Research Center; S. Gebariski, MD, Department of Radiology, Division of Neuroradiology; W.J. McCune, MD, Department of Internal Medicine, Division of Rheumatology; T. Schmidt-Wilcke, MD, Department of Anesthesiology, Chronic Pain and Fatigue Research Center, University of Michigan, Department of Neurology, Hertie Institute, University of Tübingen, Tübingen, Germany.

Address correspondence to Dr. T. Schmidt-Wilcke, Chronic Pain and Fatigue Research Center, Department of Anesthesiology, University of Michigan, 2325 Stone Road, Ann Arbor, MI 48105, USA. E-mail: tobias.schmidt-wilcke@med.uni-tuebingen.de

Accepted for publication December 1, 2011.

Systemic lupus erythematosus (SLE) is a chronic inflammatory, immune-mediated disease, which affects 0.1% of the general population. Neuropsychiatric symptoms have been reported to occur in 25%–70% of patients with SLE^{1,2} and are associated with increased morbidity and mortality^{3,4}. Clinical manifestations of neuropsychiatric SLE (NPSLE) include headaches, stroke or stroke-like symptoms, myelopathy, seizures, psychosis, confusional states, and cognitive impairment, and also peripheral manifestations such as cranial neuropathies and demyelinating polyradiculoneuropathies. Brain imaging, especially magnetic resonance imaging (MRI), is frequently used to diagnose or exclude cerebral pathologies such as edema, hemorrhage, and cerebrovascular thrombosis, and MRI has become part of the routine clinical investigation⁵. Abnormal conventional MRI findings are common in SLE and NPSLE^{6,7} and range from nonspecific small punctate focal lesions in white matter (WM; present in the majority of patients with NPSLE, but not specific⁸) to more severe findings such as cortical atrophy, ventricular dilation, cerebral edema, cerebral infarctions, and intracranial hemorrhage⁹. These findings are attributed to different mechanisms, including thrombosis, vasculitis, and antibody-mediated neuronal

injury¹⁰. From animal models there is evidence that in SLE neuroinflammatory processes might lead to neuronal loss¹¹, as well as impaired neurogenesis and neuronal migration¹².

In the framework of scientific investigations, more advanced imaging techniques have been used to also demonstrate subtle changes in regional brain structure^{13,14,15}, brain chemistry^{16,17}, cerebral blood flow^{18,19}, and cerebral glucose use²⁰, mainly in patients with NPSLE. These techniques rely either on region of interest-based or voxel-based statistical analyses and thus help to delineate group differences. Numerous studies have described cerebral atrophy in patients with SLE and NPSLE^{6,21}. Specific regions/structures of interest have been the hippocampus²², the corpus callosum²³, and the cerebellum²¹, all of which showed atrophy, compared to healthy controls. To our knowledge only 3 studies have applied automated whole-brain analysis techniques to investigate changes in regional brain morphology in patients with and without neuropsychiatric symptoms^{13,14,15}. Two studies reported cortical and subcortical gray matter (GM) atrophy in patients with NPSLE, but only subtle changes in patients with SLE^{13,14}. A third study investigated changes in WM volume in patients with SLE and controls, reporting a decrease in regional WM volume in the internal capsula, as well as in the postcentral gyrus and parahippocampal gyrus¹⁵. Interestingly, most of the patients with SLE in the latter study did not have any neuropsychiatric manifestations and the investigators suggest that WM loss, implying brain damage, is present even before clear clinical neurological symptoms are present. Thus it remains unclear at what timepoint atrophy occurs in patients with SLE and whether there are any features of brain morphology that can be identified that mark the transition from SLE to NPSLE.

NPSLE is associated with progressive WM and GM atrophy¹³, yet some regional atrophy may also be present in SLE patients without neuropsychiatric manifestations; we were specifically interested in investigating brain morphology in NPSLE patients at their first acute neuropsychiatric manifestation and comparing them to both SLE patients without current or previous neuropsychiatric history and to healthy controls. Using voxel-based morphometry (VBM)²⁴ we prospectively investigated regional brain morphology in 20 patients with an acute manifestation of NPSLE and 18 patients with SLE without a history/current manifestation of NPSLE. For the NPSLE group, MRI scans were obtained within 15 days of the neuropsychiatric event. Eighteen healthy volunteers matched for sex and age served as controls.

MATERIALS AND METHODS

Subjects. Twenty-two consecutive patients with acute NPSLE, defined as 1 or more neuropsychiatric manifestations within 2 weeks before inclusion in the study and without a history of NPSLE, and 21 consecutive patients with SLE, without history of or current neuropsychiatric symptoms, and 21 healthy controls were initially enrolled for study. The classification of

NPSLE was based on the 19 American College of Rheumatology (ACR) case definitions²⁵. In order to participate in the study, individuals needed to fulfill 4 or more ACR classification criteria²⁶ that were present within 2 weeks of the initial neuropsychiatric event. Patients in the SLE group were required to have no history of neuropsychiatric manifestations regardless of attribution. All participants were recruited from the Department of Internal Medicine, Division of Rheumatology, and the Department of Emergency Medicine at the University of Michigan. All SLE and NPSLE patients were recruited into the Michigan Lupus Cohort prior to their presentation. Patients with previous/known drug abuse, alcohol abuse, diabetes, stroke, and/or renal insufficiency were excluded. Finally, 20 NPSLE patients (20 women, mean age 40.7 yrs, range 22–67 yrs, SD 12.8), 18 SLE patients (16 women, mean age 40.64 yrs, range 22–67 yrs, SD 12.16), and 18 controls (18 women, mean age 40.64 yrs, range 19–60 yrs, SD 12.74) were included in the final brain imaging analysis. Two patients in the NPSLE group, 3 in the SLE group, and 3 controls had to be excluded from the analysis due to poor quality or motion artefacts of the high resolution structural images. There were no significant differences in age or sex distribution between groups; the 2 SLE groups did not differ with respect to disease duration and/or age at disease onset. For details see Table 1.

All subjects or the designated next of kin with power of attorney gave written consent prior to enrollment. The study had been approved by the Institutional Review Board of the University of Michigan.

Clinical assessments. All patients and controls were submitted to a standardized clinical and neurological examination including medical history (age, sex, race, age at disease onset, disease duration, etc.), physical examination, standard laboratory assessment, and a Mini-Mental State examination²⁷ (MMSE). For details of neuropsychiatric symptoms in patients with NPSLE see Table 2. MMSE evaluation in patients presenting with acute confusional state, who could not be evaluated at the time of admission, was delayed. However, all patients were able to perform the test within 96 hours of treatment. SLE and NPSLE patients underwent required laboratory tests to determine disease activity by the Systemic Lupus Erythematosus Disease Activity Index (SLEDAI)²⁸ as well as antiphospholipid antibody status. SLE was considered active with a SLEDAI score > 6. We chose this higher SLEDAI level to minimize the inclusion of patients who have persistently active serologies (anti-DNA antibodies, low complement measures, and/or leukopenia) without clinical evidence of disease activity.

Disease duration was defined as the time between the diagnosis of SLE and the day of the MRI. Central nervous system (CNS) manifestations were divided into central and peripheral, following ACR case definitions. Cumulative damage in both patient groups was assessed using the Systemic Lupus International Collaborating Clinics/American College of Rheumatology Damage Index (SLICC)⁴ at the time of acquisition of MRI. For details see Table 1.

With respect to age, disease duration, and SLEDAI and SLICC scores, as well as most laboratory data [except for the lupus anticoagulant (LAC)], groups were compared using ANOVA (for comparison of all 3 groups) or t test (in case only SLE and NPSLE patients were compared). Nonparametric (chi-square) tests were applied to compare sex distribution, LAC as a confirmation measure, β_2 -glycoprotein I antibodies (anti- β_2 -GPI; IgG, IgM, IgA), and anticardiolipin antibodies (IgG, IgM). Evidence of antibodies resulted in a score of 1 (in the corresponding category), absence resulted in a score of 0. For details see Table 3.

Conventional MRI assessment. All subjects had conventional MRI scans before and after contrast administration with the following sequences: T2-weighted, fluid attenuated inversion recovery (FLAIR), and T1-weighted images. Images were evaluated by an experienced neuroradiologist for morphological abnormalities such as acute or old infarcts, hemorrhage, focal or diffuse brain atrophy, focal lesions or pathological contrast enhancement, and for any additional lesions not related to SLE. The lesion burden, in the form of WM T2/FLAIR hyperintensive lesions, was defined as mild (1–5 small WM lesions), moderate (5–10 WM lesions), or severe (> 10 WM lesions). The neuroradiologist was blinded to clinical history and

Table 1. Demographic data and disease severity of subjects in the study.

Characteristic	Controls, n = 18	SLE Patients, n = 18	NPSLE Patients, n = 20	Significance
Age, mean/SD yrs (range)	40.64/12.74 (19–60)	40.64/12.16 (22–67)	40.7/12.8 (22–67)	$F_{(2,53)} = 0.101$ $p = 0.904$
Female, n	18	16	20	Chi-square = 2.3 $p > 0.05$
Race, n	1 Asian 17 white	1 AA 17 white	6 AA 14 white	
Age at disease onset, mean/SD yrs (range)	NA	34.2/10.8 (19–56)	32.8/13.9 (14–65)	$T_{(2,36)} = 0.349$ $p = 0.73$
Disease duration, mean/SD yrs (range)	NA	4.7/5.1 (0.6–15)	8/6.9 (0.7–23)	$T_{(2,34)} = -1.68$ $p = 0.102$
SLEDAI, mean/SD (range)	NA	1.8/2.17 (0–8)	11.4/6.3 (1–25)	$T_{(2,34)} = -5.95$ $p < 0.001$
SLICC, mean/SD (range)	NA	0.53/1.01 (0–3)	0.95/1.12 (0–4)	$T_{(2,36)} = -1.2$ $p = 0.233$
Mini-Mental State score	33–32	31–33	31–32	$p > 0.2$

AA: African American; NPSLE: neuropsychiatric systemic lupus erythematosus; SLE: systemic lupus erythematosus; SLEDAI: Systemic Lupus Erythematosus Disease Activity Index; SLICC: Systemic Lupus Erythematosus International Collaborating Clinics; NA: not applicable.

Table 2. Clinical manifestation, cerebrospinal fluid (CSF) findings and initial therapy of systemic lupus erythematosus patients who have neuropsychiatric symptoms.

Patient	Focal Disease	Diffuse Disease	CSF Findings	Therapy
1		Transverse myelitis (thoracic cord)	WBC 4 [†] , protein 34, IgG index 0.57	Pulse steroids**, CYC
2		Hallucinations, confusion	NA	Pulse steroids, CYC
3		Depression	NA	Antidepressants
4	R 6th nerve palsy		WBC 2, protein 29, IgG index 0.43	Pulse steroids, MYC
5	L Horner syndrome	Lupus headache	WBC 3, protein 34, IgG index 0.73 [†]	Pulse steroids, MYC
6		Acute cognitive decline	NA	Steroids
7		Disorientation, confusion, expressive aphasia	WBC 5 [†] , protein 45, IgG index 0.72 [†]	Pulse steroids, AZA
8	R hemiparesis		NA	Pulse steroids
9	TIA (L paresthesia, dysarthria)		NA	Pulse steroids
10	L hemiparesis, paresthesia		NA	Pulse steroids
*		Organic brain syndrome, acute cognitive decline	WBC 4 [†] , protein 31, IgG index 0.56 [†]	Pulse steroids, MYC
11		Lupus headache	WBC 8 [†] , protein 65 [†] , IgG index 0.88 [†]	Pulse steroids, MYC
12		Organic brain syndrome (loss of consciousness, confusion)	NA	Pulse steroids, CYC
*		Lupus headache	WBC 6 [†] , protein 42, IgG index 0.56	Steroids
13		Acute cognitive decline	NA	Pulse steroids
14		Transverse myelitis, lupus headache	WBC 2, protein 20, IgG index 0.50	Pulse steroids, CYC
15		Psychosis	WBC 0, protein 19, IgG index 0.44	Pulse steroids, CYC
16	TIA (expressive aphasia)		NA	Pulse steroids
17		Psychosis	NA	Pulse steroids, CYC
18		Acute cognitive decline	NA	Pulse steroids, MYC
19		Psychosis	WBC 0, protein 31	Pulse steroids, CYC
20	TIA (dysarthria, L hemiparesis)	Acute confusional syndrome	NA	Pulse steroids

* Patients excluded from analysis. ** Pulse steroids: solumedrol 1000 mg for 3 days followed by oral prednisone 1 mg/kg. † Abnormal CSF results. WBC: white blood cell count; VI: xxx; CYC: cyclophosphamide; MYC: mycophenolate; AZA: azathioprine; NA: not applicable; TIA: transient ischemic attack.

to which group the subject belonged (control, SLE, or NPSLE), but was aware of the patient's age and sex.

Voxel-based morphometry – MRI protocol. MR imaging was performed on a 3.0 Tesla scanner (Philips Achiva 2.6.3.4; Philips, Best, The Netherlands). All subjects underwent conventional MR brain imaging before and after

contrast administration. In addition a T1-weighted 3-D turbo field-echo dataset was acquired (TR 9.8 ms, TE 4.6 ms, flip angle 8°, field of view 252 x 252, yielding 168 sagittal slices with acquired voxel size of 1 x 1.26 x 1.0 mm and reconstructed to 0.87 x 0.87 x 1.00 mm).

Parenchymal volumes and fractions. The SPM5 software package

Table 3. Laboratory results and antibody data.

Variable	Controls, n = 18	SLE Patients, n = 18	NPSLE Patients, n = 20	Significance
Hemoglobin, mean/SD g/dl (range)	13.51/1.066 (11.6–15.5)	13.44/1.084 (10.9–15.8)	12.84/1.58 (9.5–14.7)	$F_{(2,51)} = 1.42$ $p = 0.252$
WBC, mean/SD K/mm ³ (range)	5.9/1.27 (3.9–8.4)	5.85/1.99 (2.6–9.2)	7.29/3.82 (2.9–17.3)	$F_{(2,51)} = 1.78$ $p = 0.179$
Platelet count, mean/SD K/mm ³ (range)	268.6/46.54 (214–365)	265.74/56.58 (152–405)	296.1/114.6 (176–683)	$F_{(2,51)} = 0.86$ $p = 0.43$
Creatinine, mean/SD g/dl (range)	0.778/0.157 (0.6–1.2)	0.823/0.206 (0.6–1.50)	0.756/0.154 (0.5–1.0)	$F_{(2,50)} = 1.82$ $p = 0.172$
dsDNA, mean/SD IU/ml (range)	NA	9.535/10.22 (0–28)	28.14/37.5 (0–126)	$T_{(2,34)} = -1.98$ $p = 0.056$
C3, mean/SD mg/dl (range)	NA	114.94/18.22 (85–145)	124.4/29.5 (65–189)	$T_{(2,34)} = -1.138$ $p = 0.263$
C4, mean/SD mg/dl (range)	NA	23.53/8.16 (7–27)	24.7/8.6 (11–39)	$T_{(2,33)} = -0.402$ $p = 0.690$
ESR, mean/SD mm/h (range)	NA	14.7/7.6 (4–27)	16.3/13.6 (2–43)	$T_{(-0.437)} = -0.437$ $p = 0.665$
CRP, mean/SD mg/dl (range)	NA	0.212/0.237 (0–1)	1.1/2.4 (0–3.3)	$T_{(2,32)} = -1.559$ $p = 0.129$
β_2 -GPI IgG, SGU (range)	NA	All negative (0–1)	1 of 19 positive (0–1)	Chi-square = 0.92 $p = 0.337$
β_2 -GPI IgM, SMU (range)	NA	All negative (0–1)	3 of 19 positive (0–1)	Chi-square = 2.928 $p = 0.087$
β_2 -GPI IgA, SAU (range)	NA	All negative (0–1)	All negative (0–1)	NA
aCL IgG, GPL (range)	NA	1 of 17 positive (0–1)	2 of 19 positive (0–1)	Chi-square = 0.253 $p = 0.615$
aCL IgM, MPL (range)	NA	All negative (0–1)	1 of 19 positive (0–1)	Chi-square = 0.920 $p = 0.337$
LAC (range)	All negative (0–1)	4 of 17 positive	1 of 19 positive (0–1)	Chi-square = 2.503 $p = 0.114$

β_2 -GPI: β_2 -glycoprotein I; C3: C3 complement; C4: C4 complement; aCL: anticardiolipin antibody; CRP: C-reactive protein; ESR: Westergren sedimentation rate; NPSLE: neuropsychiatric systemic lupus erythematosus; LAC: lupus anticoagulant (binominal); SLE: systemic lupus erythematosus; WBC: white blood cell count; NA: not applicable; IgG GPL: IgG phospholipid unit; IgM MPL: IgM phospholipid units.

(Functional Imaging Laboratories, London, UK) running under Matlab 7b was used to preprocess and analyze MRI data. Estimation of total GM volume (GMV), WM volume (WMV), and cerebrospinal fluid (CSF) was performed by segmenting the original image into GM, WM, and CSF, using the Individual Brain Atlases using Statistical Parametric Mapping software for automatic parcellation of brain structures (Cuban Neuroscience Center; Website: <http://www.thomaskoenig.ch/Lester/ibaspm.htm>). In order to correct for naturally occurring differences in brain sizes, we also calculated GM and WM fractions (GMF and WMF). This was calculated by dividing both GMV and WMV by total intracranial volume (e.g., $GMF = GMV / (GMV + WMV + CSF)$).

VBM – image preprocessing and statistical analyses. Preprocessing of structural images for VBM analyses was performed using the VBM toolbox (VBM 5.1; Structural Brain Mapping Group, University of Jena, Jena, Germany; Website: <http://dbm.neuro.uni-jena.de/vbm/>), which involved spatial normalization, segmentation, and spatial smoothing (Gaussian kernel of 8-mm full-width at half-maximum for GM images). Modulated images were used for statistical analyses; correspondingly, GM and WM values are referred to as regional GM or WM volume.

Modulated images were saved with correction for nonlinear warping only; i.e., volume changes due to affine normalization were not considered. This approach is recommended if the hypothesis is about differences in regional brain volume that are corrected for different brain sizes (Structural Brain Mapping Group, University of Jena; Website: <http://dbm.neuro.uni-jena.de/vbm/segmentation/modulation/>).

To avoid possible edge effects around the border between GM and WM and to include only relatively homogenous voxels, we excluded all voxels with a matter value < 0.1 (of a maximum value of 1). Statistical tests (ANCOVA, with age as covariate of no interest) to identify differences between groups were performed using the general linear model implemented in SPM5. In a second step, for explorative purposes, we performed correlation analyses between clinically relevant scores/laboratory data (SLEDAI, SLICC, antiphospholipid antibodies) and regional GM volume, to search for possible associations.

Statistical analysis and correction for multiple comparisons were performed as follows: statistical parametric maps (based on group comparisons and/or correlation analyses) were thresholded at $p < 0.001$ (uncorrected, voxel level). Clusters were deemed significant at a cluster extent of 800 contiguous voxels (whole-brain correction) as estimated by the AlphaSim application (implemented in the Analysis of Functional NeuroImages software; US National Institute for Mental Health, Bethesda, MD, USA; Website: <http://afni.nimh.nih.gov/afni/doc/manual/AlphaSim>), based on a Monte Carlo simulation (5000 simulations) applied to a whole-brain mask (including cortical, GM, WM, CSF, brainstem, and cerebellum). With respect to the changes in regional brain morphology described in the literature we allowed in a second step a less conservative cluster extent threshold of 200 contiguous voxels in the regions previously described. Anatomical labeling of brain regions showing significant differences between groups or associations with clinical variables was performed using the SPM5 extension xjVIEW (Functional Imaging Laboratories;

RESULTS

Clinical manifestations, disease severity, and serological data. Seventeen diffuse manifestations and 7 focal manifestations were present in the NPSLE group: psychosis 3, organic brain syndrome 9 (cognitive decline, confusion, etc.), headaches 4, transverse myelitis 1, cerebrovascular disease 5, and cranial nerve palsy 2. Nineteen out of 20 patients were acutely treated with intravenous and/or oral steroids. One patient was treated exclusively with selective serotonin reuptake inhibitors. Thirteen patients required the addition of immunosuppressive drugs as well (Table 2).

Disease duration was longer in the NPSLE group (mean 7.8 yrs, range 0.7–23, SD 6.7) compared to the SLE group (4.7 yrs, range 0.6–15, SD 5.1); however, this difference did not achieve significance ($p = 0.11$). Disease activity was sig-

nificantly higher in the NPSLE group, by SLEDAI score ($p < 0.001$). No differences were found in SLICC scores between groups (Table 1).

NPSLE patients had higher levels of anti- β_2 -GPI IgA ($p < 0.05$) than SLE patients. NPSLE patients also showed a trend to have higher levels of dsDNA antibodies (anti-dsDNA; $p < 0.06$). Other antiphospholipid antibodies (anti- β_2 -GPI IgG/IgM, anticardiolipin antibody, and LAC) did not differ significantly between the 2 patient groups (Table 3).

Conventional MRI findings. Mild or moderate diffuse brain atrophy was present in 26.8% of the patients (15/56). No patient had acute ischemia. One patient with SLE had a wedge-shaped area of encephalomalacia in the right frontal lobe and one patient with NPSLE had an old infarct in the right frontal lobe. A mild lesion burden, as defined above, was seen in 77.8% of the patients with SLE (14/18), a moderate burden in 16.7% (3/18), and a severe burden in 5.6%

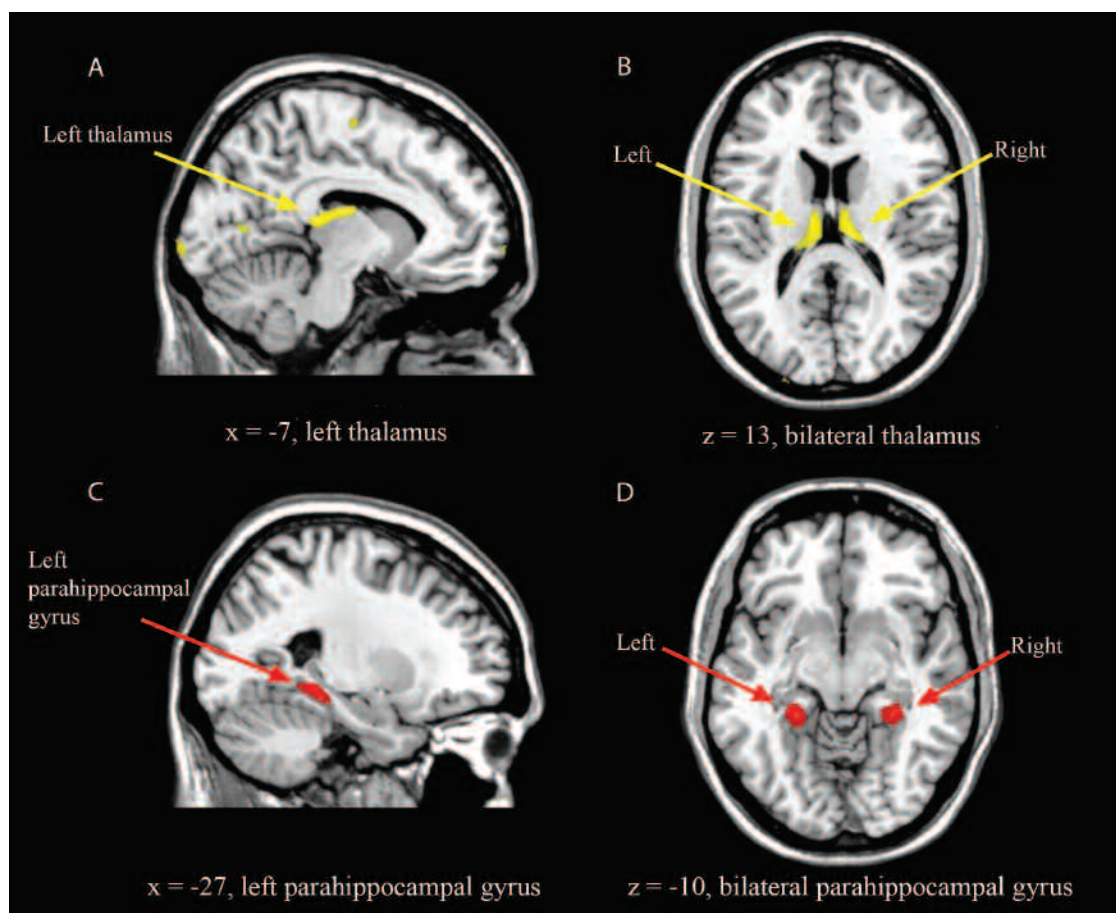


Figure 1. Differences in regional gray matter volume between patients with NPSLE and healthy controls. A and B: Decreases in regional gray matter volume in the posterior thalamus bilaterally (marked in yellow) in patients with NPSLE, compared to healthy controls (peak voxels: $x = 12, y = -24, z = 13, z \text{ value} = 4.37$; $x = -7, y = -20, z = 13, z \text{ value} = 3.97$). C and D: Increases in regional gray matter volume in the posterior parahippocampal gyrus bilaterally (marked in red) in patients with NPSLE, compared to healthy controls (peak voxels: $x = 29, y = -37, z = -9, z \text{ value} = 4.10$; $x = -25, y = -38, z = -7, z \text{ value} = 4.54$). B and D: The left side of the image is the left side of the brain. Clusters are superimposed on a normalized T1-weighted image as provided by MRIcron.

(1/18). One of the 20 patients with NPSLE had no lesions (5%); a mild lesion burden was seen in 60% of the NPSLE patients (12/20), a moderate burden in 25% (5/20), and a severe burden in 10% (2/20). In the control group, 6 participants (33.3%) had a mild lesion burden, 1 (5.6%) a moderate burden, and 1 (5.6%) a severe burden. In addition some incidental findings were noted: 7 venous angiomas, 3 pineal cysts, 2 arachnoid cysts, 1 small meningioma, and 1 aneurysm of the right carotid artery.

Global volumes. Comparing GMV, WMV, and the corresponding fractions (GMF and WMF, respectively) we found no significant differences across the 3 groups (Table 4).

Voxel-based morphometry. VBM analyses revealed several regions of GM atrophy in various parts of the brain in both SLE and NPSLE patients. SLE patients without neuropsychiatric symptoms showed GM atrophies in the right precentral gyrus, parietal lobe bilaterally, and the posterior thalamus bilaterally. Additionally, the SLE patients showed an increase in regional GMV in the left posterior parahippocampal gyrus.

NPSLE patients showed GM atrophies in the right inferior frontal gyrus, right parietal lobe, left occipital lobe, and the posterior thalamus. An increase in regional GMV in patients with NPSLE was noted in the posterior parahippocampal gyrus bilaterally and the left cerebellum (Table 3, Figure 1). On visual inspection of the statistical maps the thalamic atrophy and the increase in GMV in the parahippocampal gyri were more pronounced in the patients with NPSLE; however, the difference between the 2 patient groups was not significant (Table 5, Figure 1).

DISCUSSION

Using high-resolution structural images and VBM, we investigated changes in global and regional GM volume in SLE patients with and without neuropsychiatric manifestations and in healthy controls. There were no statistically significant differences in global GMV or WMV between the 3 groups. Regional GM atrophy was found in SLE and NPSLE, most prominently in the thalamus bilaterally and also in the precentral gyrus, the parietal lobe/precuneus, and the occipital lobe. Further, we found an increase in regional GMV in the posterior part of the parahippocampal gyrus on the left side in SLE patients and bilaterally in NPSLE patients (at the threshold determined *a priori*). Using the sta-

tistical approach/threshold described above, we found no significant differences between the NPSLE and SLE patients, although the changes in the thalamus and parahippocampal gyrus were more pronounced in NPSLE patients.

With respect to the patients with NPSLE, our data are in agreement with other studies using automated analysis techniques in as much as they also found a decrease in regional GMV in various cortical and subcortical structures, including the thalamus^{13,14}. However, atrophy, especially cortical atrophy, was not as pronounced as it was in other studies that examined NPSLE patients with a longer history of disease. In our study the thalamus was the brain structure that showed the most prominent atrophy. The thalamus has been implicated in various confusional states/organic brain syndromes^{29,30}, including postoperative delirium³¹ and Korsakoff syndrome³². Against this background it is tempting to hypothesize that the changes in thalamus, having reached a certain degree, contribute to confusion and/or behavioral abnormalities in patients with NPSLE. Interestingly, some studies demonstrated abnormal regional blood flow¹⁹ and disturbed tissue integrity³³ in the thalamus of patients with NPSLE. As outlined above, SLE-associated brain lesions can be based on different underlying mechanisms, such as vascular occlusion resulting from vascular inflammation, thrombosis, and/or atherosclerotic changes, as well as a “bland vasculopathy” that has been reported in autopsy studies^{10,34,35,36}. It is conceivable that a diffuse neuronal loss in the cerebral cortex, as well as WM lesions, could lead to axonal degeneration and to a secondary (remote) atrophy in the thalamus. However, possibly a more localized pathophysiologic mechanism needs to be considered. The thalamus makes up the floor of the lateral ventricles and is partly covered by the choroid plexus, which in turn has frequently been described to be a specific target of SLE-associated inflammation^{36,37}. In this context one can speculate whether a continuing autoimmune process in the choroid plexus and/or cytotoxicity of the CSF could promote atrophy of the underlying thalamic tissue.

Further, we found an increase in regional GMV in the posterior part of the parahippocampal gyrus (extending into the fusiform gyrus and hippocampus) in both patient groups, which was more pronounced in the NPSLE group. Although the hallmark of cerebral alterations in SLE is brain atrophy and neuronal degeneration^{11,23}, as well as impaired neurogenesis/neuronal migration¹², populations of proliferative

Table 4. Global gray and white matter volumes/fractions. Data are mean/SD.

	Controls	SLE Patients	NPSLE Patients	p
Gray matter volume, cm ³	655.7/39.3	637.0/53.7	648.2/61.1	0.57
Gray matter fraction	0.44/0.027	0.43/0.045	0.43/0.042	0.53
White matter volume, cm ³	447.3/38.7	426.5/55.8	439.8/51.2	0.44
White matter fraction	0.29/0.03	0.28/0.03	0.29/0.03	0.51

NPSLE: neuropsychiatric systemic lupus erythematosus; SLE: systemic lupus erythematosus.

Table 5. Differences in regional gray matter volume — voxel-based morphometry.

Region	Cluster Size, no. Voxels	z Score, Peak Voxels	MNI Coordinates		
			x	y	z
Control > SLE					
L thalamus	1365	4.19	-13	-31	12
R thalamus	582	3.84	13	-25	14
R precentral gyrus	696	3.99	43	-14	52
R parietal lobe/precuneus	673	3.62	6	-66	38
L parietal lobe/precuneus	673	3.32	-3	-66	42
Control < SLE					
L parahippocampal gyrus	743	4.08	-28	-34	-12
Control > NPSLE					
L thalamus	1133	3.93	-12	-31	12
R thalamus	821	4.12	12	-25	13
R parietal lobe	351	4.36	23	-75	38
L occipital lobe	576	3.64	-12	-104	-4
R inferior frontal gyrus	168	4.09	50	32	-3
Control < NPSLE					
L parahippocampal gyrus	1646	4.42	-26	-37	-8
R parahippocampal gyrus	1265	4.06	29	-37	-9
Cerebellum, vermis	217	3.53	-2	-59	-37
L cerebellum, posterior lobe	1965	4.04	-29	-70	-55

MNI: Montreal Neurological Institute; NPSLE: neuropsychiatric systemic lupus erythematosus; SLE: systemic lupus erythematosus.

brain cells in the subgranular zone of the dentate gyrus have been described in SLE animal models¹². It is tempting to hypothesize that the local increases in GMV reflect a repair mechanism.

One important difference compared with other studies is that our study included only patients with acute neuropsychiatric manifestations, while other studies have evaluated patients with a combination of present and past CNS manifestations. Given that brain atrophy is an ongoing process in NPSLE, it is conceivable that the degree of brain atrophy at this early stage is still relatively mild, explaining why it does not differ significantly from that seen in the patients with SLE.

Our data indicate that GM atrophy in the thalamus as well as an increase in regional parahippocampal volume (at least unilaterally) were also present in SLE patients (without neuropsychiatric manifestations), which to our knowledge has not been reported before, although nonspecific MRI abnormalities are known to be present in a high percentage of SLE patients without neuropsychiatric symptoms⁶. Our findings are in accord with a recent study by Xu, *et al*¹⁵ reporting decreases in WMV in SLE patients without neuropsychiatric manifestations, suggesting that subclinical brain tissue damage is also (or already) present in at least some members of this group of patients.

Our study, like most reports of imaging in neuropsychiatric lupus, is limited because it did not specifically address the role of covariates such as the degree of pain, depression, and drug intake in study patients. Studies using VBM have reported changes similar to those noted in our study (especially the thalamus) in chronic pain states, depression, and

other psychiatric disorders^{38,39}. Both pain and psychiatric comorbidities are seen commonly in NPSLE and in SLE without neuropsychiatric manifestations. Unfortunately, at the time our study was begun these effects of pain and psychiatric disorders on brain morphometry were not known, and thus we did not collect data on the duration or intensity of pain, or perform structured clinical interviews to assess lifetime or present history of a psychiatric disorder. These factors deserve examination in future studies of structural or functional brain imaging in SLE.

Another potential limitation of our study is the lack of data on the cumulative dose of steroids in the 2 patient groups. In other neuroinflammatory diseases, such as multiple sclerosis, it has been reported that disease-modifying drugs have differential effects on brain volume⁴⁰; for SLE there is indirect evidence that immunosuppressive therapy might have a protective effect on WMV¹⁵. However, this requires investigation within longitudinal studies. The majority of patients in our study (in both patient groups) had no history of severe disease prior to the study, which leads us to infer that the cumulative steroid dose prior to the time of presentation was low in the 2 patient groups. Prior to the MRI evaluation, the prednisone dose in both patient groups was < 7.5 mg/day. The NPSLE group received high steroid doses and/or cyclophosphamide after or a short period (1–2 days) before the MRI scans were performed, making it unlikely that either drug accounts for the findings observed in our study.

Finally, we studied patients with a definite diagnosis of lupus who presented symptoms that, after detailed evaluation by both the clinical team and a faculty rheumatologist-

investigator, were attributed to (and treated as) SLE rather than to any other condition such as thromboembolism, atherosclerosis, metabolic diseases, etc. Unfortunately, not all patients had a CSF analysis, which represents a weakness of our study.

Our data suggest that changes in regional brain morphology are present in patients with SLE, both those without neuropsychiatric symptoms and those with recent onset of a first episode of NPSLE. The presence of areas of both decreased and increased volume suggests that there may be areas of both neurodegeneration and (disturbed) regeneration. That the group of patients with SLE resembled the group of NPSLE patients more than the controls indicates that, with respect to regional brain morphology, SLE and NPSLE patients have the same "brain signature," suggesting that a subset of patients without clinical NPSLE may have early morphologic changes similar to those seen in NPSLE. Although clinical assessment is the cornerstone of SLE diagnosis, confirmation of the diagnosis is difficult and frequently presumptive. Given the robustness and specificity of GM changes, especially in the thalamus, it is conceivable that GM changes are suited for more advanced brain imaging techniques, i.e., machine learning and pattern recognition analysis, which could even be combined with other imaging modalities, such as diffusion tensor imaging, perfusion, etc. These approaches could further enhance our ability to detect and possibly treat NPSLE at an earlier and potentially more reversible stage.

REFERENCES

1. Brey RL, Holliday SL, Saklad AR, Navarrete MG, Hermsillo-Romo D, Stallworth CL, et al. Neuropsychiatric syndromes in lupus: Prevalence using standardized definitions. *Neurology* 2002;58:1214-20.
2. Monastero R, Bettini P, Del Zotto E, Cottini E, Tincani A, Balestrieri G, et al. Prevalence and pattern of cognitive impairment in systemic lupus erythematosus patients with and without overt neuropsychiatric manifestations. *J Neurol Sci* 2001;184:33-9.
3. Sibley JT, Olszynski WP, Decoteau WE, Sundaram MB. The incidence and prognosis of central nervous system disease in systemic lupus erythematosus. *J Rheumatol* 1992;19:47-52.
4. Gladman D, Ginzler E, Goldsmith C, Fortin P, Liang M, Urowitz M, et al. The development and initial validation of the Systemic Lupus International Collaborating Clinics/American College of Rheumatology damage index for systemic lupus erythematosus. *Arthritis Rheum* 1996;39:363-9.
5. Appenzeller S, Pike GB, Clarke AE. Magnetic resonance imaging in the evaluation of central nervous system manifestations in systemic lupus erythematosus. *Clin Rev Allergy Immunol* 2008;34:361-6.
6. Cotton F, Bouffard-Vercelli J, Hermier M, Tebib J, Vital Durand D, Tran Minh VA, et al. MRI of central nervous system in a series of 58 systemic lupus erythematosus (SLE) patients with or without overt neuropsychiatric manifestations. *Rev Med Interne* 2004; 25:8-15.
7. Petri M, Naqibuddin M, Carson KA, Wallace DJ, Weisman MH, Holliday SL, et al. Brain magnetic resonance imaging in newly diagnosed systemic lupus erythematosus. *J Rheumatol* 2008;35:2348-54.
8. Jennings JE, Sundgren PC, Attwood J, McCune J, Maly P. Value of MRI of the brain in patients with systemic lupus erythematosus and neurologic disturbance. *Neuroradiology* 2004;46:15-21.
9. Sibbitt WL Jr, Brooks WM, Kornfeld M, Hart BL, Bankhurst AD, Roldan CA. Magnetic resonance imaging and brain histopathology in neuropsychiatric systemic lupus erythematosus. *Semin Arthritis Rheum* 2010;40:32-52.
10. Fragoso-Loyo H, Richaud-Patin Y, Orozco-Narvaez A, Davila-Maldonado L, Atisha-Fregoso Y, Llorente L, et al. Interleukin-6 and chemokines in the neuropsychiatric manifestations of systemic lupus erythematosus. *Arthritis Rheum* 2007;56:1242-50.
11. Ballok DA, Woulfe J, Sur M, Cyr M, Sakic B. Hippocampal damage in mouse and human forms of systemic autoimmune disease. *Hippocampus* 2004;14:649-61.
12. Stanojic M, Burstyn-Cohen T, Nashi N, Lemke G, Sakic B. Disturbed distribution of proliferative brain cells during lupus-like disease. *Brain Behav Immun* 2009;23:1003-13.
13. Appenzeller S, Bonilha L, Rio PA, Min Li L, Costallat LT, Cendes F. Longitudinal analysis of gray and white matter loss in patients with systemic lupus erythematosus. *Neuroimage* 2007;34:694-701.
14. Jung RE, Segall JM, Grazioplene RG, Qualls C, Sibbitt WL, Roldan CA. Cortical thickness and subcortical gray matter reductions in neuropsychiatric systemic lupus erythematosus. *PLoS One* 2010;5:e9302.
15. Xu J, Cheng Y, Chai P, Lu Z, Li H, Luo C, et al. White-matter volume reduction and the protective effect of immunosuppressive therapy in systemic lupus erythematosus patients with normal appearance by conventional magnetic resonance imaging. *J Rheumatol* 2010;37:974-86.
16. Sundgren PC, Jennings J, Attwood JT, Nan B, Gebarski S, McCune WJ, et al. MRI and 2D-CSI MR spectroscopy of the brain in the evaluation of patients with acute onset of neuropsychiatric systemic lupus erythematosus. *Neuroradiology* 2005;47:576-85.
17. Appenzeller S, Li LM, Costallat LT, Cendes F. Neurometabolic changes in normal white matter may predict appearance of hyperintense lesions in systemic lupus erythematosus. *Lupus* 2007;16:963-71.
18. Shen YY, Kao CH, Ho YJ, Lee JK. Regional cerebral blood flow in patients with systemic lupus erythematosus. *J Neuroimaging* 1999;9:160-4.
19. Oda K, Matsushima E, Okubo Y, Ohta K, Murata Y, Koike R, et al. Abnormal regional cerebral blood flow in systemic lupus erythematosus patients with psychiatric symptoms. *J Clin Psychiatry* 2005;66:907-13.
20. Otte A, Weiner SM, Peter HH, Mueller-Brand J, Goetze M, Moser E, et al. Brain glucose utilization in systemic lupus erythematosus with neuropsychiatric symptoms: A controlled positron emission tomography study. *Eur J Nucl Med* 1997;24:787-91.
21. Muscal E, Traipe E, de Guzman MM, Myones BL, Brey RL, Hunter JV. Cerebral and cerebellar volume loss in children and adolescents with systemic lupus erythematosus: A review of clinically acquired brain magnetic resonance imaging. *J Rheumatol* 2010;37:1768-75.
22. Appenzeller S, Carnevalle AD, Li LM, Costallat LT, Cendes F. Hippocampal atrophy in systemic lupus erythematosus. *Ann Rheum Dis* 2006;65:1585-9.
23. Appenzeller S, Rondina JM, Li LM, Costallat LT, Cendes F. Cerebral and corpus callosum atrophy in systemic lupus erythematosus. *Arthritis Rheum* 2005;52:2783-9.
24. Ashburner J, Friston KJ. Unified segmentation. *Neuroimage* 2005;26:839-51.
25. The American College of Rheumatology nomenclature and case definitions for neuropsychiatric lupus syndromes. *Arthritis Rheum* 1999;42:599-608.

26. Tan EM, Cohen AS, Fries JF, Masi AT, McShane DJ, Rothfield NF, et al. The 1982 revised criteria for the classification of systemic lupus erythematosus. *Arthritis Rheum* 1982;25:1271-7.
27. Folstein MF, Folstein SE, McHugh PR. "Mini-mental state". A practical method for grading the cognitive state of patients for the clinician. *J Psychiatr Res* 1975;12:189-98.
28. Bombardier C, Gladman DD, Urowitz MB, Caron D, Chang CH. Derivation of the SLEDAI. A disease activity index for lupus patients. The Committee on Prognosis Studies in SLE. *Arthritis Rheum* 1992;35:630-40.
29. Predescu A, Damsa C, Riegiert M, Bumb A, Pull C. Persistent psychotic disorder following bilateral mesencephalo-thalamic ischaemia: case report [in French]. *Encephale* 2004;30:404-7.
30. Mittal M, Khan S. Starvation causes acute psychosis due to anterior thalamic infarction. *South Med J* 2010;103:701-3.
31. Shioiri A, Kurumaji A, Takeuchi T, Matsuda H, Arai H, Nishikawa T. White matter abnormalities as a risk factor for postoperative delirium revealed by diffusion tensor imaging. *Am J Geriatr Psychiatry* 2010;18:743-53.
32. Reed LJ, Lasserson D, Marsden P, Stanhope N, Stevens T, Bello F, et al. FDG-PET findings in the Wernicke-Korsakoff syndrome. *Cortex* 2003;39:1027-45.
33. Hughes M, Sundgren PC, Fan X, Foerster B, Nan B, Welsh RC, et al. Diffusion tensor imaging in patients with acute onset of neuropsychiatric systemic lupus erythematosus: A prospective study of apparent diffusion coefficient, fractional anisotropy values, and eigenvalues in different regions of the brain. *Acta Radiol* 2007;48:213-22.
34. Santer DM, Yoshio T, Minota S, Moller T, Elkon KB. Potent induction of IFN-alpha and chemokines by autoantibodies in the cerebrospinal fluid of patients with neuropsychiatric lupus. *J Immunol* 2009;182:1192-201.
35. Okamoto H, Katsumata Y, Nishimura K, Kamatani N. Interferon-inducible protein 10/CXCL10 is increased in the cerebrospinal fluid of patients with central nervous system lupus. *Arthritis Rheum* 2004;50:3731-2.
36. Duprez T, Nzeusseu A, Peeters A, Houssiau FA. Selective involvement of the choroid plexus on cerebral magnetic resonance images: A new radiological sign in patients with systemic lupus erythematosus with neurological symptoms. *J Rheumatol* 2001;28:387-91.
37. Amaro E Jr, Scheinberg M. Onset of cognitive dysfunction in systemic lupus erythematosus and selective involvement of the choroid plexus. *J Rheumatol* 2009;36:2554-5.
38. Schmidt-Wilcke T, Luerding R, Weigand T, Jurgens T, Schuierer G, Leinisch E, et al. Striatal grey matter increase in patients suffering from fibromyalgia — A voxel-based morphometry study. *Pain* 2007;132 Suppl 1:S109-16.
39. Soriano-Mas C, Hernandez-Ribas R, Pujol J, Urretavizcaya M, Deus J, Harrison BJ, et al. Cross-sectional and longitudinal assessment of structural brain alterations in melancholic depression. *Biol Psychiatry* 2011;69:318-25.
40. Zivadinov R, Reder AT, Filippi M, Minagar A, Stuve O, Lassmann H, et al. Mechanisms of action of disease-modifying agents and brain volume changes in multiple sclerosis. *Neurology* 2008;71:136-44.