

# Consider the Tidemark



As the most conspicuous histologic feature of normal adult articular cartilage, the tidemark begs for our understanding. In their original description, Fawns and Landells likened this landmark to the irregular line of debris that is left on a sandy beach by the high point of a now-receding tide<sup>1</sup> (Figure 1A). Such tidemarks comprise a mixture of marine flotsam, and so contain a variety of stuff from the sea. If the tidemark of cartilage is aptly named, as I believe it to be, it too should be a passive deposit of debris, but what are its constituents and where do they come from?

I have argued elsewhere that apoptotic chondrocytes provide the probable source<sup>2,3</sup>. According to this concept, the cells of adult cartilage turn over on a regular but as yet unknown schedule. They are continually replaced from the articular margins by in-migration of primitive chondrocytes that differentiate as they ascend and course through the superficial zone along the existing, collagenous scaffold. These cells then mature and move down into the matrix, which they remodel as they go<sup>4</sup>.

Upon their death, they disintegrate into a shower of apoptotic bodies that are driven deeper by the episodic loading of normal joint usage. Ultimately, this path is arrested by the underlying, calcified cartilage that serves as a semipermeable membrane, retaining larger, stainable molecules as a tidemark, while it allows water and smaller solutes to pass on into the subchondral bone<sup>5,6</sup>.

We know relatively little about these retained materials. A wide range of histologic stains recognize the tidemark and this promiscuity suggests a corresponding variety of as-yet unidentified molecules (Figure 1, B-F). Older studies provide a partial list including phospholipids, alkaline phosphatase, and adenosine triphosphatase<sup>7,8,9,10</sup>, while more recent work implicates DNA (by diamidino phenylindole staining, Figure 1G)<sup>2</sup>, 4 different lectins<sup>10</sup>, and high mobility group box chromosomal protein 1 (HMGB1)<sup>11,12</sup>. Smaller solutes, which may represent deposition in the calcification front, include lead, zinc, and tetracycline<sup>13,14</sup>. To my knowledge, plasma proteins have not been sought, but most of these molecules are anions and so will be excluded from normal hyaline cartilage, as immunoglobulins and albumin are known to be<sup>15</sup>.

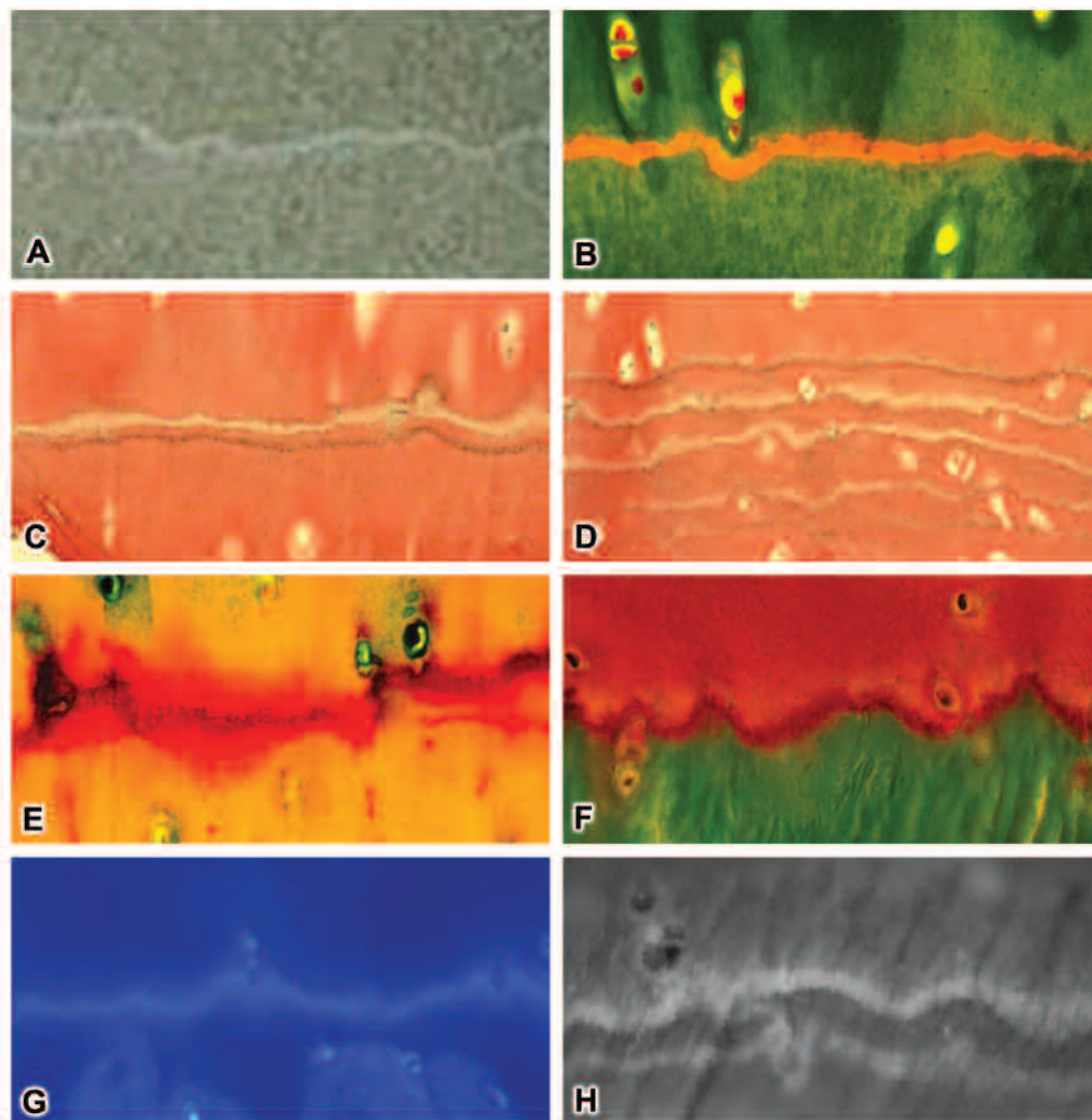
More precise characterization has been inhibited by difficulty in sectioning the adjacent, calcified tissue; by limita-

tions in access to this deep, thin, and irregular layer; and by its striking autofluorescence, which implies deposition of fluorescent materials, but complicates interpretation of immunofluorescence-based methods of molecular recognition (Figure 1H). Despite these limitations, sufficient evidence implies that there is a lot of different stuff in the tidemark and that much of it is the stuff of chondrocytes rather than synovial fluid or the matrix of hyaline cartilage.

Among existing concepts of the tidemark, one of the most persistent holds it to be the scar of the original, subchondral growth plate. This fits well with the fact that the tidemark initially develops when and where the growth plate ceases its work. Tidemarks are not seen in children but develop in all adults after puberty. Subsequently, however, the tidemark may not stay at its initial site. As loading mechanics change and osteoarthritic joints age, new tidemarks often appear (Figure 1D). These new layers resemble the original in all respects, but only one can mark the site of the “one and done” growth plate. Instead, reduplication must reflect an ongoing process.

The tidemark has also been defined by its location at the junction between pliant hyaline cartilage and more rigid, calcified tissue. The mechanics of this unique interface are fascinating and may well be relevant in the pathogenesis of osteoarthritis, but they do not constitute a “mark.” That aspect is revealed by its staining properties. If the stained materials do not come from chondrocytes, what else could be their source and why would they wind up in cartilage? If the deposits do not reflect a decrement in permeability, what else could explain their layered accumulation? When we can characterize these substrates better and understand the basis of their deposition, that knowledge may help us better to understand the physiology of cartilage and the pathophysiology of the diseases that affect it.

Ultimately, the tidemark may be of most interest to rheumatologists in terms of its relevance to rheumatic disease. There, it appears to form a major, and perhaps the major, site of periarticular erosions by rheumatoid pannus<sup>16,17,18</sup>. In one report, such invasions were called the “snakeskin” phenomenon in view of their tendency to undermine a “skin” of relatively normal hyaline cartilage<sup>19</sup>. As it is envisioned here, the tidemark is unique as a normal, extracellular deposit of intracellular proteins (whose anti-



**Figure 1.** A. A tidemark on the beach at Manzanita, Oregon, USA. B. Mallory aniline blue stain of the tidemark in a normal human metacarpal phalangeal (MCP) joint. Note that cell nuclei and the tidemark share orange staining not seen in the matrix. This image, as well as those that follow, was from an older subject without known rheumatic disease whose body was donated for anatomic study through the will body program at the University of Washington. C and D. Von Gieson stains of first phalanx base and metacarpal head from 1 MCP joint. The trilaminar structure seen here was stressed by Lyons, *et al*<sup>10</sup>. Its basis remains unexplained. The tidemark duplication seen in the metacarpal head is generally considered to be evidence of osteoarthritis. E. Mowat stain. Granularity of the tidemark (? apoptotic bodies) was described in the classic report of Fawns and Landells<sup>1</sup>. F. Masson trichrome stain. Again note that, as in all sections, cell nuclei and the tidemark share comparable staining. G. Diamidino phenylindole (DAPI) stain<sup>2</sup>. DAPI is considered to be specific for the AT groove of DNA. H. Unstained section examined with ultraviolet microscopy showing autofluorescence of the tidemark (clear middle band seen here and in C is thought to be phospholipid).

genicity may have been amplified by citrullination as part of the apoptotic process) and they are accompanied by proinflammatory HMGB1 and DNA. If these proteins are then recognized by the host immune system, a progressive process of immune-mediated articular damage and destruction becomes a logical consequence. Normal deposits of intracellular antigens occur at no other site, and their pres-

ence in the tidemark may explain why this systemic disease selectively destroys human joints.

Tidemarks are not a specific feature of rheumatoid arthritis (RA) but are present in the synovial joints of every normal adult as well as those who have osteoarthritis. In other normal tissues, the recognition and removal of apoptotic materials is a complex process involving “find-me” and

“eat-me” signals as well as factors to inhibit an untoward response by the innate immune system<sup>20</sup>. Immunoglobulins need not be involved. This editorial does not presume to define just what might go wrong with this balance in patients with RA. Instead, it appeals for the students of such signals to consider the tidemark as a possibly fruitful field for their investigations.

The concept of an immune disease driven by apoptosis-derived antigens is not new. It has been explored extensively in the context of systemic lupus erythematosus (SLE)<sup>21,22</sup>. In fact, the present perspective of the tidemark as a potential target for autoimmune responses could ultimately contribute to better understanding of the articular manifestations not only of RA but also of SLE as well as other immune-mediated rheumatic diseases. This possibility, of course, remains a working hypothesis that may not withstand further scrutiny but, if for no other reason than its histologic prominence, the tidemark begs for our understanding.

**PETER A. SIMKIN, MD,**  
Division of Rheumatology,  
Department of Medicine,  
University of Washington,  
Seattle, Washington, USA

Address correspondence to Dr. P.A. Simkin, Division of Rheumatology, Box 356428, Department of Medicine, University of Washington, Seattle, Washington 98195, USA. E-mail: psimkin@uw.edu

## ACKNOWLEDGMENT

Kirkwood A. Johnston, MD, and Nguyet-Anh Tran, MD, assisted in obtaining the photographs, and Kimberly Cho assembled the figure.

## REFERENCES

1. Fawns HT, Landells JW. Histochemical studies of rheumatic conditions I. Observations on the fine structures of the matrix of normal bone and cartilage. *Ann Rheum Dis* 1953;12:105-13.
2. Simkin PA. A biography of the chondrocyte. *Ann Rheum Dis* 2008;67:1064-8.
3. Simkin PA. Rethinking the physiology of articular cartilage. *J Clin Rheum* 2009;15:260-3.
4. Castillo ECG, Kouri JB. A new role for chondrocytes as non-professional phagocytes. An in vitro study. *Microsc Res Tech* 2004;64:269-78.
5. Simkin PA, Peterson JR. The cartilage/bone interface is permeable to saline under physiologic articular pressures [abstract]. *Arthritis Rheum* 2001;44 Suppl:S48.
6. Arkkill KP, Winlove CP. Solute transport in the deep and calcified zones of cartilage. *Osteoarthritis Cartilage* 2008;16:708-14.
7. Dmitrovsky E, Land LB, Bullough PG. The characterization of the tidemark in human articular cartilage. *Metab Bone Dis Rel Res* 1978;1:115-8.
8. Havelka S, Horn V, Spohrova D, Valough P. The calcified-noncalcified cartilage interface: The tidemark. *Acta Biologica Hungarica* 1984;35:271-9.
9. Oettmeir R, Abendroth K, Oettmeir S. Analysis of the tidemark on human femoral heads. I. Histochemical, ultrastructural and microanalytic characterization of the normal structure of the intercartilagenous junction. *Acta Morph Hung* 1989;37:155-68.
10. Lyons TJ, Stoddart RW, McClure SF, McClure JM. The tidemark of the chondro-osseous junction of the normal human knee joint. *J Mol Hist* 2005;36:207-15.
11. Ley C, Ekman S, Ronéus B, Eloranta ML. Interleukin-6 and high mobility group box protein-1 in synovial membranes and osteochondral fragments in equine osteoarthritis. *Res Vet Sci* 2009;86:490-7.
12. Heinola T, Kouri VP, Clarijs P, Ciferska H, Sukura A, Salo J, et al. High mobility group box-1 (HMGB-1) in osteoarthritic cartilage. *Clin Exp Rheumatol* 2010;28:511-8.
13. Zoeger N, Roschger P, Hofstaetter JG, Jokubonis C, Pepponi G, Falkenberg G, et al. Lead accumulation in tidemark of articular cartilage. *Osteoarthritis Cartilage* 2006;14:906-13.
14. Revell PA, Pirie C, Amir G, Rashad S, Walker F. Metabolic activity in the calcified zone of cartilage: Observations on tetracycline labeled articular cartilage in human osteoarthritic hips. *Rheumatol Int* 1990;10:143-7.
15. Zatarain-Rios E, Mannik M. Charge-charge interactions between articular cartilage and cationic antibodies, antigens, and immune complexes. *Arthritis Rheum* 1987;30:1265-73.
16. Hough AJ, Sokoloff L. Pathology. In: Utsinger P, Zvaifler N, Ehrlich G, editors. *Rheumatoid arthritis*. Philadelphia: JB Lippincott Company; 1985:49-69.
17. Leisen JC, Duncan H, Riddle JM, Pitchford WC. The erosive front: A topographic study of the junction between the pannus and the subchondral plate in the macerated rheumatoid metacarpal head. *J Rheumatol* 1988;15:17-22.
18. Fassbender HG, Seibel M, Hebert T. Pathways of destruction in metacarpal and metatarsal joints of patients with rheumatoid arthritis. *Scand J Rheumatol* 1992;21:10-6.
19. Barrie HJ. Histologic changes in rheumatoid disease of the metacarpal and metatarsal heads as seen in surgical material. *J Rheumatol* 1981;8:246-57.
20. Li W. Eat-me signals: Keys to molecular phagocyte biology and “appetite” control. *J Cell Physiol* 2011 Apr 25 [E-pub ahead of print]
21. Suber T, Rosen A. Apoptosis cell blebs: Repositories of autoantigens and contributors to immune context. *Arthritis Rheum* 2009;60:2216-9.
22. Peng Y, Elkon KB. Autoimmunity in MFG-E8-deficient mice is associated with altered trafficking and enhanced cross-presentation of apoptotic cell antigens. *J Clin Invest* 2011;121:2221-41.

*J Rheumatol* 2012;39:890–2; doi:10.3899/jrheum.110942