

## Pulmonary Toxicity After Initiation of Azathioprine for Treatment of Interstitial Pneumonia in a Patient with Rheumatoid Arthritis

To the Editor:

Pulmonary involvement of rheumatoid arthritis (RA) includes drug-induced pulmonary toxicity, interstitial pneumonia (IP) due to RA itself, airway lesions, pleural lesions, and pulmonary infections due to the use of immunosuppressants. It is sometimes difficult to differentiate between these conditions. Pulmonary toxicity has been reported to be often induced by methotrexate and leflunomide but rarely by azathioprine (AZA). We describe a patient with RA and IP, in whom AZA induced pulmonary toxicity.

The patient was a 72-year-old man diagnosed with RA (Steinbrocker stage III, class 2), treated with 5 mg/day prednisolone (PSL) and with clinically low disease activity. He developed a nonproductive cough 2 years ago. Chest radiograph and high-resolution computed tomography (HRCT) of the chest at that time revealed ground-glass opacities (GGO) in the bilateral peripheral lung fields and honeycomb-like cysts in the dorsal side of both lower lung fields, leading to a diagnosis of IP. Pulmonary function tests showed a vital capacity (VC) of 99.3%, and DLCO 54.2%.

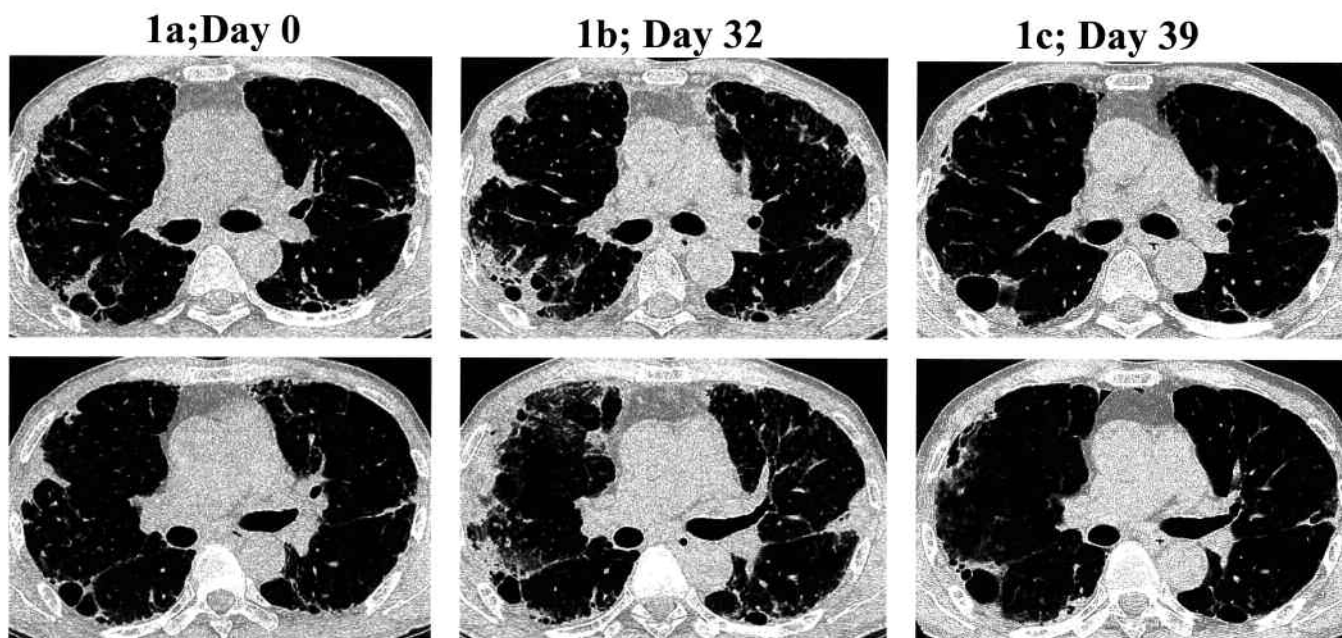
After he developed exertional dyspnea (Hugh-Jones Grade II) in March 2006, he was referred to our hospital and was admitted on June 20, 2006. Fine crackles were audible in both lower lung fields. Blood tests showed a white blood cell (WBC) count 10,940/ $\mu$ l (73% neutrophils), C-reactive protein (CRP) 2.08 mg/dl, erythrocyte sedimentation rate 59 mm/h, and a Krebs von den Lungen-6 level of 335 U/ml. SpO<sub>2</sub> (room air) was 96%. Chest radiograph and HRCT of the chest revealed that the extent of GGO in the bilateral peripheral lung fields and honeycomb-like cysts on the dorsal side of both lower lung fields had increased (Figure 1a). Pulmonary function tests showed vital capacity 80.3% and DLCO 41.4%. He had active RA, indicated by a CRP-based 28-joint Disease Activity Score of 3.15, and worsening IP.

He was treated with an increased dose (20 mg/day) of PSL in addition to 100 mg/day AZA on the 25th hospital day. Six days after starting AZA,

he developed a fever of 39°C and dyspnea. Laboratory findings showed SpO<sub>2</sub> of 94%, WBC count 23,870/ $\mu$ l, and CRP 23.87 mg/dl. Chest HRCT showed consolidation surrounding the GGO in the subpleural regions of the left upper and right upper and middle lobes (Figure 1b). We initiated therapy of 1.0 g/day meropenem hydrate, 400 mg/day clarithromycin, and 300 mg/day voriconazole, and discontinued the AZA. This treatment resulted in normal WBC and CRP level, and rapid improvement of SpO<sub>2</sub> (96%) and the infiltrative shadows on chest HRCT (Figure 1c). Tests were negative for  $\beta$ -D-glucan, aspergillus antigen, cryptococcus antigen, and leukocyte cytomegalovirus pp65 antigen. Sputum cultures were negative for pathogenic bacteria. He was treated again with 50 mg/day AZA from the 43rd hospital day and redeveloped a fever of 37.8°C with dyspnea. SpO<sub>2</sub> was 94% on room air, WBC count was 21,250/ $\mu$ l (94.5% neutrophils), and CRP 16.92 mg/dl. Chest HRCT showed consolidations and GGO in the subpleural regions of the left upper and right upper and middle lobes (Figure 2a). Discontinuation of AZA resulted in improvement of clinical symptoms and findings on HRCT (Figure 2b). During the course, 20 mg/day PSL was continuously administered. Thereafter, cyclosporine 175 mg/day was initiated, with improvement of the IP.

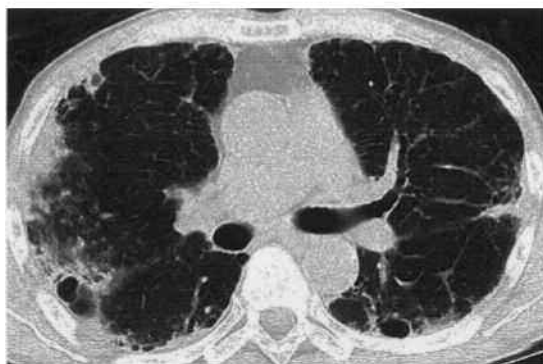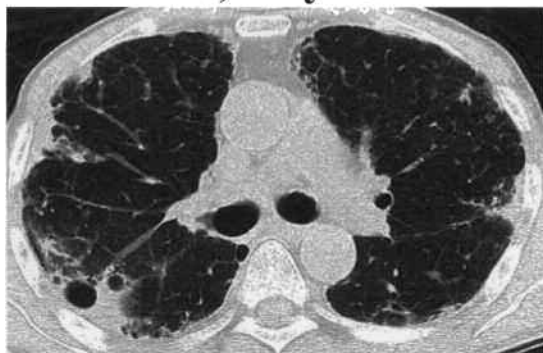Adverse events associated with AZA include fever, joint pain, bone marrow suppression, hepatitis, and infection but rarely pulmonary toxicity<sup>1</sup>. AZA-induced pulmonary toxicities have been reported in patients with kidney transplantation<sup>2,3,4,5</sup>, inflammatory bowel disease<sup>1,6,7,8</sup>, membranous nephropathy<sup>9</sup>, and autoimmune hepatitis<sup>10</sup>. To our knowledge, no previous studies have reported AZA-induced pulmonary toxicity in the field of connective tissue diseases.

Pulmonary lesions such as IP concomitantly develop in a high proportion of patients with collagen disease including RA, and it is important to differentiate these lesions from drug-induced IP. In particular, in our patient, it was difficult to differentiate AZA-induced IP from the acute exacerbation of RA-IP. In patients with the acute exacerbation of RA-IP, a GGO involving the entire lungs is detected on chest CT, showing rapid enlargement. However, in our case, a localized consolidation and GGO involving the right superior lung were observed, differing from the imaging characteristics of acutely exacerbating RA-IP. Further, incidental, addi-

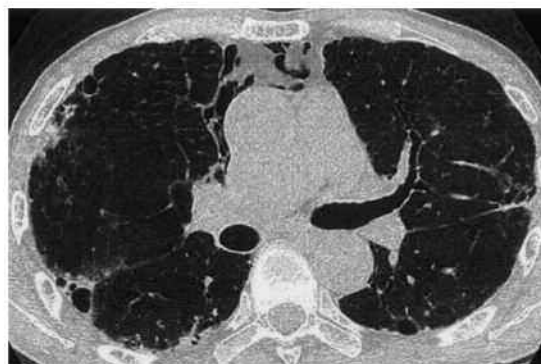
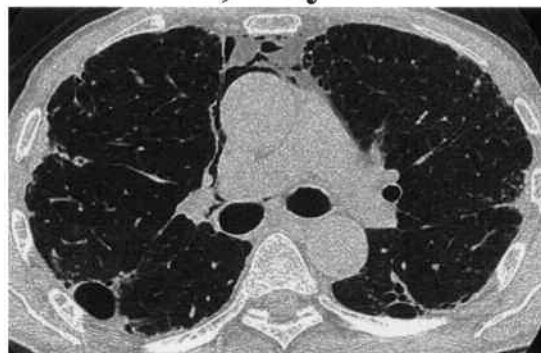
**Figure 1.** Time course of changes in chest HRCT findings. Chest HRCT on admission revealed an infiltrative shadow and ground-glass opacities in bilateral peripheral lung fields and honeycomb-like cysts on the dorsal side of both lower lung fields (1a). Chest HRCT 6 days after starting azathioprine (AZA) showed an infiltrative shadow and surrounding ground-glass opacities in subpleural regions of the left upper and right upper and middle lobes (1b). After discontinuation of AZA, pulmonary infiltrative shadow and ground-glass opacities disappeared (1c).

**2a; Day 43**



**2b; Day 60**



**Figure 2.** Time course of changes in chest HRCT findings. Azathioprine (AZA) was readministered beginning with a 50 mg/day dose from the 43rd hospital day, after which an infiltrative shadow and ground-glass opacities reappeared in the subpleural regions of the left upper and right upper and middle lobes (2a). Discontinuation of AZA again resulted in improvement of the pulmonary shadows (2b).

tional AZA administration resulted in the reexacerbation of the pulmonary shadow. Based on this, a diagnosis of AZA-induced IP was made, ruling out the acute exacerbation of RA-IP.

AZA treatment can result in both allergic toxicities and dose-dependent toxicities. Bedrossian, *et al* reported that 4 kidney transplant patients treated with AZA died of pulmonary toxicity that was dose-dependent<sup>4</sup>. Stetter, *et al*, Rubin, *et al*, and Ananthakrishnan, *et al* reported cases of pulmonary toxicity in which the patients initially presented with fever, cough, and dyspnea within 6 weeks after AZA administration<sup>3,6,8</sup>. IP improved after the discontinuation of AZA and steroid administration, suggesting an allergic mechanism. In our patient, IP exacerbation with fever and dyspnea occurred 6 days after beginning the administration of AZA and improved after discontinuation. Resumption of AZA therapy was followed by the recurrence of pulmonary shadows on chest HRCT on the same day. These observations suggest that the pulmonary toxicity occurring in this patient was related to an allergic mechanism.

TAKAAKI ISHIDA, MD; TAKUYA KOTANI, MD, PhD; TOHRU TAKEUCHI, MD, PhD; SHIGEKI MAKINO, MD, PhD, Department of Internal Medicine (I), Osaka Medical College, Daigaku-Machi 2-7, Takatsuki, Osaka 569-8686, Japan. Address correspondence to Dr. Ishida; E-mail: t-takeuchi@poh.osaka-med.ac.jp

## REFERENCES

1. Nagy F, Molnar T, Makula E, Kiss I, Milassin P, Zollei E, et al. A case of interstitial pneumonitis in a patient with ulcerative colitis treated with azathioprine. *World J Gastroenterol* 2007;13:316-9.

2. Fauroux B, Meyer-Milsztain A, Boccon-Gibod L, Leverger G, Clément A, Biour M, et al. Cytotoxic drug-induced pulmonary disease in infants and children. *Pediatr Pulmonol* 1994;18:347-55.
3. Stetter M, Schmidl M, Krapf R. Azathioprine hypersensitivity mimicking Goodpasture's syndrome. *Am J Kidney Dis* 1994;23:874-7.
4. Bedrossian CW, Sussman J, Conklin RH, Kahan B. Azathioprine-associated interstitial pneumonitis. *Am J Clin Pathol* 1984;82:148-54.
5. Brown AL, Corris PA, Ashcroft T, Wilkinson R. Azathioprine-related interstitial pneumonitis in a renal transplant recipient. *Nephrol Dial Transplant* 1992;7:362-4.
6. Rubin G, Baume P, Vandenberg R. Azathioprine and acute restrictive lung disease. *Aust NZ J Med* 1972;2:272-4.
7. Krowka MJ, Breuer RI, Kehoe TJ. Azathioprine-associated pulmonary dysfunction. *Chest* 1983;83:696-8.
8. Ananthakrishnan AN, Attila T, Otterson MF, Lipchik RJ, Massey BT, Komorowski RA, et al. Severe pulmonary toxicity after azathioprine/6-mercaptopurine initiation for the treatment of inflammatory bowel disease. *J Clin Gastroenterol* 2007;41:682-8.
9. Weisenburger DD. Interstitial pneumonitis associated with azathioprine therapy. *Am J Clin Pathol* 1978;69:181-5.
10. Perreux F, Zenaty D, Capron F, Trioche P, Odièvre M, Labrune P. Azathioprine-induced lung toxicity and efficacy of cyclosporin A in a young girl with type 2 autoimmune hepatitis. *J Pediatr Gastroenterol Nutr* 2000;31:190-2.

*J Rheumatol* 2012;39:5; doi:10.3899/jrheum.111415