

Interleukin 6 Blockade in Spondyloarthritis

To the Editor:

We read with interest the case report by Cohen, *et al* on sustained clinical improvement under tocilizumab [a humanized monoclonal antiinterleukin 6 (IL-6) receptor antibody] in a patient with HLA-B27-positive ankylosing spondylitis (AS)¹. The patient had not responded after 3 anti-tumor necrosis factor (TNF- α) agents. There are still few but promising reports of successful treatment of spondyloarthritis (SpA) with tocilizumab. Here we add our experience.

A 61-year-old woman had a 19-year history of HLA-B27-positive AS. At onset, radiographic imaging showed multilevel spondylodiscitis with acquired vertebral blocks and grade IV bilateral sacroiliitis. Due to insufficient response to nonsteroidal antiinflammatory drugs, she was prescribed etanercept from 2003 to 2010. In 2010, etanercept was switched to adalimumab because of multiple side effects including recurrent urinary tract infections, rhinosinusitis, furunculosis, and patient-reported shortness of breath after etanercept injections. Despite its efficacy on axial symptoms, adalimumab was withdrawn after 8 months because of the recurrence of infectious episodes including herpes zoster, rhinosinusitis, persistent furunculosis, and a dengue virus after traveling to the West Indies. One month after adalimumab discontinuation, she experienced a severe flare: total back pain assessed on a 100-mm visual analog scale (VAS) was 72/100, the Bath Ankylosing Spondylitis Disease Activity Index (BASDAI) was 53/100, the BAS Functional Index (BASFI) was 29.7/100, and C-reactive protein (CRP) was 30 mg/l. Spinal magnetic resonance imaging (MRI)

revealed multilevel inflammatory lesions of T1 and T6–T8 vertebral bodies and posterior structures (Figure 1A).

Considering the previous side effects of anti-TNF- α agents, the intensity of AS symptoms, and the limited therapeutic options, tocilizumab was introduced at 8 mg/kg every 4 weeks. Four weeks after the first infusion, a 60% improvement of axial pain was noted, the duration of morning stiffness was reduced to 5 min, and BASDAI was 23/100. In addition, CRP was normalized (< 1 mg/l). No infectious manifestation or allergic reaction was reported. At her last visit in our department, after a total of 4 tocilizumab infusions at 8 mg/kg/month, the patient reported a 100% clinical improvement: VAS for back pain was 0/100, there was no night pain or morning stiffness, and BASDAI was 2/100. Repeated CRP measurements were normal (< 1 mg/l). The MRI of the spine performed at the 20-week followup showed a partial regression of inflammatory lesions at T1 and T6–T7–T8 levels (Figure 1B). No safety issues were raised at the 24-week followup.

The potential benefit of tocilizumab in SpA has been suggested by increased IL-6 expression in the serum, sacroiliac joints, and peripheral joints^{2,3,4,5}, and in several recent isolated case reports^{1,6,7,8,9,10}. All cases reported to date were HLA-B27-positive; 3 patients were naive for anti-TNF- α therapy^{3,9,10}, and 4 had previously failed 3 anti-TNF- α agents^{1,6,7,8}. Clinical improvement under IL-6 antagonists was reported in all but 1 patient⁷.

As in the case reported by Cohen, *et al*, we also observed a remarkable and fast clinical response to tocilizumab in a patient with HLA-B27-positive AS who had received anti-TNF- α agents¹. Interestingly, Cohen, *et al* suggest that the frequency of tocilizumab infusions may be different in AS

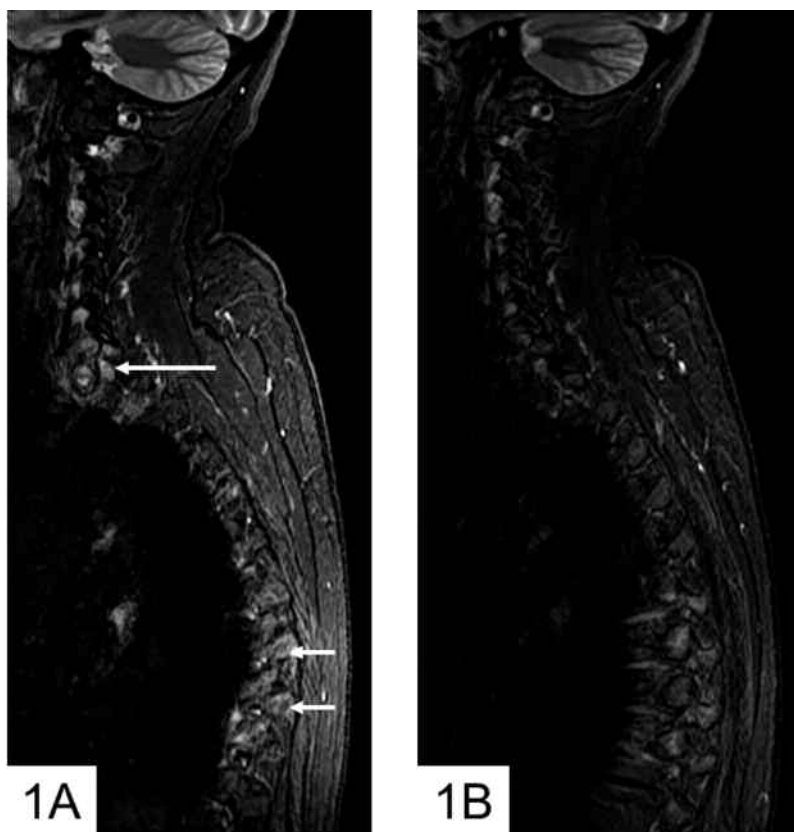


Figure 1. A. Sagittal short-tau inversion recovery (STIR) magnetic resonance (MR) image of the cervical spine before tocilizumab. Marked inflammatory costovertebral lesions are visible at upper thoracic level (long white arrow) and mid-thoracic level (short white arrows). B. Sagittal STIR MR image of the cervical spine after tocilizumab. Normalization of upper thoracic spine with no visible inflammatory lesion. Some residual changes are visible at mid-thoracic level.

than in rheumatoid arthritis, because they had to resort to infusions every 3 weeks to control symptoms, as described in a patient with AS and another with Crohn's disease^{1,8}. These patients had not responded to 3 anti-TNF- α agents and also abatacept in the latter case. In contrast with these descriptions, the clinical improvement observed in our patient was rapid, occurring after 4 weeks of treatment, and it did not require an increase in the frequency of tocilizumab infusions. However, tocilizumab was not chosen because of anti-TNF- α inefficacy but because of safety issues with TNF- α antagonists: a history of likely allergic manifestations and recurrent infections during both etanercept and adalimumab therapy. Moreover, we also noted an improvement in spinal MRI inflammatory lesions after the 20-week followup, which has not been described to date under tocilizumab therapy. To our knowledge, spinal MRI assessment is well documented in only 1 other case of SpA treated with tocilizumab⁶. That patient, described by Henes, *et al*, displayed persistent inflammatory lesions on spinal MRI 18 weeks after tocilizumab initiation⁶.

Together with previous reports, our observation provides further evidence for the potential use of tocilizumab in SpA. This treatment may be an alternative therapeutic option in patients refractory to or intolerant of anti-TNF- α agents. However, the efficacy of tocilizumab cannot be extended to SpA before the results of ongoing controlled clinical trials are made available, and the use of MRI as a potential outcome measure in the followup of this treatment remains to be determined.

EUGÉNIE KOUMAKIS, MD, Paris Descartes University, Rheumatology A Department, Cochin Hospital, APHP; ANTOINE FEYDY, MD, Paris Descartes University, Radiology B Department, Cochin Hospital, APHP; ANDRÉ KAHAN, MD, PhD; YANNICK ALLANORE, MD, PhD, Paris Descartes University, Rheumatology A Department, Cochin Hospital, APHP, Paris, France. Address correspondence to Dr. Y. Allanore, Service de Rhumatologie A, Hôpital Cochin, 27 Rue du Faubourg Saint-Jacques, 75014 Paris, France. E-mail: yannick.allanore@cch.aphp.fr

REFERENCES

1. Cohen JD, Ferreira R, Jorgensen C. Ankylosing spondylitis refractory to tumor necrosis factor blockade responds to tocilizumab [letter]. *J Rheumatol* 2011;38:1527-8.
2. Gratacos J, Collado A, Filella X, Sanmarti R, Canete J, Llena J, et al. Serum cytokines (IL-6, TNF- α , IL-1- β and IFN- γ) in ankylosing spondylitis: A close correlation between serum IL-6 and disease activity and severity. *Br J Rheumatol* 1994;33:927-31.
3. Wendling D, Racadot E, Toussiot E, Wijdenes J. Combination therapy of anti-CD4 and anti-IL6 monoclonal antibodies in a case of severe spondylarthropathy. *Br J Rheumatol* 1996;35:1330.
4. Bal A, Unlu E, Bahar G, Aydog E, Eksioglu E, Yorgancioglu R. Comparison of serum IL-1- β , sIL-2R, IL-6, and TNF- α levels with disease activity parameters in ankylosing spondylitis. *Clin Rheumatol* 2007;26:211-5.
5. Francois RJ, Neure L, Sieper J, Braun J. Immunohistological examination of open sacroiliac biopsies of patients with ankylosing spondylitis: Detection of tumour necrosis factor alpha in two patients with early disease and transforming growth factor beta in three more advanced cases. *Ann Rheum Dis* 2006;65:713-20.
6. Henes JC, Horger M, Guenaydin I, Kanz L, Koetter I. Mixed response to tocilizumab for ankylosing spondylitis. *Ann Rheum Dis* 2010;69:2217-8.
7. Wendling D, Bossert M, Prati C. Short-term effect of IL-6 inhibition in spondylarthritis. *Joint Bone Spine* 2010;77:624-5.
8. Brulhart L, Nissen MJ, Chevallier P, Gabay C. Tocilizumab in a patient with ankylosing spondylitis and Crohn's disease refractory to TNF antagonists. *Joint Bone Spine* 2010;77:625-6.
9. Tanaka T, Kuwahara Y, Shima Y, Hirano T, Kawai M, Ogawa M, et al. Successful treatment of reactive arthritis with a humanized anti-interleukin-6 receptor antibody, tocilizumab. *Arthritis Rheum* 2009;61:1762-4.
10. Shima Y, Tomita T, Ishii T, Morishima A, Maeda Y, Ogata A, et al. Tocilizumab, a humanized anti-interleukin-6 receptor antibody, ameliorated clinical symptoms and MRI findings of a patient with ankylosing spondylitis. *Mod Rheumatol* 2011;21:436-9.

J Rheumatol 2012;39;5; doi:10.3899/jrheum.110955