

**Vasculitis, Vitiligo, Thyroiditis, and Altered Hormone Levels After Anti-Tumor Necrosis Factor Therapy**

To the Editor:

A 55-year-old Israeli man with a history of psoriatic arthritis presented with vitiligo (Figure 1). He received infliximab infusions at a dose of 5 mg/kg every 6 weeks for 2 years to manage his psoriatic arthritis. Twelve weeks

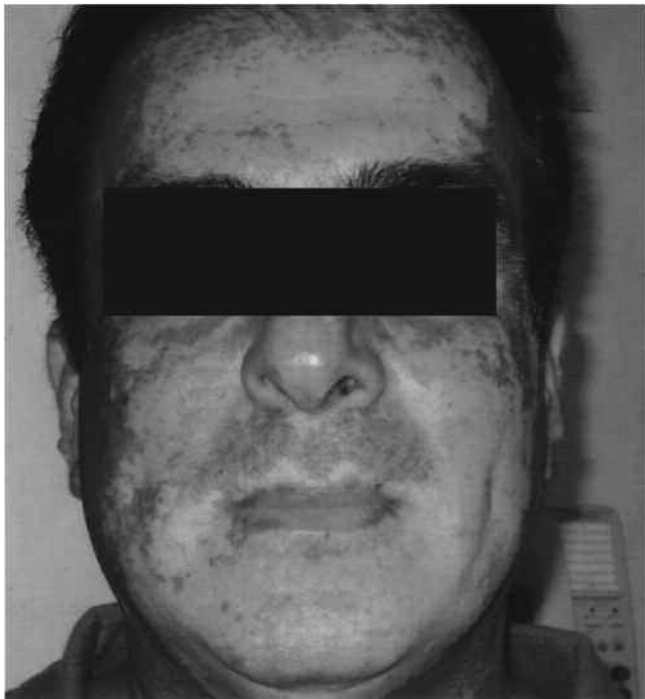

Figure 1. A 55-year-old man with vitiligo after several months of therapy with an anti-TNF drug.

prior to presentation in our clinic, his physician doubled the dose of infliximab from 400 to 800 mg. After this, vitiligo appeared on the face, groin, hands, and feet over a 2-week period. The patient related that 2 years before this he received 500 mg of infliximab instead of the 400 mg dose and he then experienced areas of depigmentation, but to a lesser degree.

Laboratory tests showed normal blood cell count, biochemistry, urine test, and complement levels. Prior to the increase of infliximab, his primary care physician noted elevated thyroid-stimulating hormone (TSH) of 5.62, suggesting early hypothyroidism. Rheumatoid factor, cardiolipin antibody, native DNA antibody, SM/RNP antibody, Scl-70 antibody, and antibodies to Ro/La were all negative. His total IgG was elevated at 2238 mg/dl.

He had early evidence of gynecomastia and decreased libido, and sex steroid levels were investigated. On Day 700 several weeks after discontinuation of infliximab, his plasma estradiol was elevated at 77.7 pg/ml (normal 0–56 pg/ml) with normal testosterone (472 ng/dl) and elevated prolactin level, 46 ng/ml. At this time his C-reactive protein (CRP) was elevated (2.63 mg/l); as well, the skin lesions stopped progressing and he experienced a 5% repigmentation of all lesions.

Five months after discontinuation of TNF inhibition, he developed biopsy-proven pyoderma gangrenosum on his legs, pedal edema, and 2 gangrenous toes on his right foot. With corticosteroids, his wounds healed over a 60-day period. During this time, his CRP rose again and thyroid peroxidase antibody was elevated at 143 IU/ml. All thyroid function tests remained normal. His antineutrophilic cytoplasmic antibody was negative and there was no evidence of vasculitis or thrombosis on arteriography or venography.

Because of continued arthritis pain, he received a different TNF inhibitor, etanercept, at 1000 days into his clinic study. Taking this agent, he improved from Day 1016 to Day 1288. During this time, his thyroid peroxidase antibody levels were elevated (Figure 2) and he suddenly developed a raised purpuric vasculitis with blisters and blebs on his lower torso and his lower extremities. The TNF inhibitor was stopped and a skin biopsy revealed leukocytoclastic vasculitis. At cessation of the drug therapy, his CRP was extremely high at 180 mg/l and his erythrocyte sedimentation rate began to rise. The significant decline in his testosterone levels could be attributed to corticosteroids, which had been taken for the vasculitis. He was also antinuclear antibody (ANA)-positive at this time. Examination of

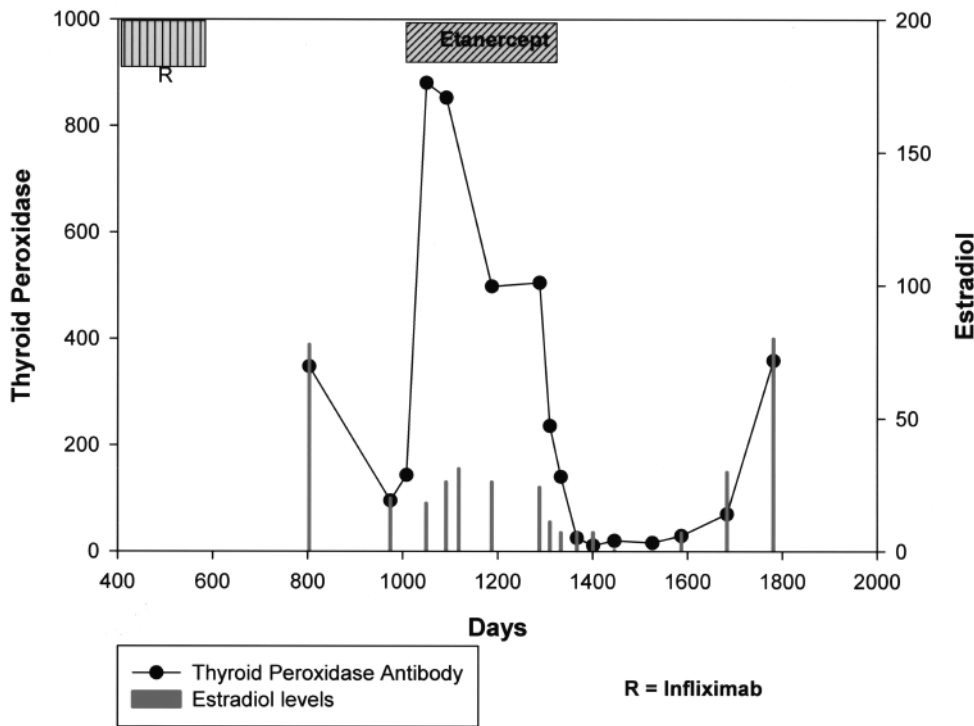


Figure 2. Course of therapy with etanercept and infliximab during the entire course of therapy of this patient. Estradiol levels (normal 0–56 pg/ml; shown in color) are elevated between treatment periods with anti-TNF drugs. Anti-thyroid peroxidase (normal 0–34 IU/ml) is elevated at the time of etanercept therapy.

his sex steroids at Day 1300 revealed normal levels of estradiol and low levels of testosterone.

He developed acute glomerulonephritis manifested by an active urine sediment, nephrotic-range proteinuria (spot urine protein/creatinine ratio of 13.4 and serum creatinine of 2.1), and hypertension. Subsequent complement levels, antineutrophil cytoplasmic antibodies (ANCA), and anti-glomerular basement membrane were negative. A renal biopsy revealed crescentic necrotizing glomerulonephritis. H&E stains showed involvement of 90% of the glomeruli. Immunofluorescence showed 2+ linear staining for IgG, kappa and lambda light chains, and albumin. Electron microscopy revealed injury of the podocytes with effacement of the foot processes and absence of tubuloreticular inclusions. With both cytotoxic and corticosteroid therapy, his serum creatinine improved from 2.1 to 1.4 mg/dl. On Day 1800, taking no steroids or anti-TNF medication, his estradiol level rose to 78 pg/ml and he was noted to have profound gynecomastia.

This describes the onset of an autoimmune disease coupled with the intermittent infusion of TNF inhibitors over a 5-year period. The clinical onset of nonsegmental vitiligo, thyroiditis, and vasculitis, coupled with a positive ANA, hypergammaglobulinemia, and elevated estradiol level, is significant to the etiopathogenesis of this patient's disease. Both thyroiditis and pyoderma gangrenosum developed after anti-TNF therapy, and the elevation of antithyroid peroxidase antibodies coincident with the infusion of an anti-TNF inhibitor is significant. The elevated TSH prior to the onset of anti-TNF therapy suggests that the thyroiditis preceded the anti-TNF infusion.

The association of high anti-thyroid peroxidase antibody associated with anti-TNF therapy has not been described. There is one case report of vitiligo following the administration of infliximab<sup>1</sup>, and no cases relate these phenomena to the presence of new autoantibodies in a male as a result of the TNF inhibition. There are reports of autoimmune disease after anti-TNF therapy<sup>2,3</sup>. Altered levels of sex steroids occur in patients on anti-TNF therapy<sup>4</sup>. Aromatase, the enzyme that converts androgens to estrogens, is stimulated by TNF- $\alpha$ , and the early and late elevated levels of estradiol may reflect the level of TNF that existed in this patient prior to infliximab<sup>5</sup>. Inhibitors of TNF decrease the estrogen levels in joint fluids after therapy through a mechanism that involves a decrease in aromatase activity<sup>6</sup>. Estrogens are independent upregulators of immunoglobulin synthesis and the patient's total immunoglobulin of 2238 mg/dl during the time of high estrogen levels reflects that effect<sup>7</sup>. An increase of peripheral aromatase in patients with untreated rheumatoid arthritis causes elevation of estradiol. Thyroiditis relates to high levels of estradiol in mice<sup>8</sup>, and is an antigen expressed with some frequency in patients with systemic lupus erythematosus<sup>2</sup> for unclear reasons, with resultant thyroiditis.

The action of the TNF inhibitors on male hormone levels or fertility in general is not known, but the literature suggests an effect, which requires more investigation<sup>9</sup>. TNF- $\alpha$  cytokine inhibitors are associated with vas-

culitis and a crescentic glomerulonephritis<sup>10</sup>, but not in the absence of ANCA.

ROBERT G. LAHITA, MD, PhD, FRCP, FACP, FACR, Department of Medicine, Newark Beth Israel Hospital, 201 Lyons Avenue, Newark, New Jersey 07112; MELCHIORE A. VERNACE, MD, Nephrology-Hypertension Specialists, Doylestown, Pennsylvania, USA. Address correspondence to Dr. Lahita; E-mail: r.lahita@att.net

*The authors express their gratitude to Erin Duggan for assistance with the manuscript.*

## REFERENCES

1. Ramirez-Hernandez M, Marras C, Martinez-Escribano JA. Infliximab induced vitiligo. *Dermatology* 2005;210:79-80.
2. Shoenfeld Y. The kaleidoscope of autoimmunity. *Autoimmunity* 1993;15:245-51.
3. Ramos-Casals M, Perez-Alvarez R, Diaz-lagares C, Cuadrado MJ, Khamashta MA. Autoimmune disease induced by biological agents; a double edged sword? *Autoimmun Rev* 2010;9:188-93.
4. Cutolo M, Sulli A, Capellino S, Villaggio B, Montagna P, Pizzorni C, et al. Anti-TNF and sex hormones. *Ann NY Acad Sci* 2006;1069:391-400.
5. Tengstrand B, Carlstrom K, Fellander-Tsai L. Abnormal levels of serum dehydroepiandrosterone, estrone, and estradiol in men with rheumatoid arthritis: high correlation between serum estradiol and current degree of inflammation. *J Rheumatol* 2003;30:2338-43.
6. Macdiarmid F, Wang DF, Duncan LG. Stimulation of aromatase activity in breast fibroblasts by tumor necrosis factor alpha. *Mol Cell Endocrinol* 1994;106:17-21.
7. Cutolo M, Sulli A, Capellino S, Villaggio B, Montagna P, Seriolo B, et al. Sex hormones influence on the immune system: basic and clinical aspects in autoimmunity. *Lupus* 2004;13:635-8.
8. Ansar Ahmed S, Young PR, Penhale WJ. Beneficial effects of testosterone in the treatment of chronic autoimmune thyroiditis in rats. *J Immunol* 1986;136:143-7.
9. Paschou S, Voulgari PV, Vrabie IG, Saougou IG, Drosos AA. Fertility and reproduction in male patients with ankylosing spondylitis treated with infliximab. *J Rheumatol* 2009;36:351-4.
10. Doulton TW, Tucker B, Reardon J, Velasco N. Antineutrophil cytoplasmic antibody-associated necrotizing crescentic glomerulonephritis in a patient receiving treatment with etanercept for severe rheumatoid arthritis. *Clin Exp Rheumatol* 2006;24 Suppl:S106.

*J Rheumatol* 2011;38:3; doi:10.3899/jrheum.100968