

# Prospective Evaluation of Clinical and Ultrasound Findings in Ankle Disease in Juvenile Idiopathic Arthritis: Importance of Ankle Ultrasound

LAURA PASCOLI, STEPHEN WRIGHT, CATHERINE McALLISTER, and MADELEINE ROONEY

**ABSTRACT. Objective.** To prospectively compare clinical examination of the ankle structures with ultrasound (US) findings.

**Methods.** In 42 children with juvenile idiopathic arthritis (JIA; 25 girls, 17 boys, mean age 11.3 yrs, range 2.3–22.3 yrs), a total of 61 swollen/painful ankles were assessed clinically and ultrasonographically. Accurate clinical examination of the entire ankle joint was performed, focusing especially on 3 regions — tibiotalar joint and medial and lateral tendons. Clinical and US findings were both scored 0–3 (normal-severe).

**Results.** US demonstrated no signs of tibiotalar joint effusion in 14 out of 43 ankles considered clinically involved. For the medial tendons, US showed tenosynovitis in 13 ankles out of 31 thought to be clinically normal; and for the lateral tendons, of the 19 deemed to be clinically involved, less than 50% had involvement on US. Very poor agreement was observed comparing the clinical and US scores for the 3 regions: tibiotalar joint, kappa = 0.3; medial tendons, kappa = 0.24; lateral tendons, kappa = 0.25. With regard to other ankle structures, only 39% of the subtalar (talocalcaneal) joints considered clinically involved were deemed abnormal on US. Finally, of the 10 ankles with talonavicular US effusion, only 2 were considered clinically involved.

**Conclusion.** Using US findings as the “gold standard,” clinical examination of the ankle in children with JIA was found to be inadequate in identifying the structures involved. US assessment prior to any glucocorticoid injection should be considered to improve the outcome. A prospective study comparing the outcome following clinical- versus US-guided ankle joint injection should be undertaken, to confirm our findings. (First Release Sept 15 2010; J Rheumatol 2010;37:2409–14; doi:10.3899/jrheum.091262)

## Key Indexing Terms:

JUVENILE IDIOPATHIC ARTHRITIS

ULTRASOUND

ANKLE

Juvenile idiopathic arthritis (JIA) describes a group of chronic arthritides occurring in children before their sixteenth birthday. It is not uncommon, with a worldwide prevalence of 0.07 to 4.01 per 1000 children<sup>1</sup>. Seven clinical subgroups have been identified, and for all of them, arthritis is the common feature<sup>2</sup>. The criteria do not include involvement of structures around the joints such as the tendons. The pattern of joints involved varies between subtypes. However, the most frequently affected joints are knees (77%), followed by ankles (58%), hands, wrists, feet, elbows, hips, and shoulders<sup>3</sup>.

While there have been a number of studies on hip, hand, wrist, and especially the knee in JIA, very few have been undertaken on the ankle joint, although it is the second most frequently affected joint in children.

Intraarticular corticosteroid (IAC) injections are frequently used by clinicians in the management of joint disease in JIA, with good effect<sup>4,5,6,7,8,9,10,11,12,13,14</sup>. Beukelman, *et al*<sup>15</sup> reported that 94% of pediatric rheumatologists would recommend IAC injection of the ankle in clinical practice. However, despite being the second most commonly affected (and injected) joint, remarkably little has been written about the effectiveness of IAC injection in ankle disease in JIA. Our experience, and that of others<sup>5,12</sup>, is that the results following clinically guided IAC in ankle disease are less effective. Interestingly, Breit, *et al*<sup>16</sup> in a retrospective analysis reported better results; IAC injections of the ankle were undertaken following ultrasound (US) assessment.

Thus one explanation for a poorer outcome could be the complexity of the ankle region compared to the knee. Tarsal and subtalar involvement as well as tendon involvement can be difficult to distinguish clinically from tibiotalar disease, especially in the very young. In other words the poor result

From the Belfast Hospital Trust and the Department of Paediatric Rheumatology, Queen's University of Belfast, Belfast, UK.

Supported by the Research and Development Office, Northern Ireland.

L. Pascoli, MD, Research Fellow; S. Wright, PHD, MB, BCh, BAO, Senior Registrar; C. McAllister, RMN, Research Nurse, Belfast Hospital Trust; M. Rooney, MB, BCh, BAO, MRCP, DCH, MD, FRCPI, Senior Lecturer, Consultant, Paediatric Rheumatology, Queen's University of Belfast.

Address correspondence to Dr. M. Rooney, Paediatric Rheumatology Research Group, MEU Queens University Belfast, Musgrave Park Hospital, Stockman's Lane, Belfast BT97JB, UK.

E-mail: m.rooney@qub.ac.uk

Accepted for publication July 6, 2010.

Personal non-commercial use only. The Journal of Rheumatology Copyright © 2010. All rights reserved.

from IAC injection may be due to incorrect identification of the structures involved.

Since 2003 we have been using musculoskeletal US as a routine clinical tool in our pediatric rheumatology clinics. US is an accurate and noninvasive imaging technique, well tolerated by children to evaluate synovitis, tendonitis, and tenosynovitis in the arthritic joint. In adult arthritis, use of US has dramatically changed standard clinical assessment of patients<sup>17</sup>.

A number of studies have been published on US in JIA; most are limited to knee and hip joints<sup>18,19,20,21,22,23,24,25,26,27,28,29,30,31,32,33,34,35</sup>. Some studies demonstrated the higher sensitivity of US with respect to clinical assessment in detecting joint involvement<sup>20,21,26,28,31</sup>.

In 2006 we undertook a retrospective study comparing "ankle" swelling with US findings in that region. We demonstrated poor correlation between the clinical and US findings in ankle disease in JIA<sup>36</sup>. Moreover, we showed that tibiotalar disease was overdiagnosed and tendon involvement underdiagnosed. However, in that study, no attempt was made to clinically identify the structures involved in the ankle region, as historically, ankle swelling was assumed to indicate tibiotalar disease.

With this knowledge, we have since 2007 prospectively assessed the clinical and US findings in symptomatic and/or swollen ankles of children with JIA. In clinical examinations we also attempted to identify what structures were involved in the ankle region.

The purpose of this study was to compare our clinical evaluation of ankle structures with that observed on ultrasound.

Informed verbal consent was obtained from parents and children to participate in this evaluation.

## MATERIALS AND METHODS

**Clinical evaluation.** Children were prospectively assessed at our pediatric rheumatology outpatients and day ward clinics. Forty-two children with JIA according to the ILAR classification<sup>2</sup>, with swollen and/or painful ankles, were recruited.

The ankle region was clinically assessed and scored by an experienced pediatric rheumatologist (MR) for involvement of the main ankle joint (tibiotalar joint), medial tendons (tibialis posterior tendon group), and lateral tendons (peroneal tendons). Structures were scored 0–3, with 0 = normal, 1 = mild, 2 = moderate, 3 = severe. Involvement of other structures such as talonavicular, tendons in the anterior region of the ankle, and subtalar (anterior aspect of the talocalcaneal joint) was recorded. Subtalar clinical involvement was based on pain evoked by internal and external passive movement of this joint and on limitation of motion.

**Ultrasonography.** At the same consultation, the ankles were scanned by clinicians experienced in US (LP, SW) blinded to the clinical findings of the pediatric rheumatologist. US scan was performed using an Esaote MyLab 25 (LA523E 7.5–12 MHz linear transducer).

US findings were scored on a scale of 0–3 using a semiobjective grading system, as follows.

Effusion was scored as 0: No effusion; 1. Mild: effusion filling less than 50% of the tibiotalar recess; 2. Moderate: effusion filling the tibiotalar recess; and 3. Marked: effusion bulging out of the tibiotalar recess.

Synovial hypertrophy was scored subjectively on a semiquantitative basis, as 0: No synovial hypertrophy; 1. Mild: less than 25% of the joint space filled with synovium; 2. Moderate: 25–50% of the joint space filled with synovium; and 3. Marked: more than 50% of the joint space filled with synovium.

Due to the limits of the MyLab 25 instrument, power Doppler was not quantified and the presence or absence of power Doppler signal alone was recorded. Thus the Doppler findings do not contribute to the US scores. Images were obtained using the following settings: frequency 12 MHz, PRF 0.7 MHz, with lowest filter and highest gain that did not display background artefact.

Ankle images were obtained by longitudinal and transverse scans of tibiotalar joint, tibialis posterior tendon group, and peroneal tendons, with knee in 45 degrees of flexion.

We also scanned talonavicular and subtalar joints, and tendons in the anterior region of the ankle (tibialis anterior, extensor hallucis longus, and extensor digitorum). We scanned the subtalar joint in the transverse position, with the probe on the lateral and medial malleolus at 4 o'clock and then moving it down and distally 1 or 2 cm until the subtalar joint was visualized. An effusion is demonstrated by a hypoechoic signal. Moreover we performed unenhanced power Doppler imaging of the same structures.

Stored blinded images were further analyzed for consensus by 2 assessors.

**Statistical analysis.** We used a kappa statistic with linear weights to measure the degree of agreement between clinical and US findings, and to measure interobserver agreement between the 2 ultrasonographers. Fisher's exact test was used to compare the 3 ankle regions between children with oligoarticular JIA (oJIA) and polyarticular JIA (pJIA). Using musculoskeletal ultrasound findings as the "gold standard," the positive predictive values (PPV) and negative predictive values (NPV) were also calculated.

**Ethical approval.** This project was submitted to the NIREC (No. 09/NIR02/2). It was deemed by the committee that since our study formed part of our routine clinical assessment the study was considered to be a service evaluation and thus ethical approval was not necessary. The study is registered with the Belfast Health and Social Care Trust Research Office.

## RESULTS

A total of 61 ankles from 42 children with JIA were assessed.

The interobserver US reliability analysis showed there was good agreement between the 2 ultrasonographers (linear weighted kappa = 0.8).

Clinical subtypes, demographics, and medications are listed in Table 1.

Agreement of involved compared with noninvolved joints according to the clinical and US findings is given in Table 2. Table 2 also gives PPV and NPV from clinical examinations for the 3 structures analyzed using US as gold standard. We observed that the sum of PPV and NPV was 1.23 or 1.21 every time, indicating weak diagnostic ability of the clinical examination compared with the US evaluation.

Of the 61 ankles assessed, 43 were clinically considered to have involvement of the tibiotalar joint. However, 14 of these (32%) had no evidence of tibiotalar effusion or of synovial hypertrophy on US. In 31 ankles the tibialis posterior tendon group was not thought to be involved clinically. However, 13 of these (42%) had evidence of involvement on US. For the peroneal tendons, of the 19 deemed to be clinically involved, only 8 (42%) had involvement on US.

Table 1. Clinical subtypes, demographics, and medications of study subjects.

Feature	Polyarticular JIA	Oligoarticular JIA	Extended oJIA	Systemic JIA	Enthesitis-related JIA	Psoriatic JIA
Patients, no.	19	17	3	1	1	1
Ankles, no.	28	23	4	2	2	2
Female/male	12/7	11/6	1/2	0/1	0/1	1/0
Mean age at visit, yrs (range)	13.3 (4.9–22.3)	8.4 (2.3–17.4)	9.2 (3.4–13.1)	14.4	14.5	17.3
Mean disease duration, yrs (range)	6.3 (0.7–21.2)	2.2 (0.2–9.1)	4.5 (0.6–12.4)	2.1	6	1.2
NSAID/analgesic	14	14	2	—	1	—
Methotrexate (MTX)	15	1*	1	1	—	1
Sulfasalazine	—	—	—	—	1	—
Prednisolone	4	—	—	1	—	1
Etanercept	4	—	—	—	—	—
Infliximab	1	—	—	—	—	—
Anakinra	—	—	—	1	—	—

\* Antinuclear antibody-positive oligoarticular JIA, taking MTX for bilateral anterior uveitis. NSAID: nonsteroidal antiinflammatory drug.

Table 2. Agreement between structures that were involved versus those with no involvement according to the clinical and ultrasound (US) findings.

	Clinically Normal, US Normal	Clinically Normal, US Abnormal	Clinically Abnormal, US Normal	Clinically Abnormal, US Abnormal	PPV*	NPV*
Tibiotalar joint	18/10	18/8	43/14	43/29	0.67	0.56
Tibialis postendon group	31/18	31/13	30/11	30/19	0.63	0.58
Peroneal tendons	42/33	42/9	19/11	19/8	0.42	0.79

\* PPV (positive predictive value) and NPV (negative predictive value) of clinical examination for the 3 structures analyzed using US as gold standard.

Normal and abnormal US images of the tibiotalar joint and medial tendons are shown in Figure 1 and Figure 2.

Of interest, from the US scans, the tibiotalar joint alone was involved in only 12 ankles (19.7%), whereas both the tibiotalar and tendons were involved in 37 ankles (60.6%). Conversely, tendons alone were involved in 12 ankles (19.7%).

We then compared the clinical and US scores (0–3) for the 3 regions using the linear weighted kappa. Very poor agreement was observed: for the tibiotalar joint, the kappa value was 0.3; for the tibialis posterior tendon group the kappa value was 0.24; and for the peroneal tendons kappa value was 0.25.

In our previous retrospective study<sup>36</sup> we observed that tendon involvement was significantly more common in children with oJIA than in those with pJIA. We thus compared the frequency of joint and tendon involvement between

these 2 groups. No significant differences were observed ( $p = 0.17$ – $0.66$ , Fisher's exact test). However, we observed that medial tendon involvement was twice that of the lateral, peroneal tendons (32 vs 17, respectively).

Subtalar involvement was assessed clinically on all ankles. We did not include these scans in our formal analysis as the subtalar region has not, to date, been adequately assessed ultrasonographically. Thus consensus on involvement according to US findings was not established. However, we will comment on our findings. Twenty-three subtalar joints were considered to be clinically involved; from these, only 9 US scans (39%) were deemed abnormal. Figure 3 shows US findings in the subtalar joint. Moreover, on scanning the ankle region, we observed 10 ankles with talonavicular involvement (Figure 4); only 2 of them were considered to be clinically involved.

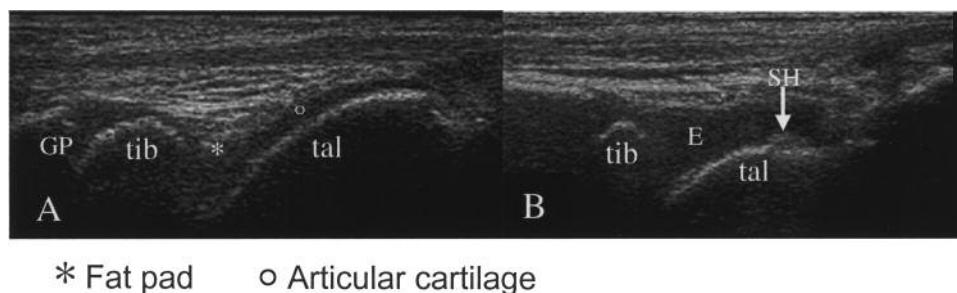
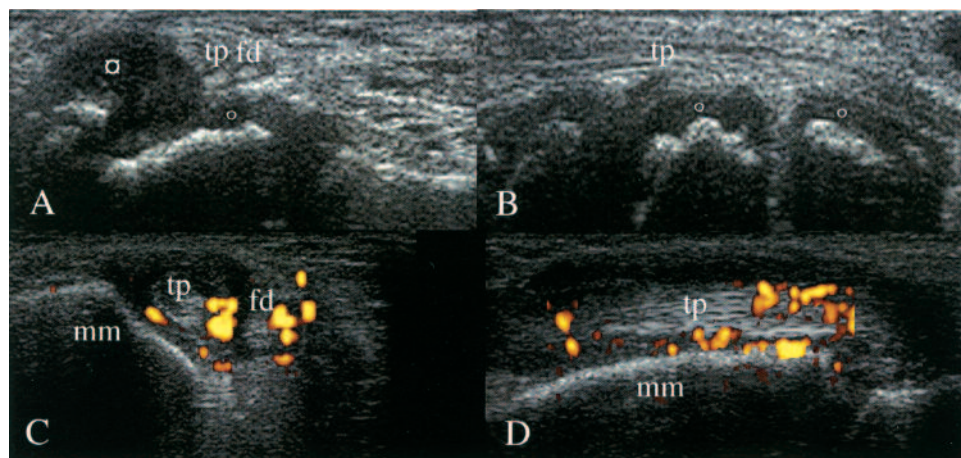


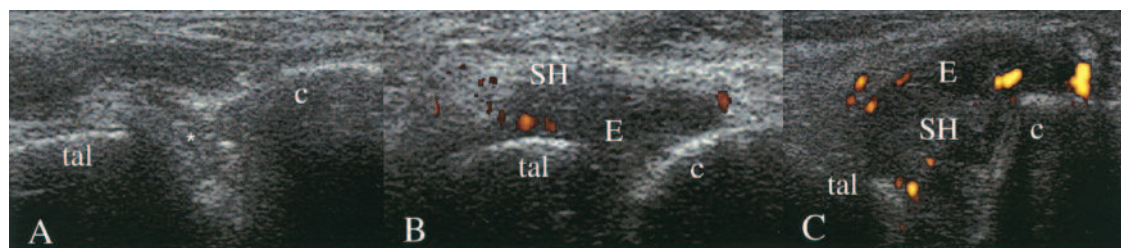
Figure 1. Tibiotalar joint. A. Longitudinal scan: normal joint (girl, age 10 yrs). B. Longitudinal scan: moderate joint effusion (E) and mild synovial hypertrophy (SH) (girl, age 6 yrs). GP: growth plate; tib: tibia; tal: talus.





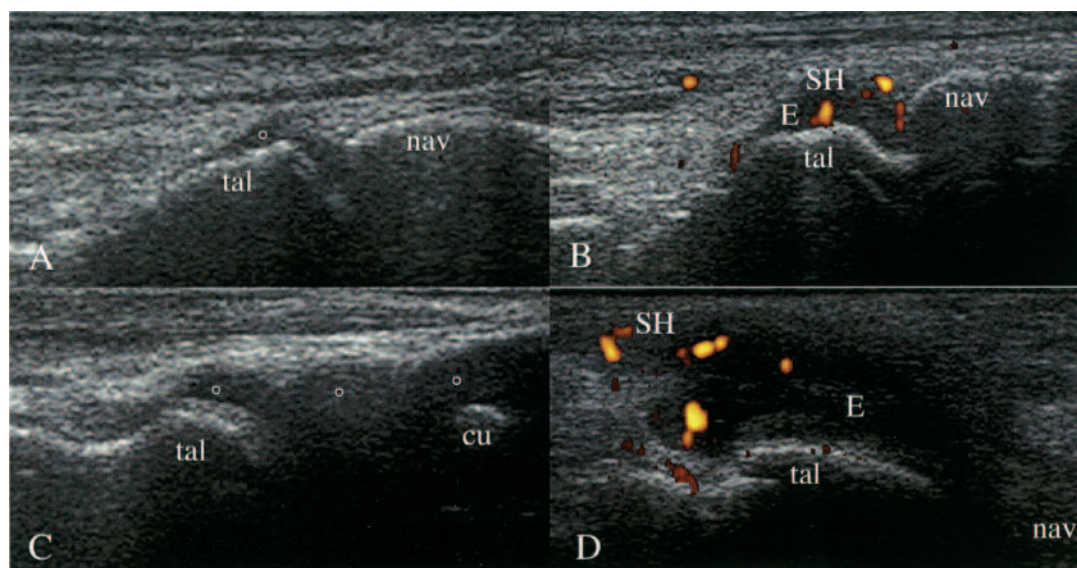
□ Medial malleolus cartilage halo    ○ Articular cartilage

**Figure 2.** Tibialis posterior tendon. A. Transverse scan: normal (girl, age 5 yrs). B. Longitudinal scan: normal (girl, age 5 yrs). C. Transverse scan: severe effusion, moderate synovial hypertrophy, severe pannus development (girl, age 15 yrs). D. Longitudinal scan: severe effusion, moderate synovial hypertrophy, severe pannus development (girl, age 15 yrs). tp: tibialis posterior tendon; mm: medial malleolus; fd: flexor digitorum tendon.



\* Fat pad

**Figure 3.** Subtalar joint. A. Transverse scan: normal (girl, age 12 yrs). B. Transverse scan: moderate E, moderate SH, mild PD (F, 10 yrs). C. Transverse scan: severe effusion (E), moderate synovial hypertrophy (SH), moderate pannus development (girl, age 15 yrs). tal: talus; c: calcaneus.



○ Articular cartilage

**Figure 4.** Talonavicular joint. A. Longitudinal scan: normal (girl, age 9 yrs). B. Longitudinal scan: mild effusion (E), mild synovial hypertrophy (SH), moderate pannus development (girl, age 9 yrs). C. Longitudinal scan: normal (girl, age 2 yrs). Note the difference in cartilage thickness between A and C. D. Longitudinal scan, medial aspect: severe effusion, mild synovial hypertrophy, moderate pannus development (boy, age 16 yrs). tal: talus; nav: navicular; cu: cuneiform.

Finally, power Doppler (PD) investigation was performed on all structures that had been viewed by US. We found a positive signal in one or more structures involved per ankle in 13 ankles of 11 patients.

## DISCUSSION

This is the first prospective assessment of ankle disease in JIA. Clinical examination of the ankle area in these children frequently results in incorrect findings. It should be noted that the clinical examination was undertaken by a clinician who was aware of the findings from our previous retrospective study<sup>36</sup> and who had thus examined these joints in great clinical detail. We would suggest that routine clinical assessment may be less thorough.

Using US as the gold standard, clinical evaluation of the ankle structures has a weak diagnostic ability (Table 2), confirming the findings of our retrospective study<sup>36</sup> that clinical assessment of the ankle region in children with JIA is inadequate in identifying the structures involved. In our opinion, this explains the poor response to IAC injections in this region.

We have demonstrated a very poor agreement between clinical and US scores for the 3 ankle structures assessed, as defined by the kappa values.

In our previous retrospective study<sup>36</sup> we observed that tendon involvement was significantly more common in children with oJIA than in those with pJIA. Interestingly, in the present prospective study, we observed no significant differences ( $p = 0.17$ – $0.66$ , Fisher's exact test).

Only 39% of the subtalar joints considered to be clinically involved showed signs of synovitis on US. By contrast, Remedios, *et al*<sup>7</sup> showed that, of the 10 subtalar joints with pannus on magnetic resonance images (MRI), only 2 were thought to have had clinical evidence of synovitis. Therefore the clinical examination does not correlate with either US or MRI findings. More studies are needed to assess this joint on US in order to adequately evaluate its usefulness in detecting synovitis.

Of interest, we were surprised to find a substantial number of children with talonavicular involvement that was overlooked clinically.

Limitations of our study would include the following. Power Doppler imaging was performed on all structures that had undergone ultrasound scanning. However, we have to take into account that the Esaote MyLab 25 scanner used in the study is relatively poor at detecting a power Doppler signal in synovitis. Thus we did not include power Doppler in our US score. Only painful and/or swollen ankles were studied, with no controls (i.e., clinically normal ankles in nonaffected children); we do not know whether controls may have had US abnormalities. But this was not the purpose of the investigation.

In adult arthritis the use of US scans has dramatically changed standard clinical assessment of patients<sup>17</sup>. It is well

established that this imaging technique is a valuable complementary tool, enabling clinicians to improve the accuracy of their diagnostic skills including management decisions<sup>37</sup>. Further, US guidance improves the efficacy of joint fluid aspiration and local corticosteroid injection in inflammatory arthritis<sup>38,39,40,41,42</sup>. Finally, adult US standard reference values<sup>43</sup> and guidelines<sup>44</sup> do exist.

In children, US has a special benefit over other imaging techniques (radiographs and MRI) since it produces no ionizing radiation and does not require sedation/general anesthetic. Thus, an appropriately trained clinician can use it in the clinic and at the bedside as often as necessary for accurate diagnosis to guide joint injections and for assessment at followup.

We observed that, of the 43 joints thought to have tibiotalar involvement clinically, one-third were normal on US. This has significant implications for classification of children into JIA subtypes. The ILAR classification<sup>2</sup> refers to joint involvement, not tendon involvement. It could thus be argued that children could erroneously be described as having polyarticular disease when only tendons are involved. We suggest that these US findings necessitate further discussion of the definition and classification of JIA.

Our results highlight the value of US in pediatric rheumatology and we would stress that US assessment prior to any joint injections in this region would potentially improve the efficacy of IAC injection. There is now a need for a prospective study comparing the outcome between clinical versus US-guided intraarticular corticosteroid injections in ankle disease in JIA.

## ACKNOWLEDGMENT

We thank the children with JIA and their families for agreeing to take part in this study. We are indebted to Mike Stevenson, Senior Lecturer in Medical Statistics, Queen's University Belfast, for help with statistical analysis.

## REFERENCES

1. Manners PJ, Bower C. Worldwide prevalence of juvenile arthritis: why does it vary so much? *J Rheumatol* 2002;29:1520-30.
2. Petty RE, Southwood TR, Manners P, Baum J, Glass DN, Goldenberg J, et al. International League of Associations for Rheumatology. Classification of juvenile idiopathic arthritis: second revision, Edmonton, 2001. *J Rheumatol* 2004;31:390-2.
3. Selvaag AM, Flatø B, Dale K, Lien G, Vinje O, Smerdel-Ramoya A, et al. Radiographic and clinical outcome in early juvenile rheumatoid arthritis and juvenile spondyloarthritis: a 3-year prospective study. *J Rheumatol* 2006;33:1382-91.
4. Tynjälä P, Honkanen V, Lahdenne P. Intra-articular steroids in radiologically confirmed tarsal and hip synovitis of juvenile idiopathic arthritis. *Clin Exp Rheumatol* 2004;22:643-8.
5. Zulian F, Martini G, Gobber D, Agosto C, Gigante C, Zaccchello F. Comparison of intra-articular triamcinolone hexacetonide and triamcinolone acetonide in oligoarticular juvenile idiopathic arthritis. *Rheumatology* 2003;42:1254-9.
6. Eberhard BA, Sison MC, Gottlieb BS, Ilowite NT. Comparison of the intraarticular effectiveness of triamcinolone hexacetonide and triamcinolone acetonide in treatment of juvenile rheumatoid arthritis. *J Rheumatol* 2004;31:2507-12.



7. Remedios D, Martin K, Kaplan G, Mitchell R, Woo P, Rooney M. Juvenile chronic arthritis: diagnosis and management of tibio-talar and sub-talar disease. *Br J Rheumatol* 1997;36:1214-7.
8. Beukelman T, Arabshahi B, Cahill AM, Kaye RD, Cron RQ. Benefit of intraarticular corticosteroid injection under fluoroscopic guidance for subtalar arthritis in juvenile idiopathic arthritis. *J Rheumatol* 2006;33:2330-6.
9. Zulian F, Martini G, Gobber D, Plebani M, Zacchello F, Manners P. Triamcinolone acetonide and hexacetonide intra-articular treatment of symmetrical joints in juvenile idiopathic arthritis: a double-blind trial. *Rheumatology* 2004;43:1288-91.
10. Boehnke M, Behrend R, Dietz G, Küster RM. Intraarticular hip treatment with triamcinolone hexacetonide in juvenile chronic arthritis. *Acta Univ Carol Med (Praha)* 1994;40:123-6.
11. Broström E, Hagelberg S, Haglund-Akerlind Y. Effect of joint injections in children with juvenile idiopathic arthritis: evaluation by 3D-gait analysis. *Acta Paediatr* 2004;93:906-10.
12. Marti P, Molinari L, Bolt IB, Seger R, Saurenmann RK. Factors influencing the efficacy of intra-articular steroid injections in patients with juvenile idiopathic arthritis. *Eur J Pediatr* 2008;167:425-30.
13. Unsal E, Makay B. Intraarticular triamcinolone in juvenile idiopathic arthritis. *Ind Pediatr* 2008;45:995-7.
14. Arabshahi B, Dewitt EM, Cahill AM, Kaye RD, Baskin KM, Towbin RB, et al. Utility of corticosteroid injection for temporomandibular arthritis in children with juvenile idiopathic arthritis. *Arthritis Rheum* 2005;52:3563-9.
15. Beukelman T, Guevara JP, Albert DA, Sherry DD, Burnham JM. Usage of intra-articular corticosteroid injections for the treatment of juvenile idiopathic arthritis: a survey of pediatric rheumatologists in the United States and Canada. *Clin Exp Rheumatol* 2008;26:700-3.
16. Breit W, Frosch M, Meyer U, Heinecke A, Ganser G. A subgroup-specific evaluation of the efficacy of intraarticular triamcinolone hexacetonide in juvenile chronic arthritis. *J Rheumatol* 2000;27:696-702.
17. Cimmino MA, Grassi W, Cutolo M. Modern imaging techniques: a revolution for rheumatology practice. *Best Pract Res Clin Rheumatol* 2008;22:951-9.
18. Friedman S, Gruber MA. Ultrasonography of the hip in the evaluation of children with seronegative juvenile rheumatoid arthritis. *J Rheumatol* 2002;29:629-32.
19. Frosch M, Foell D, Ganser G, Roth J. Arthrosonography of hip and knee joints in the follow-up of juvenile rheumatoid arthritis. *Ann Rheum Dis* 2003;62:242-4.
20. Sureda D, Quiroga S, Arnal C, Boronat M, Andreu J, Casas L. Juvenile rheumatoid arthritis of the knee: evaluation with US. *Radiology* 1994;190:403-6.
21. Cellerini M, Salti S, Trapani S, D'Elia G, Falcini F, Villari N. Correlation between clinical and ultrasound assessment of the knee in children with mono-articular or pauci-articular juvenile rheumatoid arthritis. *Pediatr Radiol* 1999;29:117-23.
22. Doria AS, Kiss MH, Lotito AP, Molnar LJ, de Castro CC, Medeiros CC, et al. Juvenile rheumatoid arthritis of the knee: evaluation with contrast-enhanced color Doppler ultrasound. *Pediatr Radiol* 2001;31:524-31.
23. Shahin AA, el-Mofty SA, el-Sheikh EA, Hafez HA, Ragab OM. Power Doppler sonography in the evaluation and follow-up of knee involvement in patients with juvenile idiopathic arthritis. *Z Rheumatol* 2001;60:148-55.
24. El-Miedany YM, Housny IH, Mansour HM, Mourad HG, Mehanna AM, Megeed MA. Ultrasound versus MRI in the evaluation of juvenile idiopathic arthritis of the knee. *Joint Bone Spine* 2001;68:222-30.
25. Tynjälä P, Honkanen V, Lahdenne P. Intra-articular steroids in radiologically confirmed tarsal and hip synovitis of juvenile idiopathic arthritis. *Clin Exp Rheumatol* 2004;22:643-8.
26. Shanmugavel C, Sodhi KS, Sandhu MS, Sidhu R, Singh S, Katariya S, et al. Role of power Doppler sonography in evaluation of therapeutic response of the knee in juvenile rheumatoid arthritis. *Rheumatol Int* 2008;28:573-8.
27. Eich GF, Hallé F, Hodler J, Seger R, Willi UV. Juvenile chronic arthritis: imaging of the knees and hips before and after intraarticular steroid injection. *Pediatr Radiol* 1994;24:558-63.
28. Fedrizzi MS, Ronchezel MV, Hilario MO, Lederman HM, Sawaya S, Goldenberg J, et al. Ultrasonography in the early diagnosis of hip joint involvement in juvenile rheumatoid arthritis. *J Rheumatol* 1997;24:1820-5.
29. Kallio P, Ryöppy S, Jäppinen S, Siponmaa AK, Jääskeläinen J, Kunnamo I. Ultrasonography in hip disease in children. *Acta Orthop Scand* 1985;56:367-71.
30. Rydholm U, Wingstrand H, Egund N, Elborg R, Forsberg L, Lidgren L. Sonography, arthroscopy, and intracapsular pressure in juvenile chronic arthritis of the hip. *Acta Orthop Scand* 1986;57:295-8.
31. Kakati P, Sodhi KS. Clinical and ultrasound assessment of the knee in children with juvenile rheumatoid arthritis. *Ind J Pediatr* 2007;74:831-6.
32. Malattia C, Damasio MB, Magnaguagno F, Pistorio A, Valle M, Martinoli C, et al. Magnetic resonance imaging, ultrasonography, and conventional radiography in the assessment of bone erosions in juvenile idiopathic arthritis. *Arthritis Rheum* 2008;59:1764-72.
33. Karmazyn B, Bowyer SL, Schmidt KM, Ballinger SH, Buckwalter K, Beam TT, et al. US findings of metacarpophalangeal joints in children with idiopathic juvenile arthritis. *Pediatr Radiol* 2007;37:475-82.
34. Goldenstein C, McCauley R, Troy M, Schaller JG, Szer IS. Ultrasonography in the evaluation of wrist swelling in children. *J Rheumatol* 1989;16:1079-87.
35. Jank S, Haase S, Strobl H, Michels H, Häfner R, Missmann M, et al. Sonographic investigation of the temporomandibular joint in patients with juvenile idiopathic arthritis: a pilot study. *Arthritis Rheum* 2007;57:213-8.
36. Rooney ME, McAllister C, Burns JF. Ankle disease in juvenile idiopathic arthritis: ultrasound findings in clinically swollen ankles. *J Rheumatol* 2009;36:1725-9.
37. Karim Z, Wakefield RJ, Conaghan PG, Lawson CA, Goh E, Quinn MA, et al. The impact of ultrasonography on diagnosis and management of patients with musculoskeletal conditions. *Arthritis Rheum* 2001;44:2932-3.
38. Cardinal E, Chhem RK, Beauregard CG. Ultrasound-guided interventional procedures in the musculoskeletal system. *Radiol Clin North Am* 1998;36:597-604.
39. Koski JM. Ultrasound guided injections in rheumatology. *J Rheumatol* 2000;27:2131-8.
40. Grassi W, Farina A, Filippucci E, Cervini C. Sonographically guided procedures in rheumatology. *Semin Arthritis Rheum* 2001;30:347-53.
41. Sofka CM, Collins AJ, Adler RS. Use of ultrasonographic guidance in interventional musculoskeletal procedures: a review from a single institution. *J Ultrasound Med* 2001;20:21-6.
42. Balint PV, Kane D, Hunter J, McInnes IB, Field M, Sturrock RD. Ultrasound guided versus conventional joint and soft tissue fluid aspiration in rheumatology practice: a pilot study. *J Rheumatol* 2002;29:2209-13.
43. Schmidt WA, Schmidt H, Schicke B, Gromnica-Ihle E. Standard reference values for musculoskeletal ultrasonography. *Ann Rheum Dis* 2004;63:988-94.
44. Backhaus M, Burmester GR, Gerber T, Grassi W, Machold KP, Swen WA, et al. Working Group for Musculoskeletal Ultrasound in the EULAR Standing Committee on International Clinical Studies including Therapeutic Trials. Guidelines for musculoskeletal ultrasound in rheumatology. *Ann Rheum Dis* 2001;60:641-9.