Sarcoid Arthropathy

SUCHARITHA SHANMUGAM, MD; LAWRENCE H. BRENT, MD, Department of Medicine, Albert Einstein Medical Center, Philadelphia, Pennsylvania 19141, USA. Address reprint requests to Dr. L.H. Brent, Einstein Arthritis Center, 5501 Old York Road, Korman 103, Philadelphia, PA 19141. E-mail: brentl@einstein.edu. (J Rheumatol 2008;35:1892–3)

A 29-year-old African American man presented with pain, stiffness, and deformities involving both hands. He had an 11-year history of sarcoidosis presenting with pulmonary and neurological involvement and uveitis leading to blindness in the left eye. He noted pain, stiffness, swelling, and deformity of the hands for several years. On examination, the hands revealed swelling involving several proximal interphalangeal joints and severe deformity and resorption of the distal interphalangeal joints with dystrophic nail changes (Figure 1). Plain radiographs revealed multiple lytic lesions in both hands, involving predominantly the distal phalanges but also the proximal interphalangeal and metacarpophalangeal joints (Figure 2).

Sarcoid bone involvement occurs in 1%–13% of patients. It is most common in patients between the ages of 30 and 50 years and in African Americans[1]. Lytic lesions observed on plain radiographs are also called bone cysts. They present either as minute cortical defects or large punched-out cysts involving the heads of middle and proximal phalanges and less frequently in the metacarpal heads[2]. Cortical borders of the bones are usually well preserved. Distal tuft destruction can be seen in advanced cases. Subchondral lesions that extend into joint spaces can lead to joint involvement. Bone involvement is often associated with chronic fibrotic sarcoidosis in other sites and indicates a poor prognosis[2]. Treatment options for osseous sarcoidosis include antimalarial agents such as hydroxychloroquine and chloroquine, colchicine, and nonsteroidal antiinflammatory drugs[3]. Infliximab has been used in the treatment of refractory sarcoidosis, with pulmonary, skin, liver, central nervous system, and bone involvement[4,5].

REFERENCES

1. Judson MA. Extrapulmonary sarcoidosis. Semin Resp Crit Care Med 2007;28:83-101.
2. James DG, Neville E, Carstairs LS. Bone and joint sarcoidosis. Semin Arthritis Rheum 1976;6:53-81.
3. Wilcox A, Bharadwaj P, Sharma OP. Bone sarcoidosis. Curr Opin Rheumatol 2000;12:321-30.
4. Judson MA, Baughman RP, Costabel U, et al. Efficacy of infliximab in extrapulmonary sarcoidosis: results from a randomized trial. Eur Respir J 2008;31:1189-96. Epub 2008 Feb 6.
5. Doty JD, Mazur JE, Judson MA. Treatment of sarcoidosis with infliximab. Chest 2005;127:1064-71.

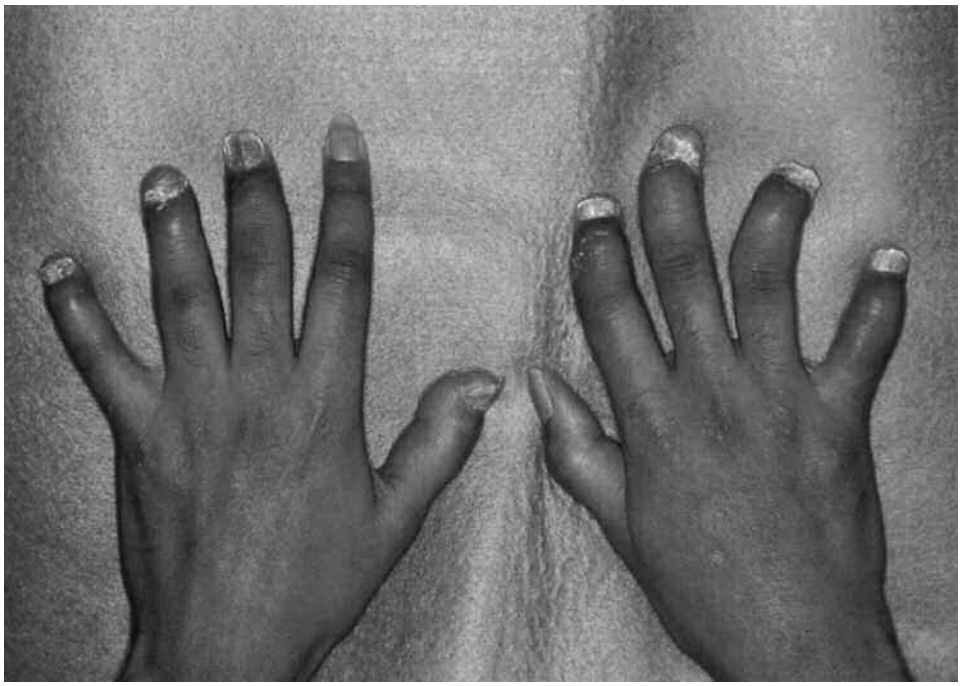

Figure 1. Sarcoid arthropathy resulting in severe deforming arthritis especially involving distal joints associated with dystrophic nail changes.

Personal non-commercial use only. The Journal of Rheumatology Copyright © 2008. All rights reserved.

Downloaded on April 24, 2024 from www.jrheum.org

Figure 2. Plain radiographs of the hands show a destructive arthritis associated with bony cysts due to sarcoidosis.

Personal non-commercial use only. The Journal of Rheumatology Copyright © 2008. All rights reserved.

Downloaded on April 24, 2024 from www.jrheum.org