

## Deep Venous Thrombosis Associated with Osteochondromatosis

JOHANNES W.G. JACOBS, MD, Associate Professor, Rheumatologist, Department of Rheumatology and Clinical Immunology, F02.27, University Medical Center, PO Box 85500, 3508 GA, Utrecht, The Netherlands. Address reprint requests to Dr. Jacobs. E-mail: J.W.G.Jacobs@UMCUtrecht.nl

In a 55-year-old man with an 8 year history of intermittent knee osteoarthritis (OA), deep venous thrombosis (DVT) was diagnosed in his right lower leg. There was no history of risk factors for thrombosis, such as prolonged bed rest or long air travel. On physical examination there were signs of DVT in the right lower leg and OA of the knees with a small amount of intraarticular fluid; and a large Baker's cyst orig-

inating from the right knee joint was suspected. Ultrasonography showed multiple hyperechogenic loose bodies in a Baker's cyst (Figure 1).

On radiographic examination, multiple round or ovoid ossified loose bodies were seen dorsally to the right knee joint, as were signs of osteoarthritis (Figure 2).

Osteochondromatosis is a rare and usually monoarticular

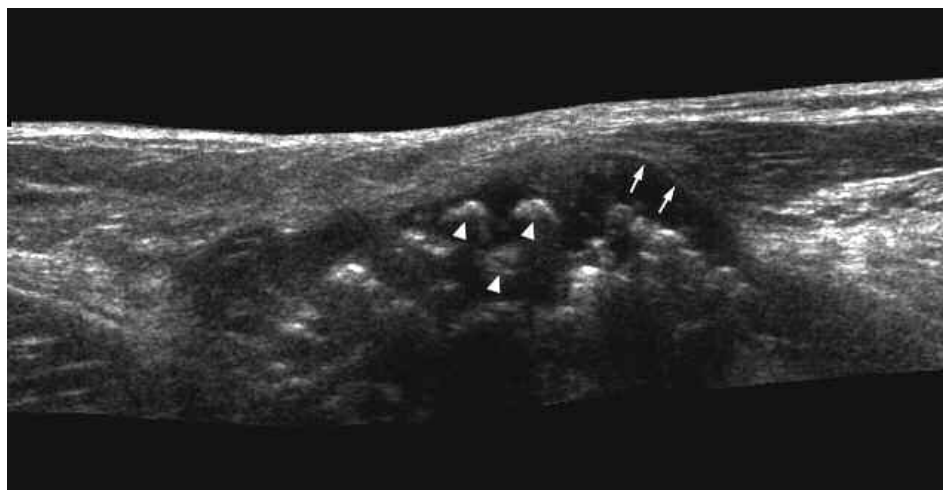


Figure 1. Ultrasound image showing hyperechogenic loose bodies in a Baker's cyst. Arrows: outer contour of Baker's cyst; arrowheads: loose bodies.

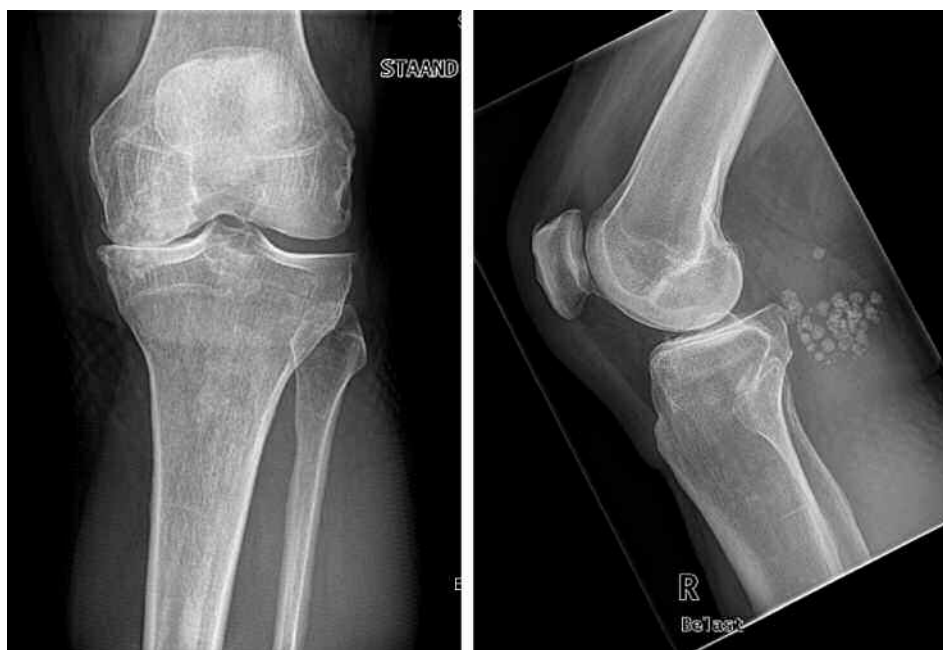

Figure 2. Radiography reveals multiple round or ovoid ossified loose bodies dorsally to the right knee joint and signs of osteoarthritis.

joint disorder, in which mesenchymal cells in the synovial sublining differentiate into chondroblasts that form cartilaginous nodules ranging in size from a few millimeters to several centimeters. These can be seen on arthroscopic examination of the synovium<sup>1</sup> and may undergo enchondral ossification and become detached to form intraarticular loose bodies. Osteochondromatosis of the knee, hip, shoulder, temporomandibular joint, and subacromial bursa has been described<sup>2-7</sup>. Osteochondromatosis occurs in adults, usually middle aged men, and can be primary or secondary, e.g., associated with OA. Signs and symptoms include joint pain, swelling, crepitus, and limitation of range of motion with locking of the joint. Malignant transformation has been reported in up to 5%<sup>8</sup>. In this patient, the osteochondromatosis with accumulation of the loose bodies in a Baker's cyst was associated with DVT, possibly by compression of the popliteal vein.

As therapy, synovectomy is indicated in the early stages and can be performed arthroscopically<sup>1</sup>. If untreated, secondary OA may ensue. On the other hand, osteochondromatosis may be secondary to OA.

## REFERENCES

1. Bruggeman NB, Sperling JW, Shives TC. Arthroscopic technique for treatment of synovial chondromatosis of the glenohumeral joint. *Arthroscopy* 2005;21:633.
2. Bouhaouala MH, Said W, Salah MH, Bouaziz N, Mourali S, Chaabane S. Isolated synovial chondromatosis of the subacromial bursa: report of a new case and review of the literature [French]. *J Radiol* 2006;87:65-8.
3. Church JS, Breidahl WH, Janes GC. Recurrent synovial chondromatosis of the knee after radical synovectomy and arthrodesis. *J Bone Joint Surg Br* 2006;88:673-5.
4. Godde S, Kusma M, Dienst M. Synovial disorders and loose bodies in the hip joint. Arthroscopic diagnostics and treatment [German]. *Orthopade* 2006; 35:67-76.
5. Huh JK, Park JY, Lee S, Lee SH, Choi SW. Synovial chondromatosis of the temporomandibular joint with condylar extension. *Oral Surg Oral Med Oral Pathol Oral Radiol Endod* 2006;101:e83-e88.
6. Van P, Wilusz PM, Ungar DS, Pupp GR. Synovial chondromatosis of the subtalar joint and tenosynovial chondromatosis of the posterior ankle. *J Am Podiatr Med Assoc* 2006;96:59-62.
7. Chillemi C, Marinelli M, de Cupis V. Primary synovial chondromatosis of the shoulder: clinical, arthroscopic and histopathological aspects. *Knee Surg Sports Traumatol Arthrosc* 2005;13:483-8.
8. Davis RI, Hamilton A, Biggart JD. Primary synovial chondromatosis: a clinicopathologic review and assessment of malignant potential. *Hum Pathol* 1998;29:683-8.