



INSTRUCTIONS FOR LETTERS TO THE EDITOR

Editorial comment in the form of a Letter to the Editor is invited. The length of a letter should not exceed 800 words, with a maximum of 10 references and no more than 2 figures or tables; and no subdivision for an abstract, methods, or results. Letters should have no more than 4 authors. Financial associations or other possible conflicts of interest should be disclosed.

Letters should be submitted via our online submission system, available at the Manuscript Central website: <http://mc.manuscriptcentral.com/jrheum> For additional information, contact the Managing Editor, The Journal of Rheumatology, E-mail: jrheum@jrheum.com

First Release April 15 2008

Chikungunya Viral Polyarthritits

To the Editor:

Chikungunya virus (CHIKV) polyarthritits can mimic rheumatoid arthritis (RA) by joint distribution and possible chronicity. It should be suspected in patients with RA-like features who have a history of travel to endemic areas, viremic symptoms, and rash. We describe one such case.

A 59-year-old previously healthy Canadian man was referred in mid-2006, with a 6-week history of symmetrical polyarthritits that was nonresponsive to nonsteroidal antiinflammatory drugs (NSAID). While visiting Mauritius 6 weeks earlier, he had developed fever, rigors, sweats, and intense polymyalgia. Over the ensuing 48 hours he developed severe polyarthralgia of his hands and feet, and an erythematous rash on his legs and feet. Except for the polyarthralgia, all symptoms abated in 4–5 days. On examination, he had synovitis at the metacarpophalangeal (MCP) joints, proximal interphalangeal joints, metatarsophalangeal (MTP) joints, and both wrists and ankles, and enthesitis at the insertions of both Achilles tendons (Figure 1).

Investigations revealed negative rheumatoid factor and antinuclear antibody, erythrocyte sedimentation rate 24 mm/h, C-reactive protein 3 mg/dl, and normal complete blood count, creatinine, electrolytes and liver function tests. CHIKV hemagglutination inhibition titer was elevated at 1:2560, and Dengue virus serology was negative. Hand radiographs showed no erosive changes.

Given his travel history, transient febrile illness, and positive CHIKV serology, he was diagnosed with CHIKV polyarthritits. He received 2 doses of 80 mg methylprednisolone intramuscularly 4 weeks apart, with good response. When reviewed 8 weeks after initial consultation, he had improved significantly, but synovitis of the wrists and MTP joints persisted. He was then given hydroxychloroquine 200 mg orally twice daily and prednisone orally 7.5 mg daily, the latter tapered in 6 weeks. On last followup, about 16 months after the acute illness, he was still having stress pain at the wrists and MCP, and was continued on hydroxychloroquine, with intermittent NSAID use. Repeat hand radiographs at that time showed no erosions, and anti-citrullinated peptide antibody was negative.

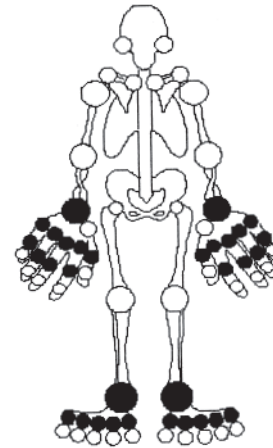


Figure 1. Affected joints (in black) in a patient with CHIKV polyarthritits presenting 6 weeks after onset of illness.

CHIKV is a mosquito-borne RNA virus, transmitted primarily by the *Aedes aegypti* and *Aedes albopictus* species¹. The illness is characterized by 3–7 days of high fever, headache, rash, myalgia, and severe arthralgia/arthritis, the hallmark of the disease. Arthropathy can be debilitating, accounting for the name “Chikungunya,” which, in the language of the Makonde (northern Mozambique), means “that which bends up.” It is mainly distal and symmetric, and can be persistent, with 12% of patients affected for 3–5 years in one study².

After many years of quiescence, CHIKV reemerged in early 2005 with an outbreak in the Comoros Islands. It subsequently spread to other Indian Ocean islands, including Reunion, where 255,000 cases were reported in just over one year following an outbreak in March 2005³. CHIKV was implicated in 228 deaths in the Reunion outbreak (about 1 per 1000 clinical cases)⁴. Several states in India were also affected throughout 2006, with more than 1.25 million clinical cases and attack rates reaching 45% in some areas⁵.

CHIKV infection has been reported in travelers returning from known outbreak areas to Europe, the United States, Canada, the Caribbean, and parts of South America⁶. It is now apparent that returning viremic travelers can precipitate local outbreaks. In late August 2007, authorities reported an outbreak in the Emilia Romagna region of Italy, with 254 potential cases reported as of mid-September 2007⁷. That outbreak was traced to a traveler returning from India. The globalization of *A. albopictus* to most tropical and temperate areas¹, including the Americas up to southern areas of Canada, renders pandemic potential to CHIKV.

Suspected cases should be confirmed by serology. Reverse transcription-polymerase chain reaction (RT-PCR) is useful during the initial viremic phase (Day 0 to Day 7), but classic serological methods are simpler (hemagglutination inhibition titer, complement binding, immunofluorescence, and ELISA)⁸. IgM is detectable (1–12 days) by ELISA immunofluorescent assay and persists up to 3 months. IgG is detected in convalescent samples and persists for years. The sensitivity and specificity of these tests are poorly established, however.

Treatment of CHIKV infection and arthritis has been primarily supportive with fluids, rest, NSAID, and other analgesics. A small, open, pilot study (1984) suggested improvement in the Ritchie articular index and morning stiffness with chloroquine phosphate⁹. To date, no vaccine or antiviral agent is available⁸. Infection is thought to confer lifelong immunity¹⁰.

In summary, CHIKV polyarthritits can mimic RA by joint distribution and possible chronicity. It should be suspected in patients with RA-like features who have a history of travel to endemic areas, viremic symptoms, and rash. Suspected cases should be confirmed via serology.

Although treatment is primarily supportive, our case suggests that patients with persistent arthropathy may benefit from corticosteroids and longer-term treatment with hydroxychloroquine. Intuitively, other disease-modifying antirheumatic drugs may be of benefit as well. This area would require controlled study, especially as the epidemic continues.

With continued travel to and immigration from areas with CHIKV outbreaks, the number of affected patients seen in non-endemic areas is likely to increase. Of greater concern is the pandemic risk posed by vector globalization. The emergence and rapid spread of West Nile virus in 1999 in the United States testify that arboviruses are a threat to developed countries with a temperate climate. Clinicians should be aware of viremic symptoms in travelers returning from endemic areas. Suspected cases of CHIKV should be immediately reported to public health authorities, and measures taken to avoid local outbreaks.

RAJ J. CARMONA, MBBS, Rheumatology Fellow; SAEED SHAIKH, FRCP, Assistant Clinical Professor, Rheumatology; NADER A. KHALIDI, FRCP, Associate Clinical Professor, Rheumatology, Department of Rheumatology, McMaster University, 240 James St. South, Hamilton, Ontario L8P 3B3, Canada. Address reprint requests to Dr. Carmona. E-mail: rajcarmona@hotmail.com

REFERENCES

1. Charrel R, de Lamballerie X, Raoult D. Chikungunya outbreaks — the globalization of vector-borne diseases. *N Engl J Med* 2007;356:769-71.
2. Brighton SW, Prozesky OW, de la Harpe AL. Chikungunya virus infection — a retrospective study of 107 cases. *S Afr Med J* 1983;63:313-5.
3. Public Health Agency of Canada. Travel health advisory. Outbreak of chikungunya virus: south west Indian Ocean and India. May 2006. [Internet. Cited February 28, 2008.] Available from: <http://news.gc.ca/web/view/en/index.jsp?articleid=215809&keyword=chikungunya>.
4. Institut de Veille Sanitaire. Chikungunya outbreak on Reunion: update on June 1 2006 [French]. June 2006. [Internet. Cited February 28, 2008.] Available from: http://www.invs.sante.fr/presse/2006/le_point_sur/chikungunya_reunion_020606/index.html.
5. World Health Organization. Epidemic and pandemic alert and response — Chikungunya in India. October 17 2006. [Internet. Cited February 28, 2008.] Available from: http://www.who.int/csr/don/2006_10_17/en/index.html.
6. Warner E, Garcia-Diaz J, Balsamo G, et al. Chikungunya fever diagnosed among international travelers — United States, 2005-2006. *MMWR Morbidity and Mortality Weekly Report*. 2006 September 29. [Internet. Cited February 28, 2008.] Available from: www.cdc.gov/mmwr/preview/mmwrhtml/mm5538a2.htm.
7. World Health Organization Regional Office for Europe. Communicable disease surveillance and response. Chikungunya in Emilia Romagna Region, Italy. 2007 September 16. [Internet. Cited February 28, 2008.] Available from: http://www.euro.who.int/surveillance/outbreaks/20070904_1.
8. Pialoux G, Gauzere B, Jaureguierry S, et al. Chikungunya, an epidemic arbovirus. *Lancet Infect Dis* 2007;7:319-27.
9. Brighton SW. Chloroquine phosphate treatment of chronic Chikungunya arthritis. An open pilot study. *S Afr Med J* 1984;66:217-8.
10. Centers for Disease Control and Prevention. Division of Vector-Borne Infectious Disease. Chikungunya fever fact sheet. November 29, 2007. [Internet. Cited February 28, 2008.] Available from: www.cdc.gov/ncidod/dvbid/Chikungunya/chikvfact.htm.

Increase in Plasma Levels of Adiponectin After Administration of Anti-Tumor Necrosis Factor Agents in Patients with Rheumatoid Arthritis

To the Editor:

Adiponectin, a fat-derived adipocytokine, is abundantly expressed in adipose tissue. It exhibits antiatherogenic, antidiabetic, and antiinflammatory effects¹. Blood adiponectin levels are low in subjects with metabolic syndrome and/or cardiovascular diseases, and its lowered levels in sera are closely associated with increased cardiovascular mortality in metabolic syndrome. Cardiovascular events are the most important cause of death also in patients with rheumatoid arthritis (RA), and improvement in mortality among patients with RA after the introduction of anti-tumor necrosis factor (TNF) agents² could be related to changes in the levels of adipocytokines. We evaluated plasma levels of adiponectin before and after treatment with anti-TNF agents in Japanese patients with RA.

Patients' characteristics are shown in Table 1. Infliximab was infused at 3 mg/kg body weight at Weeks 0, 2, and 6, and blood samples were obtained just before the first and third infusions. Etanercept was injected subcutaneously 25 mg twice weekly for more than 3 months. Blood samples were collected at baseline, 2 months after treatment, and at the latest visits, with a mean interval of 7.2 (SD 3.0) months (range 3–13 mo) after the first injection. Levels of total and high molecular weight (HMW) adiponectin were measured using ELISA kits (R&D Systems, Minneapolis, MN; and Linco Research, St. Charles, MO, USA, respectively). Total adiponectin levels were also measured in 37 patients with RA who were anti-TNF-naïve and whose disease activities were stable, and in 19 healthy controls [11 men, 8 women, mean age 36.3 ± 9.3 years (range 26–55)]. The Wilcoxon signed-rank test was employed for statistical analysis. Multiple regression analysis was performed to examine the relationship between adiponectin levels and baseline characteristics [sex, disease duration, age, body mass index, prednisolone dosage, methotrexate use, C-reactive protein, and Disease Activity Score (DAS28)]. A p value < 0.05 was considered significant.

The results are shown in Figure 1. Adiponectin levels of healthy controls (female, 13.5 ± 2.7 µg/ml; male, 7.8 ± 4.5 µg/ml) did not differ significantly from those of patients with RA at baseline (female, 12.9 ± 5.1 µg/ml; male, 8.6 ± 5.6 µg/ml). In both infliximab- and etanercept-treated groups, the levels of total and HMW adiponectin increased significantly only in female patients (Figure 1, A, C, and D, respectively). In patients with RA who were naïve to anti-TNF agents and in healthy controls, there were no changes in total adiponectin levels (Figure 1, E and F). Multiple regression analysis showed female sex and DAS28 were statistically significant independent variables (data not shown).

Serum levels of adiponectin are reported to be higher in patients with RA than in healthy controls³ and it is suggested that adiponectin could be proinflammatory *in vitro*⁴. However, these variables did not differ significantly in our population. The precise reason for the contradictory results is unknown, but it could be due to the differences in patients' demographics and/or ethnicity.

Etanercept increases serum levels of total adiponectin, but not HMW adiponectin, in patients with metabolic syndrome⁵. However, we found significant increases in plasma levels of both total and HMW adiponectin after treatment with infliximab and etanercept in Japanese women with RA. TNF and adiponectin mutually inhibit the production of each other in adipose tissue⁶, therefore, blockage of the action of TNF by anti-TNF agents is a reasonable explanation. Alleviation of joint inflammation *per se* by treatment might be another explanation for the increase in plasma adiponectin; insulin resistance is improved by anti-TNF agents in patients with inflammatory diseases such as RA and ankylosing spondylitis⁷, but not in the obese and patients with type 2 diabetes^{5,8}.

Härle, *et al* reported no influence on the serum levels of adiponectin in patients with RA treated with adalimumab⁹, which contradicts our results. In our results, adiponectin tended to increase more in the etanercept-treated group. Etanercept was administered much more frequently than inflix-

Table 1. Clinical characteristics of the patients.

Characteristic	Anti-TNF Agents		Control RA
	Infliximab	Etanercept	
No. of patients	56	28	37
Age, yrs (range)	52.4 ± 12.3 (25–77)	59.5 ± 13.6 (17–80)	57.5 ± 11.0 (34–75)
Females, n (%)	48 (85.7)	24 (85.7)	30 (81.1)
Duration of RA, yrs	7.9 ± 9.1	11.2 ± 9.8	10.8 ± 7.8
Body mass index, kg/m ² (median)	21.9 ± 2.9 (21.4)	21.3 ± 3.1 (20.7)	21.4 ± 2.7 (21.5)
Patients receiving PSL, n (%)	40 (71.4)	20 (71.4)	27 (75.0)
PSL dosage, mg/day	5.8 ± 2.4	5.7 ± 1.5	3.7 ± 2.6
Patients receiving MTX, n (%)	56 (100)	17 (60.7)	16 (44.4)
MTX dosage, mg/week	7.4 ± 1.4	7.1 ± 1.6	6.7 ± 2.0
Concomitant DMARD except MTX			
Bucillamine	2		9
Salazosulfapyridine	3	3	6
Leflunomide			1
Mizorbine			1
Tacrolimus			2
Actarit	2		

Data are expressed as mean ± SD or number (%). TNF: tumor necrosis factor; RA: rheumatoid arthritis; PSL: prednisolone; MTX: methotrexate; DMARD: disease modifying antirheumatic drugs.

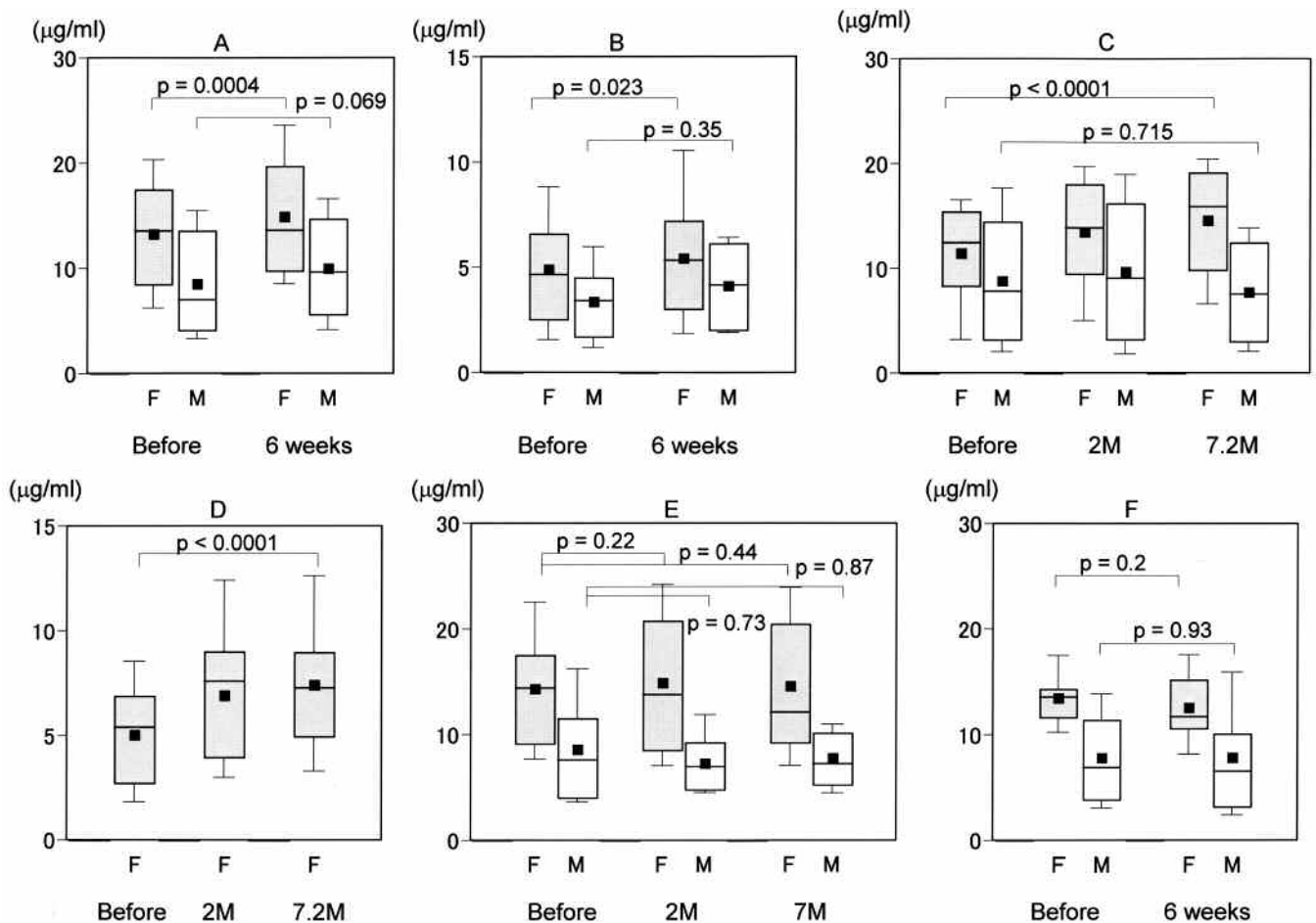


Figure 1. Changes in total and HMW adiponectin levels after anti-TNF treatment. A. Changes in total plasma adiponectin levels after treatment with infliximab. B. Changes in plasma HMW adiponectin level in the same group shown in A. C. Changes in total plasma adiponectin levels after treatment with etanercept. D. Changes in plasma HMW adiponectin levels in the same group shown in C. In 2 of 4 male patients in this group, plasma levels of HMW adiponectin were below the sensitivity limit of the ELISA, therefore, only data from female patients are depicted here. E. Total plasma adiponectin levels in anti-TNF-naive patients with RA, measured 7 months apart. F. Plasma total adiponectin levels in healthy volunteers measured 6 weeks apart. Each box represents 25th to 75th percentiles. Lines outside boxes represent 10th and 90th percentiles. Lines inside boxes represent median, solid squares represent the mean. F: female, M: male.

inab; adalimumab came in between. Blood was collected immediately before the next administration of anti-TNF agents and the adiponectin-increasing effects could have waned by that time. Another explanation is the difference between Härle's patient population and ours.

Interestingly, the increase of adiponectin was observed only in women in our study. The major reason for this could be that the number of men studied was too small, 8 and 4 male patients in the infliximab and etanercept groups, respectively. Sex differences might be fundamentally important to this issue; testosterone replacement therapy suppresses total and HMW adiponectin in hypogonadal men¹⁰. Recently, it was reported that TNF inhibitors reduce mortality only in women with RA². This coincides well with our results that only female patients showed increases in plasma adiponectin levels after treatment with anti-TNF agents. Whether this indicates cause and effect or is just a coincidence needs to be addressed in the future.

TAKAO NAGASHIMA, MD, PhD; HIKARU OKUBO-FORNBACHER, MD; YOKO AOKI, MD; YASUYUKI KAMATA, MD; HIROTAKA KIMURA, MD; TAKESHI KAMIMURA, MD, PhD; HIROYUKI NARA, MD; MASAHIRO IWAMOTO, MD, PhD, Assistant Professor; TAKU YOSHIO, MD, PhD, Associate Professor; HITOAKI OKAZAKI, MD, PhD, Associate Professor; SEIJI MINOTA MD, PhD, Professor of Medicine, Division of Rheumatology and Clinical Immunology, Department of Medicine, Jichi Medical University, Yakushiji 3311-1, Shimotsuke-shi, Tochigi, 329-0498, Japan. Address reprint requests to Dr. T. Nagashima. E-mail: naga4ma@jichi.ac.jp

Supported in part by a Jichi Medical University Young Investigator Award.

REFERENCES

1. Matsuzawa Y. The metabolic syndrome and adipocytokines. *FEBS Lett* 2006;580:2917-21.
2. Jacobsson LT, Turesson C, Nilsson JA, et al. Treatment with TNF blockers and mortality risk in patients with rheumatoid arthritis. *Ann Rheum Dis* 2007;66:670-5.
3. Otero M, Lago R, Gomez R, et al. Changes in plasma levels of fat-derived hormones adiponectin, leptin, resistin and visfatin in patients with rheumatoid arthritis. *Ann Rheum Dis* 2006;65:1198-201.
4. Ehling A, Schaffler A, Herfarth H, et al. The potential of adiponectin in driving arthritis. *J Immunol* 2006;176:4468-78.
5. Lo J, Bernstein LE, Canavan B, et al. Effects of TNF-alpha neutralization on adipocytokines and skeletal muscle adiposity in the metabolic syndrome. *Am J Physiol Endocrinol Metab* 2007;293:E102-9.
6. Maeda N, Shimomura I, Kishida K, et al. Diet-induced insulin resistance in mice lacking adiponectin/ACRP30. *Nat Med* 2002;8:731-7.
7. Kiortsis DN, Mavridis AK, Vasakos S, Nikas SN, Drosos AA. Effects of infliximab treatment on insulin resistance in patients with rheumatoid arthritis and ankylosing spondylitis. *Ann Rheum Dis* 2005;64:765-6.
8. Dominguez H, Storgaard H, Rask-Madsen C, et al. Metabolic and vascular effects of tumor necrosis factor-alpha blockade with etanercept in obese patients with type 2 diabetes. *J Vasc Res* 2005;42:517-25.
9. Härle P, Sarzi-Puttini P, Cutolo M, Straub RH. No change of serum levels of leptin and adiponectin during anti-tumour necrosis factor antibody treatment with adalimumab in patients with rheumatoid arthritis. *Ann Rheum Dis* 2006;65:970-1.
10. Xu A, Chan KW, Hoo RL, et al. Testosterone selectively reduces the high molecular weight form of adiponectin by inhibiting its secretion from adipocytes. *J Biol Chem* 2005;280:18073-80.

Graves' Disease in a Patient with Rheumatoid Arthritis During Treatment with Anti-Tumor Necrosis Factor- α

To the Editor:

In the last decade, blockade of tumor necrosis factor- α (TNF- α) has established itself as a new standard for treatment of rheumatoid arthritis (RA). In the late 1990s, the first clinical trials reported an impressive decrease in disease activity¹. However, the initial mood of victory was tempered by several serious adverse events, mainly infections, among them tuberculosis². In addition, some autoimmune conditions, such as lupus-like disease and multiple sclerosis^{3,4}, were reported. Increasing knowledge of treatment-related adverse events resulted in an annually updated consensus statement² and in pretreatment screening recommendations for tuberculosis⁵. Irrespective of this, longterm effects of anti-TNF- α are still not known, indicating that a continuous alertness for unexpected (rare) adverse events is warranted. We provide the first report of a patient who developed an autoimmune thyroid disease (ATD) during treatment with anti-TNF- α , 8 years after onset of treatment.

In our outpatient clinic, a 70-year-old woman developed Graves' disease (GD) after an infectious episode, while being treated with anti-TNF- α for active RA. She had had RA since 1976 and was initially treated with conventional disease modifying antirheumatic drug (DMARD) therapy, which was discontinued because of inefficacy. She entered a clinical trial in 1998 with adalimumab, which soon proved to be highly effective. During this long period of treatment, she had a number of adverse events, the majority being pneumonias. In the beginning of 2006, she was treated with broad-spectrum antibiotics because of pneumonia in the right middle lobe, visible on a chest radiograph. After normalization of both the acute-phase response and chest radiograph, she did not recover completely and kept feeling ill and tired, without any clear signs or symptoms of another disease. Notably, the efficacy of the anti-TNF- α treatment was gradually decreasing for the last 6 months. Additional laboratory research indicated a significant hyperthyroidism [thyroid-stimulating hormone (TSH) < 0.010 mE/l (reference 0.4–4.0 mE/l); free T4 60.9 pmol/l (reference 8–22 pmol/l)]. Importantly, no thyroid nodules, palpitations, increased sweating, hair loss, exophthalmia, heat sensitivity, or irritability were reported upon history and examination. In the peripheral blood, antibodies against both thyroperoxidase [143 IE/ml (reference < 101 IE/ml)] and thyroglobulin [668 IE/ml (reference < 345 IE/ml)] were present, indicating an ATD. Thyroid scintigraphy revealed GD as the cause of the hyperthyroidism. She was treated with thiamazole (30 mg/day) and propranolol and improved clinically with a fully normalized TSH and free T4 within 4 months. Treatment with adalimumab was stopped, because of inefficacy in combination with recurrent infections. GD is one of the most common causes of hyperthyroidism.

The development of GD is intriguing in our patient since she already had another autoinflammatory disease and was treated with anti-TNF- α . In the literature, the occurrence of ATD has been associated with RA⁶. However, no data are available on the relation with the treatment for RA. In our RA-comorbidity cohort⁷ (n = 1065), 4.6% of the patients (n = 49) had thyroid disease, including 1 patient with GD. This patient, however, had never been treated with anti-TNF- α before the onset of GD. In addition to RA, systemic lupus erythematosus, systemic sclerosis, Sjögren's syndrome, and poly/dermatomyositis have been reported to be associated with an increased prevalence of ATD⁶, suggesting an association of ATD with autoimmune diseases in general. The role of TNF- α in the pathogenesis of ATD is unclear. A potential role for TNF- α in GD has been suggested for Graves' ophthalmology based on histological examination⁸. Conflicting data have been reported on circulating TNF- α levels in GD during the disease course⁸⁻¹¹. In our patient, we did not observe clear signs and symptoms that identified GD. This may be because the typical clinical picture of GD is absent in a number of patients. Another explanation could be that TNF- α blockade may mask clinical signs and symptoms, leading to underreporting. This hypothesis is in accord with a recent study in which a positive effect of 12 weeks of treatment with etanercept on Graves' exoph-

thymia is reported in 10 patients¹². At the time the complaints of fatigue started in our patient, secondary inefficacy to anti-TNF- α treatment was developing, potentially due to formation of human anti-human antibodies. This might have resulted in an altered balance of the immune system, allowing GD to develop. More knowledge on the role of TNF- α in GD is needed to reveal how anti-TNF- α might have contributed to the development of GD in this case.

Ours is the first report of a patient diagnosed with GD during anti-TNF- α treatment. Whether there is a relationship between symptoms of GD and anti-TNF- α remains uncertain. This case once more indicates that thorough monitoring of patients who are treated with anti-TNF- α should be emphasized.

ANTOINE W.T. van LIESHOUT, MD; MARJONNE C.W. CREEMERS, MD, PhD, Department of Rheumatology; TIMOTHY R.D.J. RADSTAKE, MD, PhD, Departments of Rheumatology and General Internal Medicine; LAMMY D. ELVING, MD, PhD, Department of General Internal Medicine; PIET L.C.M. van RIEL, MD, PhD, Department of Rheumatology, Radboud University Nijmegen Medical Centre, Nijmegen, The Netherlands.

Address reprint requests to Dr. M. Creemers, UMC St. Radboud 470 Rheumatology Geert, Grootplein 8, 6500 HB Nijmegen, The Netherlands. E-mail: m.creemers@reuma.umcn.nl

We thank W. Kievit (Rheumatology, UMCN, Nijmegen) for collecting the clinical data from our prospective cohort database, and R. Rambaratsingh (Abbott, The Netherlands) for retrieving serum samples for determination of thyroid antibodies. We thank I. Klasen and J. Goërtz (ABTI, UMCN, Nijmegen) for measuring antibodies.

REFERENCES

1. Maini R, St. Clair EW, Breedveld F, et al. Infliximab (chimeric anti-tumour necrosis factor alpha monoclonal antibody) versus placebo in rheumatoid arthritis patients receiving concomitant methotrexate: a randomised phase III trial. ATTRACT Study Group. *Lancet* 1999;354:1932-9.
2. Hyrich KL, Silman AJ, Watson KD, Symmons DP. Anti-tumour necrosis factor alpha therapy in rheumatoid arthritis: an update on safety. *Ann Rheum Dis* 2004;63:1538-43.
3. Mohan N, Edwards ET, Cupps TR, et al. Demyelination occurring during anti-tumor necrosis factor alpha therapy for inflammatory arthritides. *Arthritis Rheum* 2001;44:2862-9.
4. Shakoor N, Michalska M, Harris CA, Block JA. Drug-induced systemic lupus erythematosus associated with etanercept therapy. *Lancet* 2002;359:579-80.
5. Furst DE, Breedveld FC, Kalden JR, et al. Updated consensus statement on biological agents, specifically tumour necrosis factor- α blocking agents and interleukin-1 receptor antagonist, for the treatment of rheumatic diseases, 2005. *Ann Rheum Dis* 2005;64 Suppl:iv2-14.
6. Biro E, Szekanez Z, Czirjak L, et al. Association of systemic and thyroid autoimmune diseases. *Clin Rheumatol* 2006;25:240-5.
7. Welsing P, Van Riel P, Franssen J, Kievit W. The relation of disease activity and methotrexate with the risk of cardiovascular disease in patients with rheumatoid arthritis [abstract]. In: Program, European League Against Rheumatism 2005 Annual Scientific Meeting; June 8-11, 2005; Vienna, Austria. Abstract OP0103.
8. Avunduk AM, Avunduk MC, Pazarli H, et al. Immunohistochemical analysis of orbital connective tissue specimens of patients with active Graves ophthalmopathy. *Curr Eye Res* 2005;30:631-8.
9. Celik I, Akalin S, Erbas T. Serum levels of interleukin 6 and tumor necrosis factor-alpha in hyperthyroid patients before and after propylthiouracil treatment. *Eur J Endocrinol* 1995;132:668-72.
10. Chopra IJ, Sakane S, Teco GN. A study of the serum concentration of tumor necrosis factor-alpha in thyroidal and nonthyroidal illnesses. *J Clin Endocrinol Metab* 1991;72:1113-6.
11. Diez JJ, Hernanz A, Medina S, Bayon C, Iglesias P. Serum concentrations of tumour necrosis factor-alpha (TNF-alpha) and soluble TNF-alpha receptor p55 in patients with hypothyroidism and hyperthyroidism before and after normalization of thyroid function. *Clin Endocrinol* 2002;57:515-21.
12. Paridaens D, van den Bosch WA, van der Loos TL, Krenning EP, van Hagen PM. The effect of etanercept on Graves' ophthalmopathy: a pilot study. *Eye* 2005;19:1286-9.

Effective Treatment of Steroid Refractory Adult-onset Still's Disease with Anakinra

To the Editor:

We describe rapid and sustained response of a 44-year-old woman with steroid-refractory adult-onset Still's disease (AOSD) to treatment with the interleukin 1 (IL-1) receptor antagonist anakinra as a first-line immunosuppressive therapy. The fast mode of action compared to conventional disease modifying antirheumatic drugs (DMARD) and tumor necrosis factor (TNF) inhibitors paired with an acceptable safety profile had prompted us to initiate a primary IL-1 receptor-blocking therapy. The rapid clinical response (cessation of fever within 12 h) and normalization of elevated acute-phase laboratory measures within a few days, together with recent data suggesting a crucial role of IL-1 in the pathogenesis of systemic-onset juvenile rheumatoid arthritis and AOSD, encourage first-line therapy with anakinra in these patients.

A 44-yr-old Caucasian woman was transferred to our emergency department from a community hospital due to a 2-week history of high-spiking fever recurring every day with temperature peaks of 41°C in the evening. The fever had not been responsive to treatment with antibiotics and was associated with systemic inflammatory symptoms including chills, ubiquitous arthralgias, myalgias, especially in the lower limbs, and a non-itching exanthema. Before the acute onset of the disorder, she had never experienced similar symptoms or any other health problem. She denied visits to foreign countries in the past months.

At examination we found a middle-aged woman in reduced condition with fever (41°C), pharyngitis, conjunctivitis, mild hepatosplenomegaly, heart rate of 100 per minute, and a systolic heart murmur. We noted a non-itching salmon-colored rash, which was most prominent at the extremities (Figure 1) and resolved within 48 h. Clinically, no joint swelling or synovitis was found. Laboratory testing revealed elevated C-reactive protein (CRP) and erythrocyte sedimentation rate, leukocytosis, normocytic anemia, elevated lactate dehydrogenase (LDH), and slightly raised liver enzymes (Figure 2). Suspecting AOSD, we observed extremely high levels of serum ferritin (51,100 ng/ml, normal range 10–120 ng/ml) and increased concentrations of soluble IL-2 receptors (6061 U/ml, normal range 223–710 U/ml). A bone marrow aspiration was performed to exclude an underlying malignancy and to detect possible hemophagocytosis. Cytology revealed solely a hypercellular bone marrow, and flow-cytometry showed an overexpression of CD38 and CD11c on monocytes, indicating immunoactivation and an activated T-cell population (partly HLA-DR+, CD38+, CD25+). Serological analysis indicated no infection with *Treponema pallidum*, *Borrelia*, parvovirus, rubella, HIV, hepatitis B virus (HBV), HCV, HAV, Epstein Barr virus, cytomegalovirus, or human herpesvirus 6. Blood cultures and urinalysis had been negative 3 times. A chest radiograph, abdominal ultrasound, computerized tomography scan of the perinasal sinuses, and transesophageal echocardiography were unremarkable, despite a mild splenomegaly and marginal insufficiency of the aortic valve. Serum electrophoresis showed a polyclonal gammopathy and an acute-phase response. No evidence was found for any other rheumatic disorder, and antinuclear antibodies and rheumatoid factors were negative.

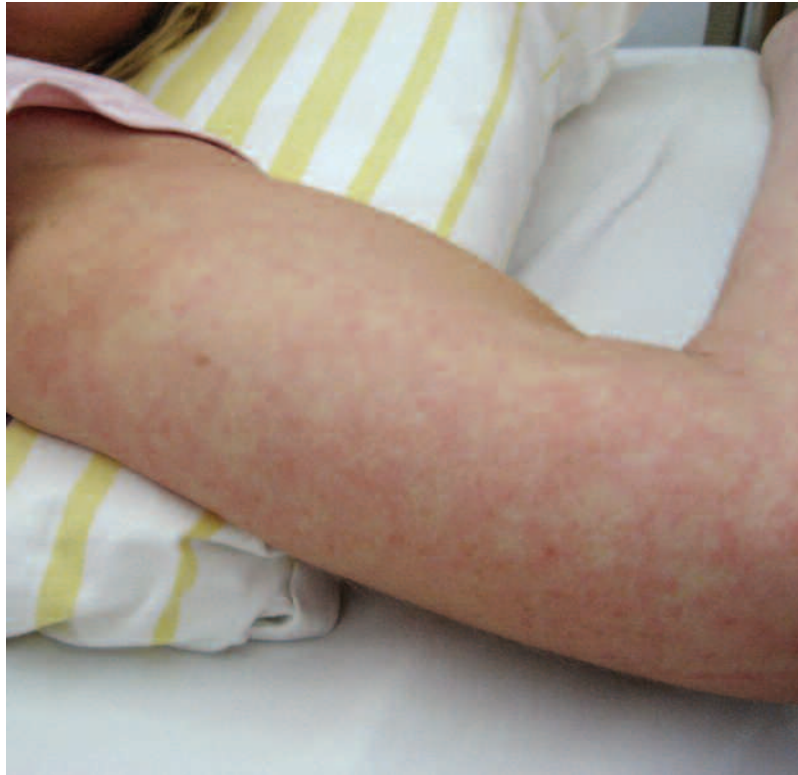

Figure 1. Non-itching salmon-colored rash on the right arm.

Since the patient met all classification criteria for AOSD¹ and no evidence for any other autoimmune disorder, malignancy, or infectious disease was found, steroid therapy with oral prednisolone 1 mg/kg body weight in addition to 1.5 g aspirin was initiated; this had no effect on signs and symptoms. After 3 days of unsuccessful oral prednisolone, intravenous pulses of 250 mg prednisolone per day were given. In spite of the dose escalation, the fever recurred every day with a peak in the evening and resistance to treatment with paracetamol, metamizol, and diclofenac.

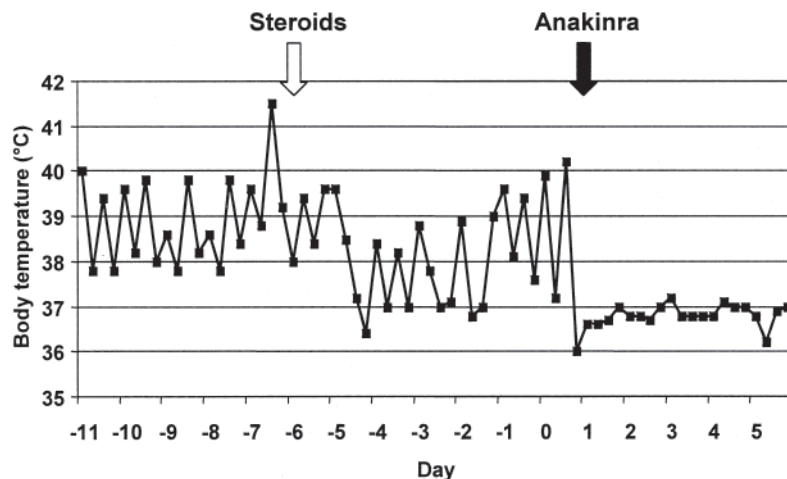
In view of this primary response failure to steroids, we decided to begin additional immunosuppressive therapy with anakinra. Indeed, within a few hours of a single subcutaneous application of 100 mg anakinra, the fever subsided and the patient experienced a complete remission of clinical symptoms, with normalization of laboratory findings after a few days (Figure 2). In parallel with the dramatic clinical improvement, the concentration of serum ferritin diminished rapidly from 51,100 to 3480 ng/ml after 10 days of therapy. Similarly, CRP, LDH, and leukocyte counts returned to normal values. Within 6 weeks of treatment the serum ferritin normalized completely. Prednisolone was tapered below 7.5 mg/day within 3 months. After 6 months, low-dose prednisolone was discontinued, and the time interval between the anakinra applications was gradually increased. Currently, after 8 months of treatment, the patient remains in remission receiving anakinra 100 mg subcutaneously 3 times weekly.

AOSD was first described by Bywaters in 1971² and represents a rare systemic inflammatory disorder with an estimated incidence of 1 to 2 cases per million inhabitants per year in Western Europe³. Due to this low incidence, few data on diagnosis and therapy derived from case reports and limited retrospective studies are available⁴. The etiology of AOSD remains elusive. Currently, the hypothesis of an exacerbated immune response based on a dysregulation of cytokine-mediated signaling cascades is favored⁵. IL-1 appears to play a central pathogenic role in systemic inflammatory disorders like juvenile and adult-onset Still's disease and periodic fever syndromes^{6,7}. IL-1-mediated inflammatory activity is mirrored by a remarkable elevation of ferritin level, which is upregulated by this proin-

flammatory cytokine⁸. After very promising effects of anti-IL-1 receptor therapy in children with systemic-onset juvenile rheumatoid arthritis⁷, successful treatment of AOSD with anakinra has been described in single case reports and a series of 4 patients who did not respond adequately to conventional DMARD or anti-TNF- α therapy (methotrexate, cyclosporine, sulfasalazine, infliximab, or etanercept)^{9,10}. Recently, Kallioliias, *et al* reported a prompt response and longterm steroid-sparing effect of anakinra in 3 patients that had previously required high steroid doses to control disease activity and in one patient who was refractory to methotrexate and etanercept¹¹.

Anakinra presents several advantages over conventional DMARD, with a faster response and a favorable safety profile with fewer opportunistic infections compared to TNF inhibitors; the prompt, sustained clinical response and subsequent improvement of laboratory measures in our patient encourage further use of anakinra as a first-line therapy in severe steroid refractory AOSD. Yet a longer observation time and larger series of patients will be needed to determine optimal length of treatment course, longterm outcomes, and complications with anakinra. Moreover, the cost-effectiveness of IL-1 receptor blockade for severe AOSD has to be evaluated, weighing the expected delay of response to DMARD in severe steroid-refractory AOSD compared to the costs of anakinra and potential side effects of both treatment strategies. Additional anti-IL-1 strategies with improved pharmacokinetics, such as the IL-1 TRAP (soluble IL-1 receptor that binds and neutralizes IL-1), are being developed and may provide clinical advantages due to a longer application interval.

JUDITH MAIER, MD; GABRIELE BIRKENFELD, MD; JOCHEN PFIRSTINGER, MD; JÜRGEN SCHÖLMECH, MD, Professor; Department of Internal Medicine I, University Hospital, Regensburg; MARTIN FLECK, MD, Professor, Department of Rheumatology/Clinical Immunology, Asklepios-Clinic, Bad Abbach; HILKE BRÜHL, PD, MD, Department of Internal Medicine I, University Hospital, Regensburg, Germany. Address reprint requests to Dr. H. Brühl, Department of



Parameter	normal range	Before Anakinra	With Anakinra	
			Day 10	Day 27
C-reactive protein	< 5 mg/l	175	1.33	< 0.5
WBC	4.8 – 10.8 /nl	16.67	6.91	4.13
Hemoglobin	11.7 - 15.7 g/dl	8.5	10	12
ESR	10/20 mm/1/2h	68/105	n.d.	15/30
Ferritin	10 - 291 ng/ml	51100	3480	478.7
Soluble IL-2-receptor	223 - 710 U/ml	6961	2207	1530
LDH	100 - 247 U/l	1426	356	240
AST	< 35 U/l	307	32	26
ALT	< 35 U/l	343	116	20

Figure 2. The patient's temperature in response to treatment with steroids and anakinra. Day 1 = start of treatment with anakinra. Table gives laboratory results before and after treatment with anakinra. WBC: white blood cell count; ESR: erythrocyte sedimentation rate; LDH: lactate dehydrogenase.

Internal Medicine I, University of Regensburg, 93042 Regensburg Germany. E-mail: hilke.bruehl@klinik.uni-regensburg.de

REFERENCES

1. Yamaguchi M, Ohta A, Tsunematsu T. Preliminary criteria for classification of adult onset Still's disease. *J Rheumatol* 1992;19:424-30.
2. Bywaters EGL. Still's disease in the adult. *Ann Rheum Dis* 1971;30:121-33.
3. Magadur-Joly G, Billaud E, Barrier JH. Epidemiology of adult Still's disease: estimate of the incidence by a retrospective study in west France. *Ann Rheum Dis* 1995;54:587-90.
4. Efthimiou P, Paik PK, Bielory L. Diagnosis and management of adult onset Still's disease. *Ann Rheum Dis* 2006;65:564-72.
5. Choi JH, Su CH, Lee YM, Suh YJ, Lee SK. Serum cytokine profiles in patients with adult onset Still's disease. *J Rheumatol* 2003;30:2422-7.
6. Dinarello CA. Blocking IL-1 in systemic inflammation. *J Exp Med* 2005;201:1355-9.
7. Pascual V, Allantaz F, Arce E, Punaro M, Banchereau J. Role of interleukin-1 (IL-1) in the pathogenesis of systemic onset juvenile idiopathic arthritis and clinical response to IL-1 blockade. *J Exp Med* 2005;201:1479-86.
8. Rogers JT, Bridges KR, Durmowicz GP, Glass J, Auron PE, Munro HN. Translational control during the acute phase response. Ferritin synthesis in response to interleukin-1. *J Biol Chem* 1990;265:14572-8.
9. Godinho Vasques FM, Santos Parreira MJ, Canas da Silva J. Refractory adult onset Still's disease successfully treated with anakinra. *Ann Rheum Dis* 2005;64:647-8.
10. Fitzgerald AA, LeClercq SA, Yan A, Homik JE, Dinarello CA. Rapid responses to anakinra in patients with refractory adult-onset Still's disease. *Arthritis Rheum* 2005;52:1794-803.
11. Kalliolias GD, Georgiou PE, Antonopoulos IA, Andonopoulos AP, Liossis SC. Anakinra treatment in patients with adult-onset Still's disease is fast, effective, safe and steroid sparing: experience from an uncontrolled trial. *Ann Rheum Dis* 2007;66:842-3.

Churg-Strauss Syndrome and Revascularization of the Hand: A Case Report

To the Editor:

Churg-Strauss syndrome (CSS) is characterized by allergic rhinitis, asthma, and peripheral blood eosinophilia resulting from systemic vasculitis of small to medium-size vessels¹. Although the exact cause of the syndrome is not known, it is felt to be due to an autoimmune process². Lack of easy diagnosis and full understanding of the disease process makes treatment

challenging. We describe a case of critical ischemia of the hand due to CSS in which a combination of medical and surgical treatment salvaged the hand.

A 54-year-old man presented with severe pain and black discoloration to several digits of both hands. In the 6 months prior to the referral he had noticed worsening of new Raynaud's symptoms in both hands. His history included a 12-year period of intermittent steroid-dependent asthma (both oral and inhaled steroid), a 6-year history of sinusitis with nasal polyposis resulting in 3 separate polypectomies, and a single episode of pulmonary hemorrhage requiring hospitalization 7 years earlier. He had a significant allergy to aspirin and nonsteroidal antiinflammatory medications resulting in a severe asthmatic reaction.

He was admitted to hospital with a diagnosis of critical ischemia of the second and third digits of the left hand. Left subclavian angiography was performed and the results were consistent with decreased flow through both the radial and ulnar arteries. There were occlusions of the radial artery at the level of the anatomical "snuff box" and the ulnar artery proximal to the wrist crease and extending into the superficial palmar arch (Figure 1). Nitroglycerin given intravenously for vasodilation resulted in improved but subnormal flow through both arteries. Other significant investigations showed hypereosinophilia (25% on differential of white blood cell count on more than 2 occasions), elevated immunoglobulin E to 156 g/l, elevated immunoglobulin G to 5.3 g/l, normal erythrocyte sedimentation rate and C-reactive protein, and negative antinuclear antibodies, cryoglobulins and antineutrophil cytoplasmic antibodies (both cANCA and pANCA). A computerized tomography scan of his sinuses revealed extensively thickened mucosa in both the maxillary and ethmoidal sinuses. He was given a trial infusion of 72 h of continuous intravenous alprastodil (20 µg/kg/min) without noticeable improvement. The anesthesia service was consulted and a stellate ganglion block was completed that did not provide any pain relief or improvement in symptoms.

Due to ongoing ischemia and pain he was referred to the plastic surgery service for possible surgical intervention. He underwent exploration and excision of thrombosed sections of both ulnar and radial arteries. The radial artery was reconstructed with an 8 cm interpositional vein graft at the level of the anatomical snuff box. The ulnar artery was reconstructed with a 13 cm interpositional vein graft extending from the distal one-third of the forearm to the palmar arch. A palmar digital sympathectomy of the common digital arteries in the palm was also completed in addition to the revascularization. During the same procedure otolaryngology performed bilateral nasal polypectomy for tissue samples.

Pathology specimens obtained in the operating room revealed numerous changes. The ulnar artery biopsy demonstrated a healed vasculitis

within the vessel wall and an organized (7 cm long and 2–3 cm wide) thrombus with many eosinophils present (Figure 2). The radial artery demonstrated near complete obliteration of the vascular lumen by recanalized organized thrombus. Nasal specimens showed pathological evidence of inflammatory polyps with absence of vasculitis.

Postoperatively the patient had complete resolution of pain and ischemic signs and symptoms in his left hand. At followup a year later he was doing remarkably well and his vasculitis continued to be in remission. His medications had been reduced to include azathioprine 100 mg orally daily, prednisone 5 mg daily equivalent dose, nifedipine 20 mg orally daily, and clopidogrel 75 mg orally daily. He had regained his sense of smell, which had been absent for more than 9 years. Both radial and ulnar pulses were palpable with no pain or symptoms. The function of his left hand was essentially normal with a normal Allen's test.

CSS is classified as a small-vessel vasculitis. In the last 15 years there have been only 4 reported cases of CSS complicated by forearm vessel occlusion³. This is the first case of Churg-Strauss vasculitis with occlusion of both the radial and ulnar arteries in which surgical revascularization was used to avoid amputation.

Although CSS is relatively rare and digital necrosis is uncommon, when critical ischemia occurs this frequently leads to amputation. The presence of thrombosis in the absence of ANCA positivity and other thrombophilic factors has been reported in both hypereosinophilic syndrome and CSS³⁻⁶. Our patient did not demonstrate elevated inflammatory markers at the time of presentation, but his pathology revealed healing vasculitis and active clot formation at the time of surgical revascularization. This made it extremely difficult to determine whether vasculitis, thrombosis, or the combination of the 2 were present. Clinically, he responded only when treated with a combination of medical and surgical therapy.

Raynaud's and digital necrosis have been documented in 3 cohorts of patients with CSS at a rate of 1%–6%⁷⁻⁹. Many other studies document generalized cutaneous changes in large categories but do not clearly indicate if digital necrosis is involved. In many cases angiography is not carried out and the extent of digital ischemia is determined clinically. In some cases with digital ischemia, medical therapy was sufficient to reverse the ischemia and avoid surgical intervention^{5,10}. However, there are several reported cases of digital necrosis in CSS in which the patients progress to amputation despite treatment^{3,8,11,12}. We have described a patient with CSS who developed critical digital ischemia that failed all medical therapies for revascularization. The combination of surgical and postsurgical medical therapy allowed return of normal function of this patient's hand.

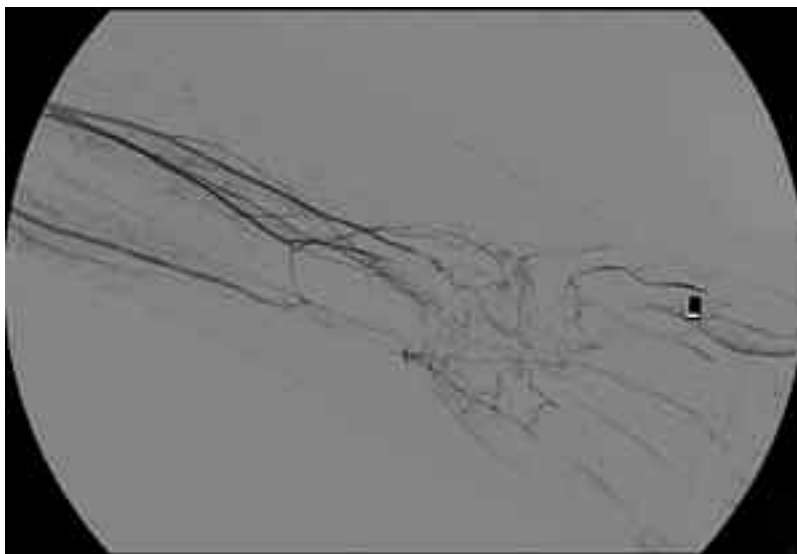

Figure 1. Left subclavian arteriogram showing occluded radial and ulnar arteries.

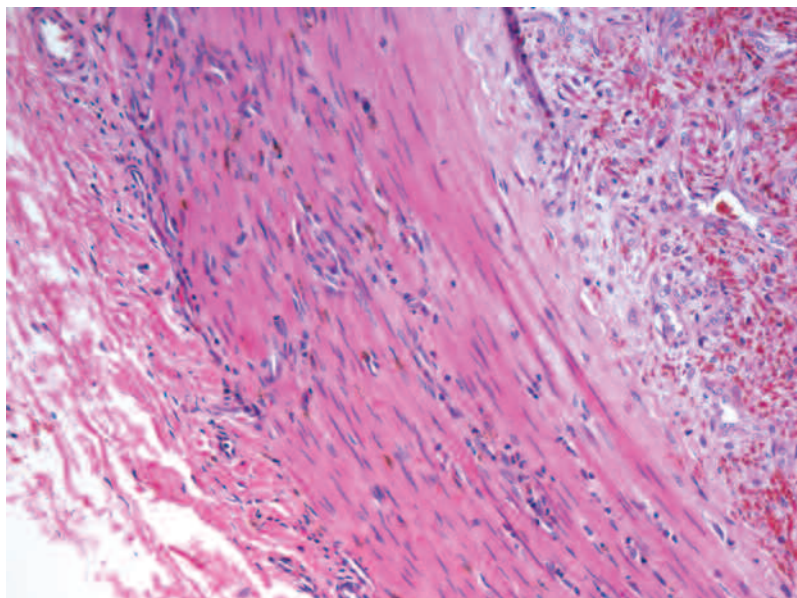


Figure 2. Pathology specimen of eosinophils infiltrating the arterial wall.

ANNIKA CARD, MD, Division of Plastic Surgery, Department of Surgery; NADER KHALIDI, MD, Section of Rheumatology, McMaster University, Hamilton; MARIE CLEMENTS-BAKER, MD, Department of Medicine, Queen's University, Kingston; ACHILLES THOMA, MD, Division of Plastic Surgery, Department of Surgery, McMaster University, 101-206 James St. South, Hamilton, Ontario L8P 3A9, Canada. Address reprint requests to Dr. Thoma. E-mail: athoma@mcmaster.ca

REFERENCES

- Masi AT, Hunder GG, Lie JT, et al. The American College of Rheumatology 1990 criteria for the classification of Churg-Strauss syndrome (allergic granulomatosis and angiitis). *Arthritis Rheum* 1990;33:1094-100.
- Jennette JC, Falk RJ, Andrassy K, et al. Nomenclature of systemic vasculitides. Proposal of an international consensus conference. *Arthritis Rheum* 1994;37:187-92.
- Otani Y, Anzai S, Shibuya H, et al. Churg-Strauss syndrome manifested as necrosis of fingers and toes and liver infarction. *J Dermatol* 2003;30:810-5.
- Inui S, Itami S, Iwai C, Yoshikawa K. Churg-Strauss syndrome involving medium-sized arteries. *J Dermatol* 2001;28:161-4.
- Oppliger R, Gay-Crosier F, Dayert E, Hauser C. Digital necrosis in a patient with hypereosinophilic syndrome in the absence of cutaneous eosinophilic vasculitis. *Br J Dermatol* 2001;144:1087.
- Hachulla E, Hatron PY, Janin A, Robert Y, Devulder B. Digital arteries, thrombosis and hypereosinophilic syndrome: an uncommon complication [French]. *Rev Med Interne* 1995; 16:434-6.
- Guillevin L, Cohen P, Gayraud M, Lhote F, Jarrousse B, Casassus P. Churg-Strauss syndrome: Clinical study and long-term follow-up of 96 patients. *Medicine* 1999;78:26-37.
- Jang K, Lim Y-S, Choi J-H, Sung KJ, Moon KC, Koh JK. Hypereosinophilic syndrome presenting as cutaneous necrotizing vasculitis and Raynaud's phenomenon complicated by digital gangrene. *Br J Dermatol* 2000;143:641-4.
- Mouthon L, Le Toumelin P, Andre MH, Gayraud M, Casassus P, Guillevin L. Polyarteritis nodosa and Churg-Strauss angiitis characteristics and outcome in 38 patients over 65. *Medicine* 2002;81:27-40.
- Mouthon L, Khaled M, Cohen P, Guillevin L, Mouthon L, Subra JF. Systemic small sized vessel vasculitis after massive antigen inhalation. *Ann Rheum Dis* 2001;60:903-4.
- Sharma BK, Daga MK, Sharma M. A limited form of Churg-Strauss syndrome presenting without asthma and eosinophilia. *Med J Aust* 2004;181:498-9.
- Liozon E, Delaire L, Lacroix P, et al. Raynaud syndrome complicated by digital gangrene during treatment with interferon-alpha [French]. *Rev Med Interne* 1997;18:316-9.

Correction

Emami Nia A, Nabavi M, Mousavi Nasab M, Kashef S. Central nervous system involvement in Blau syndrome: A new feature of the syndrome? *J Rheumatol* 2007;34:2504-5. The name of the first author should be Emaminia A. We regret the error.

Greenberg JD, Reddy SM, Schloss SG, Kurucz OS, Bartlett SJ, Abramson SB, Bingham CO III. Comparison of an in vitro tuberculosis interferon- γ assay with delayed-type hypersensitivity testing for detection of latent *Mycobacterium tuberculosis*: A pilot study in rheumatoid arthritis. *J Rheumatol* 2008;35:776-81. Text of the legend for Figure 1 should read, "Presence of anergy was defined as no individual skin test result demonstrating > 2 mm induration in the orthogonal diameter." We regret the error.