

# Correspondence



# Letters



## INSTRUCTIONS FOR LETTERS TO THE EDITOR

Editorial comment in the form of a Letter to the Editor is invited. The length of a letter should not exceed 800 words, with a maximum of 10 references and no more than 2 figures or tables; and no subdivision for an abstract, methods, or results. Letters should have no more than 4 authors. Financial associations or other possible conflicts of interest should be disclosed.

Letters should be submitted via our online submission system, available at the Manuscript Central website: <http://mc.manuscriptcentral.com/jrheum> For additional information, contact the Managing Editor, The Journal of Rheumatology, E-mail: [jrheum@jrheum.com](mailto:jrheum@jrheum.com)

### Intrinsic Muscle Spasm of the Hand: Bunnell's Sign

To the Editor:

I read with interest the recent article by Taylor and Eranki<sup>1</sup>. However, I would point out that the anatomical location of "Extensor hood" in Figure 1 is incorrect. The corrected location is shown here (Figure 1).

HAJIME ISHIKAWA, MD, Department of Rheumatology, Niigata Rheumatic Center, Shibata City, Niigata, Japan.  
E-mail: [med@ra-center.com](mailto:med@ra-center.com)

#### REFERENCE

1. Taylor TH, Eranki KP. Intrinsic muscle spasm of the hand; Bunnell's sign. *J Rheumatol* 2007;34:1332-5.

### Dr. Taylor replies

To the Editor:

Although I agree with Dr. Ishikawa's point, regarding a more diffuse depiction of the extensor hood, I think this may be difficult to convey by the corrected figure, which localizes the fibrous tissue comprising the hood as a more lateral structure. We did try to bracket this wide structure, as a way of acknowledging its more extensive nature, and admittedly this is a cartoon<sup>1</sup>. It is important to retain the concept of a more dorsal attachment to help readers conceptualize Bunnell's sign.

THOMAS TAYLOR, MD, Department of Medicine, White River Junction VA Hospital, White River Junction, Vermont, USA.  
E-mail: [Thomas.Taylor@Dartmouth.edu](mailto:Thomas.Taylor@Dartmouth.edu)

#### REFERENCE

1. Taylor TH, Eranki KP. Intrinsic muscle spasm of the hand; Bunnell's sign. *J Rheumatol* 2007;34:1332-5.

### Systemic Nocardiosis in a Case of Rheumatoid Arthritis Treated with Tumor Necrosis Factor Blockers

To the Editor:

Increasing severe or opportunistic infection risk is a major concern with the use of tumor necrosis factor (TNF- $\alpha$ ) blockers in chronic inflammatory diseases<sup>1</sup>. Among granulomatous infections, cases of nocardiosis are rarely reported. Systemic nocardiosis may have a poor prognosis. We describe such a case in a patient with longstanding rheumatoid arthritis (RA) treated with anti-TNF agents.

A 63-year-old Caucasian man, without concomitant disease, was diagnosed with erosive, rheumatoid factor-positive RA in 1990, and then treated with continuous prednisone (12 to 20 mg/day). After failure of several conventional disease modifying antirheumatic drugs, he was treated with methotrexate (MTX; 10 to 15 mg/wk) for 7 years, starting in 2000 (in association with cyclosporine for 2 years). In November 2006, lack of efficacy of this regimen (Disease Activity Score 28: 6.2) prompted initiation of anti-TNF therapy (etanercept, 3 mo treatment, and then adalimumab, 4 mo), in combination with MTX, without response (DAS 28: 6.5). Skin tuberculin test was negative and chest radiograph was normal before start of anti-TNF therapy. This treatment (anti-TNF and MTX) was stopped in July 2007 due to occurrence of subcutaneous nodules of the trunk (a biopsy of one nodule revealed a pyogenic granuloma), pulmonary nodules (Figure 1), and above all neurological signs: headache, vertigo, and cerebellar dysarthria. Investigations with computed tomography (CT) and magnetic resonance imaging led to discovery of 2 lesions, one in the right parietal region of brain, the other in the cerebellum, both with edema and mass effect (Figure 2). No motor deficiency was noted. Fever was 38°C. C-reactive protein (CRP) was 122 mg/l, white blood cell count 6/l. Cerebrospinal fluid was normal; investigations for tuberculosis, viruses (HIV, hepatitis B and C, herpes virus, picornavirus, enterovirus), cysticercosis, bilharziosis, and toxoplasmosis were negative. There were no antinuclear antibodies. Surgical brain biopsy revealed a pyogenic abscess and presence of *Nocardia farcinica*. CT scan revealed several abdominal nodules. He was then treated with antibiotics (amikacin, imipenem, and cilastatine), initially combined with high-dose, short-term steroid therapy (3 mg/kg/day) for management of cerebral edema. At 3 months, a moderate flare of RA prompted reintroduction of prednisone 10 mg/day, while antibiotics (linezolid, then sulfamethoxazole and trimethoprim) were continued. At this

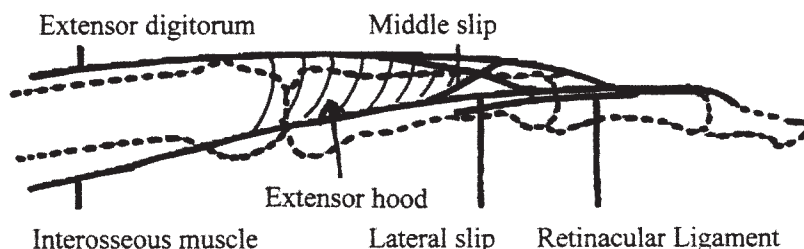


Figure 1. Redrawn figure shows anatomical location of the extensor hood.

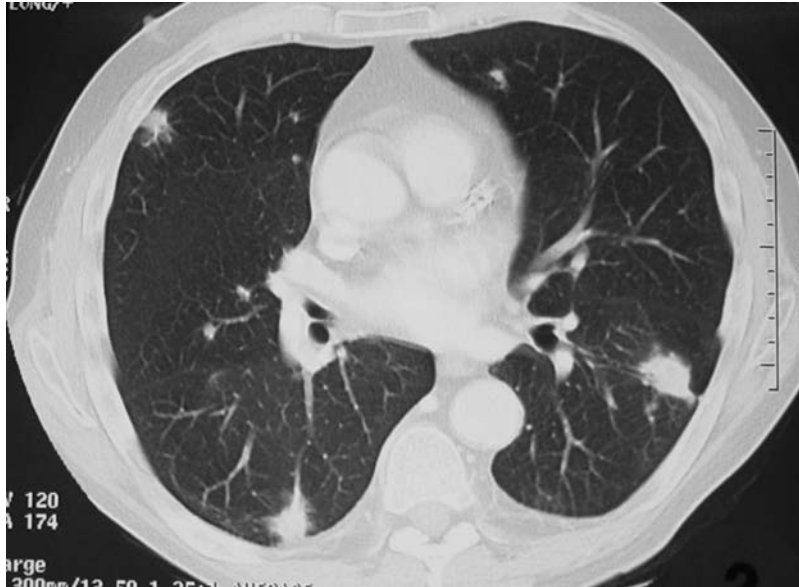

Figure 1. Thoracic CT scan shows multiple dense nodules in the pulmonary fields.

time, he exhibited progressive and moderate improvement of diplopia and dysarthria, while CT scan showed disappearance of the thoracic and abdominal nodules, and reduction of the cerebral tumoral mass. CRP had diminished to 44 mg/l.

In this patient with longstanding RA under prolonged immunosuppressive treatment (prednisone 17 yrs, MTX 7 yrs, anti-TNF agents 7 months), the diagnosis was determined of systemic nocardiosis (lung, skin, abdomen, and brain). Nocardiosis is caused by an opportunistic aerobic, Gram-positive, filamentous bacteria of the order of Actinomycetales. The most common *Nocardia* species are *N. asteroides*, *N. brasiliensis*, and *N. otitidis-caviautum*, with long incubation periods<sup>2</sup>. Contamination is mostly due to inhalation or through the skin. This rare infection occurs mainly in immunocompromised patients (immunosuppressive therapy, autoimmune diseases, transplanted patients, HIV infection)<sup>2-5</sup>. Systemic nocardiosis is defined by the presence of 2 or more foci of infection<sup>2</sup>, as in our case. The lung is the most frequent primary site of systemic nocardiosis (60% to 80% of cases)<sup>2</sup>, and cerebral or other locations may occur in 20% to 40% of cases. Central nervous system (CNS) involvement is responsible for the worst prognosis, with a 75% rate of mortality in lupus patients<sup>3</sup>. Septic arthritis<sup>2</sup> and vertebral osteomyelitis<sup>6</sup> have also been described.

TNF plays a role in the clearance of *Nocardia* in animal models<sup>7</sup>. Thus, anti-TNF therapy may favor *Nocardia* infection and dissemination. Nocardiosis under anti-TNF treatment has been rarely reported. In the US survey, 8 cases were identified among about 300,000 patients treated with anti-TNF agents<sup>8,9</sup>. Cutaneous *Nocardia* was also described in a case of RA treated with infliximab, MTX, and corticosteroids<sup>10</sup>.

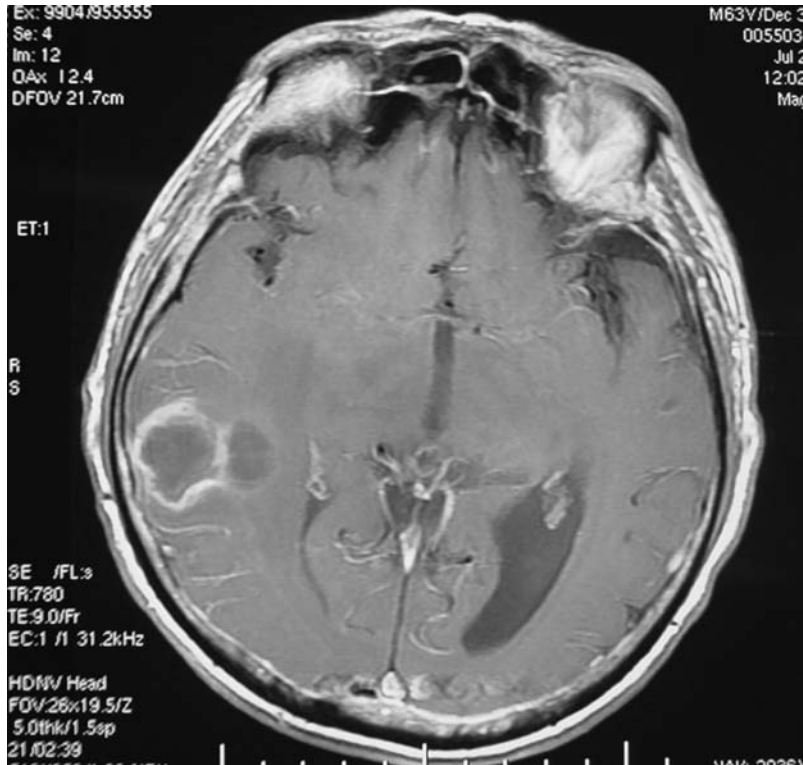
Nevertheless, it must be pointed out that nocardiosis may be diagnosed in RA patients treated with only corticosteroids and MTX<sup>11-13</sup> or corticosteroids alone<sup>14</sup>. Due to the slow growth of *Nocardia*, it is possible that anti-TNF agents in our case acted as an accelerating and disseminating factor within a previously undiagnosed nocardiosis, favored by the combination of longstanding corticosteroid and MTX therapy.

The occurrence of CNS disease in a case of a chronic inflammatory condition treated with immunosuppressive agents may be related to various diagnoses. This emphasizes the need for a precise diagnostic procedure<sup>15</sup>. The goal is the isolation of the microorganism, which may require cerebral biopsy.

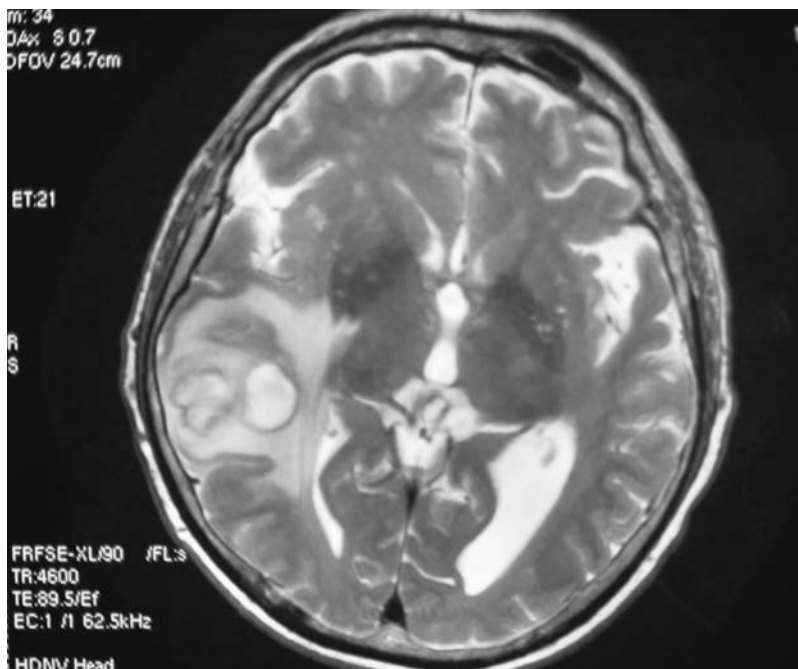
DANIEL WENDLING, MD, PhD, Department of Rheumatology;  
 MUHSEN MURAD, MD, Department of Neurology;  
 SANDRA MATHIEU, MD, Department of Rheumatology;  
 ERIC BERGER, MD; LUCIEN RUMBACH, MD, Department of Neurology, University Teaching Hospital Minjoz, and University of Franche-Comté, 25030 Besançon, France. Address reprint requests to Prof. D. Wendling, e-mail: dwendling@chu-besancon.fr  
 We thank Patrick Boiron, *Laboratoire de Mycologie appliquée, faculté de Pharmacie, Lyon*, who performed typing of the nocardia.

#### REFERENCES

1. Strangfeld A, Listing J. Bacterial and opportunistic infections during anti-TNF therapy. *Best Pract Res Clin Rheumatol* 2006;20:1181-95.
2. Charfeddine K, Kharrat M, Yaich S, et al. Systemic nocardiosis with multiple brain abscesses in a renal transplant recipient: successfully treated with antibiotics alone. *Saudi J Kidney Dis Transpl* 2002;13:498-500.
3. Justiniano M, Glorioso S, Dold S, Espinoza LR. Nocardia abscesses in a male patient with SLE: successful outcome despite delay in diagnosis. *Clin Rheumatol* 2007;26:1020-2.
4. Kilincer C, Hamamcioglu MK, Simsek O, et al. Nocardial brain abscesses: review of clinical management. *J Clin Neurosci* 2006;13:481-5.
5. Pamuk GE, Pamuk ON, Tabak F, Mert A, Ozturk R, Aktuglu Y. Systemic Nocardia infection in a patient with Behçet's disease. *Rheumatology Oxford* 2001;40:597-9.
6. Laurin JM, Resnick CS, Wheeler D, Needleman BW. Vertebral osteomyelitis caused by *Nocardia asteroides*: report and review of the literature. *J Rheumatol* 1991;18:455-8.
7. Silva CL, Faccioli LH. Tumor necrosis factor and macrophage activation are important in clearance of *Nocardia brasiliensis* from the livers and spleens of mice. *Infect Immun* 1992;60:3566-70.
8. Wallis RS, Broder MS, Wong JY, Hanson ME, Beenhouwer DO. Granulomatous infectious diseases associated with tumor necrosis factor antagonists. *Clin Infect Dis* 2004;38:1261-5.
9. Wallis RS, Broder M, Wong J, Beenhouwer D. Granulomatous infections due to tumor necrosis factor blockade: correction. *Clin*



A



B

Figure 2. Brain MRI. A. T1-weighted sequence shows right temporoparietal lesion with peripheral contrast uptake. B. T2-weighted sequence shows circular lesion with significant edema, and mass effect on the fourth ventricle.

- Infect Dis 2004;39:1254-5.
10. Fabre S, Gibert C, Lechiche C, Jorgensen C, Sany J. Primary cutaneous *Nocardia otitidiscaviarum* infection in a patient with rheumatoid arthritis treated with infliximab. *J Rheumatol* 2005;32:2432-3.
  11. Keegan JM, Byrd JW. Nocardiosis associated with low dose methotrexate for rheumatoid arthritis. *J Rheumatol* 1988;15:1585-6.
  12. Gruberg L, Thaler M, Rozenman J, Bank I, Pras M. *Nocardia*

asteroides infection complicating rheumatoid arthritis. *J Rheumatol* 1991;18:459-61.

13. Corneliessen JJ, Bakker LJ, van der Veen MJ, Rozenberg-Arska M, Bijlsma JWJ. Nocardia asteroides pneumonia complicating low dose methotrexate treatment of refractory rheumatoid arthritis. *Ann Rheum Dis* 1991;50:642-4.
14. Yoshida K, Bandoh S, Fujita J, Tokuda M, Negayama K, Ishida T. Pyothorax caused by Nocardia otitidiscaviarum in a patient with rheumatoid arthritis. *Intern Med* 2004;43:615-9.
15. Warnatz K, Peter HH, Schumacher M, et al. Infectious CNS disease as a differential diagnosis in systemic rheumatic diseases: three case reports and a review of the literature. *Ann Rheum Dis* 2003;62:50-7.

## Nocardia Infection with Adalimumab in Rheumatoid Arthritis

To the Editor:

There has been an increased rate of infections with the widespread use of immunomodulators in rheumatological diseases. With rheumatological conditions improving, adverse effects such as opportunistic infections<sup>1-4</sup> are appearing with compromised immunity. This report describes a patient who underwent therapy with the tumor necrosis factor (TNF) blocker adalimumab and then developed nocardia infection of lungs.

A 75-year-old man with a history of chronic obstructive pulmonary disease (COPD), coronary artery disease, and rheumatoid arthritis (RA) presented to hospital for intermittent left and right side chest pain and shortness of breath for several days. He was found to have no evidence of coronary event and had negative stress and cardioperfusion scans. A computerized tomography (CT) scan of chest showed no pulmonary embolism or pneumonia. He was treated with steroids for exacerbation of COPD. He improved clinically, but later developed focal right-side continuous pain and had low oxygen saturation and shallow breathing from pleuritic pain; he had a temperature of 38°C. He was transferred to our tertiary care hospital for further management. Laboratory investigations showed white blood cell count 26,200 cells/dl, and chest radiograph (Figure 1) and repeat

CT scan (Figures 2 and 3) showed organizing pneumonia impinging on the pleura on the right side. Since he had been in hospital > 48 hours and initial CT scan did not show pneumonia, he was started on vancomycin and cefepime. He did not improve clinically and continued to require increased oxygen support. A review of his history showed that he had started adalimumab therapy for refractory RA 4 months previously, with subsequent improvement in arthritic symptoms. Blood cultures were negative, but sputum cultures at this time were positive for *Nocardia asteroides* (later confirmed immunologically) and *Aspergillus fumigatus*. His antibiotic therapy was therefore changed to trimethoprim/sulfamethoxazole and voriconazole to treat both Nocardia and Aspergillus. He improved dramatically. Adalimumab was withdrawn. He was then discharged home with laboratory values close to baseline.

TNF blockers include the monoclonal antibodies infliximab and adalimumab and the soluble TNF receptor etanercept. The antibodies bind both monomeric and trimeric TNF. However, they differ in that infliximab has variable regions of mouse anti-TNF, whereas adalimumab has human variable regions.

The infections associated with TNF blockade describe disseminated forms of diseases that otherwise are quite rare. Data are available mostly for infliximab-associated infections<sup>2,3,5-7</sup>. The infection risk associated with infliximab may reflect its structure as an antibody. The binding of infliximab to soluble trimeric TNF may result in the formation of large immune complexes, which may activate complement and otherwise perturb immune function. Infliximab binding may also crosslink membrane-associated TNF, which has been reported to cause T cell apoptosis by reverse signaling. In contrast, the 1:1 binding requirement of etanercept to trimeric TNF prohibits these phenomena. If effects on T cell activation and interferon- $\gamma$  production account for the increased risk for tuberculosis (TB) associated with infliximab<sup>5</sup>, a similar risk with adalimumab should become apparent as clinical experience accumulates.

Infections associated with TNF blockers include TB<sup>5</sup>, histoplasmosis, cryptococcosis<sup>1</sup>, coccidioidomycosis<sup>6</sup>, listeriosis<sup>2</sup>, aspergillosis, viral hepatitis<sup>7</sup>, toxoplasmosis, and pneumocystosis. *Mycobacterium tuberculosis*<sup>5</sup> remains the most commonly reported pathogen associated with anti-TNF therapy. TB, histoplasmosis, coccidioidomycosis<sup>1</sup>, and listeriosis<sup>2</sup> have occurred with 2- to 10-fold greater frequency in patients treated with infliximab compared to etanercept, with trends toward increased infection risk

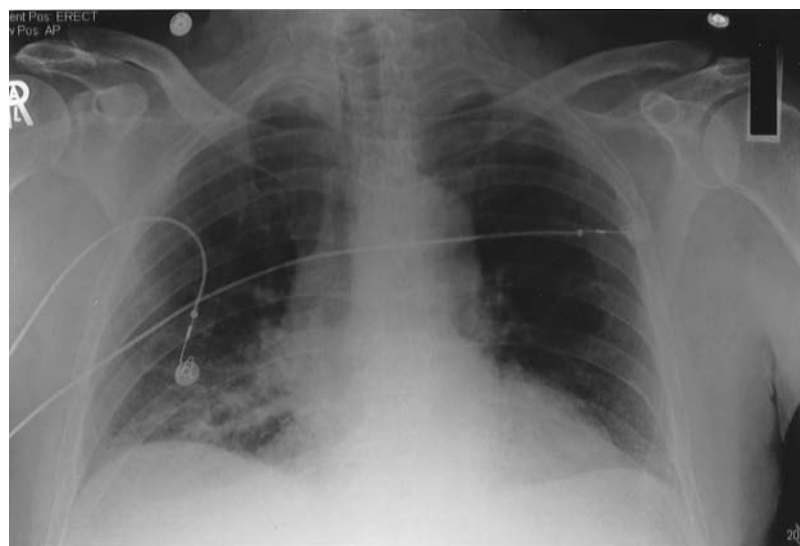


Figure 1. Chest radiograph showing consolidation of right lower zone extending from mediastinum.



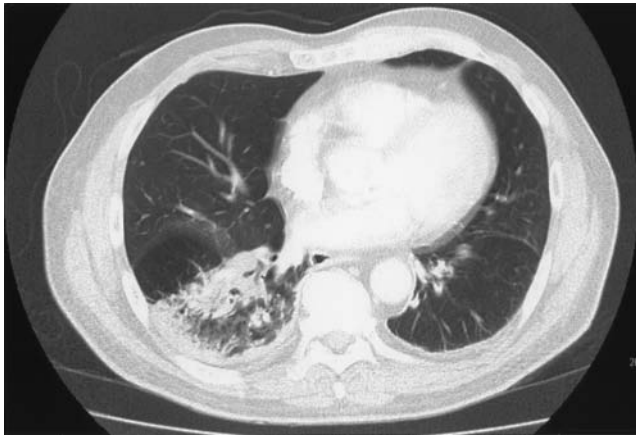

Figure 2. High resolution CT scan of chest showing consolidation of right lower lobe with impingement on pleura.

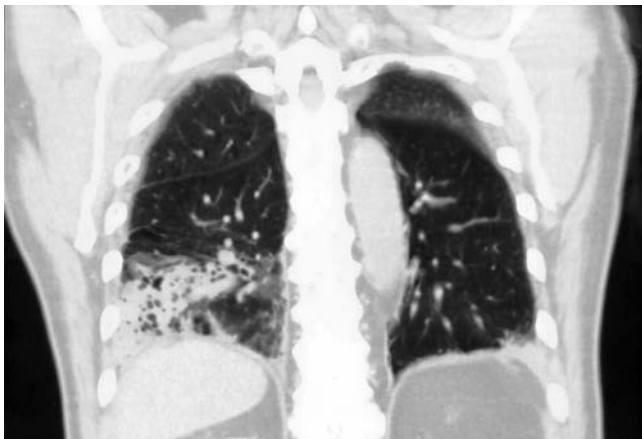


Figure 3. Coronal section CT scan of chest showing consolidation of right lobe extending to the pleura.

for candidiasis and nontuberculous mycobacteria. *Nocardia* infection has not been reported in anti-TNF therapy. Our patient may represent the first reported case of *Nocardia* infection. This case broadens the spectrum of opportunistic infections for TNF blockade treatment, and indicates the need to start broader antibiotic/antifungal treatment in an immune-compromised host.

VIJAY ARUN DORAISWAMY, MD, Western Pennsylvania Hospital (Western Clinical Campus of Temple University), 4800 Friendship Avenue, Pittsburgh, Pennsylvania 15224, USA.

#### REFERENCES

1. Horcajada JP, Peña JL, Martínez-Taboada VM, et al. Invasive Cryptococcosis and adalimumab treatment. *Emerg Infect Dis* 2007;13:953-5.
2. Bowie VL, Snella KA, Gopalachar AS, Bharadwaj P. *Listeria* meningitis associated with infliximab. *Ann Pharmacother* 2004;38:58-61.
3. Mori S, Imamura F, Kiyofuji C, Sugimoto M. Development of interstitial pneumonia in a rheumatoid arthritis patient treated with infliximab, an anti-tumor necrosis factor alpha-neutralizing antibody. *Modern Rheumatol* 2006;16:251-5.
4. Inanc N, Direskeneli H. Serious infections under treatment with

- TNF-alpha antagonists compared to traditional DMARDs in patients with rheumatoid arthritis. *Rheumatol Int* 2006;27:67-71.
5. Seong SS, Choi CB, Woo JH, et al. Incidence of tuberculosis in Korean patients with rheumatoid arthritis (RA): effects of RA itself and of tumor necrosis factor blockers. *J Rheumatol* 2007;34:706-11.
6. Bergstrom L, Yocum DE, Ampel NM, et al. Increased risk of coccidioidomycosis in patients treated with tumor necrosis factor alpha antagonists. *Arthritis Rheum* 2004;50:1959-66.
7. Tobon GJ, Canas C, Jaller JJ, Restrepo JC, Anaya JM. Serious liver disease induced by infliximab. *Clin Rheumatol* 2007;26:578-81.

#### Prevalence of Patello- and Tibiofemoral Osteoarthritis in Elva, Southern Estonia

To the Editor:

In a recent study in North Carolina, USA, 16% of the population over 45 years of age had symptomatic knee osteoarthritis (OA)<sup>1</sup>. Depending on the population studied and the epidemiological technique used, the prevalence figures for radiographic knee OA (rKOA; with or without symptoms) vary over a wide range<sup>2,3</sup>. There are limited data about the prevalence of rKOA in subjects younger than 50 years. In a Dutch study, rKOA was found in 7.7%–14.3% of persons aged 45–49 years<sup>4</sup>. In Swedish data, rKOA was detected in slightly more than 1% of individuals aged 35–54<sup>5</sup>. The prevalence must be even higher, as the 3 studies addressed only the tibiofemoral (TF) and not the patellofemoral (PF) compartment, where knee OA occurs more frequently<sup>2</sup>.

We investigated the prevalence of PF and TF rKOA among a middle-aged population and associations with the main risk factors. We studied all 559 persons aged 34–55 years included in the register of a selected family doctor in Elva, a small town in Southern Estonia. Of the 348 persons who responded to the postal questionnaire, 220 admitted either knee pain (60%) or other knee symptoms (40%). In 160 of them (79% of those with knee problems; 101 women, 59 men), radiographs of the TF joint and axial radiographs of the PF joint were taken. Two independent radiologists read the radiographs. Joint space narrowing (JSN) of the TF and PF compartments and osteophytes were assessed (grades 0–3) according to Nagaosa, *et al*<sup>6</sup>. For classification purposes, the findings of the TF and PF joints of both knees were included. Body mass index (BMI) was > 26 in 64% of the women and 58% of men.

Unilateral rKOA was found in 20% and bilateral rKOA in 44% of cases. Grade 1 OA was found in 55.6% and grade 2 or 3 OA in 8.1% of the subjects. Both early and advanced OA occurred more frequently in the PF joint. More precisely, grade 2 OA was detected in 12 persons, among whom the PF area was affected in 9. Grade 3 OA was found in 1 case in the TF area, combined with PF grade 2 OA. Thus in 10 cases out of 13, advanced PF OA would have remained undetected if an axial radiograph of the PF joint had not been taken (Table 1).

The prevalence rate of advanced (grade 2+) TF OA in the age group proved to be 1.7% (6 out of the 348 studied cases). The prevalence rate of PF OA was slightly higher: 3 isolated and 7 cases combined with TF OA (10 cases out of 348), i.e., 2.9%. The actual prevalence of rKOA 2+ (13 cases out of 348) was 3.7%. The majority of the studied cases had grade 1 KOA, usually regarded as clinically innocent. However, current evidence supports revision of this standpoint with respect to progression of rKOA<sup>7</sup> and functional impairment<sup>8</sup>.

In the group of women under 45 years of age, the number of both TF OA and PF OA cases was smaller than in those over 45 years of age ( $p = 0.02$ ,  $p = 0.06$ , respectively). Such a difference was not observed in the

Table 1. Prevalence of radiographic OA in the knee joints.

	Isolated		TF + PF, n		Total, n (%)
	TF, n	PF, n	TF	PF	
Without change			30	30	58 (36.3)
Grade 1 OA	19	40	8	4	89 (55.6)
Grade 2 OA	1	3	1*	0	12 (7.5)
Grade 3 OA	0	0			1 (0.6)
Total	20	43	39		160 (100)

\* TF grade 3 + PF grade 2. OA: osteoarthritis; TF: tibiofemoral compartment; PF: patellofemoral compartment; TF + PF: simultaneous involvement of both compartments.

men. All 7 subjects with TF OA grade 2+ were found in the group aged 45–55 years.

Considering the different radiographic findings, on average the youngest subjects were without OA in either TF or PF compartment (TF 0 and PF 0). The subjects with various combinations of OA were older, on average 45–50.5 years versus 43 years ( $p = 0.04$ ,  $p = 0.004$ ). The subgroups with PF OA tended to be younger in comparison with the subgroups with TF OA ( $p = 0.078$ ; Figure 1).

The women who had other knee complaints but were free of pain were younger than the women with knee pain (median ages 44 and 48 years, respectively;  $p = 0.012$ ). Thus we have some reason to claim that the first symptoms of knee OA may be crepitus, restricted movement, and morning stiffness, while knee pain may follow later. The process of knee OA may begin in the PF compartment, or the latter may form a separate entity. PF OA is thought to be associated with the development of disability<sup>1,8</sup>.

Correlation analysis demonstrated that (1) TF OA was associated with age in both men and women, while PF OA showed this association only in

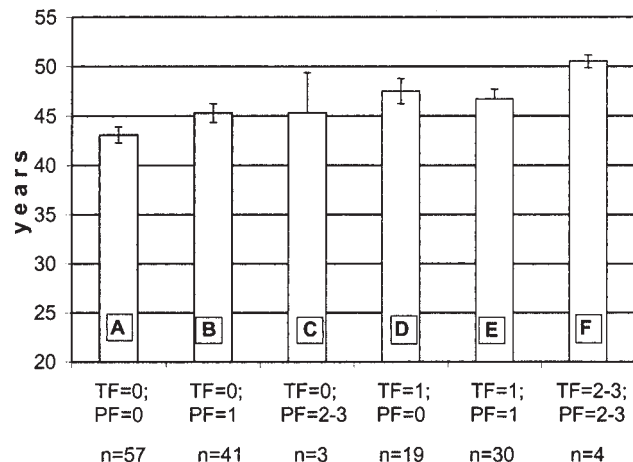


Figure 1. Mean ( $\pm$  SEM) ages of subjects in different groups with PF and TF osteoarthritis. A: without radiographic OA in PF and TF compartments. B: grade 1 OA only in PF compartment. C: isolated grade 2 or 3 OA in PF compartment. D: grade 1 OA only in TF compartment. E: grade 1 OA in TF and PF compartments. F: simultaneous grade 1 or 2 or 3 OA in TF and PF compartments. Significant differences between groups: A and B,  $p = 0.042$ ; A and D,  $p = 0.004$ ; A and E,  $p = 0.004$ ; A and F,  $p = 0.011$ ; B and F,  $p = 0.050$ .

women; (2) increased BMI showed a positive correlation with TF OA for both sexes, but not with PF OA; (3) earlier knee trauma, unlike BMI, was associated in particular with PF OA.

In summary, radiographic knee OA is common among the Estonian middle-aged population, with several differences between men and women, occurring more frequently in the PF joint.

ANN TAMM, MD, PhD, Senior Lecturer, Department of Sports Medicine and Rehabilitation, University of Tartu, Tartu; MARE LINTROP, MD, MSc, Senior Lecturer; KARIN VESKE, MD, Radiologist, Department of Radiology, Tartu University Clinics; ÜLLE HANSEN, MD, Ü. Hansen Family Practice, Elva; AGU TAMM, MD, PhD, DMSc, Professor of Laboratory Medicine, Clinic of Internal Medicine, University of Tartu, Tartu, Estonia. Address reprint requests to Dr. A. Tamm, Department of Sports Medicine and Rehabilitation, University of Tartu, Puusepa Street 1A, 2070, Tartu 50406, Estonia.

E-mail: ann.tamm@kliinikum.ee

Supported by Estonian Science Foundation grant no. 5308.

## REFERENCES

- Jordan JM, Helmick CG, Renner JB, et al. Prevalence of knee symptoms and radiographic and symptomatic knee osteoarthritis in African Americans and Caucasians: the Johnston County Osteoarthritis Project. *J Rheumatol* 2007;34:172-80.
- McAlindon TE, Snow S, Cooper C, Dieppe PA. Radiographic patterns of osteoarthritis of the knee joint in the community: importance of the patellofemoral joint. *Ann Rheum Dis* 1992;51:844-9.
- Lawrence RC, Helmick CG, Arnett FC, et al. Estimates of the prevalence of arthritis and selected musculoskeletal disorders in the United States. *Arthritis Rheum* 1998;41:778-99.
- van Saase JL, van Romunde LK, Cats A, Vandenbroucke JP, Valkenburg HA. Epidemiology of osteoarthritis: Zoetermeer survey. Comparison of radiological osteoarthritis in a Dutch population with that in 10 other populations. *Ann Rheum Dis* 1989;48:271-80.
- Petersson IF, Boegard T, Saxne T, Silman AJ, Svensson B. Radiographic osteoarthritis of the knee classified by the Ahlback and Kellgren & Lawrence systems for the tibiofemoral joint in people aged 35-54 years with chronic knee pain. *Ann Rheum Dis* 1997;56:493-6.
- Nagaosa Y, Mateus M, Hassan B, Lanyon P, Doherty M. Development of a logically devised line drawing atlas for grading of knee osteoarthritis. *Ann Rheum Dis* 2000;59:587-95.
- Wolfe F, Lane NE. The longterm outcome of osteoarthritis: rates and predictors of joint space narrowing in symptomatic patients with knee osteoarthritis. *J Rheumatol* 2002;29:139-46.
- Tamm AE, Hansen Ü, Veske K, Vija M, Tamm AO. Activity limitations in early knee osteoarthritis in 34-54 year old population in Estonia. In: Marincek C, Burger H, editors. *Rehabilitation sciences in the new millennium*. Bologna: Medimond International Proceedings; 2004:69-73.

## Rapid Response of Nail Psoriasis to Etanercept

To the Editor:

Nail psoriasis is a chronic disease affecting the appearance of the nails and causing severe distress to patients. Several methods of successful treatment for cutaneous psoriasis have been reported, and evidence-based therapies for psoriatic nail disease do exist<sup>1</sup>, although there is lack of a standardized treatment regimen.

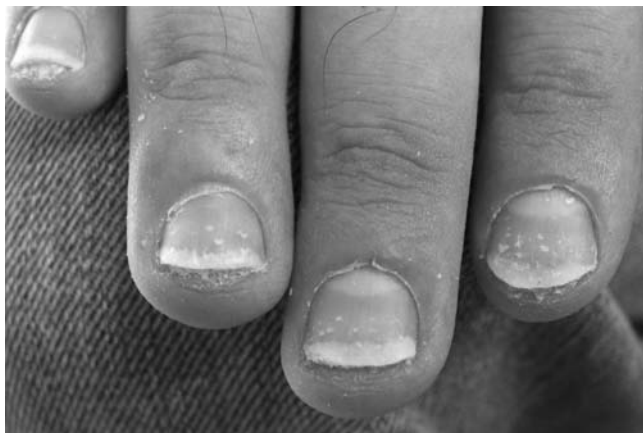

Figure 1. Oil-drop discoloration, nailbed hyperkeratosis, onycholysis, and pitting of fingernails of the right hand; April 3, 2006.

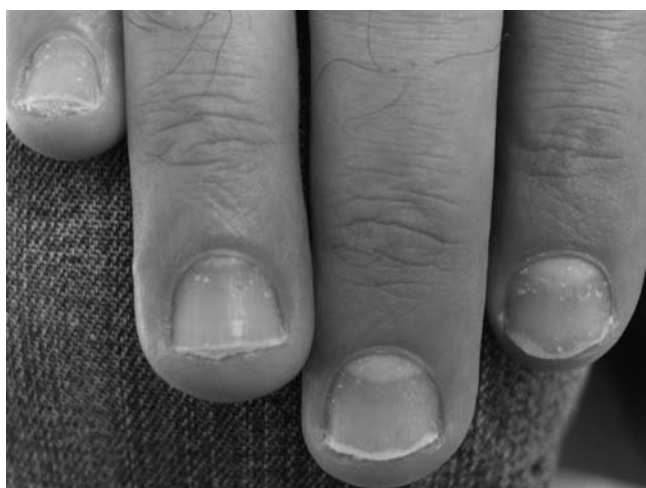

Figure 2. Significant improvement after 3 weeks of administration of etanercept 50 mg/week; April 28, 2006.

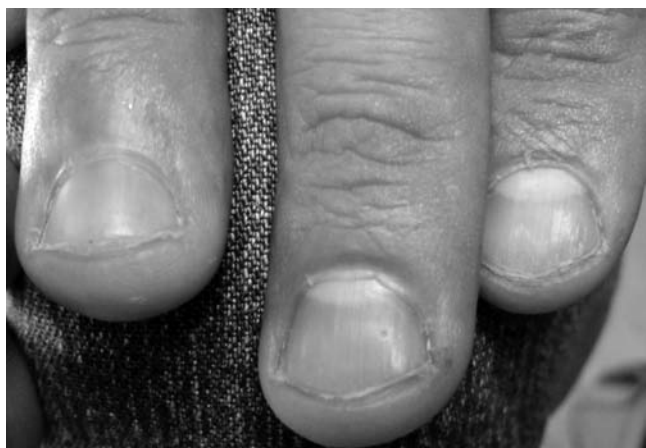

Figure 3. Complete cure was seen after 6 months of etanercept therapy; September 22, 2006.

Biological agents have established effectiveness in the treatment of psoriasis; however, reports regarding their efficacy on psoriatic nails remain limited<sup>2</sup>. We describe a case of rapid improvement of nail psoriasis in a patient receiving etanercept for plaque-type psoriasis.

A 35-year-old man with recalcitrant plaque psoriasis resistant to acitretin and cyclosporine was placed on a regimen of etanercept 50 mg per week in April 2006. All his 10 fingernails had also displayed psoriatic lesions resistant to previous treatments, while no symptoms of psoriatic arthritis were noted. The affected nails presented oil-drop discoloration, nailbed hyperkeratosis, onycholysis, and pitting (Figure 1). Toenails did not show any significant lesions.

After 3 weeks' administration of etanercept, a marked improvement was noted (Figure 2), and a complete cure was seen during the sixth month of etanercept therapy (Figure 3). Cutaneous psoriasis also showed a significant improvement. The medication was discontinued after 7 months of treatment; the patient remains free of psoriatic lesions on nails.

Etanercept has been shown to be safe and to have longterm efficacy for treatment of moderate to severe psoriasis resistant to other modes<sup>3</sup>. It acts by binding tumor necrosis factor- $\alpha$  (TNF- $\alpha$ ), which becomes biologically inactive; and therefore many proinflammatory pathways responsible for the initiation, maintenance, and recurrence of skin lesions in psoriasis are suppressed<sup>3</sup>.

Nail abnormalities are seen in about 50% of patients with psoriasis, with a wide spectrum of severity<sup>4</sup>. Medical management of nail psoriasis can be divided into the areas of topical, intralesional, radiation, and systemic and combination therapies<sup>5</sup>. The choice of treatment depends on the clinical presentation and specific patient factors. When nail psoriasis is the only manifestation, with no evidence of psoriatic arthritis, topical treatment as single therapy or in combination with systemic drugs is the most appropriate choice<sup>5</sup>. Systemic treatment is indicated when psoriatic nail disease is severe, or when topical treatment fails, or when extensive skin lesions and/or joint lesions coexist<sup>3</sup>.

In our case, etanercept showed remarkable and rapid effectiveness in the treatment of psoriatic nail disease. Our result is in agreement with other unpublished data<sup>2</sup>.

Thus etanercept may represent a safe, well tolerated alternative therapeutic option for treatment of psoriatic nail disease. Further studies are needed to establish the effectiveness and the therapeutic regimens of etanercept for treatment of nail psoriasis.

EFSTATHIOS RALLIS, MD; EVGENIA STAVROPOULOU, MD, Department of Dermatology, Army General Hospital, Athens; DIMITRIS RIGOPOULOS, MD, University of Athens, A. Sygros Hospital, Athens; CONSTANTINOS VERRIOS, MD, Tripolis, Greece. Address reprint requests to Dr. E. Rallis, 11 Pafsaniou Street, Athens, Greece GR-11635. E-mail: efrall@otenet.gr

#### REFERENCES

1. Cassell S, Kavanaugh A. Therapies for psoriatic nail disease. A systematic review. *J Rheumatol* 2006;33:1452-6.
2. de Rie M, Giannetti S, Walker J, et al. Nail psoriasis improves after 12 weeks of etanercept therapy in patients with moderate to severe psoriasis. Proceedings, 16th Congress of the European Academy of Dermatology and Venereology, Vienna, Austria, May 16-20 2007; Poster 1117:193.
3. Tyring S, Gordon KB, Poulin Y, et al. Long-term safety and efficacy of 50 mg of etanercept twice weekly in patients with psoriasis. *Arch Dermatol* 2007;143:719-26.
4. Lawry M. Biological therapy and nail psoriasis. *Dermatol Ther* 2007;20:60-7.
5. Jiaravuthisan M, Sasseville D, Vender RB, et al. Psoriasis of the nail: Anatomy, pathology, clinical presentation, and a review of the literature on therapy. *J Am Acad Dermatol* 2007;57:1-27.

# Correction

Pinto JA, Rego I, Fernandez-López C, Freire M, Fernandez-Sueiro JL, Blanco FJ, Rodríguez-Gomez M, Sanmarti R, Cañete JD. Polymorphisms in genes encoding tumor necrosis factor- $\alpha$  and HLA-DRB1 are not associated with response to infliximab in patients with rheumatoid arthritis. *J Rheumatol* 2008;35:177-8. The correct order of the authors should be J.A. Pinto, I. Rego, M. Rodríguez-Gomez, J.D. Cañete, C. Fernandez-López, M. Freire, J.L. Fernandez-Sueiro, R. Sanmarti, and F.J. Blanco. We regret the error.