

Therapy with Granulocyte Colony-Stimulating Factor in Systemic Lupus Erythematosus May Be Associated with Severe Flares

IRENE M. VASILIU, MICHELLE A. PETRI, and ALAN N. BAER

ABSTRACT. Recombinant human granulocyte colony-stimulating factor (G-CSF) has been used for treatment of febrile neutropenia in systemic lupus erythematosus (SLE) and other systemic rheumatic diseases. We describe 2 patients with SLE with disease flares with irreversible loss of renal function in association with G-CSF therapy. Eighteen patients with SLE treated with G-CSF for neutropenia have been reported, of whom 4 developed mild disease flares or cutaneous vasculitis. Our experience suggests that G-CSF therapy should be used with considerable caution in patients with SLE. (First Release July 1 2006; J Rheumatol 2006;33:1878–80)

Key Indexing Terms:

COLONY-STIMULATING FACTORS
NEUTROPENIA

SYSTEMIC LUPUS ERYTHEMATOSUS
INFECTION

Granulocyte colony-stimulating factor (G-CSF) is a hematopoietic cytokine produced by monocytes, fibroblasts, and endothelial cells that regulates the proliferation and differentiation of neutrophil precursors and modulates the functional activity of mature neutrophils¹. Recombinant human G-CSF is used to decrease the duration and severity of neutropenia, most often in patients with cancer undergoing chemotherapy². Indications for G-CSF therapy have been extended to the treatment of neutropenia with fever in patients with systemic autoimmune diseases and the mobilization of stem cells for autologous transplantation in high-dose immunosuppressive treatment protocols for severe cases of these diseases^{3,4}. G-CSF therapy is usually well tolerated, with the most common side effect being bone pain. However, flares of autoimmune disease and leukocytoclastic vasculitis have been reported^{1,5}. These have been generally mild and responsive to treatment. We describe 2 patients with systemic lupus erythematosus (SLE) who experienced severe disease flares in association with G-CSF therapy. Both patients had rapid and irreversible

decline in renal function. Our experience suggests that G-CSF should be used with caution in patients with SLE.

CASE REPORTS

Case 1. A 32-year-old woman was diagnosed with SLE in 1996 based on the presence of polyarthritis, myositis, hemolytic anemia, antinuclear (ANA) and anti-Ro antibodies, and hypocomplementemia. She was treated with oral corticosteroids. Her clinical progression was marked by the development of lupus cerebritis in 1997 and hypertension in 2000. During the 32nd week of pregnancy (September 2001), she developed renal insufficiency, nephrotic-range proteinuria, hematuria, and hypertension. Her renal disease failed to improve with high-dose corticosteroids and elective induction of labor. A postpartum kidney biopsy showed mixed World Health Organization (WHO) class IV and class V crescentic glomerulonephritis. She was treated with 6-monthly intravenous (IV) cyclophosphamide infusions, followed by maintenance therapy with mycophenolate mofetil. Her creatinine remained stable but 3+ proteinuria persisted. In April 2004 she was hospitalized with fever and intermittent right lower quadrant abdominal pain. At that time, she was receiving mycophenolate mofetil 1 g twice daily and prednisone 5 mg daily. Admission laboratory test results included: white blood cell (WBC) count 1300/mm³ with 200/mm³ neutrophils, hemoglobin 10.5 g/dl, platelets 280,000/mm³, creatinine 1.4 mg/dl, and normal complement levels. On computed tomographic (CT) imaging of the abdomen and pelvis, there was a right ovarian cyst with fluid in the cul-de-sac. She was treated empirically with antibiotics. Mycophenolate mofetil was discontinued. On the second hospital day, filgrastim (recombinant methionyl human G-CSF) was started and continued for 4 days. The WBC and neutrophil counts normalized in 4 days. After the second dose of filgrastim, her creatinine rose from 1.4 mg/dl to 1.9 mg/dl and then continued to rise despite discontinuation of filgrastim (Figure 1A). She developed nephrotic-range proteinuria (4.6 g/day) and hematuria. Serum complement levels remained normal. A kidney biopsy showed class IV WHO glomerulonephritis with crescents and fibrinoid necrosis. She received pulse IV methylprednisolone and IV cyclophosphamide. Her renal insufficiency progressively worsened and she required chronic hemodialysis 2 months after the filgrastim treatment.

Case 2. A 54-year-old woman was diagnosed with SLE in 1994. Her disease

From the Department of Medicine, State University of New York at Buffalo, Buffalo, New York; and the Department of Medicine, Johns Hopkins University School of Medicine, Baltimore, Maryland, USA.

Supported by RO1 AR043727 and Johns Hopkins Outpatient Clinical Research Center MO1-RR00052.

I.M. Vasilu, MD, Fellow in Rheumatology, State University of New York at Buffalo; M.A. Petri, MD, MPH, Professor of Medicine, Johns Hopkins University; A.N. Baer, MD, Associate Professor of Medicine, State University of New York at Buffalo.

Address reprint requests to Dr. A.N. Baer, Department of Medicine, Erie County Medical Center, 462 Grider Street, Buffalo, NY 14215.

Accepted for publication March 27, 2006.

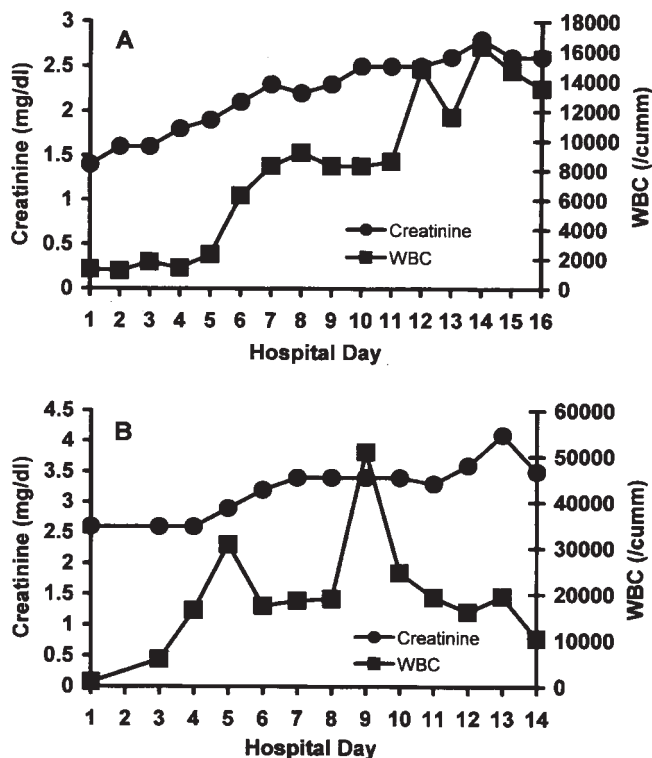


Figure 1. Changes in serum creatinine in relation to the white blood cell count (WBC) during G-CSF treatment in Case 1 (A) and Case 2 (B).

manifestations included discoid lupus, photosensitivity, oral ulcers, Raynaud's phenomenon, cutaneous vasculitis, arthralgias, pleurisy, pericarditis, diffuse proliferative glomerulonephritis, cranial neuropathy, mild pulmonary hypertension, lupus enteritis, ANA, leukopenia, lymphopenia, and hypocomplementemia. She also had antiphospholipid antibody syndrome manifested by livedo reticularis, a lupus anticoagulant, deep venous thrombosis, and digital gangrene.

In April 2004, mycophenolate mofetil therapy for proteinuria (5.1 g/day) was stopped because of intractable diarrhea. Monthly IV cyclophosphamide therapy was initiated on May 5, 2000. Serum creatinine was stable. Six days after receiving the first cyclophosphamide infusion, she was admitted with fever and an absolute neutrophil count of 700/mm³. Antibiotic coverage was instituted and filgrastim was given. *Klebsiella pneumoniae* was diagnosed, from which she recovered. The WBC count rose quickly, peaking at 51,000 by the 9th day after filgrastim therapy was initiated (Figure 1B). During hospitalization, her renal function worsened and she became oliguric and dialysis dependent by the 20th hospital day. Serum C3 was 50 mg/dl and C4 < 2 mg/dl. A repeat renal biopsy was not performed. Treatment with high-dose prednisone had no effect on her renal function. She remained dialysis-dependent and died one month later.

DISCUSSION

Our 2 patients with SLE experienced severe flares of their renal disease after receiving G-CSF therapy for neutropenia with fever. It is possible that the observed disease flares were not causally related to the G-CSF therapy. However, both patients had stable renal disease prior to the institution of G-CSF therapy. There was also a strong temporal relationship between the disease flares and the administration of G-CSF. In both patients, renal function worsened within 3 to 5 days of

implementation of G-CSF therapy and declined progressively despite escalation of immunosuppressive therapy.

Eighteen patients with SLE who received G-CSF therapy for therapy of neutropenia complicated by infections have been reported⁵⁻¹². In each patient, G-CSF therapy resulted in significant elevation of the neutrophil count and control of infection. The treatment was generally well tolerated. However, 4 patients experienced a worsening of their autoimmune disease. One patient with recurrent seizures developed a generalized seizure on the second day of G-CSF therapy^{5,8}. Another patient with neuropsychiatric lupus experienced nystagmus and worsening of psychosis during the fourth day of G-CSF treatment^{5,8}. Her symptoms resolved following discontinuation of G-CSF. Gottenberg, *et al* reported a patient with undifferentiated connective tissue disease who developed clinical symptoms of SLE after receiving G-CSF for penicillamine-induced neutropenia¹⁰. A fourth patient developed cutaneous leukocytoclastic vasculitis during treatment with G-CSF^{5,8}.

G-CSF therapy has also been associated with flares in patients with Felty's syndrome, psoriatic arthritis, multiple sclerosis, and other autoimmune diseases. Flares of rheumatoid synovitis and development of cutaneous vasculitis have been reported in patients with Felty's syndrome treated with G-CSF¹³⁻¹⁸. Kavanaugh reported a patient with psoriatic arthritis and incidental cyclic neutropenia whose skin and joint disease flared during treatment with G-CSF¹⁹. Palpable purpura and exacerbation of psoriasis developed in a patient with lung cancer and concomitant psoriasis who received G-CSF for chemotherapy-induced neutropenia²⁰. Flares of relapsing polychondritis, Wegener's granulomatosis, systemic sclerosis, and SLE have been reported after G-CSF was administered to mobilize stem cells for autologous transplantation^{3,21}. The patient in this group with SLE developed pericardial and pleural effusions and atrial fibrillation²¹. Five patients with multiple sclerosis experienced worsening neurological symptoms while receiving G-CSF to mobilize stem cells. IV methylprednisolone improved symptoms in all but one patient²². Cyclophosphamide is now used routinely in conjunction with G-CSF to decrease the occurrence of autoimmune disease flares during stem cell mobilization^{23,24}.

G-CSF is a strong activator of mature neutrophils and indirectly affects T-cells; both effects might account for the induction of disease flares in SLE. Acute renal failure, triggered by ischemia in experimental murine models, is aggravated by concomitant induction of granulocytosis by hematopoietic stem cell mobilization using G-CSF²⁵. Activated neutrophils, generated in large number by G-CSF, are thought to induce organ damage by tissue infiltration and release of proinflammatory cytokines. G-CSF also inhibits the apoptosis of neutrophils. This effect is blunted in patients with SLE, perhaps explaining the observation that such patients have an increased number of apoptotic neutrophils and potentially an enhanced source of lupus autoantigens²⁶. Colony-stimulating

factors are also proinflammatory cytokines that may promote or worsen autoimmune diseases¹⁰. G-CSF-induced upregulation of Th2-derived cytokine production with subsequent amplification of inflammatory processes has been postulated as a mechanism of SLE flares induced by G-CSF therapy²⁷.

Our experience raises concerns about the safety of G-CSF therapy in SLE. G-CSF may be an appropriate adjunct for antibiotic therapy in patients with SLE and neutropenia with severe, treatment-refractory infections. However, careful clinical judgment must be employed in selecting patients for this therapy, given the potential risk of organ- or life-threatening SLE flares. The potential for a flare may be reduced by the use of high-dose corticosteroids at the time G-CSF therapy is implemented²⁸.

REFERENCES

1. Anderlini P, Przepiorka D, Champlin R, Korbling M. Biologic and clinical effects of granulocyte colony-stimulating factor in normal individuals. *Blood* 1996;88:2819-25.
2. Frampton JE, Lee CR, Faulds D. Filgrastim. A review of its pharmacological properties and therapeutic efficacy in neutropenia. *Drugs* 1994;48:731-60.
3. Iking-Konert C, Ostendorf B, Foede M, et al. Granulocyte colony-stimulating factor induces disease flare in patients with antineutrophil cytoplasmic antibody-associated vasculitis. *J Rheumatol* 2004;31:1655-8.
4. Marmont A, Tyndall A, Gratwohl A, Vischer T. Haemopoietic precursor-cell transplants for autoimmune diseases. *Lancet* 1995;345:978.
5. Euler HH, Harten P, Zeuner RA, Schwab UM. Recombinant human granulocyte colony stimulating factor in patients with systemic lupus erythematosus associated neutropenia and refractory infections. *J Rheumatol* 1997;24:2153-7.
6. Hellmich B, Schnabel A, Gross WL. Treatment of severe neutropenia due to Felty's syndrome or systemic lupus erythematosus with granulocyte colony-stimulating factor. *Semin Arthritis Rheum* 1999;29:82-99.
7. Starkebaum G. Use of colony-stimulating factors in the treatment of neutropenia associated with collagen vascular disease. *Curr Opin Hematol* 1997;4:196-9.
8. Euler HH, Schwab UM, Schroeder JO. Filgrastim for lupus neutropenia. *Lancet* 1994;344:1513-4.
9. Ruiz-Valverde MP, Segarra A, Tovar JL, Ribera R, Piera L. Treatment of severe leukopenia with rhG-CSF in systemic lupus erythematosus treated with cyclophosphamide [letter]. *Nephron* 1996;73:715.
10. Gottenberg JE, Roux S, Desmoulins F, Clerc D, Mariette X. Granulocyte colony-stimulating factor therapy resulting in a flare of systemic lupus erythematosus [letter]. *Arthritis Rheum* 2001;44:2458-60.
11. Frosch M, Roth J, Harms E. rhG-CSF resistant neutropenia in SLE [letter]. *Ann Rheum Dis* 1997;56:396.
12. Kondo H, Date Y, Sakai Y, Akimoto M. Effective simultaneous rhG-CSF and methylprednisolone "pulse" therapy in agranulocytosis associated with systemic lupus erythematosus. *Am J Hematol* 1994;46:157-8.
13. McMullin MF, Finch MB. Felty's syndrome treated with rhG-CSF associated with flare of arthritis and skin rash. *Clin Rheumatol* 1995;14:204-8.
14. Hayat SQ, Hearsh-Holmes M, Wolf RE. Flare of arthritis with successful treatment of Felty's syndrome with granulocyte colony stimulating factor (G-CSF). *Clin Rheumatol* 1995;14:211-2.
15. Krishnaswamy G, Odem C, Chi DS, Kalbfleisch J, Baker N, Smith JK. Resolution of the neutropenia of Felty's syndrome by longterm administration of recombinant granulocyte colony stimulating factor. *J Rheumatol* 1996;23:763-5.
16. Farhey YD, Herman JH. Vasculitis complicating granulocyte colony stimulating factor treatment of leukopenia and infection in Felty's syndrome. *J Rheumatol* 1995;22:1179-82.
17. Yasuda M, Kihara T, Wada T, et al. Granulocyte colony stimulating factor induction of improved leukocytopenia with inflammatory flare in a Felty's syndrome patient. *Arthritis Rheum* 1994;37:145-6.
18. Vidarsson B, Geirsson AJ, Onundarson PT. Reactivation of rheumatoid arthritis and development of leukocytoclastic vasculitis in a patient receiving granulocyte colony-stimulating factor for Felty's syndrome. *Am J Med* 1995;98:589-91.
19. Kavanaugh A. Flare of psoriasis and psoriatic arthritis following treatment with granulocyte colony-stimulating factor. *Am J Med* 1996;101:567-8.
20. Couderc LJ, Philippe B, Franck N, Balloul-Delclaux E, Lessana Leibowitch M. Necrotizing vasculitis and exacerbation of psoriasis after granulocyte colony-stimulating factor for small cell lung carcinoma. *Respir Med* 1995;89:237-8.
21. Rosen O, Thiel A, Massenkeil G, et al. Autologous stem-cell transplantation in refractory autoimmune diseases after in vivo immunoablation and ex vivo depletion of mononuclear cells. *Arthritis Res* 2000;2:327-36.
22. Openshaw H, Stuve O, Antel JP, et al. Multiple sclerosis flares associated with recombinant granulocyte colony-stimulating factor. *Neurology* 2000;54:2147-50.
23. Burt RK, Fassas A, Snowden J, et al. Collection of hematopoietic stem cells from patients with autoimmune diseases. *Bone Marrow Transplant* 2001;28:1-12.
24. Burt RK, Traynor A, Statkute L, et al. Nonmyeloablative hematopoietic stem cell transplantation for systemic lupus erythematosus. *JAMA* 2006;295:527-35.
25. Togel F, Isaac J, Westenfelder C. Hematopoietic stem cell mobilization-associated granulocytosis severely worsens acute renal failure. *J Am Soc Nephrol* 2004;15:1261-7.
26. Armstrong DJ, Whitehead EM, Crockard AD, Bell AL. Distinctive effects of G-CSF, GM-CSF and TNF-alpha on neutrophil apoptosis in systemic lupus erythematosus. *Clin Exp Rheumatol* 2005;23:152-8.
27. Pan L, Delmonte J Jr, Jalonon CK, Ferrara JL. Pretreatment of donor mice with granulocyte colony-stimulating factor polarizes donor T lymphocytes toward type-2 cytokine production and reduces severity of experimental graft-versus-host disease. *Blood* 1995;86:4422-9.
28. Burt RK, Cohen B, Rose J, et al. Hematopoietic stem cell transplantation for multiple sclerosis. *Arch Neurol* 2005;62:860-4.