

# Correspondence



## INSTRUCTIONS FOR LETTERS TO THE EDITOR

Editorial comment in the form of a Letter to the Editor is invited. The length of a letter should not exceed 800 words, with a maximum of 10 references and no more than 2 figures or tables; and no subdivision for an abstract, methods, or results. Letters should have no more than 4 authors. Financial associations or other possible conflicts of interest should be disclosed.

Letters should be submitted via our online submission system, available at the Manuscript Central website: <http://mc.manuscriptcentral.com/jrheum> For additional information, contact the Managing Editor, The Journal of Rheumatology, E-mail: [jrheum@jrheum.com](mailto:jrheum@jrheum.com)

## Dexamethasone: An “Old New” Glucocorticoid on the Horizon!

To the Editor:

We read with great interest the article by Song, *et al* dealing with glucocorticoids (GC) in the treatment of rheumatic diseases<sup>1</sup>. New insights into the several mechanisms of action of GC were comprehensively described. The authors emphasized that these insights have led to the development of more optimized GC, including long-circulating liposomal GC, nitrosteroids, 21-aminosteroids, and selective GC receptor antagonists. The therapeutic efficacy of these new GC seems so promising that they will probably be available in clinical practice in the near future.

However, data on the use of dexamethasone, an “old new” GC, also frequently used as a GC pulse option in autoimmune diseases, are not shown<sup>2-4</sup>. We suggest that the review definitely has to be extended by data on this issue for several reasons. First, oral pulsed dexamethasone therapy has already revealed its therapeutic efficacy in several autoimmune diseases including resistant idiopathic thrombocytopenic purpura, polymyositis, and chronic inflammatory demyelinating polyneuropathy<sup>2-4</sup>. Second, a major advantage of pulsed dexamethasone therapy is that it has less mineralocorticoid activity than other high-dose GC pulse strategies<sup>5,6</sup>. And third, we recently speculated whether oral dexamethasone pulse therapy might be a new option in rheumatoid arthritis (RA) as well, probably with fewer side effects than the standard GC pulse strategies<sup>7</sup>. We determined the clinical efficacy, optimal dose, and side effects of oral pulse dexamethasone treatment in 10 patients with early active RA, concomitantly starting disease modifying antirheumatic drugs (DMARD). All patients fulfilled the American College of Rheumatology criteria and were DMARD- and glucocorticoid-naïve. Patients were treated with oral pulsed dexamethasone therapy for 4 days in a row. Four patients received 10 mg dexamethasone/day, 3 patients 20 mg/day, and 3 patients 40 mg/day. Disease activity [by Disease Activity Score (DAS)] and biochemical variables were measured for all patients at baseline and then biweekly for 4 weeks, and monthly thereafter up to 3 months. All treatment groups showed a decrease in disease activity, which did not differ between the 3 subgroups treated with different doses of oral dexamethasone pulse therapy. A decrease in

DAS of > 1.2 was observed in 7 out of these 10 patients as early as 2 weeks after starting. Eight of 10 patients responded favorably (decrease in DAS > 1.2) 4 weeks after starting. This response was sustained in the months thereafter. No side effects were reported. A decrease in cortisol concentration was observed only once, 2 weeks after starting (0.03  $\mu\text{mol/l}$ ; reference value 0.18–0.70  $\mu\text{mol/l}$ ). We concluded that oral pulsed dexamethasone therapy was an effective, safe, and promising option in patients with early RA.

We are aware that reports of dexamethasone pulse therapy in autoimmune diseases are from studies with just a small number of patients<sup>2-4,7</sup>. The new GC will certainly improve the therapeutic arsenal for patients with autoimmune diseases<sup>1</sup>. The results of these studies justify longterm controlled trials to compare pulse dexamethasone treatment with the standard and with new GC regimes.

ERIC-JAN A. KROOT, MD, PhD; MARGRIET A.M. HUISMAN, MD, PhD, Department of Rheumatology, Sint Franciscus Hospital, Kleiweg 500, 3045 PM Rotterdam, The Netherlands. E-mail: [ejankroot@yahoo.com](mailto:ejankroot@yahoo.com)

## REFERENCES

1. Song IH, Gold R, Straub RH, Burmester GR, Buttgerit F. New glucocorticoids on the horizon: repress, don't activate! *J Rheumatol* 2005;32:1199-207.
2. Andersen JC. Response of resistant idiopathic thrombocytopenic purpura to pulsed high-dose dexamethasone therapy. *N Engl J Med* 1994;330:1560-4.
3. Molenaar DS, van Doorn PA, Vermeulen M. Pulsed high dose dexamethasone treatment in chronic inflammatory demyelinating polyneuropathy: a pilot study. *J Neurol Neurosurg Psychiatry* 1997;62:388-90.
4. van der Meulen MF, Hoogendijk JE, Wokke JH, et al. Oral pulsed high-dose dexamethasone for myositis. *J Neurol* 2000;247:102-5.
5. Laan RF, Jansen TL, van Riel PL. Glucocorticosteroids in the management of rheumatoid arthritis. *Rheumatology Oxford* 1999;38:6-12.
6. Da Silva JA, Bijlsma JW. Optimizing glucocorticoid therapy in rheumatoid arthritis. *Rheum Dis Clin North Am* 2000;26:859-80.
7. Kroot EJA, Huisman AM, van Zeben J, Wouters JMGW, van Paassen HC. Oral pulsed dexamethasone therapy in early rheumatoid arthritis: a pilot study. *Ann NY Acad Sci* 2006; in press.

## Dr. Buttgerit replies

To the Editor:

Dr. Kroot and Dr. Huisman address an important question: What should be the glucocorticoid (GC) of choice for pulse therapy? From my point of view, there are 2 approaches to this question — considering results from basic research activities and/or looking at clinically established treatment procedures, as follows.

1. The existence of distinct therapeutically relevant effects of GC (genomic, specific nongenomic, unspecific nongenomic)<sup>1</sup> raised the hypothesis that the relative potencies of nongenomic and genomic effects of GC may differ. If so, the next question with regard to clinical relevance would be, what GC is most potent in producing (unspecific) nongenomic effects and therefore should be considered especially appropriate for (high dose) pulse therapy? We investigated these questions a few years ago and measured the unspecific nongenomic potencies of 5 clinically important GC (methylprednisolone, prednylidene, dexamethasone, prednisolone, and betamethasone) in order to compare them with the classical (genomic) potencies<sup>2</sup>. The immediate effects of GC on selected bioenergetic variables (such as cellular respiration, protein synthesis, and cation transport) were measured in immune cells. For unspecific nongenomic effects we found the relative drug potencies (calculated as the inverse of the equivalent

doses normalized to methylprednisolone) to be as follows: prednylidene (3.0) > dexamethasone (1.2) > methylprednisolone (1.0) > prednisolone (0.4) > betamethasone (0.2)<sup>2</sup>. This hierarchy is completely different from that for the classical effects, which seems to be important with regard to the clinical implications for (pulse) therapy<sup>2,3</sup>. More details are given in our report, but 2 facts are most interesting. First, from these results dexamethasone should indeed be appropriate for use in the setting of pulse therapy: (1) it is known to be strong in terms of genomic effects; (2) it produces important unspecific nongenomic effects (which are considered to be clinically relevant in addition to the genomic effects in pulse therapy); and (3) it appears to be even stronger than, for example, methylprednisolone or prednisolone. And second, dexamethasone was found to be much stronger than betamethasone, although both are reported to have similar affinities for nuclear receptors (genomic effects). This is perhaps the reason why dexamethasone, but usually not betamethasone, is used at high doses or in pulse therapy.

2. It seems that in the United States and in Europe the drugs methylprednisolone and prednisone are most often used in pulse therapy (or at high dosages). Kroot and Huisman cite a number of studies (most from The Netherlands) that show dexamethasone to have good efficacy in pulse therapy and perhaps even a better benefit-risk ratio than other GC.

Apart from the issues discussed above I do not know any specific scientific reasons why GC use in pulse therapy has been established this way. Historical reasons may also be relevant. To my knowledge there has been no rigorous head-to-head study that would give clear answers to the question of which GC are most appropriate for pulse therapy.

I would mention that dexamethasone is usually used for the "dexamethasone suppression test," measuring the response of the adrenal glands to ACTH. It can be speculated that this implicates unwanted effects on the hypothalamic-pituitary-adrenal axis, which prevent this drug from becoming the first choice. Kroot and Huisman have indirectly addressed this question, since they describe decreased cortisol levels 2 weeks after the start of the study in their report<sup>5</sup>.

The discussion induced by Kroot and Huisman's letter is timely and highly relevant from the clinical point of view. Although GC have been in clinical use for more than 50 years, there still remain a lot of open questions, including what GC at which dosage regimen is best for pulse therapy. Further *in vitro/in vivo* investigations and clinical trials are necessary. However, these important drugs are being used extensively without any need for large advertisements or expensive high-standard trials. This is one reason why there are few, if any, studies under way to pursue these important questions<sup>4</sup>.

FRANK BUTTGEREIT, MD, Professor, Department of Rheumatology and Clinical Immunology, Charité University Hospital, Schumannstrasse 20/21, 10117 Berlin, Germany. E-mail: frank.buttgereit@charite.de

## REFERENCES

- Buttgereit F, Straub RH, Wehling M, Burmester GR. Glucocorticoids in the treatment of rheumatic diseases: an update on the mechanisms of action. *Arthritis Rheum* 2004;50:3408-17.
- Buttgereit F, Brand MD, Burmester GR. Equivalent doses and relative drug potencies for non-genomic glucocorticoid effects: a novel glucocorticoid hierarchy. *Biochem Pharmacol* 1999;58:363-8.
- Lipworth BJ. Therapeutic implications of non-genomic glucocorticoid activity. *Lancet* 2000;356:87-9.
- Thiele K, Buttgereit F, Huscher D, Zink A, German Collaborative Arthritis Centres. Current use of glucocorticoids in patients with rheumatoid arthritis in Germany. *Arthritis Rheum* 2005;53:740-7.
- Kroot EJA, Huisman AM, van Zeben J, Wouters JMGW, van Paassen HC. Oral pulsed dexamethasone therapy in early rheumatoid arthritis: a pilot study. *Ann NY Acad Sci* 2006; in press.



## Etanercept Induced Multiple Sclerosis and Transverse Myelitis

To the Editor:

Etanercept is a tumor necrosis factor- $\alpha$  (TNF- $\alpha$ ) antagonist used in rheumatoid arthritis (RA). Several studies have raised the possibility that etanercept may have unexpected side effects such as demyelinating neurological disorders<sup>1</sup>.

We describe a 58-year-old Caucasian woman who presented with a 9-day history of left lower extremity weakness that progressed to bilateral lower extremity weakness and numbness, along with a tingling sensation in both hands. She was unable to walk without assistance and was in a wheelchair on presentation. This numbness progressed to involve most of her body, from her chest down to her toes bilaterally, as well as both hands and wrists. She reported that she slipped and fell a few days prior to these symptoms and twisted her back, without significant neurological symptoms at that time. Magnetic resonance imaging (MRI) of the cervical spine showed a 1.5 cm focal area of high signal intensity seen on T2 weighted images at the C3-C4 level (Figure 1). She was started on oral steroids without a significant improvement prior to the MRI of the cervical spine.

She had a 5-year history of RA. Because methotrexate was only of partial benefit she was switched to etanercept, which she continued for more than one year, with dramatic improvement in her joint symptoms. Etanercept was discontinued at hospital admission. She had no history of multiple sclerosis (MS) or any neurological disease.

Neurological examination revealed intact cranial nerves. Decreased sensitivity to light touch was noted in the left leg. Hip flexors, hamstrings, dorsi, and plantar flexors of the feet had decreased strength at about 4/5 in the left leg, 5/5 at the hip flexors, quads, hamstrings, dorsi, and plantar flexors of the right leg. Deltoid, biceps, and triceps had 5/5 strength. Straight leg raising test was negative bilaterally. Deep tendon reflexes were brisk in the left lower extremity with a positive Babinski's sign, but otherwise normal. A mild dysmetria was noted in her left upper extremity. MRI of the brain showed multiple areas of increased signal intensity involving the deep white matter (Figure 2).

Cerebrospinal fluid analysis showed white blood cell count was 13 cells/ml (90% lymphocytes), glucose 92 mg/dl, total protein 27 mg/dl, IgG 2.94 mg/dl, IgG index 1.05, and VDRL nonreactive. Oligoclonal bands were positive. Bacterial, viral, and fungal studies were negative. The presumptive diagnosis was MS with transverse myelitis induced or worsened by etanercept.

Etanercept was discontinued and the patient was started on intravenous methylprednisolone. She improved significantly during the next 5 days, with partial resolution of her weakness and numbness. She was again able to walk without assistance. She was discharged on tapering doses of prednisone. Three weeks after discharge she had normal gait. She denied any persistent numbness. Motor examination showed 5/5 strength in all muscle groups of all extremities. Deep tendon reflexes were +2 in all extremities. Babinski's sign was negative bilaterally. Followup brain MRI one year later showed no change in the pattern of periventricular demyelination. There was no abnormal enhancement of these changes to suggest active MS. Findings were compatible with old lesions.

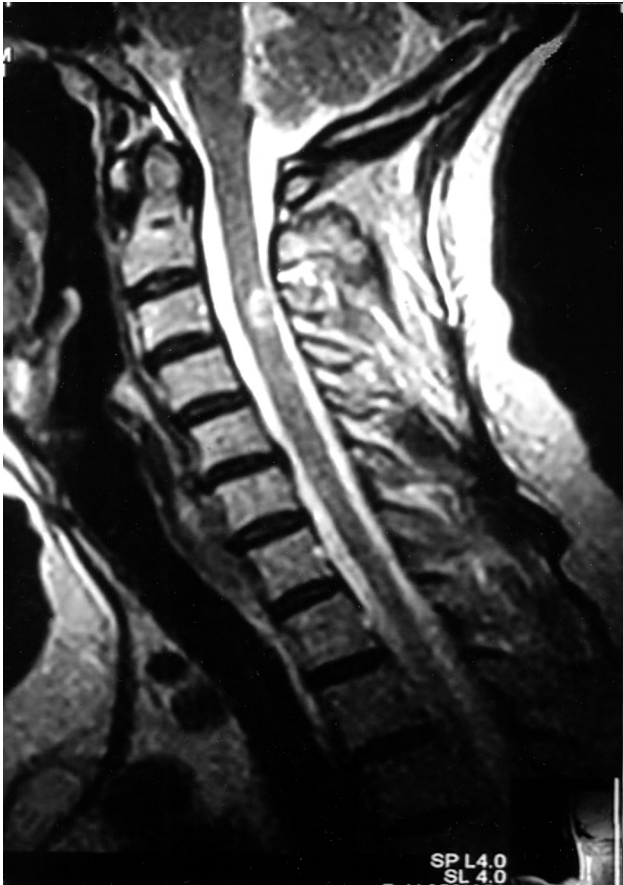

Figure 1. MRI of the cervical spine showing a 1.5 cm focal area of high signal intensity seen on T2 weighted images at the C3–C4 level.

TNF- $\alpha$  stimulates collagenase and prostaglandin E<sub>2</sub> production by human synovial cells<sup>2</sup>, induces bone resorption<sup>3</sup>, inhibits bone formation and proteoglycan synthesis<sup>4</sup>, stimulates resorption of proteoglycan, stimulates fibroblast proliferation, and increases production of interleukin 6 (IL-6), IL-8 and granulocyte macrophage-colony stimulating factor. TNF- $\alpha$  is primarily a product of synovial macrophages in RA and is present in rheumatoid synovial fluid and serum.

Etanercept, a soluble TNF- $\alpha$  receptor fusion protein that binds TNF- $\alpha$ , provides substantial benefit to patients with RA when compared to placebo<sup>5</sup>. Efficacy is similar to that of methotrexate but of more rapid onset and is recommended for patients with an inadequate response to methotrexate alone<sup>6,7</sup>.

The incidence of demyelinating disease in patients receiving etanercept (31 per 100,000 patients per year) appears to be higher than in the general population (4–6 per 100,000 per year). Symptoms include confusion, ataxia, paresthesia, optic neuritis, hemiparesis, and transverse myelitis.

Transverse myelitis is defined as the development of spinal cord dysfunction over hours or days in patients in whom there is no evidence of a compressive lesion. The initial symptoms are paresthesias, back pain, or leg weakness. Patients presenting with acute complete transverse myelitis have a risk of MS of only 5–10%. However, partial or incomplete myelitis is a much more common clinical entity and more relevant to MS; 57–72% of patients with acute partial myelitis as an initial presentation have cranial MRI abnormalities consistent with MS<sup>8,9</sup>.

Lenenercept is another recombinant TNF receptor fusion protein. A double-blind, placebo-controlled phase II study was conducted in 168 patients, most with relapsing-remitting MS, to evaluate whether lenenercept would reduce new lesions on MRI. The number of lenenercept-treated patients expe-

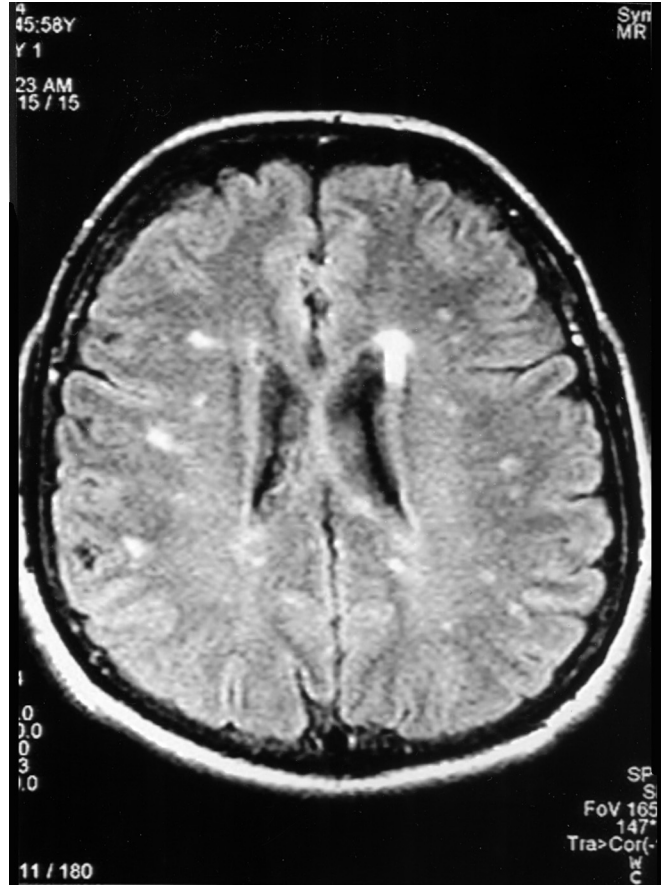


Figure 2. MRI of the brain showing multiple areas of increased signal intensity involving the deep white matter.

riencing exacerbations was significantly increased compared with patients receiving placebo ( $p = 0.007$ ) and their exacerbations occurred earlier ( $p = 0.006$ )<sup>10</sup>.

It seems reasonable to avoid the use of anti-TNF- $\alpha$  agents in patients with established demyelinating disease and to immediately discontinue therapy and pursue diagnostic tests in any patient with suspected demyelination.

NAWAR AL SAIEG, MD, Resident, Department of Internal Medicine, Western Reserve Care System; MICHAEL J. LUZAR, MD, Associate Professor of Medicine, Northeastern Ohio Universities College of Medicine, Director, Division of Rheumatology, Forum Health, Youngstown, Ohio, USA.

#### REFERENCES

1. Mohan N, Edwards ET, Cupps TR, et al. Demyelination occurring during anti-tumor necrosis factor alpha therapy for inflammatory arthritides. *Arthritis Rheum* 2001;44:2862-9.
2. Dayer JM, Beutler B, Cerami A. Cachectin/tumor necrosis factor stimulates collagenase and prostaglandin E<sub>2</sub> production by human synovial cells and dermal fibroblasts. *J Exp Med* 1985;162:2163-8.
3. Bertolini DR, Nedwin GE, Bringman TS, et al. Stimulation of bone resorption and inhibition of bone formation in vitro by human tumour necrosis factors. *Nature* 1986;319:516-8.
4. Saklatvala J. Tumour necrosis factor stimulates resorption and inhibits synthesis of proteoglycan in cartilage. *Nature* 1986;322:547-9.
5. Blumenauer B, Judd M, Cranney A, et al. Etanercept for the



treatment of rheumatoid arthritis. Cochrane Database Syst Rev 2003;CD004525.

6. Moreland LW, Baumgartner SW, Schiff MH, et al. Treatment of rheumatoid arthritis with a recombinant tumor necrosis factor receptor (p75)-Fc fusion protein. *N Engl J Med* 1997;337:141-7.
7. Moreland LW, Schiff MH, Baumgartner SW, et al. Etanercept therapy in rheumatoid arthritis. A randomized, controlled trial. *Ann Intern Med* 1999;130:478-86.
8. Morrissey SP, Miller DH, Kendall BE, et al. The significance of brain magnetic resonance imaging abnormalities at presentation with clinically isolated syndromes suggestive of multiple sclerosis. A 5-year follow-up study. *Brain* 1993;116 Pt 1:135-46.
9. Ford B, Tampieri D, Francis G. Long-term follow-up of acute partial transverse myelopathy. *Neurology* 1992;42:250-2.
10. The Lenercept Multiple Sclerosis Study Group and The University of British Columbia MS/MRI Analysis Group. TNF neutralization in multiple sclerosis: Results of a randomized, placebo-controlled multicenter study. *Neurology* 1999;53:457-65.

### Usefulness of Angioplasty in a Patient with Biopsy-Proven Giant Cell Arteritis and Severe Stenosis of the Superior Mesenteric Artery

To the Editor:

Giant cell arteritis (GCA) involves inflammation of medium to large-size arteries. Symptoms associated with large-vessel vasculitis include aortic arch syndrome with intermittent claudication in the arms. The diagnostic process can be complicated by the absence of clear cranial symptoms. Classical treatment for GCA is long-term corticosteroid therapy. Additional immunosuppressive therapy is recommended, particularly in resistant cases or when there is extensive involvement. Angioplasty and surgical revascularization of stenotic or occlusive lesions are promising complementary therapies to control signs and symptoms when medical treatment fails. We describe a patient who required angioplastic treatment to reduce abdominal pain due to intestinal angina.

A 72-year-old woman was referred to our hospital with claudication of the upper and lower extremities, abdominal discomfort, and weight loss over the past 9 months. She had no notable history. She had a poor appetite and postprandial abdominal pain, but denied bowel habit changes or

bloody or tarry stools. Claudication of the extremities had severely limited her daily activities.

On examination, vital signs were stable and no fever was recorded. Absent pulses (radial, humeral, pedius, tibial, and popliteus) were recorded. No focal neurological, cardiorespiratory, or abdominal findings of pathological value were observed.

Laboratory tests showed leukocytes  $17.2 \times 10^9/l$ , hemoglobin 103 g/l, albumin 32 nmol/l, C-reactive protein 87 mg/l and erythrocyte sedimentation rate 96 mm/h, creatine phosphokinase 20 U/l, and troponin T < 0.01  $\mu\text{g/l}$ . Previous outpatient investigation for occult blood in stools was negative. Nevertheless, upper and lower gastrointestinal (GI) tract endoscopy was normal.

No infectious focus was identified in repeated cultures and thoracoabdominal computed tomography was normal. Color duplex ultrasonography of limbs showed diffuse involvement of all arteries. Angiography of the abdomen and limbs revealed extensive diffuse vasculopathy with critical stenosis and occlusions compatible with inflammatory vasculitis (Figure 1). Considering the patient's age and the presence of severe vasculopathy associated with elevation of acute phase reactants, a diagnosis of GCA was considered. Because of that, a temporal artery biopsy was performed; this showed signs of active arteritis with multinucleated giant cells.

Large-vessel arteritis was diagnosed and prednisolone (40 mg daily) and intravenous pulse cyclophosphamide were prescribed.

She underwent a marked improvement of clinical signs and symptoms and inflammatory markers decreased, but abdominal pain continued. A second abdominal arteriography revealed severe stenosis of the superior mesenteric artery and an angioplasty was performed (Figure 2). Abdominal pain ceased completely after this intervention. Prednisolone prescription was maintained in a decreasing dosage until discontinuation.

GCA is easily recognized when cardinal signs and symptoms are present. However, in spite of extensive involvement of the aorta and other extracranial large vessels, patients do not always exhibit clinical manifestations<sup>1</sup>, or those they do present may be uncommon<sup>2</sup>. Diagnosis is difficult in such cases.

Our patient had clinical symptoms and signs of limb claudication, but with abdominal involvement. Walz-Leblanc, *et al*<sup>3</sup> found 26 cases with upper limb involvement. However, none presented ischemic manifestations in other locations.

Stenwig<sup>4</sup> reported the first well documented case of intestinal ischemia. Subsequent reports<sup>5-7</sup> described intestinal ischemia as an uncommon presentation of generalized GCA. Our case is unique in that different locations were affected — both upper and lower limbs and the GI tract.

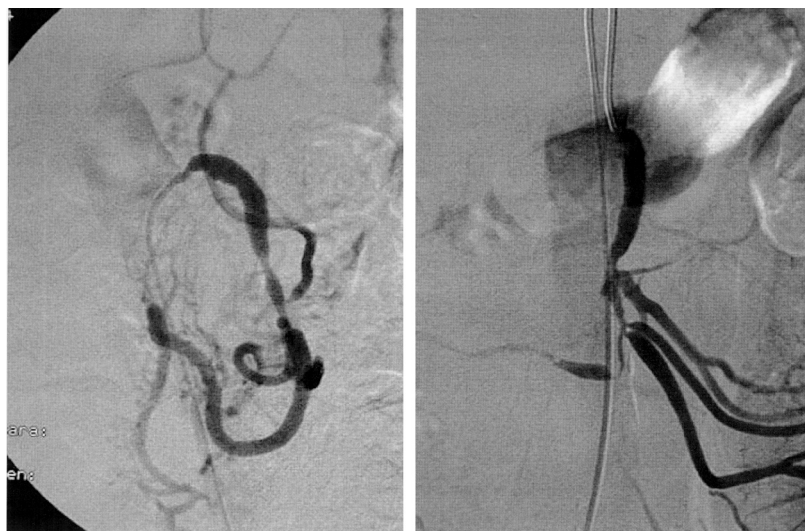


Figure 1. Selective angiography studies showing vasculopathy. Stenosis of ostium and occlusion of ileocolic artery are visible.

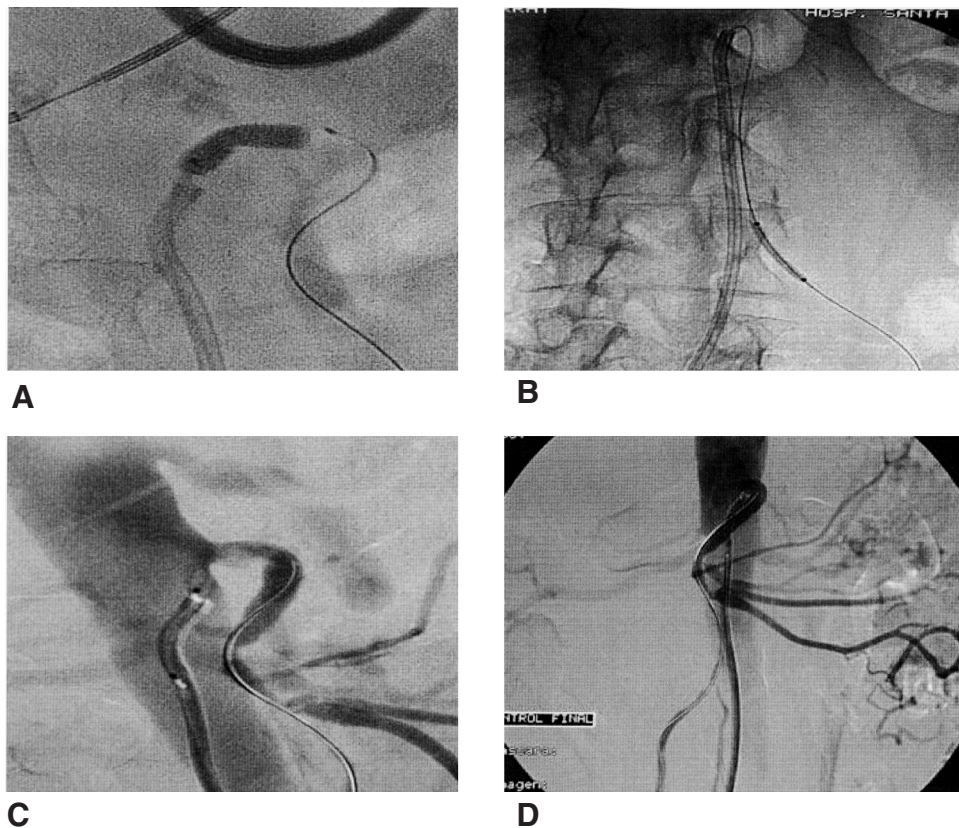


Figure 2. A. Angioplasty of the ostium of the superior mesenteric artery. B. Angioplasty of a branch of the superior mesenteric artery. C. Result after ostium lesion angioplasty. D. Result of angioplasties with repermeabilization of the ileocolic artery.

Due to the extensive vascular involvement in our patient we decided to initiate a daily dose of 40 mg prednisolone simultaneously with pulses of intravenous cyclophosphamide. This decision was based on a study by de Vita, *et al*<sup>8</sup> that reported a rapid response and significant decrease in corticosteroid dosage with the use of short-term cyclophosphamide pulse treatment plus glucocorticoids.

Like Both, *et al*<sup>9</sup>, we performed an abdominal angioplasty as symptomatic treatment despite little experience to date in the percutaneous management of occlusive or stenotic arterial disease associated with GCA. Both, *et al* evaluated the safety and effectiveness of percutaneous transluminal angioplasty for occlusive arterial disease associated with vasculitis. Eleven patients (8 with GCA, 3 with Takayasu's arteritis) underwent interventional treatment during intraarterial angiography. Technical success was 100% for stenosis and 50% for occlusive lesions. As well, successful response to angioplasty in a patient with upper limb ischemia secondary to GCA has been reported by Monte, *et al*<sup>10</sup>.

An appreciation of GCA as a disease affecting the aorta and its proximal branches rather than branch arteries alone, and awareness that atypical presentations are common, will result in fewer missed and delayed diagnoses. Finally, although our report describes only one case, the outcome suggests that interventional therapy might offer a new approach to the treatment of GCA as complementary therapy when ischemic symptoms persist despite adequate medical treatment. Controlled studies are warranted to formally address this issue.

SONIA SERRADELL, MD, Senior Resident; ANA LAIZ, MD; CARLOS CASTAÑO, MD; JOSEP MARÍA de LLOBET, MD, Department of Internal Medicine, Hospital de la Santa Creu i Sant Pau, Sant Antoni Maria i Claret 167, 167-08025 Barcelona, Spain. E-mail: sserradell@santpau.es

## REFERENCES

- Gonzalez-Gay MA, Barros S, Lopez-Diaz MJ, et al. Giant cell arteritis: disease patterns of clinical presentation in a series of 240 patients. *Medicine Baltimore* 2005;84:269-76.
- Greene GM, Lain D, Sherwin RM, Wilson JE, McManus BM. Giant cell arteritis of the legs. Clinical isolation of severe disease with gangrene and amputations. *Am J Med* 1986;81:727-33.
- Walz-Leblanc BA, Ameli FM, Keystone EC. Giant cell arteritis presenting as limb claudication. Report and review of the literature. *J Rheumatol* 1991;18:470-2.
- Stenwig JT. Intestinal gangrene due to giant-cell arteritis. Report of a case. *J Oslo City Hosp* 1976;26:49-55.
- Trimble MA, Weisz MA. Infarction of the sigmoid colon secondary to giant cell arteritis. *Rheumatology Oxford* 2002;41:108-10.
- Krant JD, Ross JM. Extracranial giant cell arteritis restricted to the small bowel. *Arthritis Rheum* 1992;25:603-4.
- Phelan MJ, Kok K, Burrow C, Thompson RN. Small bowel infarction in association with giant cell arteritis. *Br J Rheumatol* 1993;32:63-5.
- de Vita S, Tavoni A, Jeracitano G, Gemignani G, Dolcher MP, Bombardieri S. Treatment of giant cell arteritis with cyclophosphamide pulses. *J Intern Med* 1992;232:373-5.
- Both M, Jahnke T, Reinhold-Keller E, et al. Percutaneous management of occlusive arterial disease associated with vasculitis: a single center experience. *Cardiovasc Intervent Radiol* 2003;26:19-26. Epub 2003 Jan 16.
- Monte R, Gonzalez-Gay MA, Garcia-Porrúa C, Lopez-Alvarez MJ, Pulpeiro JR. Successful response to angioplasty in a patient with upper limb ischemia secondary to giant cell arteritis [letter]. *Br J Rheumatol* 1998;37:344.

## Development of Polymyalgia Rheumatica in Patients with Scleroderma

To the Editor:

Systemic sclerosis (SSc) and polymyalgia rheumatica (PMR) are uncommon but not rare rheumatic diseases. Nonetheless, we have been able to identify only 2 previous case reports of these diseases occurring in the same patient<sup>1,2</sup>. We now describe 4 patients with established SSc who were subsequently diagnosed with PMR. The various musculoskeletal symptoms that accompany SSc can make the recognition of PMR challenging in these patients<sup>3,4</sup>. In addition, the standard therapy for PMR is corticosteroids, which have been implicated in precipitating scleroderma renal crisis (SRC)<sup>5</sup>. Thus, these cases have significance for the potential diagnostic and management problems that arise when these 2 disorders occur together.

Clinical profiles of our 4 patients are summarized in Table 1. All patients were female (mean age at onset of SSc 59 yrs; mean age at onset of PMR 64 yrs) and 3 of 4 patients had the diffuse cutaneous form of the disease (dcSSc). One patient previously had SRC, but had a stable creatinine of 1.8 mg/dl when PMR was diagnosed. Each patient responded appropriately to low-dose prednisone (mean initial dose 11.9 mg/day) and was successfully tapered. None experienced hypertension or renal compromise while receiving corticosteroids. Experience with the patients described here provides a framework to discuss the co-occurrence of PMR and SSc, and in particular the unique management issue related to the use of corticosteroids in SSc.

The prevalence of scleroderma has been estimated to be between 4 and 253 cases/million<sup>6</sup>. PMR/temporal arteritis occurs in patients over the age of 50 years at a prevalence of 700 cases/100,000 population<sup>6</sup>. Based on a review of the cases noted here, we suspect that PMR and SSc occur together more frequently than suggested by the paucity of articles in the literature. The 4 were identified from a cohort of about 80 patients with SSc actively followed at our institution during this period of observation. However, these data from a single center are unlikely to be a valid estimate of the incidence or prevalence of PMR in the general SSc population.

Musculoskeletal symptoms in SSc occur frequently and include arthralgia, inflammatory arthritis, myopathy, and frank myositis<sup>3,4</sup>. Diffuse soft tissue swelling may occur early in the course of the disease during the edematous or inflammatory stage of SSc. This presentation can be difficult to distinguish from inflammatory arthritis or another systemic rheumatic disease. Subsequently, patients can develop a mildly inflammatory polyarthri-

tis, which may be erosive. Patients with SSc frequently have muscle involvement, ranging from disuse atrophy to inflammatory myositis, with elevation of creatine kinase concentrations. Finally, patients may also experience musculoskeletal symptoms secondary to osteoarthritis or soft tissue rheumatism. Given the variety of musculoskeletal symptoms that can occur in SSc, recognizing PMR can be challenging.

Several reports previously suggested a causal relationship between the use of corticosteroids and the precipitation of SRC<sup>5,7</sup>. SRC is defined as rapidly progressive renal failure with or without the new onset of accelerated hypertension. This complication occurs in about 10% of all patients with SSc and up to 20% of patients with dcSSc<sup>8</sup>. While SRC has mostly been reported in patients with dcSSc, in a study from the University of Pittsburgh, 3 of 60 patients with SRC were classified as having CREST syndrome (calcinosis, Raynaud's, esophageal dysmotility, sclerodactyly, telangiectasias)<sup>9</sup>. Risk factors associated with SRC include early disease, rapidly progressive skin thickening, prednisone use, and congestive heart failure<sup>7,9</sup>. Three of the 4 patients in this report had dcSSc and 2 developed PMR within 2.5 years of being diagnosed with SSc. One-year survival for patients with SRC treated with angiotensin-converting enzyme (ACE) inhibitors is 76% compared to 15% in patients in the pre-ACE-inhibitor era<sup>10</sup>. Despite significant improvements in treating this life-threatening complication, SRC continues to be an important cause of early morbidity and mortality in patients with SSc.

In 1998, Steen and Medsger attempted to define the relationship between corticosteroids and the risk of SRC by reviewing their experience with a large population of patients with SSc<sup>5</sup>. That case-control study analyzed 110 patients with SRC and compared them to controls matched for age and sex. They found that the addition of high-dose corticosteroids ( $\geq 15$  mg prednisone/day) within the previous 6 months was a significant risk factor for development of SRC (OR 4.37). The addition of low-dose corticosteroids ( $< 15$  mg prednisone daily) was not associated with a statistically significant increased risk.

We conclude that PMR may develop in the setting of well established SSc and that an appropriate index of clinical suspicion be raised if a characteristic symptom complex develops with supporting laboratory data. While the prevalence of these 2 disorders occurring together is not known, we suspect that it is higher than previously reported. While there is concern regarding the use of corticosteroids in patients with SSc, standard low-dose corticosteroids were well tolerated in our 4 cases. This is consistent with the analysis by Steen and Medsger that prednisone doses  $< 15$  mg/day were

Table 1. Summary of patient demographics and clinical characteristics. All patients were female.

	Patient 1	Patient 2	Patient 3	Patient 4
Current age, yrs	62	68	82	59
lcSSc	-	-	-	+
Raynaud's phenomenon	+	+	+	+
Age at onset of SSc, yrs	54	60	68	54
Age at onset of PMR, yrs	59	62	80	55
ANA titer	1:320	1:640	1:160	1:640
Anti-topoisomerase I	-	+	-	-
Anti-centromere	-	-	-	+
ESR, mm/h	52	110	NA**	44
Symptoms of temporal arteritis	No	No	No	No
Prior renal disease*	-	-	+	-
Initial prednisone dose, mg/day	20	7.5	10	10
SRC	No	No	No	No
At risk for SRC	No	No	Yes	No
Prednisone dose at last visit, mg/day	0	4	5	1

\* Patient 3 experienced renal crisis at age 70 that was successfully treated with angiotensin-converting enzyme inhibitors; baseline creatinine 1.8 mg/dl. \*\* Not applicable: ESR not performed in this patient prior to corticosteroid therapy. lcSSc: limited cutaneous SSc, ESR: erythrocyte sedimentation rate, SRC: scleroderma renal crisis after initiation of corticosteroids for PMR.



not associated with an increased risk of SRC<sup>5</sup>. However, further studies are needed to confirm these findings and we would still recommend caution in these patients.

IRENE M. ORZANO, MD, Rheumatology Fellow; EDWARD V. LALLY, MD, Director, Division of Rheumatology, Department of Medicine, Rhode Island Hospital and Brown Medical School, Associate Professor of Medicine, Brown Medical School, 2 Dudley Street, Suite 370, Providence, Rhode Island 02905, USA.  
E-mail: elally@lifespan.org

## REFERENCES

1. Perez-Jimenez F, Lopez-Rubio F, Canadillas F, Jimenez-Alonzo J, Jimenez-Perez J. Giant cell arteritis associated with progressive systemic sclerosis [letter]. *Arthritis Rheum* 1982;25:717-8.
2. Hupp SL. Giant cell arteritis associated with progressive systemic sclerosis. *J Neuroophthalmol* 1989;9:126-30.
3. Seibold JR. Scleroderma. In: Harris Jr ED, Budd RC, Firestein GS, et al, editors. *Kelley's textbook of rheumatology*. 7th ed. Philadelphia: W.B. Saunders; 2004:1279-306.
4. Pope JE. Musculoskeletal involvement in scleroderma. *Rheum Dis Clin North Am* 2003;29:391-408.
5. Steen VD, Medsger TA Jr. Case-control study of corticosteroids and other drugs that either precipitate or protect from the development of scleroderma renal crisis. *Arthritis Rheum* 1998;41:1613-9.
6. Lawrence RC, Helmick CG, Arnett FC, et al. Estimates of the prevalence of arthritis and selected musculoskeletal disorders in the United States 1998;41:778-99.
7. DeMarco PJ, Weisman MH, Siebold JR, et al. Predictors and outcome of scleroderma renal crisis: the high-dose versus low-dose d-penicillamine in early diffuse systemic sclerosis trial. *Arthritis Rheum* 2002;46:2983-9.
8. Steen VD. Scleroderma renal crisis. *Rheum Dis Clin North Am* 1996;22:861-78.
9. Steen VD, Medsger TA Jr, Osial TA Jr, Ziegler GL, Shapiro AP, Rodnan GP. Factors predicting development of renal involvement in progressive systemic sclerosis. *Am J Med* 1984;76:779-86.
10. Steen VD, Costantino JP, Shapiro AP, Medsger TA Jr. Outcome of renal crisis in systemic sclerosis: relation to availability of angiotensin converting enzyme inhibitors. *Ann Intern Med* 1990;113:352-7.

## Interstitial Granulomatous Dermatitis with Arthritis (Ackerman Syndrome)

To the Editor:

Interstitial granulomatous dermatitis with arthritis (IGDA), also known as Ackerman syndrome, is an uncommon idiopathic dermatosis with variable cutaneous expression, including subcutaneous linear cords or bands, plaques, and papules. Although rare, since its first description by Ackerman, *et al* in 1993<sup>1</sup>, an increasing number of additional cases of IGDA have been reported during recent years<sup>2-11</sup>. Despite this, IGDA is not usually considered by rheumatologists in the differential diagnosis of cutaneous lesions associated with arthritis. We describe a new case of IGDA and review the literature to summarize the clinical characteristics and prognosis of this entity.

A 44-year-old woman was referred for evaluation of a 2-month history of polyarthritis and skin lesions. She had a history of breast cancer diagnosed 2 years previously, which was treated with surgery (mastectomy and lymphadenectomy), followed by adjuvant radiotherapy, chemotherapy, and hormone therapy with tamoxifen, and was in complete clinical remission.

Physical examination showed a symmetrical nondeforming synovitis involving shoulders, elbows, wrists, metacarpophalangeal and proximal interphalangeal hand joints, knees, and ankles, and large indurated erythematous plaques on the lateral aspects of the trunk and inner aspects of the limbs. They were not painful or pruriginous. On questioning she denied any constitutional symptoms or Raynaud's phenomenon.

Laboratory data were unremarkable except for an elevated erythrocyte sedimentation rate (21 mm/h) and C-reactive protein (34 mg/dl), with mild anemia (hemoglobin level, 10 g/l). Plain radiographs of the involved joints were unremarkable except for soft tissue swelling. Chest radiograph, computed tomographic scan of the chest and abdomen, a magnetic resonance study of the affected arms, an echocardiogram, and a nailfold capillaroscopy were normal. Tumor markers and serologic tests for Lyme disease and syphilis were also negative. Antinuclear antibodies (ANA) were found positive in low titer (1:80), as well as the anti-Ro/SSA antibodies; rheumatoid factor (RF), anti-dsDNA, Sm, La/SSB, RNP, antineutrophil cytoplasmic antibodies (ANCA), anti-Jo-1, Scl-70, and anticentromere antibodies were negative. Skin biopsy results from one of the lesions revealed an infiltration of the reticular dermis with a predominance of interstitial and palisadic histiocytes with a few areas of degenerating collagen bundles associated with a variable number of polynuclear neutrophils and eosinophils (Figure 1). The patient was finally diagnosed with IGDA.

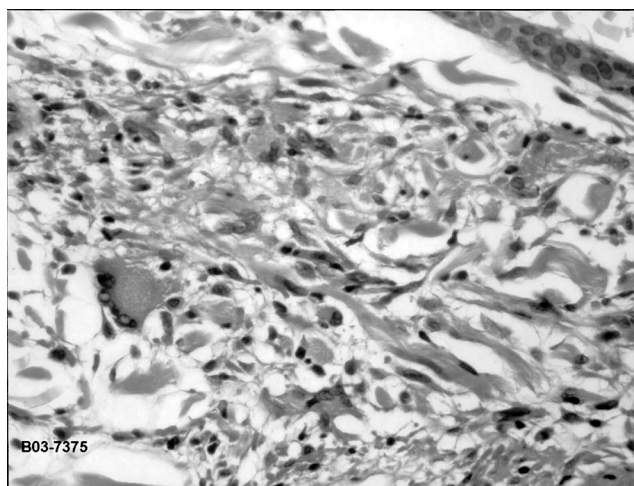
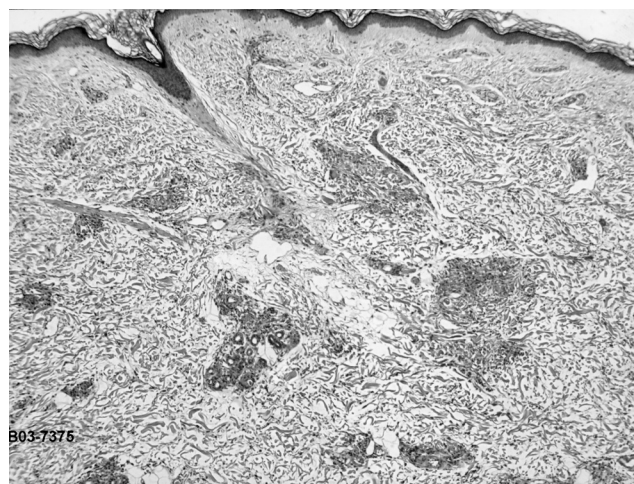


Figure 1. Histopathology, overview: A. Low power magnification shows a diffuse dense inflammatory infiltrate within reticular dermis. B. Medium magnification shows the infiltrate is composed mostly of histiocytes, scanty neutrophils, and plasma cells.

Table 1. Clinical features, treatment and outcome of patients with interstitial granulomatous dermatitis with arthritis (IGDA).

Patient	Age/Sex	Temporal Relationship Between Cutaneous and Articular Symptoms*	Articular Involvement	Cutaneous Lesions	Serologic Findings	Treatment	Outcome
1	53/F	1	Nonerosive seronegative oligoarthritis	Papules and annular plaques		NSAID, topical CS	Cured
2	65/M	2	Symmetrical nonerosive seronegative polyarthritis involving small joints of hands	Annular plaques		NSAID, topical CS	Cured
3	53/F	3	Symmetrical nonerosive seronegative polyarthritis involving small and large joints	Violaceous plaques and subcutaneous nodules		Cyclosporin A 200 mg/daily (other treatments previously assayed: MTX was stopped because of cytopenias, and SSZ was not effective)	Arthritis improved; skin lesions cured
4	40/M	2	Symmetrical nonerosive seronegative polyarthritis involving wrists, knees, and small joints of hands and feet	Subcutaneous linear cords	ANA	CS, Dapsone, and hydroxy-chloroquine (other treatments previously assayed: MTX, AZA, and CTX singly and in combination, but discontinued because of lack of benefit)	Improvement
5	73/M	1	Asymmetric nonerosive oligoarthritis involving hands	Subcutaneous linear cords	RF, ANA, Anti-dsDNA	NSAID, topical CS, hydroxychloroquine, dapsone	Flares and partial remissions
6	58/F	NA	Nonerosive seronegative oligoarthritis	Erythematous plaques	Anti-thyroglobulin	NSAID, CS	Cured
7	74/F	NA	Nonerosive seronegative oligoarthritis	Erythematous plaques	Anti-thyroglobulin	NSAID, CS	Cured
8**	62/F	2	Symmetrical nonerosive seronegative polyarthritis involving small and large joints	Erythematous plaques and subcutaneous nodules	p-ANCA	Surgical removal of the lung cancer and NSAID	Cured
9	56/F	3	Migratory polyarthralgia/arthritis involving hands, feet, wrists, and ankles	Annular plaques	Anti SSA, ANA, Antihistones	CS	NA (lost to followup)
10	26/F	3	Migratory polyarthralgia/arthritis of the hands, feet, and knees	Annular plaques		NSAID, topical CS	Joints symptoms improved; skin lesions persisted
11	78/M	3	Polyarthralgia/arthritis involving hands	Erythematous papules and plaques	RF, ANA	CS	Cured
Our case	44/F	2	Symmetrical nonerosive seronegative polyarthritis involving small and large joints	Erythematous plaques	ANA	CS	Cured

\* Temporal relationship between cutaneous and articular symptoms: 1 = cutaneous lesions preceded the onset of arthritis; 2 = simultaneous onset; 3 = arthritis preceded the skin lesions. \*\* Lung cancer was concurrently discovered with the diagnosis of IGDA. ANA: antinuclear antibodies; ANCA: antineutrophil cytoplasmic antibodies; AZA: azathioprine; CTX: cyclophosphamide; CS: corticosteroids; MTX: methotrexate; NA: not available; NSAID: nonsteroidal anti-inflammatory drugs; RF: rheumatoid factor; SSZ: sulfasalazine.

Corticosteroids were administered in variable doses (30 to 5 mg daily of prednisone) and the skin lesions as well as the arthritis resolved entirely within 18 weeks. At the present time the patient is completely symptom-free.

IGDA is an uncommon condition of unknown etiology that primarily

affects middle-aged patients<sup>1-11</sup>. It presents with cutaneous and joint manifestations; the main clinical characteristics and outcome of published cases of IGDA<sup>3-6,8-11</sup> are summarized in Table 1 (only cases that were sufficiently detailed to be individually analyzed were included). Cutaneous manifestations are variable<sup>1-11</sup>; most typical are large subcutaneous linear



cords or bands, often producing a rope-like configuration, extending from the axillae down the lateral aspects of the trunk. In fact, the “rope sign” is considered a pathognomonic clinical feature of IGDA. In other cases, cutaneous lesions are annular or erythematous to violaceous plaques generally located on the limbs, lateral aspects of the trunk, or buttocks, without the rope sign; some of these patients also present subcutaneous nodules or erythematous papules. Although some of these lesions may mimic other dermatoses including inflammatory stages of linear scleroderma, eosinophilic fasciitis, granuloma annulare, and erythema chronicum migrans, the histology of IGDA is distinctive and characterized by a diffuse dense inflammatory infiltrate, composed mostly of histiocytes within reticular dermis. Small foci of degenerated collagen and histiocytes are arranged in palisades. The presence of neutrophils and eosinophils can be an additional finding in the infiltrate. Mucin deposition and vasculitis are not expected. Recently, the name palisaded neutrophilic and granulomatous dermatitis has been proposed to include IGDA and other similar conditions<sup>12-14</sup>.

The arthritis accompanying these skin lesions may appear before, during, or many years after the onset of the cutaneous lesions. Joint involvement is usually symmetrical, and mainly affects the small joints of hands, wrists, elbows, and shoulders. In fact, some of these patients fulfil American College of Rheumatology (ACR) classification criteria for rheumatoid arthritis (RA)<sup>15</sup>, but their arthritis usually follows a relatively benign course, is generally nondeforming and nonerosive, and it does not go along with rheumatoid nodules. In addition, development of interstitial granulomatous dermatitis in patients with classic erosive RA has also been documented<sup>2,7,13,14</sup>.

Of interest, isolated cases associated with neoplasia<sup>10</sup> and systemic diseases other than RA, such as autoimmune thyroiditis, vitiligo, and hemolytic anemia, have also been reported<sup>2,7,9</sup>. Moreover, some patients with IGDA are reported to have positive rheumatoid factor and autoantibodies, such as ANA, anti-dsDNA, anti-Ro/SSA, antihistones, ANCA, and antithyroglobulin antibodies<sup>6,8-11</sup>.

The cause of IGDA is currently unknown, although the occasional positivity of RF and/or other autoantibodies and the association with a variety of autoimmune disorders support the hypothesis that autoimmune mechanisms may be involved<sup>2</sup>. The optimal therapy for IGDA is difficult to establish, since the available experience is anecdotal. Most relief is achieved with nonsteroidal antiinflammatory drugs (NSAID) and topical corticosteroids or prednisone (usually with an initial dose of 30 mg/day). In some cases, the course of the disease is characterized by flares and remissions.

In conclusion, IGDA is rare and relatively unknown to rheumatologists, but we believe it should be considered in the differential diagnosis of cutaneous lesions associated with arthritis.

NOEMI BUSQUETS-PÉREZ, MD; JAVIER NARVAEZ, MD, PhD,  
E-mail: 31577edd@comb.es; JOSE VALVERDE-GARCÍA, MD, PhD,  
Department of Rheumatology, Hospital Universitario de Bellvitge-IDIBELL, Barcelona 08907, Spain.

## REFERENCES

- Ackerman AB, Guo Y, Vitale P, Vossaert K. Clues to diagnosis in dermatopathology, Volume 3. Chicago: ASCP Press; 1993:309-12.
- Crowson AN, Magro C. Interstitial granulomatous dermatitis with arthritis. *Hum Pathol* 2004;35:779-80.
- Altaykan A, Erkin G, Boztepe G, Gokoz A. Interstitial granulomatous dermatitis with arthritis. *Hum Pathol* 2004;35:892-4.
- Banuls J, Betlloch I, Botella R, et al. Interstitial granulomatous dermatitis and arthritis. *Eur J Dermatol* 2003;13:308-10.
- Wollina U, Schönlebe J, Unger L, Weigel K, Köstler E, Nüsslein H. Interstitial granulomatous dermatitis with plaques and arthritis. *Clin Rheumatol* 2003;22:347-9.
- Kroesen S, Itin PH, Hasler P. Arthritis and interstitial granulomatous dermatitis (Ackerman syndrome) with pulmonary silicosis. *Semin Arthritis Rheum* 2003;5:334-40.
- Tomasini C, Pippione M. Interstitial granulomatous dermatitis with plaques. *J Am Acad Dermatol* 2002;46:892-9.
- Verneuil L, Domp Martin A, Comoz F, Pasquier CJ, Leroy D. Interstitial granulomatous dermatitis with cutaneous cords and arthritis: a disorder associated with autoantibodies. *J Am Acad Dermatol* 2001;45:286-91.
- Aloi F, Tomasini C, Pippione M. Interstitial granulomatous dermatitis with plaques. *Am J Dermatopathol* 1999;21:320-3.
- Schreckenber C, Asch PH, Sibilía J, et al. Interstitial granulomatous dermatitis and paraneoplastic rheumatoid polyarthritis disclosing cancer of the lung. *Ann Dermatol Venereol* 1998;125:585-8.
- Long D, Thiboutot DM, Majeski JT, Vasily DB, Helm KF. Interstitial granulomatous dermatitis with arthritis. *J Am Acad Dermatol* 1996;34:957-61.
- Al-Daraji WI, Coulson IH, Howat AJ. Palisaded neutrophilic and granulomatous dermatitis. *Clin Exp Dermatol* 2005;30:578-9.
- Bremner R, Simpson E, White CR, Morrison L, Deodhar A. Palisaded neutrophilic and granulomatous dermatitis: an unusual cutaneous manifestation of immune-mediated disorders. *Semin Arthritis Rheum* 2004;34:610-6.
- Chu P, Connolly MK, LeBoit PE. The histopathologic spectrum of palisaded neutrophilic and granulomatous dermatitis in patients with collagen vascular disease. *Arch Dermatol* 1994;130:1278-83.
- Arnett FC, Edworthy SM, Bloch DA, et al. The American Rheumatism Association 1987 revised criteria for the classification of rheumatoid arthritis. *Arthritis Rheum* 1988;31:315-24.

## Granulomatous Uveitis Revealing Wegener's Granulomatosis

To the Editor:

Wegener's granulomatosis (WG) is a systemic vasculitis of unknown origin characterized by prominent involvement of upper and lower respiratory tract and kidney. Histological pattern consists of the triad of giant cell granuloma, necrosis, and vasculitis involving capillaries and small and middle size arterioles. Ocular involvement, present in nearly half of patients with WG, is uncommonly the presenting feature. We describe a case of localized WG that presented as severe recurrent uveitis.

Our patient, a French man born in 1950, was referred in 2001 to the Department of Internal Medicine for recurrent right anterior uveitis evolving since 1985 and treated with corticosteroid subconjunctival injections and/or eyedrops. Sudden loss of vision occurred in August 2000, and 4 months before that, sore throat, left hearing loss, temporal headaches, and myalgias developed. Visual acuity was reduced to perception of light in the right eye and 20/50 in the left eye. Arterial pressure was 105/60 mm Hg. Tuberculin testing was positive. Ophthalmologic examination revealed “granulomatous” panuveitis with retinal vasculitis and severe macular cystoid edema. Laboratory tests showed leukocyte count 6400/mm<sup>3</sup>, hemoglobin 13.8 g/dl, platelet count 300,000/mm<sup>3</sup>, and erythrocyte sedimentation rate 6 mm/h. Angiotensin-converting enzyme was 62 U/l (n = 40–100). Proteinuria and hematuria were absent, serum creatinine was 110 μmol/l. Antineutrophil cytoplasmic antibody (ANCA) testing was positive with cytoplasmic fluorescence, but antigenic specificity remained undetermined. Thoracic computerized tomographic (CT) scan displayed a middle lobe right cavitating nodule. Sinus CT scan was normal. Bronchoalveolar lavage fluid examination showed 140,000 cells/ml consisting of 75% macrophages with 75% siderophages. Surgical pulmonary lung biopsy disclosed giant-cell granulomatous inflammation involving pulmonary parenchyma, bronchi wall, and pleura associated with necrosis and vasculitis. Corticosteroid therapy was started with 1g methylprednisolone pulse for 3 days, followed by 50 mg daily prednisone, as well as 1 g intravenous cyclophosphamide pulse. Visual acuity increased to 20/100 in the right eye and 20/25 in the left eye, with disappearance of macular cystoid edema, and chest radiograph normalized. In November 2002, after the 8th

pulse, cyclophosphamide was switched to methotrexate 15 mg weekly as prednisone dosage was 13 mg daily. In March 2003, his uveitis relapsed, with decreased visual acuity to 20/100 in the right eye and 20/50 in the left. Ophthalmologic examination revealed interstitial keratitis, mild anterior uveitis, posterior uveitis, and retinal vasculitis. As increasing prednisone dosage up to 25 mg daily was ineffective, intravenous cyclophosphamide was reinstated in May 2003. In November 2003, cyclophosphamide was replaced by 3 g daily mycophenolate mofetil because of hematuria without proteinuria. At present, he is in remission with 15 mg daily prednisone and 3 g daily mycophenolate mofetil. ANCA testing was negative. Visual acuity improved to 20/20 in the left eye after a cataract surgery.

Our patient had localized WG with upper respiratory tract and pulmonary involvement confirmed by the presence of necrotic giant-cell granuloma and vasculitis at histological examination of pulmonary biopsy, thereby fulfilling the American College of Rheumatology (ACR)<sup>1</sup> and the Chapel Hill criteria for WG<sup>2</sup>. He had 2 uncommon features of WG: (1) the disease presented as ocular involvement that remained isolated for 15 years before occurrence of upper respiratory tract and pulmonary involvement, and (2) ocular involvement consisted of uveitis.

Ocular involvement is present in 28–58% of patients with WG and is a presenting feature in 8–16% of the cases. In a study of 33 patients with systemic WG and ocular involvement, Harper, *et al*<sup>3</sup> observed only 3 patients who had initial ocular inflammation and subsequently developed systemic WG in an average of 22 months. In all these cases, ocular involvement consisted of scleritis. Besides cases of systemic WG, they also identified 14 patients with isolated ocular involvement with histopathologic findings suggestive of WG based on granulomatous inflammation and vasculitis in ocular tissues. Ocular involvement consisted of scleritis (n = 10), keratitis, episcleritis, and muscle pseudotumor. However, isolated ocular involvement, even when associated with giant cell granuloma and vasculitis, is not sufficient to fulfil ACR criteria for WG, which require at least 2 of the following 4 criteria, yielding a sensitivity of 88% and a specificity of 92%: (1) oral ulcers or purulent or bloody nasal discharge, (2) nodules or fixed infiltrates or cavities, (3) microhematuria or red cell casts, and (4) granulomatous inflammation within the wall of an artery or extravascular area<sup>1</sup>. In the Chapel Hill nomenclature, WG is defined as a granulomatous inflammation involving the respiratory tract, and necrotizing vasculitis affecting small to medium-size vessels with a common necrotizing glomerulonephritis<sup>2</sup>.

Anterior uveitis is not a frequent ophthalmologic feature of WG. Granulomatous anterior uveitis associated with vitritis was present in one out of 15 patients in the series reported by Haynes, *et al*<sup>4</sup>. These authors emphasized that uveitis was not previously described in WG. However, 20 years earlier, Straatsma<sup>5</sup> found 3 cases of uveal involvement in 15 patients with WG and ocular involvement. The uveal aspect was not described, but histologic confirmation was obtained in 2 cases with vasculitis and granuloma on uveal tissue. Stavrou, *et al*<sup>6</sup> found no cases of anterior uveitis in 29 patients with WG and ocular involvement. Uveitis was present in 4 out of 40 patients with ocular WG in a series reported by Bullen, *et al*<sup>7</sup>. Two had cystoid macular edema associated with “snowballs” in the peripheral fundus and pars planitis.

Our patient was positive for ANCA with cytoplasmic fluorescence, but the antigenic specificity was not determined. ANCA are present in almost 90% of cases of WG, usually directed against proteinase 3. Their specificity is 98% for systemic vasculitis, mainly WG, but also micropolyangiitis and crescentic glomerulonephritis. Hence, negative testing against proteinase 3 does not exclude diagnosis of WG.

In conclusion, WG should be added to the list of causes of chronic uveitis.

DU LE THI HUONG, MD, PhD, Department of Internal Medicine;  
THI HA CHAU TRAN, MD, Department of Ophthalmology; JEAN-CHARLES PIETTE, MD, Department of Internal Medicine, Groupe Hospitalier Pitié-Salpêtrière, 83 boulevard de l'Hôpital, 75013 Paris, France.

## REFERENCES

1. Leavitt RY, Fauci AS, Bloch DA, et al. The American College of Rheumatology 1990 criteria for the classification of Wegener's granulomatosis. *Arthritis Rheum* 1990;33:1101-7.
2. Jennette JC, Falk U, Andrassy K, et al. Nomenclature of systemic vasculitides. Proposal of an International Consensus Conference. *Arthritis Rheum* 1994;37:187-92.
3. Harper SL, Letko B, Samson M, et al. Wegener's granulomatosis: the relationship between ocular and systemic disease. *J Rheumatol* 2001;28:1025-32.
4. Haynes BF, Fishman ML, Fauci AS, Wolff SM. The ocular manifestations of Wegener's granulomatosis. Fifteen years experience and review of the literature. *Am J Med* 1977;63:131-41.
5. Straatsma BR. Ocular manifestations of Wegener's granulomatosis. *Am J Ophthalmol* 1957;44:789-99.
6. Stavrou P, Deutsch J, Rene C, Laws DE, Luqmani RA, Murray PI. Ocular manifestations of classical and limited Wegener's granulomatosis. *Q J Med* 1983;86:719-25.
7. Bullen CL, Liesegang TJ, McDonald TJ, DeRemee RA. Ocular complications of Wegener's granulomatosis. *Ophthalmology* 1983;90:279-90.

---

## A Boy with Fever and Whorl Keratopathy

To the Editor:

Tumor necrosis factor receptor-associated periodic syndrome (TRAPS) and Fabry disease are both uncommon genetic disorders characterized by multisystem involvement (Table 1). We describe for the first time a patient with the coexistence of these 2 conditions.

A 9-year-old boy presented to our rheumatology clinic for evaluation for recurrent febrile episodes. About every 8 weeks he developed fever (up to 105°F), arthralgias, myalgias, headache, abdominal pain, nausea, vomiting, cough, and hyperparesthesias affecting the extremities. The year prior to his evaluation at our clinic he also developed decreased visual acuity and arthralgias and myalgias that were not associated with febrile episodes.

Physical examination was remarkable for eyelid swelling, thinning of the subcutaneous tissue of the extremities, and presence of angiokeratomas. Ophthalmologic examination revealed subepithelial, anterior stromal whorl-like deposits, a characteristic infiltrate seen in Fabry disease. The finding of a reduced  $\alpha$ -galactosidase A level measured in both plasma (0.3 U/ml; reference range 6.20–18.6 U/ml) and in leukocytes (0.4 U/mg; reference range 12.8–74.1 U/mg) along with identification of a missense mutation in the patient's  $\alpha$ -galactosidase gene confirmed the presence of Fabry disease.

An additional diagnosis of TRAPS was made after sequence analysis of the tumor necrosis factor receptor superfamily 1A (TNFRSF1A) gene was performed. This revealed a heterozygous missense mutation in exon 4. This mutation, referred to as R92Q, is associated with TRAPS<sup>1</sup>.

Our patient's mother was a heterozygote carrier for the same Fabry mutation, but she did not have the R92Q mutation. His father and brother were both asymptomatic and positive for the R92Q mutation. His 8-year-old brother also had the Fabry gene mutation.

Fabry disease is a rare X-linked recessive lysosomal storage disorder caused by  $\alpha$ -galactosidase A ( $\alpha$ -Gal A) deficiency, which results in the multisystemic deposition of globotriaosylceramide within susceptible cells, tissues, and organs, leading to early death<sup>2</sup>. In classic disease the metabolic abnormality manifests usually by 10 years of age and is characterized by severe acroparesthesias, angiokeratomas, corneal opacities, and hypohidrosis. Abdominal pain is common and occurs after meals. Significant airflow obstruction and fever is also frequent in these patients<sup>2</sup>.

Table 1. Disease characteristics of Fabry disease and TRAPS.

	Fabry Disease	TRAPS
Mode of inheritance	X-linked	Autosomal dominant/incomplete penetrance
Attack duration	Chronic or episode	> 5 days
Age of symptom presentation	8–10 yrs	Median age of onset 3 yrs
Skin manifestations	Angiokeratomas	Migratory erythematous rash
Gastrointestinal manifestations	Abdominal pain after meals	Serositis
Fever	Low grade fevers	Temperature > 38°C
Renal manifestations	Endstage renal disease late in 3rd decade	Only if amyloid related renal disease develops
Cardiac manifestations	Left and right ventricular hypertrophy, and valvular and conduction abnormalities	None
Nervous system manifestations	Transient ischemic accident, cerebrovascular accident	Optic neuritis, behavioral changes
Eye involvement	Whorl shaped keratopathy	Periorbital edema and/or conjunctivitis

Atypical male variants, because of low residual  $\alpha$ -Gal A levels, have an attenuated form of the disease and present usually after age 40 years with mild proteinuria and/or cardiac manifestations of the disease<sup>3</sup>. The majority of female carriers will be asymptomatic or have mild disease manifestations such as corneal dystrophy, angiokeratomas, hypohidrosis, and infrequent attack of acroparesthesias<sup>3</sup>. Enzyme replacement therapy (ERT), which has been shown to clear globotriaosylceramide from the kidneys, heart, and skin, is now the standard of care in the treatment of symptomatic Fabry disease<sup>3,4</sup>.

The autosomal dominant disease TRAPS is characterized by episodes of fever, myalgia, arthralgia or arthritis, rash, abdominal pain, pleuritis, periorbital edema, and conjunctivitis lasting for at least 5 days. Mutations of the TNFRSF1A receptor gene on chromosome 12 have been recognized as the cause of TRAPS<sup>5</sup>. The disease mechanism is commonly attributed to impaired TNFRSF1A receptor shedding after engagement and signaling by TNF- $\alpha$ , which leads to a decreased amount of receptor available to bind soluble TNF- $\alpha$  and repress inflammation<sup>5</sup>. Receptor shedding is normal with the R92Q mutation, which suggests that defective receptor shedding does not account for the entire disease mechanism<sup>5</sup>.

Nonsteroidal antiinflammatory drugs and glucocorticoids relieve acute attacks but in most patients do not alter frequency of episodes<sup>5</sup>. Etanercept, an anti-TNF medication, decreases the frequency of attacks and improves disease activity, allowing corticosteroid reduction<sup>6</sup>.

It was interesting that there was no family history of a similar febrile illness despite family members who carried the R92Q mutation, particularly in the brother who had both the TRAPS and Fabry mutations. This R92Q mutation has been documented in 1% of Northern European subjects who were asymptomatic and is thought to have low penetrance<sup>7</sup>. The mother did have a history of acroparesthesias likely secondary to mild Fabry disease.

Our patient was prescribed a trial of colchicine to treat the TRAPS, but this was discontinued because of lack of benefit. He began treatment for Fabry disease with ERT and has gone 9 months without a recurrent febrile/pain episode, his longest symptom-free period to date.

The severity and early onset of symptoms in our patient may reflect an interaction between the 2 genetic disorders, potentially worsening the clinical phenotype. In patients with a diagnosis of TRAPS who have atypical symptoms, further investigation to evaluate for the presence of other concomitant conditions should be performed. A missed diagnosis of Fabry disease without the opportunity for treatment could have had tragic consequences for this patient.

CHRISTINE HALLIGAN, MD, Division of Rheumatology; BRYCE A. HEESE, MD, Department of Medical Genetics, Mayo Clinic, Rochester, Minnesota; GRANT MELLOR, MD, Ottumwa Pediatrics, Ottumwa, Iowa; VIRGINIA V. MICHELS, MD, Department of Medical Genetics; ANN REED, MD, Division of Rheumatology, Mayo Clinic, 200 First Street, Rochester, Minnesota 55905, USA. Address reprint requests to Dr. Reed. E-mail: reed.ann@mayo.edu

#### REFERENCES

1. Sarrauste de Menthiere C, Terriere S, Pugnere D, Ruiz M, Demaille J, Touitou I. INFEVERS: the Registry for FMF and hereditary inflammatory disorders mutations. *Nucl Acids Res* 2003;31:282-5.
2. Mehta A. New developments in the management of Anderson-Fabry disease. *QJM* 2002;95:647-53.
3. Desnick RJ, Brady R, Barranger J, et al. Fabry disease, an under-recognized multisystemic disorder: expert recommendations for diagnosis, management, and enzyme replacement therapy. *Ann Intern Med* 2003;138:338-46.
4. Eng CM, Guffon N, Wilcox WR, et al. International Collaborative Fabry Disease Study Group. Safety and efficacy of recombinant human alpha-galactosidase A — replacement therapy in Fabry's disease. *New Engl J Med* 2001;345:9-16.
5. Hull KM, Drewe E, Aksentijevich I, et al. The TNF receptor-associated periodic syndrome (TRAPS): emerging concepts of an autoinflammatory disorder. *Medicine* 2002;81:349-68.
6. Drewe E, McDermott EM, Powell PT, Isaacs JD, Powell RJ. Prospective study of anti-tumour necrosis factor receptor superfamily 1B fusion protein, and case study of anti-tumour necrosis factor receptor superfamily 1A fusion protein, in tumour necrosis factor receptor associated periodic syndrome (TRAPS): clinical and laboratory findings in a series of seven patients. *Rheumatology Oxford* 2003;42:235-9.
7. Aksentijevich I, Galon J, Soares M, et al. The tumor-necrosis-factor receptor-associated periodic syndrome: new mutations in TNFRSF1A, ancestral origins, genotype-phenotype studies, and evidence for further genetic heterogeneity of periodic fevers. *Am J Hum Genet* 2001;69:301-14.