Accuracy and Dispersal of Subacromial and Glenohumeral Injections in Cadavers

NIGEL HANCHARD, DONAL SHANAHAN, TRACEY HOWE, JONATHAN THOMPSON, and LORNA GOODCHILD

ABSTRACT. ***Objective.*** "Blind" shoulder injections are often inaccurate and infiltrate untargeted structures. We tested a hypothesis that optimizing certain anatomical and positional factors would improve accuracy and reduce dispersal.

Methods. We evaluated one subacromial and one glenohumeral injection technique on cadavers.

Results. Mean accuracy was 91% for subacromial-targeted and 74 and 91% (worst- and best-case scenarios) for joint-targeted injections. Mean dispersal was 19% for subacromial-targeted and 16% for joint-targeted injections. All results bettered those reported previously.

Conclusion. These "optimized" techniques might improve accuracy and limit dispersal of blind shoulder injections in clinical situations, benefiting efficacy and safety. However, evaluation is required in a clinical setting. (J Rheumatol 2006;33:1143–6)

Key Indexing Terms:
SHOULDER PAIN ANTIINFLAMMATORY AGENTS INJECTIONS CADAVER

Subacromial and glenohumeral steroid injections are common interventions for shoulder pain, but evidence for their efficacy is inconclusive[1]. This may reflect variable injection accuracy across clinical trials[1], many of which, in keeping with typical clinical practice, employed "blind" techniques. The "hit" rates of clinical studies for blind subacromial bursal/space injections have been reported as 87% for an anterolateral approach[2]; 70% for a posterolateral approach[3]; 67% when performed by an orthopedic consultant or specialist physiotherapist versus 48% when by a registrar, each using an anterior approach[4]; and 65% and 29%, respectively, for a lateral approach[5,6]. Hit rates of 83% were reported for an anterolateral approach to the subacromial bursa/space in cadavers[7]. Clinical evaluations of glenohumeral injection accuracy reported hit rates of only 11% and 42%[6,7]. Some small studies with confirmed injection placement have now correlated accuracy and treatment efficacy[2,3,5-7], signalling that accuracy should be a key consideration for researchers and clinicians alike. Moreover, although evidence for lasting steroid-induced soft tissue damage is circumstantial in humans, a number of controlled animal studies have found intratendinous injections harmful[9]; and in rats, repeated peritendinous (subacromial) triamcinolone injections at human equivalent dosages induced structural changes in even normal rotator cuffs[10]. Thus a further consideration is that of "dispersal": up to 93% of successful hits on the subacromial bursa are accompanied by coincidental hits on untargeted structures[4]. To test the hypothesis that optimizing certain anatomical and positional factors would improve upon previously reported levels of subacromial and glenohumeral injection accuracy, we evaluated 2 injection techniques (one subacromial, one glenohumeral) on cadavers.

From the Teesside Centre for Rehabilitation Sciences, University of Teesside, Middlesbrough; Department of Anatomy and Clinical Skills, School of Medical Education Development, University of Newcastle, Newcastle-upon-Tyne; Glasgow Caledonian University, Glasgow; Physiotherapy Department, York District Hospital, York; and Physiotherapy Department, The James Cook University Hospital, Middlesbrough, UK.

Nigel Hanchard gratefully acknowledges the UK Department of Health for the fellowship award that funded this study.

N.C.A. Hanchard, MSc, Department of Health Research Fellow, Teesside Centre for Rehabilitation Sciences, University of Teesside; D. Shanahan, PhD, Prosector, Department of Anatomy and Clinical Skills, School of Medical Education Development, University of Newcastle; T.E. Howe, PhD, Director, HealthQWest, Glasgow Caledonian University; J. Thompson, BSc (Hons), Extended Scope Practitioner of Physiotherapy, Physiotherapy Department, York District Hospital; L. Goodchild, BSc (Hons), Extended Scope Practitioner of Physiotherapy, Physiotherapy Department, The James Cook University Hospital.

Address reprint requests to N. Hanchard, Teesside Centre for Rehabilitation Sciences (University of Teesside), The James Cook University Hospital, Marton Road, Middlesbrough, TS4 3BW, UK. E-mail: n.hanchard@tees.ac.uk

Accepted for publication February 27, 2006.

MATERIALS AND METHODS

Injection techniques. Each cadaver was prone, shoulder adducted and slightly flexed, elbow flexed to 90°, and forearm folded across the abdomen.

Subacromial space. A 5 cm 21-gauge needle was inserted 1 cm inferior and 1 cm lateral to the acromial angle, and aimed 1 cm lateral to the mid-acromioclavicular joint-line superiorly (Figure 1). On contacting hard tissue at a depth compatible with that of the target (the underside of the anterior acromion), a 1 ml bolus of acrylic dye, color coded according to the injector and the targeted structure, and pretested for contrast, was administered.

Shoulder joint. A 5 cm 21-gauge needle inserted 1 cm inferior and 1 cm medial to the acromial angle was directed towards the middle of the coracoid's inferior edge (Figure 2). If not halted by contact with firm/hard tissue at a depth compatible with that of the target (the humeral head), the needle was partially withdrawn and redirected more laterally until this was achieved, whereupon a bolus was injected as described above.

If resistance to injection was met with either technique, the needle was rotated 180° on its long axis (to free the bevel) and withdrawn minimally if resistance persisted.

Injectors. Two specialist physiotherapists, accredited in musculoskeletal injection therapy and with 8 years' and 18 months' injection experience, respectively, performed the injections. Both were accustomed to injecting the

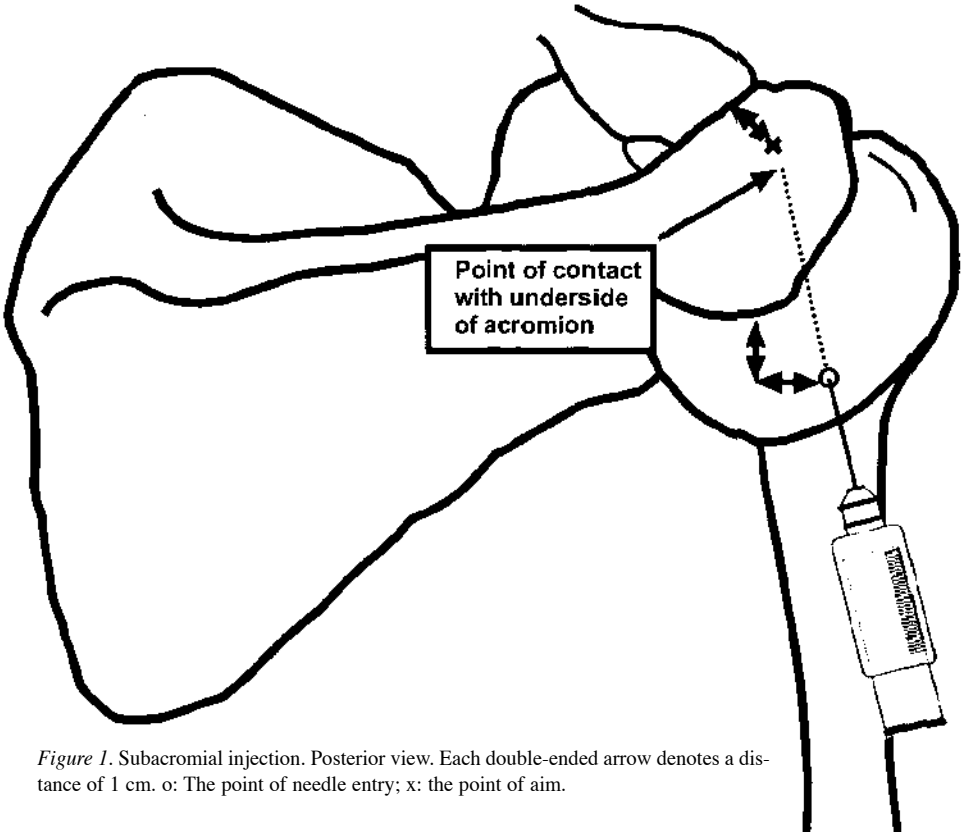

Figure 1. Subacromial injection. Posterior view. Each double-ended arrow denotes a distance of 1 cm. o: The point of needle entry; x: the point of aim.

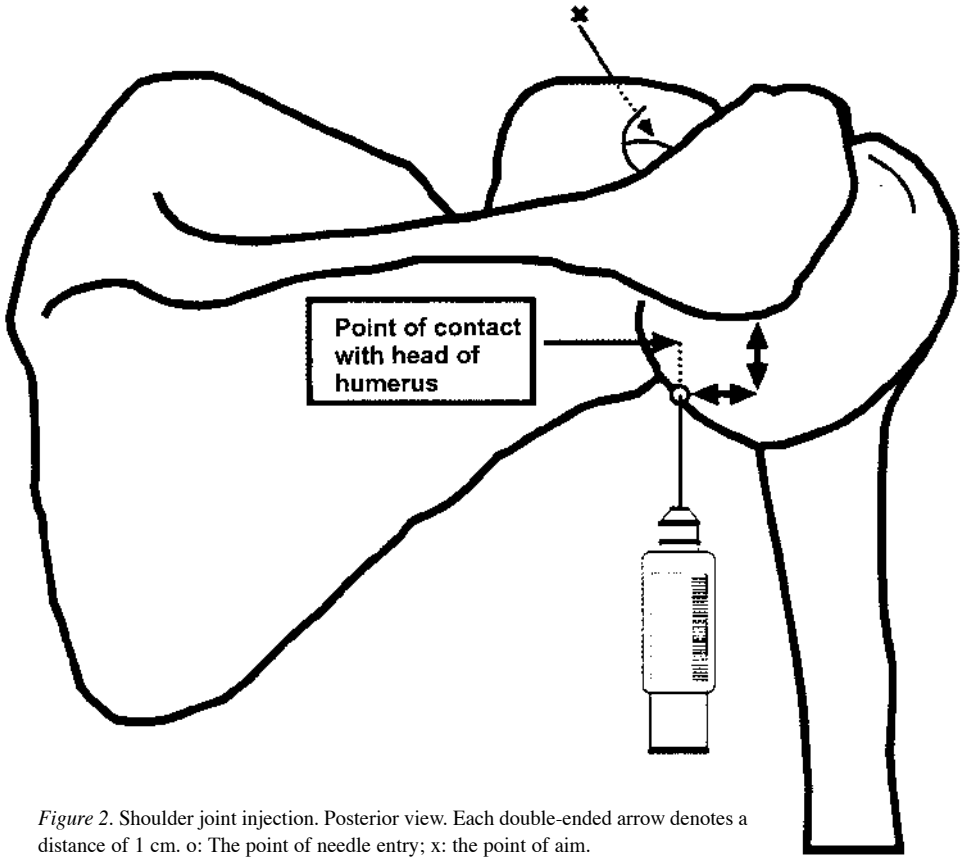

Figure 2. Shoulder joint injection. Posterior view. Each double-ended arrow denotes a distance of 1 cm. o: The point of needle entry; x: the point of aim.

glenohumeral joint by a posterior approach similar to that evaluated, but neither routinely used a posterolateral approach for subacromial injections. Following explanation of the techniques, a practice session on 2 cadaveric specimens was conducted prior to the study.

Cadavers. Eleven embalmed cadavers (5 male) were available for injection. Their mean age was 78 years (range 65–89, standard deviation 7.6) at death, which was from natural causes in every case. Their builds were "slim" (n = 5), "average" (n = 2), "slightly obese" (n = 2), "obese" (n = 1), and "very obese" (n = 1).

Dye inspection procedure. Embalmed skin resembles hard soap in consistency, and needed to be cut and peeled back (reflected) from over pectoralis major, deltoid, and the upper arm to enable palpation of bony landmarks. For each target, the injector marked the points of needle insertion and aim using mapping pins and gave the injection. The pins, which, like the injection needle itself, left no puncture mark on the cadaveric tissue, were then removed, blinding the second injector to the determinations of the first. Following the injections, a prosector (DS) incised the deltoid muscle vertically 2.5 cm posterior to the deltopectoral groove, reflected the muscle, then looked for dye positioned subacromially (the bursal walls were indistinct in most specimens, preventing more precise localization) as well as within the deltoid itself. The rotator cuff tendons were inspected and divided, allowing access to the joint, where dye was sought. The other musculotendinous structures around the shoulder joint were also probed and inspected for dye, along with their surrounding and intervening fascial planes; and the acromioclavicular joint was inspected through an anterosuperior incision. The prosector noted the colors and locations of any dyes found.

RESULTS

There were 2 protocol violations. In both instances the errors were identified, and the data excluded, prior to dissection. Forty-three injections were available for analysis for each target structure.

Following 5 of the joint-targeted injections, dye was identified solely within the fibrous tissue of the capsule. Alternative analyses are presented, respectively counting these as misses and hits (worst- and best-case scenarios).

The subacromial injections were consistently accurate, with 19 out of 21, and 20 out of 22 hits (91%) for the 2 injectors. However, the first injector had more coincidental hits on untargeted structures (5/21, 24%, vs 3/22, 14%). The mean value for coincidental hits during subacromial injections was 19%. The hit rates for the glenohumeral joint were 14/22 (64%) and 18/21 (86%) for the worst-case scenarios (mean 74%), and 19/22 (86%) and 20/21 (95%) for the best-case scenarios (mean 91%). Again, the first injector had a higher rate of coincidental hits on untargeted structures (6/22, 27%, vs 1/21, 5%). The mean value for coincidental hits during joint injections was 16%. The various untargeted structures that were coincidentally hit are itemized in Table 1.

DISCUSSION

The high hit rate for subacromial injections compares favorably with rates reported for other techniques[2-7]. Also, the rate of unintended hits during subacromially-targeted injections was substantially lower than the 63% (for the subacromial space) and 79–93% (for the subacromial bursa) reported elsewhere[3-5,7]. For joint-targeted injections, even taking the worst-case scenario, the hit rate was substantially higher than the 11% and 42% reported[6,8], while the unintended hit rate was much lower (versus ≥ 89% and ≥ 58%)[6,8].

The occasional finding of dye within the fibrous tissue of the joint capsule was unexpected and would be unlikely *in vivo*. In living subjects, even those with capsular disorders, the shoulder position used would not approach the limit of internal rotation. The posterior capsule would therefore be lax, allowing interposition of injected material between itself and the humeral head. In our sample, however, due to post mortem changes, this position was frequently at end range, and the posterior capsule, drawn tight over the humeral head, prevented such interposition. Replicating these conditions in fresh turkey shoulder joints, we have observed that injections into lax aspects of the capsule penetrate intraarticularly, whereas those into aspects stretched over articular cartilage exude extraarticularly: in embalmed human cadavers, delamination of the relatively desiccated, paper-like capsule is possible instead. Considering these points, infiltrating embalmed

Table 1. Unintended fates of dyes associated with injections targeting the subacromial bursa/space and glenohumeral joint.

Intended Target	Unintended Fate of Dye	No. of Cases
Subacromial bursa/space, 43 injections	Deep to infraspinatus fascia	2
	Superficial to joint capsule	1
	Tracking along supraspinatus fascia	1
	In shoulder joint capsule	2
	Deltoid muscle	1
	Acromioclavicular joint	1
Total		8
Glenohumeral joint, 43 injections	Subacromial via full-thickness cuff tear	1
	Subacromial (minor flecking only)	1
	Inferior to spine of scapula	1
	Infraspinatus muscle	1
	Deep to infraspinatus fascia	1
	Dye not found	1
Total		6

capsular tissue would probably correspond to intraarticular placement in the living subject.

A potential weakness of our study was the need to reflect the dense overlying embalmed skin and subcutaneous tissues to enable palpation. However, this was not thought to compromise the cadaveric model's validity, because the landmarks remained obscured by a layer of subdermal fat, and the injectors gained little, if any, visual advantage.

In keeping with our hypothesis, several factors may account for the apparent efficacy of the techniques evaluated relative to those previously described. The bony landmarks are readily identifiable, the needle paths accessible, and end-feel is utilized to aid orientation (direction and depth) to the joint cavity or the vault of the subacromial bursa. (Positioning a patient in sitting position might increase subacromial accessibility still further by means of gravitational traction on the arm.) For glenohumeral injections, the adducted and medially rotated shoulder position offers the largest possible area of the head of humerus as a target, and is comfortable for patients with capsular disorders. Additional advantages of the prone lying position would be fixation of the patient's forearm under the trunk, and consequent stabilization of the shoulder, and a reduced risk of syncope relative to the sitting position.

These optimized techniques — which seem promising in cadavers — may potentially improve the accuracy and limit the dispersal of blind shoulder injections in clinical situations, with possible benefits for efficacy and safety. Clinical evaluation is required to further test this hypothesis.

ACKNOWLEDGMENT

The authors thank Dr. Helen Handoll for her helpful comments on the manuscript, and Mr. Colin Cooling, MA, for providing the line drawings.

REFERENCES

1. Buchbinder R, Green S, Youd JM. Corticosteroid injections for shoulder pain. Cochrane Database Syst Rev: CD004016 2003.
2. Esenyel CZ, Esenyel M, Yesiltepe R, et al. The correlation between the accuracy of steroid injections and subsequent shoulder pain and function in subacromial impingement syndrome. Acta Orthop Traumatol Turc 2003;37:41-5.
3. Yamakado K. The targeting accuracy of subacromial injection to the shoulder: an arthrographic evaluation. Arthroscopy 2002;18:887-91.
4. Chambers I, Hide G, Bayliss N, Feary J. An audit of accuracy and efficacy of injections for subacromial impingement comparing consultant, registrar and physiotherapist. J Bone Joint Surg Br, Orthopaedic Proceedings 2005;87 Suppl 2:160 [abstract].
5. Naredo E, Cabero F, Beneyto P, et al. A randomized comparative study of short term response to blind injection versus sonographic-guided injection of local corticosteroids in patients with painful shoulder. J Rheumatol 2004;31:308-14.
6. Eustace JA, Brophy DP, Gibney RP, Bresnihan B, Fitzgerald O. Comparison of the accuracy of steroid placement with clinical outcome in patients with shoulder symptoms. Ann Rheum Dis 1997;56:59-63.
7. Partington PF, Broome GH. Diagnostic injection around the shoulder: hit and miss? A cadaveric study of injection accuracy. J Shoulder Elbow Surg 1998;7:147-50.
8. Jones A, Regan M, Ledingham J, Patrick M, Manhire A, Doherty M. Importance of placement of intra-articular steroid injections. BMJ 1993;307:1329-30.
9. Paavola M, Kannus P, Jarvinen TA, Jarvinen TL, Jozsa L, Jarvinen M. Treatment of tendon disorders: Is there a role for corticosteroid injection? Foot Ankle Clin 2002;7:501-13.
10. Tillander B, Franzen LE, Karlesson MH, Norlin R. Effect of steroid injection on the rotator cuff: An experimental study in rats. J Shoulder Elbow Surg 1999;8:271-4.