Magnetic Resonance Imaging Is More Sensitive Than Radiographs in Detecting Change in Size of Erosions in Rheumatoid Arthritis

TIMOTHY S. CHEN, JOHN V. CRUES III, MUHAMMAD ALI, and ORRIN M. TROUM

ABSTRACT: ***Objective.*** To evaluate the technological performance of magnetic resonance imaging (MRI) with respect to projection radiography by determining the incidence of changes in the size of individual bone lesions in inflammatory arthritis, using serial high-resolution in-office MRI over short time intervals (8 months average followup), and by comparing the sensitivity of 3-view projection radiography with in-office MRI for detecting changes in size and number of individual erosions.

Methods. MR examinations of the wrists and second and third metacarpophalangeal joints were performed using a portable in-office MR system in a total of 405 patients with inflammatory arthritis, from one rheumatologist's practice, who were undergoing aggressive disease modifying antirheumatic drug therapy. Of the patients, 156 were imaged at least twice, allowing evaluation of 246 followup examinations (mean followup interval of 8 months over a 2-year period). Baseline and followup plain radiographs were obtained in 165 patient intervals. Patients refused radiographic examination on 81 followup visits.

Results. MRI demonstrated no detectable changes in 124 of the 246 (50%) followup MRI examinations. An increase in the size or number of erosions was demonstrated in 74 (30%) examinations, a decrease in the size or number of erosions in 36 (15%), and both increases and decreases in erosions were seen in 11 (4%). In the 165 studies with followup radiographic comparisons, only one examination (0.8%) showed an erosion not seen on the prior examination and one (0.8%) showed an increase in a previously noted erosion.

Conclusion. We showed that high-resolution in-office MRI with an average followup of 8 months detects changes in bony disease in 50% of compliant patients during aggressive treatment for inflammatory arthritis in a single rheumatologist's office practice. Plain radiography is insensitive for detecting changes in bone erosions for this patient population in this time frame. (First Release Aug 1 2006; J Rheumatol 2006;33:1957–67)

Key Indexing Terms:
RHEUMATOID ARTHRITIS EROSIONS IN-OFFICE MAGNETIC RESONANCE IMAGING
DISEASE MODIFYING ANTIRHEUMATIC DRUGS MAGNETIC RESONANCE IMAGING

Rheumatoid arthritis (RA) is a chronic inflammatory arthropathy of unknown etiology that has a worldwide distribution and affects all age groups, although the prevalence increases with age, and the peak incidence in women is between the fourth and sixth decades. The disease affects between 0.3% and 1.5% of the North American population and has a 2.5:1 female-to-male ratio[1]. RA has many visceral manifestations, but it primarily involves the synovium and articular structures of joints where the disease is characterized by synovitis, leading to bone erosions, articular cartilage loss, damage to supporting structures (tendons, ligaments), and potential ankylosis[1,2]. Because work disability is closely associated with radiographic measures of bone destruction[3,4], and its natural course is chronic and unremitting with few patients achieving longterm remission prior to joint destruction, aggressive therapy has been advocated in early disease to prevent joint destruction and accompanying morbidity[5-10]. The success of disease modifying antirheumatic drugs (DMARD) and more recently biologic response-modifying drugs in arresting and even reversing the bone destruction process, and the high costs of the tumor necrosis factor-alpha inhibitors (TNF-α), have stimulated increased interest in methods for evaluating erosions as objective criteria for instituting more aggressive treatment regimens and monitoring their efficacy.

From Radnet Management, Los Angeles; and Orrin M. Troum, MD and Medical Associates, Santa Monica, California, USA.

Drs. Crues and Troum own stock (less than 1% of outstanding shares) in MagneVu Inc. These shares have no monetary value at present.

Supported in part by a grant from the Centocor Division of Johnson & Johnson and from Radnet Management, a subsidiary of Primedex Health Systems.

T.S. Chen, MD, Radnet Management; J.V. Crues, MD, Radnet Management and Volunteer Clinical Professor, University of California, San Diego, School of Medicine; M. Ali, MD, Radnet Management; O.M. Troum, MD, Orrin M. Troum, MD and Medical Associates and Clinical Professor, Keck School of Medicine.

Address reprint requests to Dr. J. Crues, Radnet Management, 1516 Cotner Ave., Los Angeles, California 90025, USA.
E-mail: crues@radnetonline.com

Accepted for publication April 7, 2006.

Personal non-commercial use only. The Journal of Rheumatology Copyright © 2006. All rights reserved.

Downloaded on April 19, 2024 from www.jrheum.org

Clinical and biochemical criteria are important in evaluating patients for diagnosis and disease activity, but bone destruction can progress, even in apparent clinical remission[11]. Imaging, therefore, is a promising adjunct to the evaluation of patients with RA[12].

Traditionally, conventional radiography has been the gold standard in imaging of RA. Scoring systems such as the Larsen and Sharp systems have been developed and modified in an attempt to standardize evaluation[13-15]. Ultrasound has been shown to be sensitive in detecting synovial thickening, synovial vascularity, and bone erosions in experienced hands[16-18]. Multiple studies have measured increased sensitivity of magnetic resonance imaging (MRI) for detecting bone changes characteristic of erosions compared with projection radiography[19-24]. Lesions detected by MRI may progress to typical radiographic erosions over 2–6 years[25-27]. Changes in the MR appearance of erosions in patients with established RA are less well described[28-31]. Our study was designed to compare the sensitivity of MR versus conventional radiography in detecting changes in sizes of erosions over a relatively short timeframe, as detection of changes may be of value in guiding recently advanced pharmacotherapy.

MATERIALS AND METHODS

Study subjects. Data were based on a total of 405 consecutively seen patients from one rheumatologist's practice, with a diagnosis of either rheumatoid or psoriatic arthritis (PsA) and no contraindications to MRI, who agreed to be evaluated by MRI. All patients with active disease were aggressively treated with DMARD therapy for inflammatory arthritis over a period of 24 months. Of the patients, 95% met the American College of Rheumatology (ACR) criteria for RA. Five percent satisfied ACR criteria for PsA. Comparisons between the sensitivity of plain radiograph versus MRI findings in detecting periarticular bony lesions in a subgroup of these patients were previously published[19]. That article did not analyze interval changes in erosions. This article documents the incidence of changes in the size and number of bone lesions involving the second and third metacarpophalangeal (MCP) joints and wrists in patients over time intervals ranging from one month to 2 years, as evaluated with in-office MRI versus radiographs. A single rheumatologist (OT) provided clinical management of all study subjects.

MR examination. One hundred fifty-six patients returned for followup examinations, of whom one had 4 followup examinations, 23 had 3 followup examinations, 41 had 2 followup examinations, and 91 had one followup examination. The mean followup interval was 8 months. Followup examinations were compared to the most recent prior examination of the same patient. Each prior examination/followup comparison pair was evaluated independently of any earlier examinations. Two hundred forty-nine patients either did not return for followup or their initial MRI was performed less than 6 months before termination of data acquisition.

MRI examinations were performed using a portable in-office high-resolution scanner (previously distributed in the United States as Applause, GE Medical Systems; manufactured by MagneVu, Carlsbad, California; Figure 1)[19,31,32]. This portable scanner has a 0.2 Tesla inhomogenous magnetic field and is unique in that it requires no special radio frequency or magnetic shielding, can be plugged into an ordinary 110 V AC wall adapter, and, despite weighing 175 lbs, is mounted on wheels, making it portable. It occupies about 4 m^2 of floor space. These characteristics make it amenable to in-office placement, and its small size and open configuration enhance patient comfort during the scan.

MR examination of the second and third MCP joints and wrists included 2 sequences in each of the 2 locations: T1 spin echo (3D acquisition, TR/TE, 100/27 ms; flip angle 90˚, field of view 50 × 75 × 10 mm; 2 excitations, 1.0 × 1.0 × 1.0 mm isotropic resolution) in the initial one-third of studies and (0.6 mm section thickness and 1.0 mm coronal in-plane resolution, acquisition time 15 min) in the latter two-thirds of studies, and STIR (3D acquisition, TR/TE/TI, 100/24/50 ms; field of view 50 × 75 × 10 mm, 4 excitations, 1.0 mm section thickness, 1.4 mm coronal in-plane resolution) in the initial one-third of studies and (0.6 mm section thickness, 1.4 mm coronal in-plane resolution, acquisition time 13 min) in the latter two-thirds of studies. Other joints were occasionally imaged based on the patient's clinical symptoms, including the proximal interphalangeal joints and the metatarsophalangeal joints. Although image acquisition was a 3-dimensional technique with isotropic or near isotropic resolution, most interpretations were obtained by displaying the data in the coronal plane.

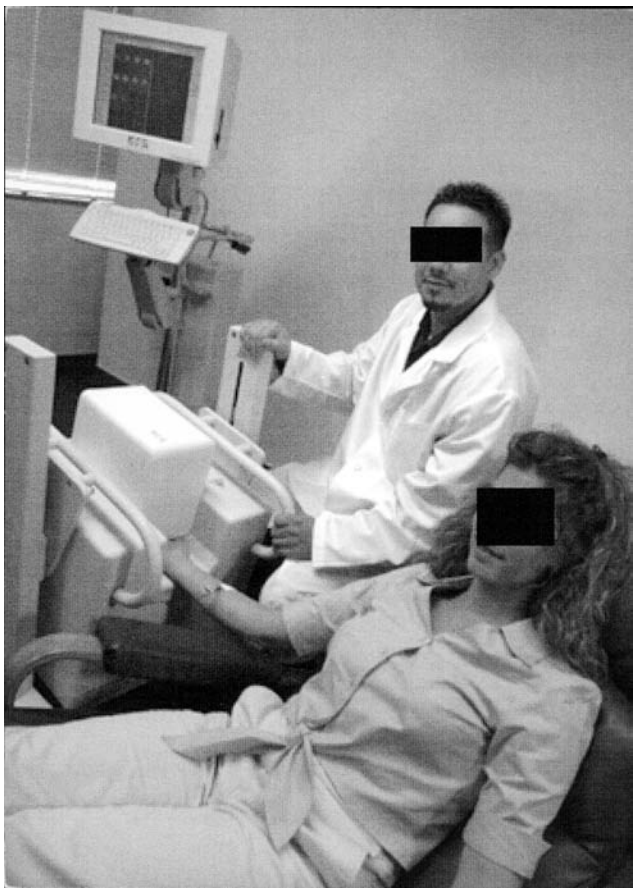

Figure 1. The Applause in-office MR scanner. The small size and portability of the Applause in-office scanner is apparent in this image of a volunteer with her hand placed within the scanner in a position to scan the second and third MCP joints.

Radiographic examinations. Baseline standard posteroanterior, lateral, and oblique radiographs of the hands and wrist were obtained in a total of 368 patients. The 3 standard radiographic views were used in this study instead of a single posteroanterior projection, because 3 projections increase the sensitivity for detecting bone lesions and evaluating their sizes and morphologies. One hundred twenty-three patients had a total of 165 followup radiographic examinations. Of these, 224 (78%) were performed on the same day as the MR, and another 21 (7%) examinations were performed within 30 days of the MR. The remaining 41 (14%) examinations were beyond the ± 30 day timeframe of the MR examination and were therefore considered invalid for comparison. The projection radiographs were evaluated for the presence of bone erosions before evaluating the MR images and again after interpreting the MR images. On the second viewing of the plain radiographs, the regions associat-

Personal non-commercial use only. The Journal of Rheumatology Copyright © 2006. All rights reserved.

Downloaded on April 19, 2024 from www.jrheum.org

ed with changes in erosions on the MRI studies were reevaluated, and, in order to minimize false-negative radiographic interpretations, the results of the second radiographic interpretations are the results we report. Although the use of the second radiographic interpretation increased the sensitivity for detecting bone erosions in our previous experience[19], there were no discrepancies between the first and second radiographic interpretations for erosion changes in the data for this article. The number of followup radiographs is less than the number of MRI due to patients refusing followup radiographs. The most common reason for patient refusal was concern over radiation exposure. The mean followup interval was the same as the MR followup interval (8 months).

Interpretation. Radiographic and MR images were interpreted by a single board-certified radiologist with more than 18 years of musculoskeletal MR reading experience (JC). MR examinations were transferred from the portable scanner in the rheumatologist's office to the radiologist via a virtual private network on the Internet and were read on soft-copy workstations. All the MR examinations were interpreted prospectively, one time, with the reader aware of the age, sex, and presumptive diagnosis. Conventional radiographs were read as hard-copy films on a standard view box.

On the MR images, the presence of erosions, soft tissue thickening (indicating synovitis), and joint space narrowing were assessed. Erosions were defined as focal areas of marrow signal loss on the T1-weighted images with increased signal intensity on the STIR images in the periarticular regions that extend to the cortical surface. Cortically-based signal changes less than 2 mm in maximum diameter were reported as "cortical irregularity" and not scored as erosions. Lesions were not scored as erosions unless their maximum diameter was 2 mm or greater. Erosion size was documented as a single measurement in the maximum dimension of the erosion as measured on the coronal image extending through the center of the lesion. Typical erosion sizes ranged from 2 mm to 10 mm, although larger erosions were occasionally noted. Changes in erosions were judged to be significant if their measurement varied by 20% or more. This number is a compromise between sensitivity and specificity for lesion growth. This was based upon the image acquisition spatial resolution being at least 1 millimeter in all 3 planes, although most of the followup studies were obtained with $1.0 \times 1.0 \times 0.6$ millimeter spatial resolution. As most lesions were roughly spherical or half-spherical and measured between 3 and 6 mm, many images were obtained through each lesion, minimizing the error due to partial volume artifacts.

RESULTS

MR imaging. Figure 2 shows a summary of the MR data acquired. No detectable changes were seen in 124 of the 246 (50%) followup MRI examinations. One examination typically included 2 sequences obtained at 4 locations (right and left second and third MCP and right and left wrists). One or more erosions increased in size without any erosions decreasing in size in 74 (30%) study intervals (Figure 3). One or more erosions decreased in size without any erosions increasing in 36 (15%) intervals (Figure 4), and both increases and decreases in erosions were seen in 11 (4%) intervals (Figure 5). Motion artifact obscured images in one (< 1%) study.

When 632 individual locations with erosions were followed, no changes occurred in 481 (76%), increases were seen in 87 (14%), decreases present in 52 (8%), both increases and decreases in 3 (< 1%), and motion artifact obscured 9 (1%). In 178 locations initially without erosions, 150 (84%) showed no changes and 26 (15%) showed new erosions on followup.

Evaluating individual locations of the MR followup exam-

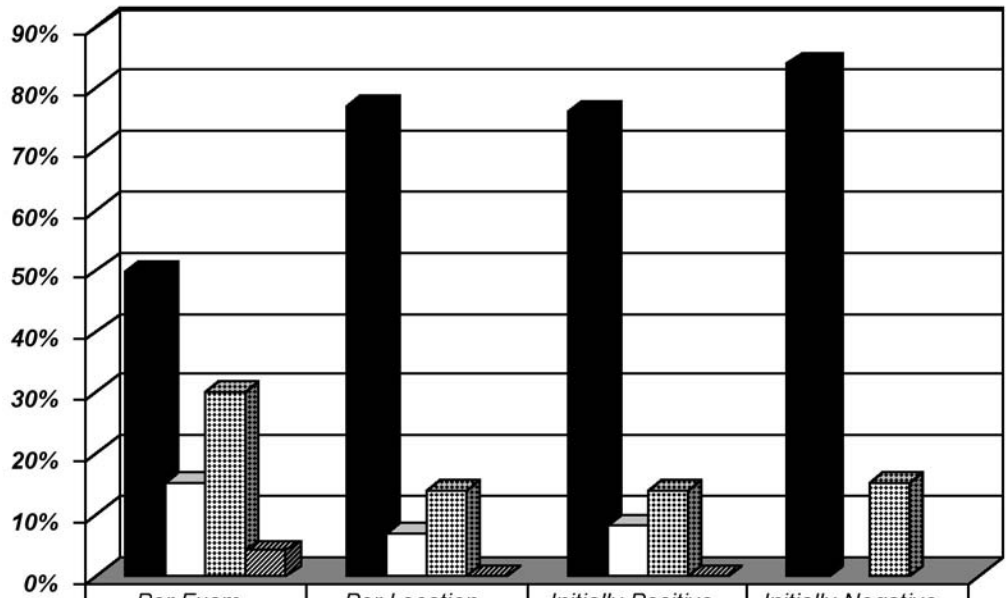

	Per Exam	Per Location	Initially Positive	Initially Negative
■ No Change	50%	77%	0.76	0.84
□ Decrease	15%	0.07	0.08	
⊞ Increase	30%	0.14	0.14	0.15
▨ Both	4%	0	0	

Figure 2. Detection of changes in erosions in the second and third MCP joints and the wrist on MRI in 4 categories: Overall change per patient examination, change based on individual scan locations, change in locations that were initially positive for erosions, and change in locations that were initially negative for erosions.

Personal non-commercial use only. The Journal of Rheumatology Copyright © 2006. All rights reserved.

Downloaded on April 19, 2024 from www.jrheum.org

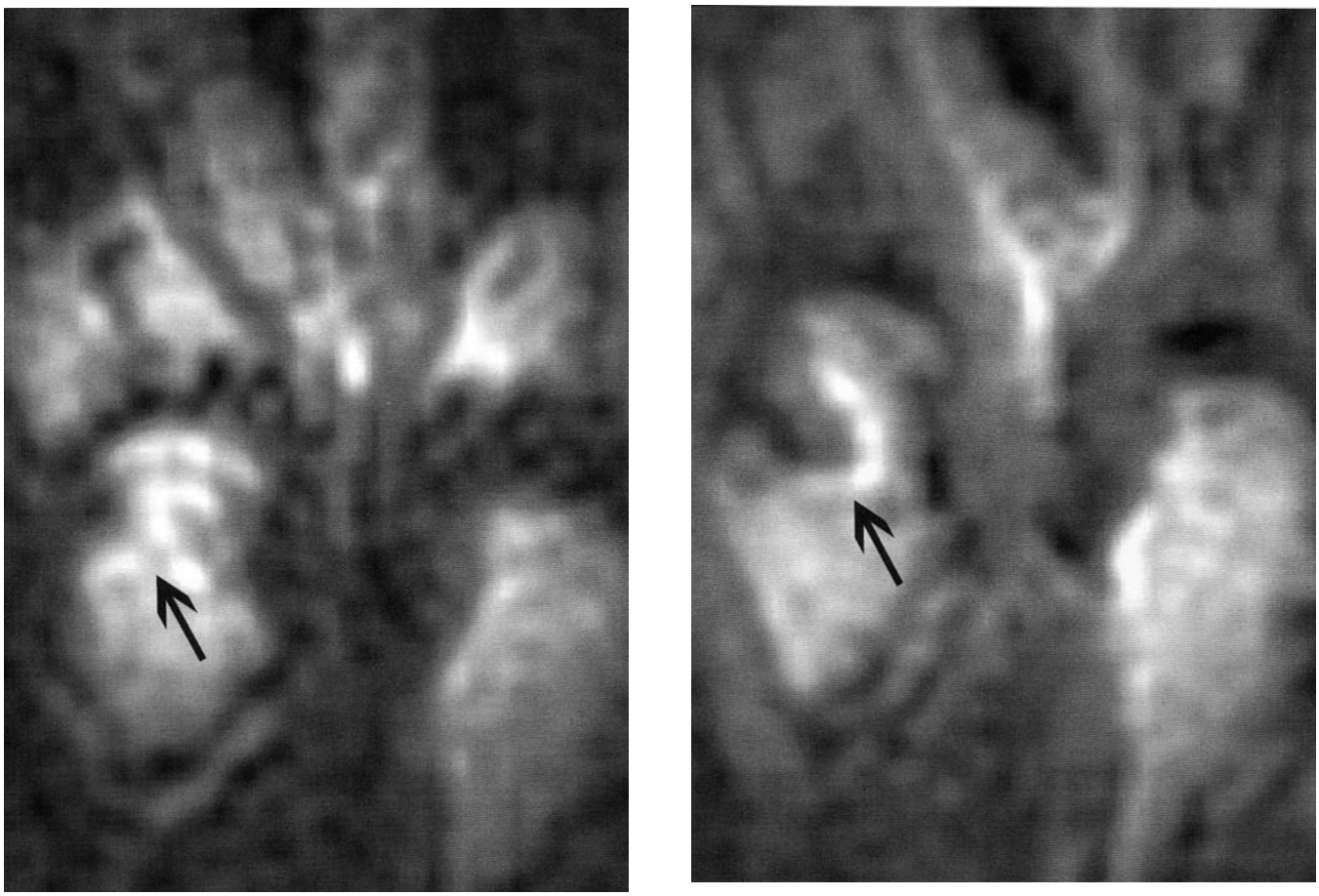

A B

Figure 3. MRI of the right second and third MCP joints showing an increase in the size of an erosion in a patient treated with MTX only. A. This single tomographic slice through a coronal data set shows a small marginal erosion on the ulnar aspect of the third MCP head (arrow) on February 16, 2004. B. On the followup MR scan performed on August 19, 2004, the erosion has increased in size (arrow).

inations demonstrated that the right MCP location showed the most frequent changes with 60 out of 211 examinations (28%), the left MCP changed in 36 out of 191 examinations (19%), the right wrist changed in 43 out of 212 (20%), and the left wrist changed in 33 out of 195 examinations (17%). Not all of the 246 examinations had data evaluating all 4 body locations. Comparing the MCP location to the wrist location for each side demonstrated that of 422 comparison pairs, 235 showed no changes at either location. Of the remaining 130 examination pairs that showed changes, 17 (13%) showed concordant changes (i.e., both improved or both worsened), and 113 (87%) showed discordant changes (i.e., one improved and the other worsened or stayed the same). Comparing the left MCP to the right MCP and the left wrist to the right wrist, there were a total of 330 examination pairs, 209 (63%) of which showed no changes on either side. Of the remaining 121 examination pairs, 28 (23%) showed concordant changes and 93 (77%) showed discordant changes. The comparison data of the MCP versus wrist and left versus right observations both show that the changes in bone erosions in this short timeframe do not occur symmetrically at all 4 locations. The observed frequency of discordant changes was statistically significant ($p < 0.001$).

In the 165 patient intervals with followup radiographic comparisons, only one examination clearly showed an erosion not seen on the prior examination (Figure 6), and one examination showed an increase in a previously noted erosion.

DISCUSSION

The increased sensitivity of MRI versus projection radiography in detecting focal bone abnormalities in RA is well established[12,19-22,24,31,33,34]. Consequently, MRI is becoming a valuable tool in staging the extent of erosive disease at the time of diagnosis of inflammatory arthropathy. The sensitivity of MRI in detecting changes in bone injury over time is less well established[28,29,35]. We attempted to determine how frequently and in what timeframe progression and regression of bone injury could be detected by high-resolution MRI in patients treated with DMARD therapy in a clinical rheumatologist's practice. With an average followup of 8 months,

Personal non-commercial use only. The Journal of Rheumatology Copyright © 2006. All rights reserved.

Downloaded on April 19, 2024 from www.jrheum.org

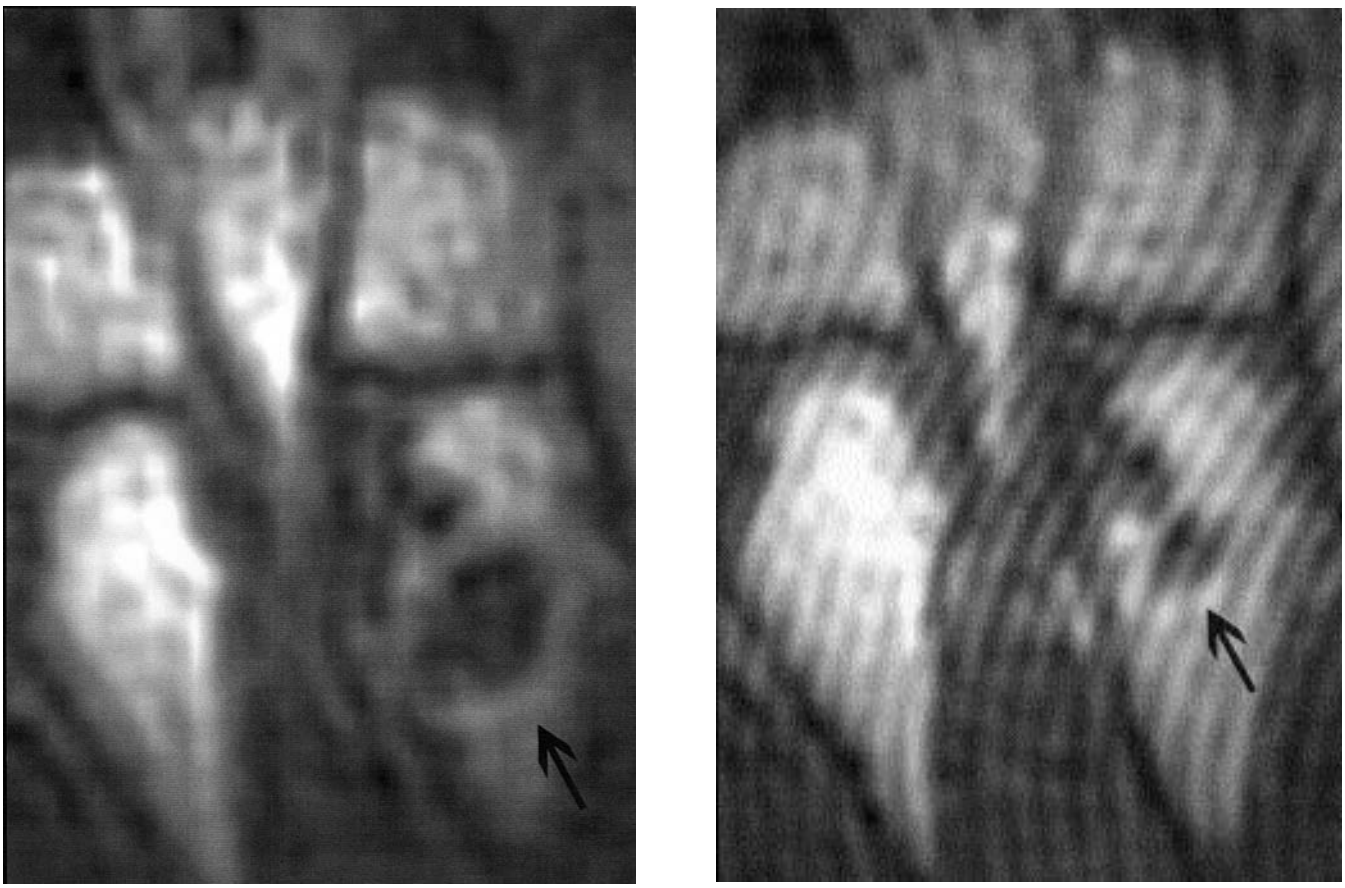

A B

Figure 4. Decrease in erosion size. A. A large erosion is seen involving the radial aspect of the left third MC head (arrow) on February 9, 2004. The patient was started on a TNF-α inhibitor. B. After 9 months on the TNF-α inhibitor the erosion is significantly smaller (arrow) on November 3, 2004.

50% of patients undergoing aggressive DMARD therapy showed changes in MR findings versus only 1% using projection radiography. In-office, high-resolution MRI is significantly more sensitive in detecting changes in erosions in patients undergoing treatment for RA than projection radiography, supporting MRI as an effective tool for following bone injury in patients with RA treated with DMARD.

When the incidence of bone changes in individual locations was evaluated, the right MCP location was positive more often than any other location at 28% of intervals. Further, comparisons between right-sided versus left-sided changes and MCP versus wrists showed discordant/asymmetric changes. This suggests that imaging a single location will not provide optimal sensitivity for following patients' response to therapy. However, we were unable to correlate MR changes with patient handedness, with physical examination for inflammation, or with patient symptoms. It is possible that further studies correlating changes in individual locations over time with these parameters might allow more targeted imaging to be performed in following patients, thus increasing the cost-efficacy of MRI.

Other methods of evaluating for bone erosions have been proposed, including ultrasound and computerized tomography (CT)[12,36]. Ultrasound is useful for detection of erosions and can demonstrate pannus formation. But ultrasound is operator dependent, its sensitivity is no better than MRI, and it is insensitive for detection of bone marrow edema or early inflammatory cell infiltration of marrow (osteitis)[37,38]. CT is excellent for demonstrating erosions but is less accurate in evaluating periarticular soft tissues. CT is insensitive for bone marrow edema and early osteitis, and it exposes the patient to ionizing radiation[36]. High-resolution, multi-detector CT also suffers from lack of portability, an advantage of both ultrasound and the in-office MRI. Doppler US and contrast-enhanced MRI can also evaluate disease activity, a function for which contrast-enhanced CT may be less well-suited due to poorer contrast resolution[39-41]. For these reasons, MRI is the most promising modality for evaluating bony erosive disease[12,22,31,33].

A "window of opportunity" hypothesis has been proposed suggesting that early DMARD treatment may be critical in stabilizing or reversing disease progression[8]. This hypothesis states that patients treated early in their disease course with disease modifying therapy will fare better than those with delayed treatment. This is in part due to evidence that irreversible bone destruction occurs early in the course of RA in

Personal non-commercial use only. The Journal of Rheumatology Copyright © 2006. All rights reserved.

Downloaded on April 19, 2024 from www.jrheum.org

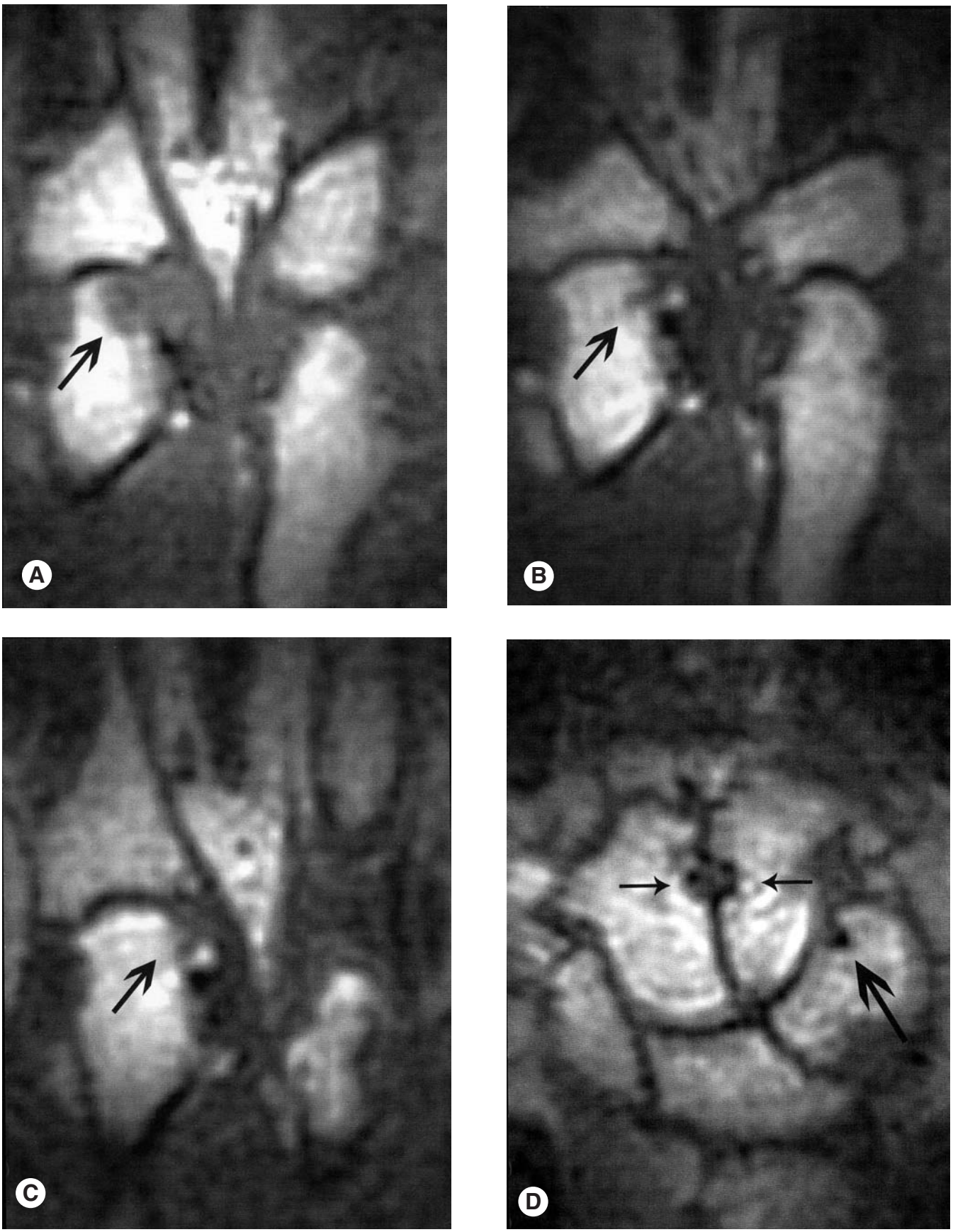

Personal non-commercial use only. The Journal of Rheumatology Copyright © 2006. All rights reserved.

Downloaded on April 19, 2024 from www.jrheum.org

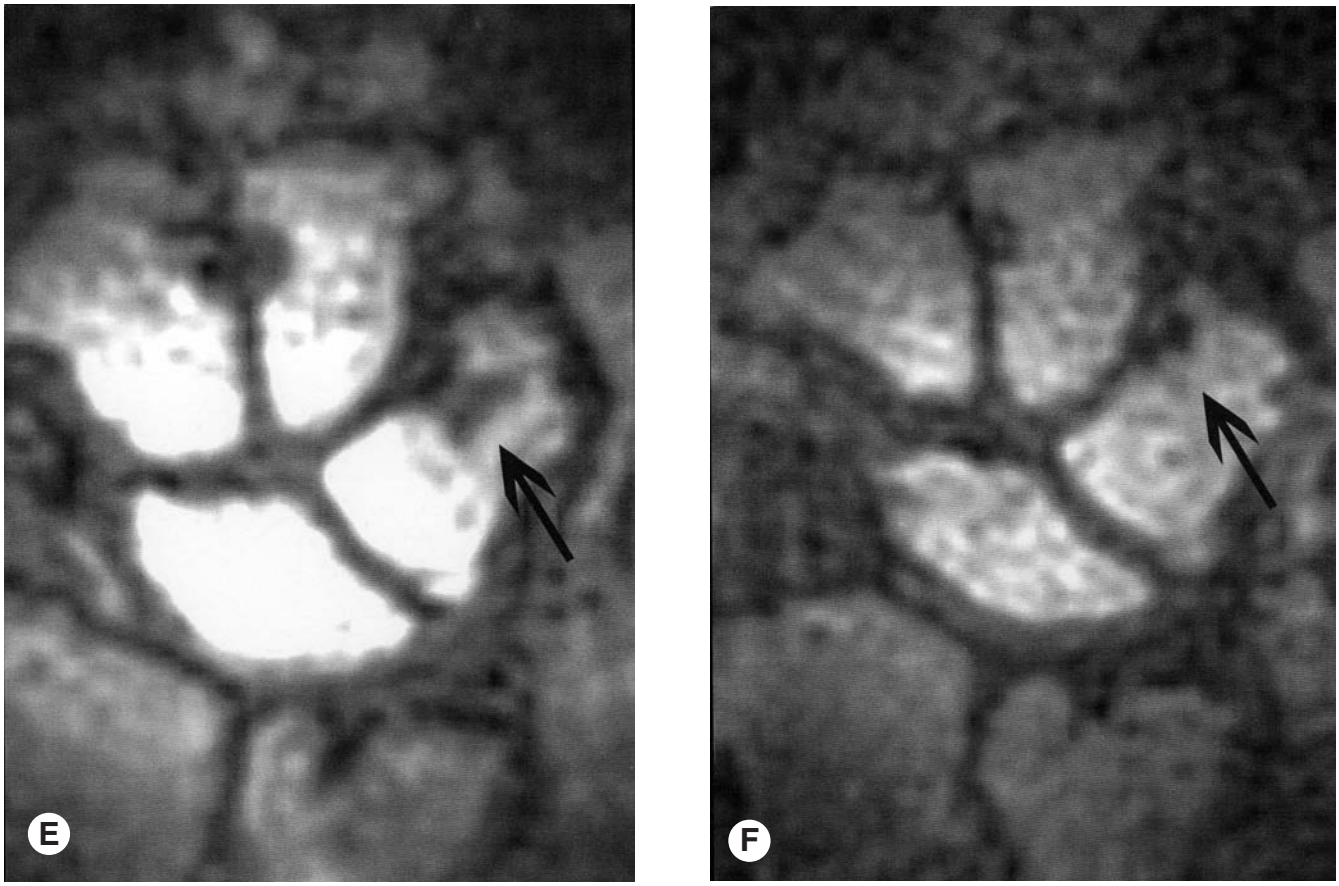

Figure 5. Simultaneous progression and regression of erosions. A. This T1-weighted coronal image shows a subchondral marginal erosion involving the radial aspect of the third MC head (arrow). The patient was given MTX and a TNF-α inhibitor. B. After 6 months on therapy the subchondral lesion markedly improved (arrow). C. Continued improvement is seen after 11 months (arrow). D. The wrist images on the same patient showed an erosion of the distal triquetrum (arrow) at diagnosis. The signal changes in the hamate and capitate are normal ligament insertion sites (small arrows). E. Increase in the size of the distal triquetral erosion is evident after 6 months of treatment (arrow) in the same time interval during which the MCP lesion in panel B decreased in size. F. The distal triquetral erosion decreased in size during the additional 5 months of therapy (arrow).

many patients and the possibility that the mechanism of disease in RA may be ameliorated if checked early[42]. Further, bone destruction can occur even in the absence of clinical and biochemical changes, thus highlighting the need for imaging[11]. Current recommendations that patients should be followed with periodic radiographs should be reconsidered, since radiographic detection of erosions will not occur until significant damage has occurred, precluding the benefits of early treatment[24-27,43]. Prior data showing the increased sensitivity of MRI over plain radiography in detecting bone injury supports a role for MRI in determining when advanced therapy to modify bone injury should be introduced into the treatment decision algorithm for patients with RA[25,44-46]. Our study shows that in-office MRI is significantly more sensitive than projection radiography in detecting changes in bone erosions on the average of 8-month intervals, strongly suggesting that MRI is a better tool than projection radiography in following bone injury response to treatment. Well-defined studies using MRI to follow patients on specific treatment protocols are warranted to confirm this finding.

Criticisms of using MRI instead of plain radiography center on the issues of cost and access, the lack of specificity of MRI in diagnosing RA, and high interobserver variability[19-21]. Standard MRI is more costly than radiography. However, the cost-effectiveness of MRI must be evaluated considering the difference in total costs of treatment and disability between patients managed with and managed without access to MRI information. When this has been evaluated in other areas of the musculoskeletal system, the cost-efficacy of MRI has been favorable[47,48]. Considering the costs of both advanced treatment and disability in RA, it seems likely that similar studies could prove significant cost-efficacy for MRI in RA. Access to MRI is also a concern, especially in areas with relatively low numbers of MRI scanners per population. This problem can be alleviated by the use of portable in-office scanners, which are relatively inexpensive and provide a level of comfort and convenience that traditional scanners cannot. In-office MRI scanners do raise significant issues of self-referral, quality control, and professional expertise that need to be addressed to ensure widespread acceptance[32,49,50].

Personal non-commercial use only. The Journal of Rheumatology Copyright © 2006. All rights reserved.

Downloaded on April 19, 2024 from www.jrheum.org

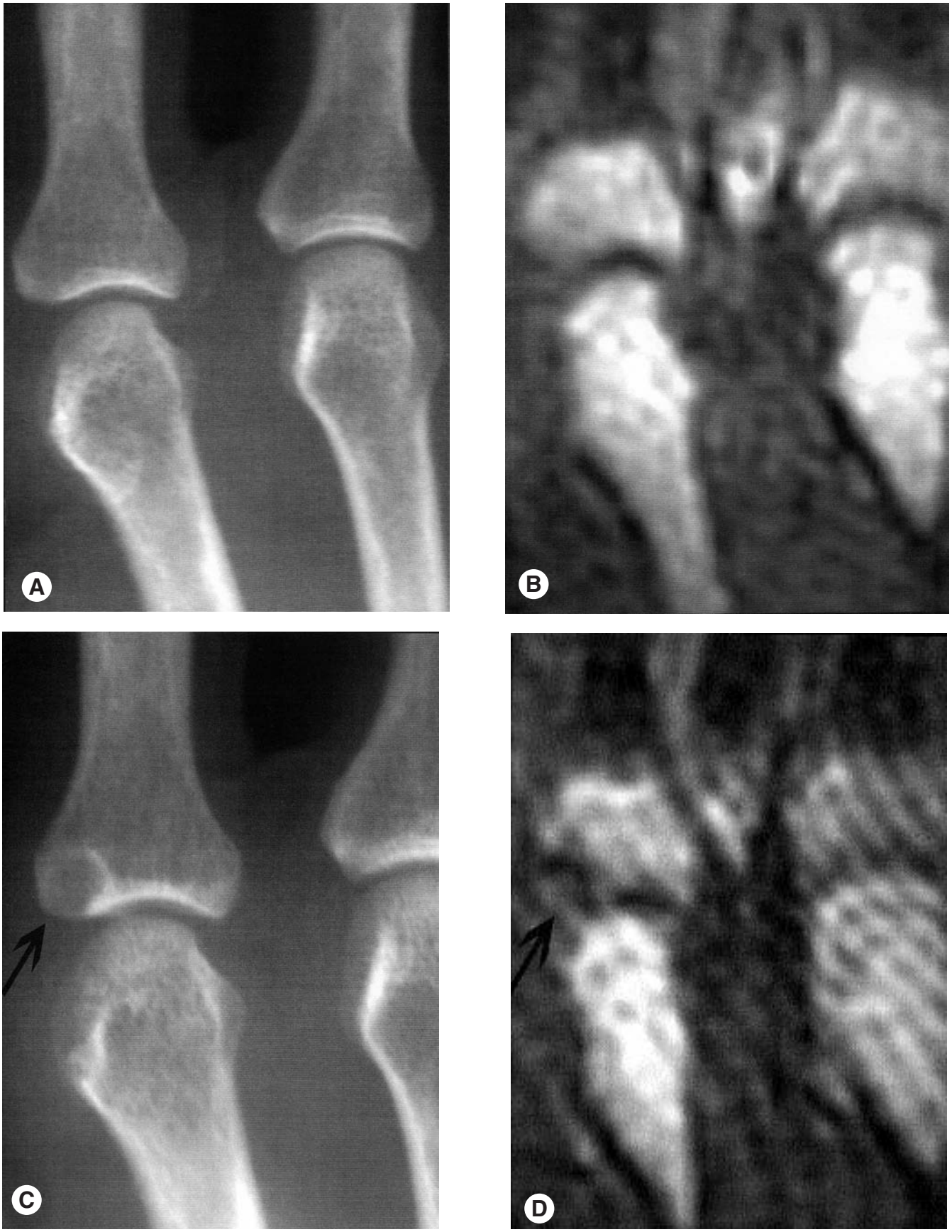

Personal non-commercial use only. The Journal of Rheumatology Copyright © 2006. All rights reserved.

Downloaded on April 19, 2024 from www.jrheum.org

Figure 6 (Oppostie page). New erosion detected by radiograph and MRI. A. PA radiograph obtained on March 27, 2003, showed no erosions of the left second and third MCP. B. The T1-weighted MRI obtained on the same date also showed no erosions. C. The PA radiograph obtained on September 8, 2003, showed a new marginal erosion involving the radial aspect of the second proximal phalanx (arrow). Other new erosions were also present. D. The T1-weighted MRI also shows the new erosion (arrow). Radial-side second MCP erosions are also present, but incompletely seen on this single tomographic slice.

Lastly, there are critics who state that there are no firm guidelines or set criteria for interpreting rheumatologic MRI, leading to high interobserver variability. This is a universal problem with any new imaging modality, including rheumatologic ultrasound[51]. Current recommendations for standardization of RA MRI interpretation using standard scanners have been published, but modifications may be necessary to be applicable to small field-of-view in-office scanners[52-58]. One particular problem we encountered using the Applause in-office scanner in interpreting studies is that the acquisition field of view was only 1 cm in the anterior-posterior direction, often incompletely visualizing the dorsal and volar aspects of the bones. An advantage of this in-office scanner is that it images at significantly higher through-plane resolution than performed in most published studies using whole-body scanners. Through-plane resolution is the spatial resolution in the dimension perpendicular to the plane of the displayed images. This is typically 2.5–3.0 mm in standard high-field imaging. In-plane resolution is the spatial resolution along the 2 dimensions within the plane of imaging, typically 0.4 mm. For spherical lesions, like small erosions, the ability to accurately resolve spatial detail of the lesion is largely dependent on the spatial resolution in the dimension with the lowest resolution, and the importance of high through-plane resolution has been shown to be significant when quantifying volume of pathology, such as articular cartilage in osteoarthritis[59]. Thus, we believe that isotropic or near isotropic imaging is highly advantageous for imaging of inflammatory arthropathies.

However, with isotropic resolution equal to or better than 1 mm in all 3 planes, normal undulations in the bone cortex associated with ligamentous and tendinous insertions, vascular channels, and subchondral cysts that extend to the cortex can simulate small erosions not detectable with lower resolution imaging. This may increase the false-positive findings, since not all erosion-like lesions are related to inflammatory arthritis[19,60,61]. Between 3% and 15% false-positive studies have been described using standard MR imaging. Many of these lesions may be posttraumatic in etiology. Demonstrating changes in erosions in 50% of our examination intervals supports the assumption that many of the bone lesions we have followed in patients with RA are associated with an active inflammatory process. Also, most patients with RA in our study presented with synovial thickening on MRI, consistent with synovitis, whereas the patients without clinical RA that we have evaluated with MRI in workers' compensation injuries rarely present with synovial thickening (unpublished data).

Limitations. Partial-volume artifacts could artificially create the illusion of changes in lesion size if the thickness of the image slice is larger than or on the order of the size of the lesion being evaluated. Since most of the lesions in this study measured from 3 to 6 mm in diameter, through-plane resolution of the order of 2.5 to 4.5 mm used with most traditional large scanners using 2-dimensional Fourier-transform reconstruction techniques (2–4 mm thick slices with 0.5 mm skip) could create artifacts due to geometrical limitations of the scanning technique. In order to minimize this effect, we used 3-dimensional Fourier-transform imaging. With this technique the slice thickness was 1.0 mm at the beginning of the study and 0.625 mm for the latter two-thirds of the study. Unlike the 2-dimensional Fourier-transform technique, there is no skip between slices using a 3-dimensional technique. Consequently, multiple images were obtained through most lesions, so partial volume artifacts are substantially less with this technique than with traditional MRI. Only lesions greater than 2 mm were considered erosions, with most lesions showing changes being larger lesions, where partial-volume artifacts are less problematic. Consequently, we believe that the 20% change in diameter threshold used to signify biologic activity is above measurement variations based on geometric arguments from partial-volume artifacts for most lesions, but this technique is insensitive to 20% changes in lesions less than 5 mm and underreports changes in small erosions. However, repeated measurements of the same patients on the same day were not performed to measure the reproducibility of detection and size measurements of lesions. So some of the interval changes we reported could be variability of measurement inherent in the technique used rather than biologic changes. We believe that these measurement variabilities were minimized due to the use of near isotropic voxel sizes, limiting erosions to lesions greater than 2 mm in size, and requiring that a greater than 20% change in maximum diameter be measured before scoring the change as significant. Further studies are warranted to confirm this assumption.

The overall followup length of our study (2 years) is rather short considering the chronic course of the disease being studied. Longer-term studies would help to confirm the benefits of integrating MRI into the management of these patients. Another limitation of the study is that patient treatment regimen was not controlled. Different treatment protocols and algorithms influence the likelihood of changes in bone erosions. Although all of our patients were taking DMARD therapy, no conclusions can be drawn as to the efficacy of the different therapeutic agents used. Our data are also based on a single observer's interpretations and therefore interobserver variability for interval changes was not measured.

Extrapolation of our findings as representative of a rheumatologist's practice must be done cautiously, as only 405 patients with the diagnosis of RA or PsA seen over a 2-

Personal non-commercial use only. The Journal of Rheumatology Copyright © 2006. All rights reserved.

Downloaded on April 19, 2024 from www.jrheum.org

year period agreed to undergo MR examination. Of these, only 156 patients returned for at least 2 MRI examinations so that an interval comparison could be made. This may have introduced an uncontrolled selection bias in the data.

In conclusion, with the increased recognition of the association of structural bone damage with disability in patients with RA and the efficacy of methotrexate (MTX) and TNF-α inhibitors in controlling the progression of bone injury, accurate measures of erosive disease have garnered increased interest. Both MRI and ultrasound have shown increased sensitivity for detection of erosions and are promising modalities for staging disease burden. We showed that for patients with RA taking DMARD therapy in a single rheumatologist's practice, 50% of compliant patients showed changes in the size of at least one erosion using in-office MRI in an 8-month followup period, as opposed to 1% with 3-view projection radiography. This supports MRI as a promising modality for following patients' structural damage while being treated with DMARD. But further studies are needed to more accurately define the sensitivity and specificity of in-office MRI in evaluating erosive changes in defined patient populations, and to establish a possible role for MRI in patient management.

REFERENCES

1. Goronzy JJ, Weyand CM. Rheumatoid arthritis A. Epidemiology, pathology, and pathogenesis. In: Rock MG, editor. Primer on the rheumatic diseases. Atlanta: The Arthritis Foundation; 2002:209-17.
2. Anderson RJ. Rheumatoid arthritis B. Clinical and laboratory features. In: Rock MG, editor. Primer on the rheumatic diseases. Atlanta: The Arthritis Foundation; 2002:218-25.
3. Kavanaugh A, Han C, Bala M. Functional status and radiographic joint damage are associated with health economic outcomes in patients with rheumatoid arthritis. J Rheumatol 2004;31:849-55.
4. Young A, Dixey J, Kulinskaya E, et al. Which patients stop working because of rheumatoid arthritis? Results of five years' follow up in 732 patients from the Early RA Study (ERAS). Ann Rheum Dis 2002;61:335-40.5.
5. O'Dell JR. Therapeutic strategies for rheumatoid arthritis. N Engl J Med 2004;350:2591-602.
6. Emery P. Evidence supporting the benefit of early intervention in rheumatoid arthritis. J Rheumatol 2002;29 Suppl 66:3-8.
7. Korpela M, Laasonen L, Hannonen P, et al. Retardation of joint damage in patients with early rheumatoid arthritis by initial aggressive treatment with disease-modifying antirheumatic drugs: five-year experience from the FIN-RACo study. Arthritis Rheum 2004;50:2072-81.
8. Landewe RBM. The benefits of early treatment in rheumatoid arthritis: confounding by indication, and the issue of timing. Arthritis Rheum 2003;48:1-5.
9. Olsen NJ, Stein CM. New drugs for rheumatoid arthritis. N Engl J Med 2004;350:2167-79.
10. Smolen JS, Emery P, Bathon J, et al. Treatment of early rheumatoid arthritis with infliximab plus methotrexate or methotrexate alone: preliminary results of the ASPIRE trial. In: European League Against Rheumatism 2003; 2003 June 17-21; Lisbon, Portugal; 2003: OP0001.
11. Molenaar ETH, Voskuyl AE, Dinant HJ, Bezemer PD, Boers M, Dijkmans BAC. Progression of radiologic damage in patients with rheumatoid arthritis in clinical remission. Arthritis Rheum 2004;50:36-42.
12. Ostergaard M, Ejbjerg B, Szkudlarek M. Imaging in early rheumatoid arthritis: roles of magnetic resonance imaging, ultrasonography, conventional radiography and computed tomography. Best Pract Res Clin Rheumatol2005;19:91-116.
13. Boini S, Guillemin E. Radiographic scoring methods as outcome measures in rheumatoid arthritis: properties and advantages. Ann Rheum Dis 2001;60:817-27.
14. Sharp JT. Assessment of radiographic abnormalities in rheumatoid arthritis: what have we accomplished and where should we go from here? J Rheumatol 1995;22:1787-91.
15. van der Heijde D. How to read radiographs according to the Sharp/van der Heijde method. J Rheumatol 2000;27:261-3.
16. D'Agostino MA, Maillefert JF, Said-Nahal R, Breban M, Ravaud P, Dougados M. Detection of small joint synovitis by ultrasonography: the learning curve of rheumatologists. Ann Rheum Dis 2004;63:1284-7.
17. Kane D, Grassi W, Sturrock R, Balint PV. Musculoskeletal ultrasound — a state of the art review in rheumatology. Part 2: Clinical indications for musculoskeletal ultrasound in rheumatology. Rheumatology Oxford 2004;43:829-38.
18. Naredo E, Bonilla G, Gamero F, Uson J, Carmona L, Laffon A. Assessment of inflammatory activity in rheumatoid arthritis: a comparative study of clinical evaluation with grey scale and power Doppler ultrasonography. Ann Rheum Dis 2005;64:375-81.
19. Crues JV, Shellock FG, Dardashti S, James TW, Troum OM. Identification of wrist and metacarpophalangeal joint erosions using a portable magnetic resonance imaging system compared to conventional radiographs. J Rheumatol 2004;31:676-85.
20. Goldbach-Mansky RT, Woodburn J, Yao L, Lipsky PE. Magnetic resonance imaging in the evaluation of bone damage in rheumatoid arthritis: a more precise image or just a more expensive one? Arthritis Rheum 2003;48:585-9.
21. Conaghan PG, Ostergaard M, McGonagle D, O'Connor P, Emery P. The validity and predictive value of magnetic resonance imaging erosions in rheumatoid arthritis: comment on the article by Goldbach-Mansky et al. Arthritis Rheum 2004;50:1009-11.
22. Guermazi A, Taouli B, Lynch JA, Peterfy CG. Imaging of bone erosion in rheumatoid arthritis. Semin Musculoskelet Radiol 2004;8:269-85.
23. McQueen FM, Stewart N, Crabbe J, et al. Magnetic resonance imaging of the wrist in early rheumatoid arthritis reveals a high prevalance of erosions at four months after symptom onset. Ann Rheum Dis 1998;57:350-6.
24. Ostergaard M, Hansen M, Stoltenberg M, et al. New radiographic bone erosions in the wrist of patients with rheumatoid arthritis are detectable with magnetic resonance imaging a median of two years earlier. Arthritis Rheum 2003;48:2128-31.
25. Benton N, Stewart N, Crabbe J, Robinson E, Yeoman S, McQueen FM. MRI of the wrist in early rheumatoid arthritis can be used to predict functional outcome at 6 years. Ann Rheum Dis 2004;63:555-61.
26. McQueen FM, Benton N, Perry D, et al. Bone edema scored on magnetic resonance imaging scans of the dominant carpus at presentation predicts radiologic joint damage of the hands and feet six years later in patients with rheumatoid arthritis. Arthritis Rheum 2003;48:1814-27.
27. Ostergaard M, Hansen M, Stoltenberg M, et al. MRI bone erosions in radiographically non-eroded rheumatoid arthritis wrist joint bones give a 4-fold increased risk of radiographic erosions five years later [abstract]. Arthritis Rheum 2002;46 Suppl:S526-7.
28. Bird P, Kirkham B, Portek I, et al. Documenting damage progression in a two-year longitudinal study of rheumatoid arthritis patients with established disease (the DAMAGE study cohort). Arthritis Rheum 2004;50:1383-9.
29. Mosher TJ. Imaging of rheumatoid arthritis: can MR imaging be

Personal non-commercial use only. The Journal of Rheumatology Copyright © 2006. All rights reserved.

Downloaded on April 19, 2024 from www.jrheum.org

used to monitor cellular response of disease? Radiology 2004;233:1-2.
30. McQueen FM, Benton N, Crabbe J, et al. What is the fate of erosions in early rheumatoid arthritis? Tracking individual lesions using x-rays and magnetic resonance imaging over the first two years of disease. Ann Rheum Dis 2001;60:859-68.
31. Ejbjerg B, Narvestad E, Jacobsen S, Thomsen HS, Ostergaard M. Optimised, low cost, low field dedicated extremity MRI is highly specific and sensitive for synovitis and bone erosions in rheumatoid arthritis wrist and finger joints: a comparison with conventional high-field MRI and radiography. Ann Rheum Dis 2005;64:1280-7.
32. Crues JV III. Extremity MRI. In: Edelman H, Zlatkin MB, Crues JV III, editors. Clinical magnetic resonance imaging. New York: Elsevier; 2005:3649-71.
33. Ostergaard M, Duer A, Moller U, Ejbjerg B. Magnetic resonance imaging of peripheral joints in rheumatic diseases. Best Pract Res Clin Rheumatol 2004;18:861-79.
34. Taouli B, Zaim S, Peterfy CG, et al. Rheumatoid arthritis of the hand and wrist: comparison of three imaging techniques. AJR Am J Roentgenol 2004;182:937-43.
35. Welsing PMJ, Landewe RBM, van Riel PLCM, et al. The relationship between disease activity and radiologic progression in patients with rheumatoid arthritis. Arthritis Rheum 2004;50:2082-93.
36. Perry D, Stewart N, Benton N, et al. Detection of erosions in the rheumatoid hand; a comparative study of multidetector computerized tomography versus magnetic resonance scanning. J Rheumatol 2005;32:256-67.
37. Hau M, Kneitz C, Tony H, Kaberle M, Jahns R, Jenett M. High resolution ultrasound detects a decrease in pannus vascularisation of small finger joints in patients with rheumatoid arthritis receiving treatment with soluble tumour necrosis factor alpha receptor (etanercept). Ann Rheum Dis 2002;61:55-8.
38. Lopez-Ben R, Bernreuter WK, Moreland LW, Alarcon GS. Ultrasound detection of bone erosions in rheumatoid arthritis: a comparison to routine radiographs of the hands and feet. Skel Radiol 2004;33:80-4.
39. Cimmino MA, Innocenti S, Livrone F, Magnaguagno F, Silvertri E, Garlaschi G. Dynamic gadolinium-enhanced magnetic resonance imaging of the wrist in patients with rheumatoid arthritis can discriminate active from inactive disease. Arthritis Rheum 2003;48:1207-13.
40. Ostergaard M, Klarlund M. Importance of timing of post-contrast MRI in rheumatoid arthritis: what happens during the first 60 minutes after IV gadolinium-DTPA? Ann Rheum Dis 2001;60:1050-4.
41. Savnik A, Bliddal H, Nyengaard JR, Thomsen HS. MRI of the arthritic finger joints: Synovial membrane volume determination, a manual vs a stereologic method. Eur Radiol 2002;12:94-8.
42. Drossaers-Bakker KW, Kroon HM, Zwinderman AH, Breedveld FC, Hazes JM. Radiographic damage of large joints in long-term rheumatoid arthritis and its relation to function. Rheumatology Oxford 2000;39:998-1003.
43. Guidelines SoRA. Guidelines for the management of rheumatoid arthritis: 2002 update. Arthritis Rheum 2002;46:328-46.
44. Lindegaard HM, Horslev-Petersen K, Vallo J, Junker P, Ostergaard M. Baseline MRI erosions in early rheumatoid arthritis MCP- and wrist joint bones markedly increase the risk of radiographic erosions at 1 year follow-up [abstract]. Arthritis Rheum 2002;46 Suppl:S521.
45. Quinn M, Conaghan PG, O'Connor P, et al. Very early treatment with infliximab in addition to methotrexate in early, poor-prognosis rheumatoid arthritis reduces magnetic resonance imaging evidence of synovitis and damage, with sustained benefit after infliximab withdrawal. Arthritis Rheum 2005;52:27-35.
46. Schumacher HR, Pessler F, Chen LX. Diagnosing early rheumatoid arthritis (RA). What are the problems and opportunities? Clin Exp Rheumatol 2003;21(5 Suppl 31):S15-9.
47. Bui-Mansfield LT, Youngberg RA, Warme W, Pitcher JD, Nguyen PL. Potential cost savings of MR imaging obtained before arthroscopy of the knee: evaluation of 50 consecutive patients. AJR Am J Roentgenol 1997;168:913-918.
48. Ruwe PA, Wright J, Randall RL, Lynch JK, Jokl P, McCarthy S. Can MR imaging effectively replace diagnostic arthroscopy? Radiology 1992;183:335-9.
49. Kouri BE, Parsons RG, Alpert HR. Physician self-referral for diagnostic imaging: review of the empiric literature. AJR Am J Roentgenol 2002;179:843-50.
50. Litt AW, Ryan DR, Batista D, Perry KN, Lewis RS, Sunshine JH. Relative procedure intensity with self-referral and radiologist referral: extremity radiography. Radiology 2005;235:142-7.
51. Brown AK, O'Connor P, Roberts TE, Wakefield RJ, Karim Z, Emery P. Recommendations for musculoskeletal ultrasonography by rheumatologists: setting global standards for best practice by expert consensus [review]. Arthritis Rheum 2005;53:83-92.
52. Bird P, Ejbjerg B, McQueen FM, Ostergaard M, Lassere M, Edmonds J. OMERACT rheumatoid arthritis magnetic resonance imaging studies. Exercise 5: An international multicenter reliability study using computerized MRI erosion volume measurements. J Rheumatol 2003;30:1380-4.
53. Conaghan PG. An international multicenter longitudinal study assessing reliability of OMERACT MRI scoring in rheumatoid arthritis category [abstract]. Arthritis Rheum 2002;46 Suppl:S526.
54. Conaghan PG, Edmonds J, Emery P, et al. Magnetic resonance imaging in rheumatoid arthritis: summary of OMERACT activities, current status, and plans. J Rheumatol 2001;28:1158-62.
55. Conaghan PG, Lassere M, Ostergaard M, et al. OMERACT rheumatoid arthritis magnetic resonance imaging studies. Exercise 4: An international multicenter longitudinal study using the RE-MRI score. J Rheumatol 2003;30:1376-9.
56. Lassere M, McQueen FM, Ostendorf B, et al. OMERACT rheumatoid arthritis magnetic resonance imaging studies. Exercise 3: An international multicenter reliability study using the RTA-MRI score. J Rheumatol 2003;30:1376-9.
57. Ostergaard M, Bird P, McQueen FM, et al. Development of a new tool for standardised assessment of rheumatoid joint inflammation and destruction: the EULAR-OMERACT magnetic resonance imaging in rheumatoid arthritis reference film atlas [abstract]. Arthritis Rheum 2004;50 Suppl:S169.
58. Ostergaard M, Peterfy CG, Conaghan PG, et al. OMERACT rheumatoid arthritis magnetic resonance imaging studies: core set of MRI acquisitions, joint pathology definitions, and the OMERACT RA-MRI scoring system. J Rheumatol 2003;30:1385-6.
59. Link TM, Sell CA, Masi JN, et al. 3.0 vs 1.5 T MRI in detection of focal cartilage pathology — ROC analysis in an experimental model. Osteoarthritis Cartilage 2005;14:63-70.
60. McQueen F, Ostergaard M, Peterfy CG, et al. Pitfalls in scoring MR images of rheumatoid arthritis wrist and metacarpophalangeal joints. Ann Rheum Dis 2005;64 Suppl 1:i48-55.
61. Ejbjerg B, Narvestad E, Rostrup E, et al. Magnetic resonance imaging of wrist and finger joints in healthy subjects occasionally shows changes resembling erosions and synovitis as seen in rheumatoid arthritis. Arthritis Rheum 2004;50:1097-106.

Personal non-commercial use only. The Journal of Rheumatology Copyright © 2006. All rights reserved.

Downloaded on April 19, 2024 from www.jrheum.org